CONTRIBUTIONS TO EMBRYOLOGY

VOLUME XII, No. 56

PUBLISHED BY THE CARNEGIE INSTITUTION OF WASHINGTON
WASHINGTON, 1921

CARNEGIE INSTITUTION OF WASHINGTON

PUBLICATION No. 275

PRESS OF A. B. GRAHAM CO.
WASHINGTON

CONTRIBUTIONS TO EMBRYOLOGY, No. 56.

STUDIES ON ABORTUSES: A SURVEY OF PATHOLOGIC OVA IN THE CARNEGIE EMBRYOLOGICAL COLLECTION.

By Franklin Paine Mall and Arthur William Meyer.

With twenty-four plates, five text-figures, and one chart.

16517

CONTENTS.

		PAGE
PREFACE.	By A. W. MEYER	5–11
CHAPTER I.	Origin of the collection. By F. P. MALL	13–24
II.	Care and utilization of the collection. By F. P. MALL	25–40
III.	Classification. By A. W. MEYER	41–49
IV.	Analysis of abortuses classed as pathologic. By A. W. MEYER. (Plates 1–6.)	51–170
	Group 1: Specimens composed of villi only	51–59
	Group 2: Chorion without amnion or cyema	60–69
	Group 3: Chorion with amnion	69–74
	Group 4: Chorionic vesicles with nodular cyemata	74–81
	Group 5: Cylindrical cyemata	81–85
	Group 6: Stunted cyemata	85–92
	Group 7: Fetus compressus	92–102
	Summary	102–107
	Protocols	107–170
V.	Relation of cyemic to chorionic size. By A. W. MEYER	171–176
VI.	Sex incidence in abortions. By A. H. SCHULTZ	177–191
VII.	Occurrence of localized anomalies in human embryos and fetuses. By F. P. MALL. (Plate 7.)	193–202
VIII.	Hydatiform degeneration in uterine pregnancy. By A. W. MEYER. (Plates 8–12.)	203–231
IX.	Hydatiform degeneration in tubal pregnancy. By A. W. MEYER (Plate 13.)	233–242
X.	The alleged occurrence of superfetation. By A. W. MEYER. (Plate 14.)	243–250
XI.	Ovarian pregnancy. By F. P. MALL and A. W. MEYER. (Plates 15 and 16.)	251–266
XII.	Lysis and resorption of conceptuses. By A. W. MEYER	267–279
XIII.	Post-mortem intrauterine changes. By A. W. MEYER. (Plates 17–19.)	281–300
XIV.	Hofbauer cells in normal and pathologic conceptuses. By A. W. MEYER. (Plate 20.)	301–314
XV.	The villi in abortuses. By A. W. MEYER. (Plates 21–23.)	315–326
XVI.	Villous nodules. By A. W. MEYER. (Plate 24.)	327–331
XVII.	Changes suggestive of lues. By A. W. MEYER	333–338
XVIII.	Some aspects of abortion. By A. W. MEYER	339–356
BIBLIOGRAPHY		357–364

STUDIES ON ABORTUSES: A SURVEY OF PATHOLOGIC OVA IN THE CARNEGIE EMBRYOLOGICAL COLLECTION.

PREFACE.

The following survey comprises a review and an analysis of conceptuses which are classed as pathologic in the first 1,000 accessions to the collection of the Department of Embryology of the Carnegie Institution of Washington. The majority of these accessions were included in the Johns Hopkins Medical School collection. They had been collected with untiring effort by Professor Mall, with the generous coöperation of numerous physicians, both at home and abroad, during the course of two decades. The accompanying studies on special topics are not, however, so limited, nor are they confined to pathologic conceptuses only. Although closely related, they aim neither at completeness nor even at unity, except as individual contributions. Since, with the exception of the tables, the survey proper is limited to the first 1,200 accessions, with only such references to the remainder of the collection as time permitted, it is very probable that some of the results and conclusions drawn from them will not be fully supported by an extension of this study to the material in the entire collection. This is due not only to the fact that the abortuses received more recently are better preserved and that the later histories are fuller, but also to the increasingly closer coöperation with clinicians which often brings us very helpful clinical sidelights. Indeed, it is this coöperation which alone can enable us satisfactorily to develop certain aspects of the new field of antenatal pathology, and help to bring a final answer to some of the many unsettled questions. Without the information which the practitioner alone can furnish one often feels helpless; for although many of the specimens are eloquent with facts, others remain entirely mute as to their story because they appear wholly normal.

The much larger series of abortuses composing the entire collection also includes unique specimens which are the product of some rare experiment on the part of nature. One is much less likely to find such specimens in a smaller and hence less representative collection. What is lacking, however, in connection with many of the specimens, otherwise so valuable, is the decidua. In the absence of the latter it is often impossible to reach even a tentative conclusion regarding the genesis of the abnormalities found in a particular specimen. In many instances this defect could be easily remedied by an appeal to our many coworkers and benefactors engaged in the practice of medicine. I am certain that they will gladly save the decidua whenever possible, merely as a matter of coöperation, although

NOTE—In view of the suggestions made in *Science* (A. W. Meyer, 1919: A suggestion from Plato, with others, vol. 49, p. 530) some of which have been incorporated in the following pages, the title of this volume demands a word of explanation. I have retained the word *ova* because the title had in part been decided upon. Moreover, the word is still used in this sense in current medical literature, but we are not considering *ova* but *conceptuses*. Besides, a considerable percentage of these undoubtedly are not pathologic or diseased, for surely post-mortem changes in structure, however profound, can not strictly be regarded as pathologic; and since derangement of function is made impossible by death, no matter how deformed or how infiltrated the tissues of an abortus may be with the cells of maternal origin, it can not therefore be said to be diseased.—A. W. M.

it need not be forgotten that the assistance we can give to donors when reporting our findings is very largely contingent upon its preservation. It is true that in the course of time, and even now to some extent, we shall be able to give a report suggestive of the possible intrauterine conditions from an examination of the conceptus alone, and just in proportion as our knowledge of the condition of the decidua increases this opinion will become more reliable, and hence also of more practical value.

The chief reason why the decidua, or the membranes, or the placenta are not preserved oftener is that physicians have not fully realized that they are needed and wanted. A mere reference to the protocols and summaries will illustrate in how large a percentage of the cases it is not included at present. Although I fully realize that often it is impossible for the physician to secure it, and that in other cases it is of little value even when secured, I am certain that the percentage of cases in which it is missing can be greatly reduced in the future with consequent mutual benefit. The closest coöperation with clinicians is necessary, not only in order to secure the necessary material, but also to obtain further information through supplementary observations upon the living patient. Only in this way can the great gap left in human obstetrics and embryology, by the impossibility of performing experiments, be partly filled. In the case of animals, experimentation no doubt will eventually determine for us the relationship of teratology to pathology, but in the case of man this relationship must be determined very largely by observation alone, for although every instance of human gestation under abnormal conditions answers to an experiment, such experiments must always remain uncontrolled, and the exact conditions which usually obtain must remain unascertainable. Nevertheless, the practitioner, with the patient's help, frequently can bear witness as to the conditions under which nature's experiment was performed and as to the sequence of crucial events, and it is on the unselfish efforts of physicians that we must depend for assistance in this matter.

Mall did a very great service in calling attention to the fact that abnormalities of the fetus are frequently associated with, even if not always or necessarily produced by, uterine diseases. The relationship between the two is revealed still further, especially in Chapter IV, and further investigation of this subject ought to bring to light facts not only of further scientific interest, but pregnant with great humanitarian service. It is startling indeed to observe what a monstrous fetus may accompany an *apparently* moderately diseased chorion, and it is equally startling to observe that a chorionic vesicle *apparently* normal may be wholly devoid of an embryo. But here we meet one of the obstacles in the way of present progress, for we do not yet know exactly what a normal ovum or villus looks like in all stages of development. Both must yet be standardized, and for this standardization a knowledge of the condition of the decidua and of the probable cause of the abortion will be extremely helpful. If all early conceptuses were undoubtedly normal, the problem would be a simple one; but very many are abnormal or atypical at least.

As our knowledge of the normal becomes more complete, we find that more and more young embryos which formerly were regarded as normal are not really so. The literature of human embryology contains many such instances, and it was impossible, and it remains impossible even at the present time, to determine in all cases whether we are dealing with a normal or an abnormal specimen, even after it has been mounted in serial sections. Hence it happens that abnormal human embryos and fetuses still are represented as normal in contemporary embryologies. It has often seemed to me that there is one source of material which could bring much help in this connection. If the many tragedies with which our coroners come in contact could always be utilized scientifically, as they rarely have been in the past, much desired information would soon be in our possession. It seems that a very promising opportunity for progress lies here. In an intelligent community public opinion will, I believe, gladly support any one in such utilization of these chance cases as soon as a broadly humanitarian, even if not a keenly scientific, attitude can be cultivated on the part of our coroners.

What can be accomplished through coöperation between public officials and laboratory workers was illustrated by the fine assistance given Professor Mall and the Department of Embryology of the Carnegie Institution of Washington by the department of health of the city of Baltimore. Indeed, one can not recall this service without feeling the deepest regret that similar coöperation, especially with coroners, has not yet been realized in more American municipalities. Such coöperation, supplemented by that of the practitioner, especially in obstetrics and gynecology, can accomplish much in the course of years. But coöperation between laboratory workers also is necessary. Even the chemist, not only the pathologist, is indispensable. Without him the anatomist often is helpless. Here, for example, is an unopened, fairly normal looking abortus composed of a clean conceptus. The periamniotic fluid, to all appearances, is absolutely normal. The interior of the chorionic vesicle also appears normal. The amniotic vesicle, although much smaller than one would expect, is normal in all other respects and distended moderately with perfectly clear and absolutely normal-looking fluid; yet such a conceptus may contain not even a trace of an embryo, even if the yolk-sac still looks normal. Such specimens are rare, but they occur, and one of the things wholly inexplicable to the anatomist is not so much the absence of the embryo as the fact that its disintegration has not resulted in the least turbidity of or deposit in the amniotic fluid or the dissolution of the amnion. Even a microscopic examination of the fluid may fail to reveal any cellular content. The anatomist desires to know not merely in what respects the composition of the intra-amniotic and periamniotic fluids has been changed, but what the enzymes are that have caused the complete lysis of the embryo, from what these arise, and how they become active. These and many other questions the chemist only can answer. For this answer fresh material is indispensable, but this the neighboring practitioners or a closely associated clinic can supply. I am aware of the fact that chemists and physiologists have not neglected these questions, but at present our knowledge

regarding these matters seems quite insufficient to enable one to formulate satisfactory hypotheses regarding many of the phenomena encountered in abortuses. To enable us to do this a much better localization and identification of the enzymes concerned would seem to be necessary.

That the dissolution of these early embryos, and undoubtedly also of the chorionic vesicles, is not due primarily or even very materially to phagocytic activity, is very evident, even upon cursory examination. In the presence of the intact chorionic and amniotic vesicles such a process is wholly excluded. Besides, one never sees any evidence of phagocytosis of the preserved fetal by the maternal tissues in human conceptuses, although evidences of the contrary processes are not wanting.

In considering some of the many problems of human antenatal pathology, it seems very probable that much light can be thrown upon them by comparative experimental pathology and studies in comparative gestation. A reliable knowledge of the comparative incidence of abnormalities in man and higher vertebrates alone would be of great value. The same thing would be true of a knowledge of the comparative incidence of uterine and ovarian or testicular disease and abnormalities of the uterine mucosa. Indeed, until these and other similar and related questions have received at least a partial answer, it will always remain rather venturesome to draw final conclusions regarding many things in human antenatal pathology, for the first question that always must be answered in connection with a particular specimen is that of its normality or pathogenicity.

His, Giacomini, and Mall took up this problem with especial devotion and have done much to lay the basis for the accomplishment of the task set for pathologic embryology by Müller (1847). Müller stated that it was the task of the pathological anatomy of prenatal life to show the progressive steps leading from the slightest deviation from the normal to the most pronounced deformity. This task is only begun and progress naturally will be slow, especially in connection with early forms, until we can discriminate better between the normal and the abnormal and the pathologic.

A comparison of the clinical data relating to infection, with the microscopic findings, will show that the correspondence is extremely slight. This is not surprising, for physicians themselves often emphasize that the history probably is quite untrustworthy. Moreover, the clinical diagnosis of infection is usually based upon the presence of fever, a putrid discharge, or certain symptoms usually regarded as indicative of fever. If the clinical reports regarding infection were based upon bacteriologic or even upon histologic examination, they would undoubtedly agree better with our findings. These showed the presence of infection, as indicated by infiltration of the decidua or by abscess formation, in a large percentage of the cases in which the decidua was present, in the specimens falling into the first five groups.

The unavoidable confusion resulting from the use of the word *ovum* to designate the unfertilized female sex-cell, this cell when fertilized, the chorionic and amniotic vesicles with or without the embryo, and even the later product of con-

ception in any and all stages of development, even up to birth, has prompted me to resort to additional terms. It certainly would seem best to restrict the term *ovum* to its comparative embryological significance and thus avoid confusion. But this restriction leaves us without a word to designate the whole product of conception. For this the word *conceptus* seemed available. At present the word *embryo* is frequently used loosely to designate conceptuses of any age. It is used still more frequently to designate merely the body of the future individual during the early stages of its development, in contradistinction to the word *fetus*, which usually is restricted to the later months. Hence we have need for still another term to be used in common for the embryonic disk, the embryo, or the fetus. Dr. Schultz has kindly suggested *kyema*, which Professor Foster suggests is preferably spelled *cyema*, adding that it is excellent Greek and was used in the proposed sense by Plato himself. It also has the advantage of being available for comparative embryology and of being easily adapted to meet such needs as are represented by the terms *cyemetric* and *cyemology*. Change may not imply improvement or progress, but the absence of it certainly never does. I realize fully that the use of unnecessary terms is to be avoided, but this is equally true of awkward circumlocution and misunderstanding. When one writes or says at present that no embryonic remnants were seen, it is impossible to know what is meant. Although the word *embryo* could by common consent be used in the proposed sense of *cyema*, long usage probably would make such an attempt futile for this reason alone. The use of this term and of others, presently to be suggested, does not change old meanings or old usage. It abrogates nothing save confusion.

Although the word *abortion* is available to designate the individual or the material aborted, it has not been the custom to use it in this inclusive sense. The word abortion, as now used, is usually restricted to the act itself. To use it in a double sense would lead to some confusion. Since blood-clot, pus, decidua, and mucosa usually are not only included with but frequently also surround the entire conceptus, I have used the word *abortus* to designate all the material expelled during an abortion. Only in this way can one avoid the use of such words as *ovum*, *mole*, *chorion*, and such expressions as *the entire mass*, *embryonic mass*, *abortion mass*, or (quite inaccurately) the *chorionic vesicle*, even when the latter is surrounded by a certain amount of decidua and blood-clot.

Since the term *fetus compressus*, as customarily used, refers to a twin fetus which died and was later subjected to pressure from the surviving, growing fetus during an extended period of time while it was undergoing mummification, the use of this term in Chapters III and IV requires definition. Practically all the specimens so designated in this survey are single, not twin. Besides, they have but rarely been subjected to pressure, and not a single specimen is dehydrated to the extent of being papyraceous. Rarely, when fetuses so termed have been subjected to pressure, this was the pressure of the contracted uterus subsequent to the absorption of the amniotic fluid. In many instances, however, these specimens were contained in a quantity of amniotic fluid sufficient to be protected from direct pressure of the uterus transmitted through the fetal membranes. More-

over, since all these, as well as the specimens of group 7, are macerated, and since all manner of gradations are found between the macerated swollen and the macerated wrinkled (fetus compressus) specimen, it may be preferable to restrict this term to its original usage. Much would also seem to be gained by an abandonment of such terms as *decidua vera* and *serotina*, which, although historical, convey false suggestions. The occurrence of a psuedo decidua does not seem to be at all established, and the sense in which the term *vera* was first used necessarily has been lost in the progress of modern embryology. The same thing applies to the term *serotina*. Hence, as suggested by others, it would seem preferable to speak of a *parietal*, a *basal*, and a *capsular* decidua, and finally relinquish the older terms.

In order to avoid possible confusion through the introduction of new terms, I have added the following diagram, which presents their relationship at a glance:

Abortus.

Conceptus.

Blood-clot.
Decidua.
Pus, etc.

Chorionic vesicle.
Amniotic vesicle.
Umbilical vesicle.
Amniotic fluid—magma.
Periamniotic fluid.
Umbilical cord.

or

Secundines—placenta and membranes.
Yolk-sac.
Cord.
Liquor amnii.

Cyema....{Embryonic disk.
Embryo.
Fetus.

In spite of the fact that some great names have long been associated with the rising subject of the pathology of human development, a routine examination of abortuses seems quite worthless to many investigators. This is natural, for, aside from the poor preservation of many of these abortuses, the conditions under which nature performs her experiments on man necessarily are uncontrolled and often also unknown. But there would seem to be no reason for rejecting any testimony which such experiments may offer, though the search be a long and a disappointing one and the conditions not standard. To regard all attempts at a study of these specimens as futile is very largely to abandon man to a cruel fate. He never can be made the subject of accurately controlled experiment or a wholly satisfying study. The rigid requirements of scientific investigation must, in the nature of things, almost always remain unfulfilled. Comparative anatomy, medicine, and pathology, as well as experiments upon animals, undoubtedly offer greater returns merely because the subject of experiment can be bred, nurtured, and sacrificed at the will and by the hand of man. But if it be conceded that in the last analysis the aim of all human effort must be directed toward the amelioration of the lot of mankind, then it would be folly to reject even the chance stalk that may spring from the grain of wheat which lay hidden in a bushel of chaff.

The conception, as well as the general plan, of this volume is that of Professor Mall himself. It was my happy experience to be invited to share in both. An unkind fate made it impossible for Professor Mall to complete his own work; for his part everyone will feel deeply grateful; for the part that might have been his, others than myself will feel an immeasurable regret.

Although the table of contents had not been prepared, the possible scope of the volume and the order of the topics had often been considered. It was the intention not only to read each other's chapters, but to discuss and revise them together. With characteristic generosity, Professor Mall suggested that, except for one chapter not contributed by either one of us (Chapter VI), we share equally in that part of the undertaking not included in the special studies. Partly in accordance with this desire, he wrote the introductory chapters in the first person plural, much against my earnest remonstrance, for my share in them is quite negligible. However, since they had been considered together they stand as he wrote them, except for a few footnotes. Unfortunately, only one of my studies was in final form before his death, but he was familiar with it, although we had not considered the paper together. Since all the remainder of my part was written subsequently, it did not seem justifiable to me to charge him with responsibility for conclusions of my own or for personal opinions which might not have commended themselves to him.

It is with the greatest satisfaction that I record in this connection his decision to mutually consider all points of difference and, if common ground could not be found, to state frankly our individual views. It was characteristic of him never to use the weight of his authority in the discussion of controverted questions—or to influence anyone's conclusions. He was ever willing to leave the truth to the future. It was this attitude that made the completion of this unfinished work a very satisfying effort, even if lonely and in some respects unsatisfactory. Chapters I, II, and VIII, and all the protocols at the end of Chapter IV, below No. 1,000, fortunately had been written by him. However, in accordance with his intentions, protocols were revised and a number of them entirely rewritten. Since he himself had requested this in the case of several which we considered together, I feel that I have merely followed his desire in this matter. In the exercise of this privilege and duty of revision I have used the greatest care to preserve his descriptions as far as possible. Indeed, in the completion of this volume, it has been my constant purpose to follow his plan, to preserve his views, and to realize his intentions. Although I feel the deepest scientific interest in this work, it has also been a labor of love and devotion, and it was a great satisfaction that its continuation was made possible by the Carnegie Institution of Washington, and that its realization was furthered in every way by my friend and former colleague, Dr. George L. Streeter.

Since these studies were completed very largely during 1918 and the spring of 1919, no references are made to the recent literature in a large portion of the volume.

A. W. Meyer.

CHAPTER I.

ORIGIN OF THE COLLECTION.

The collection of human embryos belonging to the Carnegie Institution of Washington owes its origin to thirty years of untiring effort on the part of one of the authors (Mall). The first specimen was obtained while he was a student under Professor Welch in the Pathological Department of the Johns Hopkins University; very soon another, in excellent state of preservation, was added. After his (Mall's) transfer to Clark University in 1899, embryo No. 2 was studied and modeled in wax. This was the first reconstruction of a human embryo ever made in America and at that time the most elaborate one in existence. In 1890 this specimen was offered to Professor His, who refused to accept the gift, and returned it, together with several from his own collection, expressing the hope that this small number of specimens might serve as a nucleus for a much larger collection. With the subsequent foundation of the University of Chicago, the collection was transferred there, and during the following year a few additions were made. Now somewhat augmented, it was returned to Baltimore in 1893, at the opening of the Johns Hopkins Medical School, and here it grew for a number of years, at first slowly, then more rapidly, until it was finally taken over by the Carnegie Institution of Washington in 1915.

In the beginning each specimen was labeled with the name of the physician who donated it, but it was soon found that this method was not accurate. Bottles were easily misplaced and notes lost from the files were not missed unless marked with consecutive numbers. Therefore, after the collection had grown to about 100 specimens, a system of numbering, somewhat in the order of accession, was adopted. However, a review of the catalogue later disclosed the fact that some of the specimens collected at Worcester followed in numerical order those collected at Chicago, so that for the first 100 specimens the sequence of accession can not be viewed as chronologically reliable. From an examination of table 1, in which the specimens are arranged in hundreds (or centuries), it will be observed that the first century includes catalogue numbers 1 to 98, the second century, 99 to 205, etc. These numerical discrepancies are due to the fact that quite frequently the same number is given to two or more specimens, as illustrated in the first century; or, as illustrated in the second century, a number once used may be discarded subsequently because the specimen is found to contain no remnants of an ovum. The latter specimens are finally marked on the catalogue card "No pregnancy." In this way we have been able to retain in the catalogues of the collection ovaries and uteri from non-pregnant women. The second column of the table shows the time required to collect each 100 specimens. It took 10 years for the first, 4 for the second, and 2 for the third 100; but after the collection had been transferred to the Carnegie Institution, about 400 specimens were collected in one year. It will be observed also that approximately 60 physicians contributed

TABLE 1.—*Showing gradual growth of collection.*

Centuries.	Catalogue No.	When collected.	Time.			No. of physicians.	Contributing	
			yr.	mo.	day		Hospitals.	States and countries.
1	1 to 98	1887, to June 1, 1897	10			57	0	21
2	99 to 205	June 1, 1897, to Apr. 19, 1902	4	8	18	53	6	18
3	206 to 295	May 22, 1902, to Mar. 1, 1905	2	9	9	59	4	14
4	296 to 380	Mar. 1, 1905, to Jan. 1, 1907	1	10	0	39	4	13
5	381 to 476	Jan. 2, 1907, to Jan. 1, 1911	3	11	29	55	8	17
6	477 to 571	Jan. 1, 1911, to Feb. 10, 1912	1	1	9	53	8	17
7	572 to 652c	Feb. 10, 1912, to Mar. 1, 1913	1	0	21	49	5	16
8	652d to 729	Mar. 1, 1913, to July 19, 1913	0	5	18	65	14	19
9	730 to 816b	July 19, 1913, to Jan. 9, 1914	0	5	20	62	13	21
10	817 to 900g	Jan. 9, 1914, to May 27, 1914	0	4	18	66	13	23
11	900h to 964	May 27, 1914, to Oct. 24, 1914	0	4	27	54	13	14
12	965 to 1028	Oct. 27, 1914, to Dec. 19, 1914	0	1	22	49	6	11
13	1029 to 1126b	Dec. 19, 1914, to Apr. 8, 1915	0	3	19	75	12	17
14	1127a to 1202	Apr. 8, 1915, to June 5, 1915	0	1	27	65	14	21
15	1203 to 1292	June 7, 1915, to Oct. 15, 1915	0	4	8	69	10	18
16	1293 to 1365	Oct. 19, 1915, to Jan. 17, 1916	0	2	28	57	8	19
17	1366 to 1458	Jan. 18, 1916, to May 17, 1916	0	3	29	60	9	15
18	1459 to 1545	May 19, 1916, to Aug. 7, 1916	0	3	18	56	12	21
19	1546 to 1641	Aug. 9, 1916, to Dec. 13, 1916	0	4	4	77	10	15
20	1642a to 1728	Dec. 15, 1916, to Mar. 3, 1917	0	2	18	60	10	12
21	1729 to 1829b	Mar. 5, 1917, to June 15, 1917	0	3	10	69	7	15
22	1830 to 1900/25	June 15, 1917, to Aug. 27, 1917	0	2	14	40	5	10
23	1900/26 to 1901/76	(?) (?)		(?)		(?)	(?)	(?)
24	1901/77 to 1956a	Aug. 27, 1917, to Nov. 22, 1917	0	2	25	34	5	11
25	1956b to 2051	Nov. 22, 1917, to Mar. 18, 1918	0	3	26	54	5	13

to the collection of each 100 specimens, of which number 8 (or about 13 per cent) resided in hospitals. The last column of the table shows the territorial source of each century, representing an average of 18 States from which material has been drawn. Upon comparing columns 2 and 3, it becomes apparent that by far the largest portion of the collection has come from physicians in private practice. Yet nearly all of our perfect specimens were obtained from hospitals. This is easily understood when one considers that only when the operator is near can perfectly fresh embryos be secured. In several instances these have been brought to the laboratory still living.

Table 2 gives a list of the contributing hospitals, with the number of specimens from each. As would be expected, the majority of the specimens came from hospitals located in Baltimore; second in order is New York, and third Manila, Philippine Islands. Naturally, the Johns Hopkins Hospital contributes the largest number, for its work is intimately related to our own and the members of its staff frequently are interested in embryological studies, both in this laboratory and in the clinical laboratories of the hospital. Hence we receive all of the embryological specimens found at operation.

Attention is called to the large number of specimens emanating from a single hospital in Manila. This is due to the fact that this hospital numbers among its staff several graduates from the Johns Hopkins Medical School, and these have responded loyally to our request for Filipino embryos for a study of racial embryology.

TABLE 2.—*List of hospitals and laboratories contributing embryological material.*

Hospitals and laboratories contributing embryological material.	Century 1.	Century 2.	Century 3.	Century 4.	Century 5.	Century 6.	Century 7.	Century 8.	Century 9.	Century 10.	Century 11.	Century 12.	Century 13.	Century 14.	Century 15.	Century 16.	Century 17.	Century 18.	Century 19.	Century 20.	Century 21.	Century 22.	Century 23.	Century 24.	Century 25.	Total.
Johns Hopkins, Baltimore		4		6	11	6		5	12	11	5	5	9	5	6	1	14	9	12	13	17	3		5	17	176
Maryland General, Baltimore		1																								1
Union Protestant, Baltimore		1	1		2	1											2	1								8
Church Home, Baltimore				1		4	1	1	1		4	1	1	1	2		1		3			1				22
Hebrew, Baltimore					1	1		2	3	4	2	2	7		1	2	1	2	2						3	33
Woman's, Baltimore						1				1	2		1							2				1		8
St. Agnes, Baltimore							1	1		1		1	1	2					2	1	5	1		1		17
St. Joseph's, Baltimore								1																		1
University, Baltimore								1																		1
Franklin Square, Baltimore									1		1								1							3
The Howard A. Kelly, Baltimore			1																1	1						3
Mercy, Baltimore																									1	1
Frederick City, Maryland						2		1	1							1										5
DuPont Maternity, Cambridge, Maryland																	3		1	2	1					7
Physicians and Surgeons, New York		1			2																					3
City, Blackwell's Island, New York		1																								1
Society of New York, New York						1																				1
Brooklyn, New York						2	1														1					4
Bellevue and Allied, New York							4	2	12				1	15				5								39
Roosevelt, New York								1					1													2
Kings County, New York									2	1				5	6	13				3				6	4	40
Lying-In, New York											9					9										18
Polyclinic, New York													1													1
Presbyterian, New York															1											1
French, New York																2										2
Woman's, New York																					1					1
Bender Hygienic, Albany, New York			1	5	3			1																		10
St. Peters, Albany, New York														1												1
Samaritan, Troy, New York									2					1												3
Ontario County, Canandaigua, New York						1			2																	3
State Inst. for Study of Malig. Diseases, Buffalo, New York													1													1
Adrian, Punxsutawney, Pennsylvania						1																				1
German, Philadelphia								1																		1
Allegheny General, Pittsburgh, Pennsylvania									1																	1
St. Francis, Pittsburgh, Pennsylvania														2												2
Pennsylvania, Philadelphia															1				4							5
Gynecean, Philadelphia																	1	1								2
Bellefonte, Bellefonte, Pennsylvania																1										1
Woman's, Philadelphia																				1						1
Christ, Jersey City, New Jersey								1																		1
Orange Memorial, Orange, New Jersey										1																1
Jefferson Surgical, Roanoke, Virginia									1	2	1							1	4	3	3					15
Dr. Tyler's Surgical, Greenville, S. C									2	2				6	2		1									13
Marine Eye and Ear, Portland, Maine								1		1	1															3
New England, Boston, Massachusetts			2		1																					3
Boston City, Boston				1																						1
Union, Fall River, Massachusetts														1												1
Memorial, Worcester, Massachusetts															2											2
Bridgeport General, Bridgeport, Connecticut									6	3	2		2								4	9				26
Hartford, Hartford, Connecticut								3																		3
Yale University, New Haven, Connecticut																		1								1
Lakeside, Cleveland, Ohio											1															1
Post, Fort Wayne, Michigan							2																			2
Mercy, Denver, Colorado																				1						1
County, Los Angeles, California																						12		8		20
University, Berkeley, California													1													1
L. D. S., Salt Lake City, Utah														3				4								7
Rodgers, Tucson, Arizona														2												2
Crouse, El Paso, Texas													1					9		8						18
Augustana, Chicago															1											1
Clinical and Pathological, Springfield, Ill														1												1
St. John's, Springfield, Illinois		1																								1
Procter, Peoria, Illinois											1															1
St. Francis, Peoria, Illinois																			1							1
Laboratory State Board of Health, Tampa, Fla.																	1	1								2

TABLE 2.—*List of hospitals and laboratories contributing embryological material*—Continued.

Hospitals and laboratories contributing embryological material.	Century 1.	Century 2.	Century 3.	Century 4.	Century 5.	Century 6.	Century 7.	Century 8.	Century 9.	Century 10.	Century 11.	Century 12.	Century 13.	Century 14.	Century 15.	Century 16.	Century 17.	Century 18.	Century 19.	Century 20.	Century 21.	Century 22.	Century 23.	Century 24.	Century 25.	Total.
Walter Reed General, Washington, D. C.										1																1
Garfield, Washington, D. C.											1															1
Mercy, Arkansas City, Kansas																		1								1
Montreal General, Montreal														1												1
Port Simpson, Port Simpson, British Col.																	1								4	5
Philippine General, Manila, Philippine Is.										7	12	8														27
Imperial University, Tokyo, Japan																3										3
Severance Union, Korea																		1								1
Sunday School, A. P. M., Changteh, China										2					1											3
Quaker, Nanking, China													1													1
Total	0	9	5	13	22	18	9	22	46	37	42	18	27	46	23	32	25	36	31	35	32	26	0	21	29	604

In order to obtain good specimens from hospitals, it is necessary that surgeons and pathologists connected therewith be sufficiently interested in embryology to preserve and transmit to this department any valuable specimens obtained at operations. Only in this way can we secure human embryos in as good preservation as those from the lower animals. It is very gratifying that in several instances authorities of hospitals have passed resolutions requesting the members of their respective staffs to send all of their embryological material to this department. Upon the receipt of a specimen it is described, the records filed, and a copy sent to the hospital. These records have in a number of instances enabled us to give expert information, especially in operations upon the uterine tubes in cases of doubtful pregnancy

Table 3 is interesting as showing the difficulties encountered by embryologists in collecting material. In our own experience we found at first that, although physicians seemed to be entirely willing to send specimens, we rarely received them; or, at best, only those which had been standing upon the shelves for years. These were badly preserved and of little scientific value, not only because the tissues were unfit for microscopic examination, but because histories were entirely lacking. Nevertheless, we always thankfully receive such specimens, and in return gladly send fixing fluids, write letters, and also send reprints of embryological studies to donors. In this way we have learned that a physician who will take the trouble to send one specimen is always willing to preserve carefully the next that falls into his hands, and, in the course of time, he naturally becomes a regular contributor. A number of physicians have been contributors for 30 years, and their unselfish efforts have been a great encouragement to us.

A glance at table 3 will suffice to show that over half of the specimens came from Maryland, and most of these necessarily from Baltimore; next in order is New York, and the third, Pennsylvania. The remainder cover widely scattered points, the first century being drawn from 21 States, the second from 29 States, the sources gradually expanding to include practically every State and Territory of the Union. From the beginning, a few have come regularly from abroad, so that now we have

TABLE 3.—*Sources of embryological material by states, cities, and countries.*

	Century 1.	Century 2.	Century 3.	Century 4.	Century 5.	Century 6.	Century 7.	Century 8.	Century 9.	Century 10.	Century 11.	Century 12.	Century 13.	Century 14.	Century 15.	Century 16.	Century 17.	Century 18.	Century 19.	Century 20.	Century 21.	Century 22.	Century 23.	Century 24.	Century 25.	Total.
Baltimore	49	43	62	43	47	49	41	36	34	41	34	44	53	32	44	33	54	39	67	58	54	28	...	20	56	1061
Maryland	3	3	9	...	6	7	19	13	10	8	11	12	20	10	6	13	10	15	8	10	20	10	...	7	16	246
New York	3	16	3	15	8	10	9	5	18	5	9	2	7	25	12	27	...	7	2	9	4	1	...	9	5	211
Pennsylvania	7	2	2	1	8	2	2	2	3	1	6	1	2	3	4	5	5	5	5	5	5	9	...	...	3	88
Virginia	1	...	...	...	...	...	...	2	3	3	1	...	1	...	3	1	1	2	4	3	3	...	...	1	...	29
South Carolina	1	1	...	...	...	...	...	1	3	2	...	...	...	6	5	...	2	...	1	...	1	...	...	...	...	23
Kentucky	1	...	...	...	1	...	1	...	...	...	9	...	...	...	1	...	...	...	...	1	1	...	...	...	1	16
Tennessee	2	...	1	1	...	...	...	...	...	...	...	...	...	1	...	1	...	...	...	...	...	...	...	...	...	6
Missouri	1	...	...	...	2	...	2	...	...	...	...	...	...	...	...	1	...	...	...	...	...	1	...	1	...	8
Maine	1	...	3	1	...	3	1	2	1	2	4	1	2	1	3	...	...	...	1	...	1	1	...	1	...	29
Massachusetts	1	...	2	15	1	...	...	2	2	...	2	...	1	1	...	...	...	...	1	...	...	...	...	...	...	29
Ohio	3	3	8	6	6	1	1	1	1	...	1	...	1	...	2	...	2	...	1	1	...	...	...	...	1	39
Colorado	1	...	...	...	...	...	...	...	...	...	...	...	...	...	...	...	...	2	...	...	2	...	...	...	...	5
Iowa	3	...	...	4	2	...	...	1	...	1	1	...	...	...	...	1	1	1	...	...	...	2	...	...	1	18
New Hampshire	2	...	...	...	...	...	...	...	...	...	...	...	...	1	...	...	...	...	...	...	...	...	...	...	...	3
Wisconsin	1	2	...	...	6	3	2	...	3	2	...	...	...	1	1	...	2	1	...	...	1	...	...	...	...	25
Michigan	7	...	...	1	...	...	3	1	...	1	...	27	...	4	...	2	12	1	...	...	...	...	...	...	...	59
California	3	1	1	...	...	4	7	...	3	7	1	2	3	1	2	1	1	2	1	...	...	13	...	9	...	62
Illinois	2	3	2	...	2	1	...	21	2	1	...	1	...	1	1	1	...	1	1	...	...	...	...	...	...	40
North Carolina	...	1	...	...	...	2	...	1	...	1	...	...	...	...	...	1	...	1	...	...	...	...	...	1	...	8
Kansas	...	1	...	...	...	...	...	1	...	2	...	1	1	2	...	2	...	...	2	...	1	...	...	1	1	15
District of Col.	...	14	4	6	5	2	5	...	...	2	...	...	1	...	...	1	1	1	1	...	...	...	...	1	3	47
Alabama	...	1	...	...	...	...	...	...	1	...	...	...	...	1	...	...	...	...	...	...	...	...	...	...	...	3
New Jersey	...	2	1	1	2	2	...	1	2	3	...	...	1	...	3	4	4	...	2	...	...	...	...	...	...	28
Georgia	...	2	...	...	...	2	...	...	6	...	2	...	...	1	...	...	...	...	...	...	...	...	...	...	...	13
Connecticut	...	1	...	...	1	3	1	5	...	4	...	1	2	...	6	...	...	5	3	5	4	9	...	...	...	50
West Virginia	...	1	...	...	...	4	1	...	...	1	...	...	1	...	...	...	...	...	...	2	1	...	...	...	5	16
Rhode Island	...	1	...	...	...	...	...	...	...	...	...	...	...	2	...	...	...	...	...	...	...	...	...	...	...	3
Louisiana	...	...	1	...	...	...	...	3	...	...	1	...	...	...	...	...	...	...	...	...	...	...	...	...	...	5
Minnesota	...	...	1	3	1	2	...	...	...	...	...	...	...	...	2	1	...	...	...	...	...	...	...	...	...	10
Indiana	...	...	...	3	1	...	...	...	...	...	...	...	...	...	...	1	...	...	...	1	...	...	...	...	1	7
Montana	...	...	...	...	1	...	3	...	...	...	...	...	...	...	...	...	...	...	...	...	...	...	...	...	...	4
Nebraska	...	...	...	...	...	1	1	...	1	...	...	...	...	...	...	...	...	...	...	...	...	...	...	1	...	4
North Dakota	...	...	...	...	...	...	...	1	...	...	...	...	...	...	...	...	...	...	...	...	...	...	...	...	...	1
Texas	...	...	...	...	...	...	...	1	1	...	...	...	2	...	1	...	...	8	...	4	...	...	...	...	...	17
Florida	...	...	...	...	...	...	...	...	1	1	...	...	...	1	...	1	1	1	...	...	...	...	...	...	...	6
Idaho	...	...	...	...	...	...	...	...	1	1	...	...	...	...	...	...	...	...	...	1	...	...	...	...	...	3
Oregon	...	...	...	...	...	...	...	...	1	...	...	...	1	...	...	...	...	...	...	...	...	1	...	...	...	3
Arkansas	...	...	...	...	...	...	...	...	...	2	...	...	...	3	...	...	...	...	...	...	...	...	...	...	...	5
Utah	...	...	...	...	...	...	...	...	...	...	...	...	...	...	...	...	4	...	...	...	...	...	...	...	...	4
Arizona	...	...	...	...	...	...	...	...	...	...	...	...	...	2	...	...	1	...	...	...	...	...	...	...	2	5
Washington	...	...	...	...	...	...	...	...	...	...	...	...	...	...	...	...	...	1	...	...	...	...	...	...	...	1
Canada	1	1	...	...	...	...	...	...	1	...	...	...	...	1	...	...	3	...	...	...	1	...	...	...	5	13
Germany	2	...	...	...	...	...	...	...	...	...	...	...	...	...	...	...	...	...	...	...	...	...	...	...	...	2
Philippine Is.	...	...	...	...	...	...	...	...	...	7	13	7	...	...	...	...	...	...	...	...	...	...	...	...	...	27
China	...	...	...	...	...	...	...	...	...	2	...	...	1	...	1	...	...	1	...	...	...	...	...	...	...	5
Korea	...	...	...	...	...	...	...	...	...	...	...	...	...	...	1	...	...	1	...	...	...	...	...	...	...	2
Japan	...	...	...	...	...	...	...	...	...	...	...	...	...	...	...	3	...	...	...	...	1	...	...	...	...	4
Unknown	5	1	...	...	...	2	1	...	2	...	5	1	...	...	2	...	...	...	...	...	...	25	100	48	...	192
Total	100	100	100	100	100	100	100	100	100	100	100	100	100	100	100	100	100	100	100	100	100	100	100	100	100	2500

specimens from widely different countries. This wide distribution is due to the systematic circularization of the medical profession. We began by publishing letters of appeal in scientific journals, such as the *American Naturalist;* but as this was rarely seen by physicians it proved a waste of effort. Then, at the suggestion of Professor Minot, a number of articles were published in Wood's Reference Handbook in the belief that these would come under the eyes of physicians whom we hoped to reach; this plan likewise proved of little value. Finally, a circular was drawn up, widely distributed, and reprinted in most of the medical journals of

the country. For a number of years our esteemed colleague, Dr. Howard A. Kelly, inclosed a copy of this circular with every one of his reprints.

This circularization, we believe, accounts for the responses we first received from distant and varied points. Furthermore, if the effort is worth while, as a collection grows a literature develops from it, and papers from studies of our own collection began to appear in rapid succession. Reprints of these were sent to all our contributors. This doubtless served to stimulate their interest and encourage others to send specimens, for in numerous instances physicians have written to us, at the suggestion of one of our donors, asking for information and instructions concerning the preservation and shipment of specimens. Thus, for a number of years our efforts were directed toward stimulating an increasingly large group of contributors, and we found that a succession of specimens from a physician gradually improved in quality as his knowledge and interest increased. In the course of time certain contributors, who were especially interested in the work, developed contributing centers, so that in a few instances our collection has been augmented by a number of specimens received at one time from one or another of these centers. Aside from those in our own country, such a center was established at Manila, another at Shanghai, and quite recently one in Korea. The contributors at the last two points have carried their efforts to the extent of writing letters to the various Asiatic journals, requesting the preservation of embryos for this collection; and although unforeseen difficulties are to be overcome in Asia, we hope in the course of time to acquire at least a representative number of specimens from each of the important races.

It may prove helpful to others who are making embryological collections to state that the task will probably be simplified if they will focus most of their efforts upon the immediate territory. In this way a collector can doubtless secure all the specimens he can use and, in a way, pay his debt to the local profession by running a gratuitous pathological laboratory. The collection will thus be made a central point of interest for the physicians of the community who are scientifically inclined. Our many accessions from Maryland are due largely to personal influence through which the coöperation of the practising physicians of the Johns Hopkins Hospital was secured. We have also found that most of the physicians of Baltimore were not only willing but anxious to send specimens, especially from cases of repeated abortions. Usually a physician will bring his specimen directly to the laboratory, thus affording us an opportunity to show him what is done with it and thereby increase his interest. We do not receive all the embryological material available in the State of Maryland or in the city of Baltimore, but we do get a large amount from physicians practising among the poorer classes, as well as from gynecologists and obstetricians practising among the wealthier. Most of the specimens from the poorer people belong in the third to sixth month of pregnancy and usually appear normal; while those from the upper classes are, as a rule, younger specimens and most of them are pathological.

After our collection was well established we came somewhat in conflict with the department of health of the city of Baltimore, owing to the passage of a law

requiring physicians to register all miscarriages and still-births. For a time it seemed as though this would place a ban upon collecting material in the city, but what appeared at first to be a hindrance later proved to be of great advantage and help; for the departments of health, both in city and State, have since been doing everything in their power to facilitate our work. This is well attested by the following excerpt from the Report of the Commissioner of Health to the mayor and city council of Baltimore, published in October 1913, and sent to every practising physician:

"We have through this monthly publication called attention of physicians to the requirements of the law concerning the proper registration of all abortions or still-births. We have told you that every abortion or still-birth requires a birth certificate and a death certificate. As in the application of many new laws, we have found that the practical working out of this one has produced occasionally some hardships, particularly on the poorer people, which if they had been anticipated could have been avoided by application for instructions to this department. So I take advantage of this month's publication to inform the physicians that it is not necessary to place their patrons to the expense of having a fetus, born during the period of gestation of less than five months, buried by an undertaker. Of course the body must not be disposed of in an irregular way, such as throwing it down a privy sink or burying it in the yard or cellar, as has been more or less common in the past, but if the fetal body is properly wrapped up and placed in a small box and sent to this department, along with the birth certificate and death certificate, we will see that the body is properly disposed of. I feel quite sure that this arrangement will meet, or certainly ought to meet, all the reasonable objections that can be brought against the enforcement of the new law.

"One word concerning the specimens desired by Dr. Mall of the Johns Hopkins Medical School. We want in every way to assist Dr. Mall in obtaining the specimens that he so much desires, and this regulation of the department does not in any way interfere with it, but probably may be just as easy and certainly safer in supplying the specimen. Whenever a physician has a specimen to transmit to Dr. Mall, it will not add much to the physician's trouble to stop at the Health Department, which is open at all times, to leave a birth and death certificate and get permission to leave the specimen with Dr. Mall."

However, this note delayed unduly the sending of young specimens and doubtful ones from operations, such as uterine scrappings and tubal pregnancies, and did not, it appears, encourage the reporting of abortions. Later the Department of Health of the State of Maryland permitted the filing of birth and death certificates after the specimen had been sent to this laboratory. Many more abortions are now reported than before, but in order to make the records more complete the following letter was sent out by the Department of Health in November 1916, to all practising physicians in Maryland:

"From information this Department has received, we are convinced that we are not receiving full reports of still-births. It appears that most physicians do not comprehend what is embodied in the term 'still-birth,' as used in the Registration Law of this State. For the purpose of learning the extent to which we should expect reports of still-births under this law, I have requested from the Honorable Edgar Allan Poe, Attorney General of the State of Maryland (1912–1916), a legal definition of the term, which I am enclosing herewith. You will note that it is required of you to make a report

of all products of conception no matter how early. Every still-birth should, according to the law, be treated as a birth and a death; that is, there should be filed with the registrar of vital statistics for each still-birth, no matter how early, a certificate of birth and a certificate of death.

"The Department has learned that Dr. Franklin P. Mall has been endeavoring to collect embryological material for scientific purposes, and is particularly anxious to receive fresh specimens. This, or a similar procedure, is a permissible disposition of the materials in question, and physicians may forward that which comes into their possession to Dr. Mall, corner Monument and Wolfe Streets, Baltimore, provided that as soon as they have done so, they file a certificate of birth and death, in Baltimore City with Dr. John D. Blake, and in the rural districts with the local registrar of the district in which the birth occurred. The local registrar will issue a burial permit in receipt thereof, which permit should be forwarded to Dr. Mall immediately. When material is preserved in formalin or other hardening fluid before forwarding, or in instances when it is disposed of locally, a certificate of birth and death should be filed and a burial permit received thereon before it is disposed of. In any instance where a certificate of birth and death is not filed for a still-birth it will be treated as a violation of the Registration Act."

These instructions really make it easier for physicians to send specimens to this laboratory than to dispose of them otherwise, and we have found that the instructions of the State Board of Health have furthered our work greatly. All that is necessary is to file the birth and death certificates as usual and send in the burial permit, either with the specimen or shortly afterwards, and we file it. To make this clear, Dr. Frederic V. Beitler, chief of bureau of vital statistics, wrote us as follows:

"In answer to your communication of December 7th will say that all that is necessary for you to receive for a still-birth is a burial permit like the inclosed form, which you will endorse on the back as having received the specimen. At the end of ten days all the burial permits should be sent to this office.

"Ordinarily, when a body is disposed of it is necessary to obtain this permit before removing or disposing of it, but in order to facilitate the rapid transportation of specimens to your office, we allow physicians to register the birth and death without this permit. They should, however, register the still-birth as a birth and a death as soon as possible after forwarding the specimen and then send the permit by mail to you."

A specimen is of very little value, from a medical standpoint, unless accompanied by a comprehensive history. Hence, from the very beginning we have been making every effort to get full data regarding each specimen, with the intention of determining first its age, later the cause of the abortion. As will be noted in a subsequent chapter, the former question is approaching solution, but as to the latter we are still very much in the dark. The various histories given voluntarily by physicians have served as a basis for a history blank, copies of which have been sent out quite freely during the past five years. Since this blank has been in use our histories have improved greatly in value, and as the editions of the blank have been very small, we have been able to revise it once or twice a year. At the present writing it comprises the following data:

1. Patient's name.
2. Age.
3. Race (white or colored) {father. / mother.
4. Nationality {father. / mother.
5. Date of marriage.
6. Number of births at term.
7. Total number of abortions, including the present one.
8. Order of pregnancies, whether ending at term or in abortion.
9. Date of beginning of last menstrual period.
13. Data bearing upon the cause of the present abortion:
    No data.
    Associated with disease.
    Probably induced.
    Probably not induced.
14. Venereal disease {father. / mother.
15. In case of tubal pregnancy an account should be given of the condition of the ovaries, tubes, and uterus.
16. Has the mother, or any of the sisters of the patient, had abortions.
    Physician's name.
    Address.
    In what fluid was specimen preserved.
    How much time elapsed between abortion and preservation of specimen.

When a specimen reaches the laboratory acknowledgment is promptly made, accompanied by a history blank and return envelope. Invariably the physician will fill out and return the blank, and this also is acknowledged immediately. Any request made by the physician is noted and, in the course of time, whatever information we may be able to give is sent to him. In every case a summary of the description of the specimen is furnished him.

In tendering our thanks to the many friends who have helped in the upbuilding of the collection, we wish first to state that it owes its existence primarily to the encouragement given by the great Swiss anatomist, Wilhelm His, whose lively interest in it continued until his death in 1904. From 1889 until 1914 the late Professor Minot also aided us in every way possible, not only in studying our best specimens, but also in donating many valuable pathological embryos. His great collection of vertebrate embryos in the Harvard Medical School was likewise made at the suggestion of Professor His. It will be readily seen by the appended list of contributors that large numbers of specimens have been donated by certain individuals during the past 30 years. The names of Ballard, Boldt, Brödel, Cullen, Hammack, Hunner, Lamb, Terry, Titlow, Trout, West, and Williams appear repeatedly every year.

One specimen, a negro embryo (No. 460), 21 mm. long, is worthy of special mention at this time. It was obtained from a hysterectomy performed by Professor Thomas S. Cullen, was brought to the laboratory immediately by Dr. Elizabeth Hurdon, and received alive by Professor Sabin, who injected its blood-vessels, microscopically, with India ink and preserved it perfectly in a corrosive acetic solution. During the two years following, numerous surface drawings were made of this specimen by Professor Evans under the direction of Professor Brödel; Dr. Essick and Professor Evans cut the embryo into a perfect series; and finally

Professor Lewis made an elaborate set of models of the head to illustrate its anatomy.[1]

It is impossible to adequately express our obligations to our many contributors, most of whom are practically unknown to us; but we feel that in many cases we have made lifelong friends through an extensive correspondence. In general, the work on the part of these physicians is entirely altruistic, for they hold the firm belief that the material they gather will be of greater value to science if sent to an active laboratory than if retained as fine specimens in their own small collections. We have availed ourselves of every opportunity to accord recognition to the contributor whenever a publication, dependent upon his specimen, is made. Adequate return for the trouble he has taken can never be made, unless our work proves to be of sufficient value to make him feel that he has materially helped the progress of science.

LIST OF CONTRIBUTORS.[2]

Practically all of the following are physicians. The figures indicate number of specimens received:

Baltimore City: M. Broedel 54, T. S. Cullen 44, H. B. Titlow 40, J. L. Truax 37, G. L. Hunner 34, E. B. Fenby 21, E. C. Lenhert 19, H. M. N. Wynne 19, V. N. Leonard 17, J. W. Williams 17, H. F. Cassidy 16, F. A. Conradi 16, E. J. Cook 16, A. F. Ries 16, W. T. Watson 15, J. G. Murray 14, G. G. Rusk 13, A. H. Schultz 13, J. C. Bloodgood 12, E. K. Ballard 11, G. J. France 10, A. B. Lennan 10, A. V. Zimmerman 10, C. N. Athey 8, L. E. Beach 8, H. M. Evans 8, Johns Hopkins Hospital 8, J. W. Schlieder 8, C. Vest 8, D. B. Casler 7, J. Girdwood 7, W. R. Holmes 7, J. M. Hundley 7, H. E. Knipp 7, W. W. Russell 7, H. N. Shaw 7, W. W. White 7, G. C. Blades 6, G. W. Corner 6, C. F. Coughlin 6, G. P. Evans 6, A. B. Lyman 6, M. Ostro 6, A. C. Pole 6, J. K. Seegar 6, W. G. Sexton 6, A. Wegefarth 6, G. Wilkins 6, W. D. Booker 5, W. S. Gardner 5, E. C. Gibbs 5, J. A. Luetscher 5, W. E. McClanahan 5, B. O. McCleary 5, A. W. Meyer 5, E. L. Mortimer 5, J. C. Neel 5, E. Novak 5, C. S. Parker 5, M. Rohde 5, J. W. Sanderson 5, J. B. Schwatka 5, W. Welch 5, J. H. Branham 4, E. H. Cullen 4, I. L. Fetterhoff 4, J. H. Groshans 4, J. F. Hemple 4, H. A. Kelly 4, I. Miller 4, J. H. Rehberger 4, A. Shelly 4, D. Silberman 4, J. Sperry 4, V. Van Williams 4, T. A. Ashby 3, J. Ayd 3, N. B. Bordensky 3, H. Brülle 3, W. E. Byers 3, F. A. Carpenter 3, S. A. Dodds 3, W. A. Duvall 3, H. Forsythe 3, H. Fried 3, Gavin 3, F. A. Glantz 3, G. Goldman 3, H. G. Jones 3, W. S. Love 3, J. C. Lyman 3, J. A. Melvin 3, F. K. Nichols 3, E. H. Richardson 3, H. A. Rutledge 3, W. C. Sandrock 3, G. B. Scholl 3, G. Stickney 3, H. H. Arthur 2, R. P. Batchelor 2, C. N.

Baltimore City—Continued.

Branin 2, H. T. Collenberg 2, E. V. Coolahan 2, G. C. Dohme 2, M. Flexner 2, C. M. Gabriel 2, H. J. Giering 2, Goldman 2, N. R. Gorter 2, W. Grant 2, Health Department 2, C. W. Hoffman 2, A. Horn 2, J. L. Ingle 2, Kemp 2, G. J. Lochboehler 2, A. M. McGlannan 2, R. W. B. Mayo 2, W. Neill 2, G. C. Ney 2, E. J. Russell 2, W. S. Seymour 2, M. E. Shamer 2, T. J. Simms 2, G. W. Simpson 2, A. G. Singewald 2, W. K. Skilling 2, M. G. Smith 2, G. A. Stewart 2, W. H. Strauss 2, A. Ullman 2, A. S. Warner 2, L. H. Watkins 2, P. Wegefarth 2, L. H. Wharton 2, K. M. Wilson 2, H. B. Athey 1, A. S. Atkinson 1, C. Bagley 1, H. H. Biedler 1, Billingslea 1, C. E. Brack 1, M. L. Brady 1, W. T. Carr Jr. 1, H. Chabot 1, J. W. Chambers 1, H. Cushing 1, G. W. Dobbin 1, W. M. Dumm 1, R. J. Erickson 1, C. R. Essick 1, J. M. T. Finney 1, J. Friedenwald 1, A. J. Gillis 1, F. C. Goldsborough 1, G. Heller 1, K. L. Hichew 1, J. E. Huiskamp 1, Jose L. Hirch 1, E. Hurdon 1, S. H. Hurwitz 1, E. H. Hutchinson 1, M. L. Ingram 1, C. K. Jump 1, L. Karlinsky 1, T. W. Keown 1, E. Kloman 1, H. C. Knapp 1, H. B. Kolb 1, A. J. Laciar 1, Maurice Lazenby 1, Little 1, J. G. Long 1, J. W. Lord 1, T. B. McCormick 1, D. I. Macht 1, T. H. Magness 1, A. H. A. Mayer 1, J. A. Miles 1, J. H. Mitnick 1, W. E. Moseley 1, Moss 1, J. E. Muse 1, L. E. Neale 1, R. B. Normant 1, E. D. Pleas 1, E. Plummer 1, F. Pollack 1, M. Raskin 1, J. N. Reik 1, F. R. Sabin 1, H. Schmeisser 1, W. J. Schmitz 1, A. W. Sellards 1, M. Sherwood 1, P. G. Shipley 1, C. E. Simon 1, F. R. Smith 1, G. A. Stein 1, A. R. Stevens 1, H. A. Stephenson 1, B. H.

[1] A paper dealing with the cartilaginous skull of this embryo has since been published by Dr. Lewis, Carnegie Inst. Wash. Pub. No. 272.

[2] This list had been brought up to date by Dr. Mall when this chapter was written. It therefore includes only the donors of specimens received prior to 1918.

Baltimore City—Continued.
Swint 1, G. L. Taneyhill 1, F. N. Tanner 1, B. E. Tapman 1, G. F. Taylor 1, R. T. Taylor 1, W. S. Thayer 1, M. H. Todd 1, Eugene Van Ness 1, A. Wanstall 1, W. T. Willey 1, L. R. Wilson 1, M. C. Winternitz 1, G. H. Wolterecek 1, E. B. Wright 1.

Maryland: G. C. McCormick 81, G. H. Hocking 24, W. F. Twigg 12, F. Beitler 10, N. H. D. Cox 9, C. B. Boyle 8, C. M. Hanby 8, A. R. Mackenzie 8, W. J. Todd 7, J. W. Meade 6, W. P. Miller 6, F. W. Rich 6, C. M. Ellis 5, C. W. R. Crum 4, W. H. Houston 4, G. Steele 4, S. K. Wilson 4, J. L. Adams 3, T. H. Henderson 3, R. L. Hoyt 3, T. W. Linthicum 3, M. G. Porter 3, A. C. Swink 3, M. A. Birley 2, J. S. Bowen 2, F. C. Eldred 2, A. T. Gundry 2, W. M. Lewis 2, W. H. Morris 2, S. M. Wagaman 2, E. C. Wolff 2, J. H. Bates 1, J. C. Beck 1, C. H. Beetem 1, T. Brayshaw 1, G. L. Broadrup 1, W. D. Campbell 1, M. Colton 1, C. F. Davidson 1, H. P. Fahrney 1, F. R. Gough 1, J. O. Hendrick 1, R. C. Hume 1, T. W. Koon 1, H. W. Lankford 1, J. R. Laughlin 1, J. R. Littlefield 1, H. W. McComas 1, I. J. McCurdy 1, H. A. Mitchell 1, M. F. Morrill 1, Nihiser 1, D. N. Richards 1, J. A. Ross 1, Sampson 1, H. Schapiro 1, H. H. Simmerman 1, J. D. Skilling 1, L. G. Smart 1, Wallace 1.

New York: B. F. Terry 20, J. R. Losee 18, O. S. Lowsley 12, H. J. Boldt 9, C. R. Rynd 9, J. B. Harvie 7, W. G. McCallum 6, A. W. Elting 5, S. H. Gage 4, N. Jenison 4, H. D. Senior 4, L. J. J. Commiskey 3, F. R. Ford 3, W. B. Hetfield 3, D. Jurist 3, A. T. Kerr 3, A. H. Ritter 3, M. J. Ross 3, C. K. Winne Jr. 3, F. H. Church 2, H. I. Davenport 2, Simon Flexner 2, W. F. Jones 2, B. S. Kline 2, D. H. McGray 2, N. G. Orchard 2, R. Sanderson 2, E. Schwarz 2, E. M. Stanton 2, H. C. Taylor 2, M. Warren 2, C. A. Bentz 1, H. S. Bernstein 1, H. J. Chittenden 1, H. C. Coe 1, R. J. Cole 1, E. Comstock 1, C. W. Dodge 1, Edna D. Fiske 1, H. R. Gaylord 1, Burt D. Harrington 1, W. H. Haynes 1, H. von Hoevenburg 1, J. A. Hymans 1, Johnson 1, F. Kammerer 1, E. Kellert 1, C. Kingsley 1, W. Kirk 1, L. J. Ladinski 1, J. S. Lewis 1, W. H. Licht 1, W. C. Lusk 1, McNaughton 1, Marney 1, Moffatt 1, E. M. Moore Jr. 1, W. L. Moss 1, C. W. Ottley 1, E. L. Robbins 1, J. A. Sampson 1, H. S. Steensland 1, A. R. Stevens 1, H. F. Swift 1, H. N. Vineberg 1, M. B. Wesson 1, G. H. Whitcomb 1, S. B. Wolff 1, J. Woodman 1.

Pennsylvania: P. F. Williams 12, J. M. Jackson 9, R. M. Pearce 7, A. C. Wentz 7, H. Leaman 6, W. H. McCurdy 5, H. S. Newcomer 5, John Harvey 4, H. D. King 4, I. N. Snively 4, E. W. Stick 4, W. C. Stick 4, J. E. Miesenhelder 3, I. Davis 2, T. H. Gilland 2, G. M. Gould 2, M. J. Locke 2, D. F. Unger 2, R. B. Varden 2, D. Dale 1, J. Y. Dale 1, German Hospital 1, M. S. Hardy 1, C. C. Hartman 1, Hoge 1, E. B. McGraw 1, J. H. Sieling 1, F. F. Simpson 1, A. B. Snively 1, J. S. Swartzwelder 1, T. P. Tredway 1.

Connecticut: T. Wheeler 34, G. B. Cowell 6, E. J. O'Shaughnessy 5, W. H. Fairfield 4, E. A. Wells 4, G. W. Cox 3, T. J. Roche 3, D. M.

Connecticut—Continued.
Trecartin 3, H. M. Griffin 2, O. Ramsey 2, J. M. Slemons 2, Anderson 1, J. W. Churchman 1, F. H. Cooper 1, E. A. Deming 1, Formichello 1, C. C. Godfrey 1, R. G. Harrison 1, C. N. Haskell 1, E. B. Ives 1, H. B. Lambert 1, R. J. Lynch 1, E. F. Oliver 1, Stevens 1.

Michigan: G. L. Streeter 46, B. N. Epler 9, F. Shilleto 4, C. Brumme 3, E. H. Cullen 3, L. H. Stewart 3, L. W. Haynes 2, J. L. Robinson 2, E. J. O'Brien 1, L. S. Crotser 1, L. J. Crum 1, L. H. S. Dewitt 1, E. G. Knill 1, F. L. Pierce 1, H. N. Torry 1.

District of Columbia: D. S. Lamb 29, T. C. Smith 14, Gray 4, E. H. Egbert 3, R. Munson 3, H. L. E. Johnson 2, E. C. C. Winter 2, O. H. Coumbe 1, H. T. A. Lemon 1, G. F. Lull 1, W. A. Moncrief 1, G. B. Miller 1, M. M. Park 1, M. Parsons 1, B. F. Poole 1, M. B. Strickler 1.

California: A. Miller 30, R. W. Hammack 19, R. L. Jump 3, E. Rosenceranz 2, J. C. Spencer 2, C. M. Faris 1, W. C. McKee 1, A. W. Meyer 1, W. L. Wills 1.

Massachusetts: C. S. Minot 17, D. V. Adriance 2, J. L. Bremer 2, E. Morse 2, R. S. Perkins 2, R. F. Rand 2, E. M. Rockwood 2, A. W. Buck 1, M. S. Haynes 1, J. L. Huntington 1, M. W. Marvel 1, G. L. Richards 1, M. A. Southard 1, L. N. Wilson 1.

Philippine Islands: R. W. Hammack 25, C. Fernando 6, P. K. Gilman 3, B. C. Crowell 1, C. H. Manlove 1, D. P. Quazon 1, M. Quazon 1.

West Virginia: P. M. Barrett 21, H. G. Steele 3, F. K. Vass 3, G. Ackermann 2, D. D. Chapman 1, W. W. Golden 1, P. L. Gray 1, H. O. Henry 1, D. J. Long 1.

Virginia: J. M. Melton 8, H. B. Disbrow 4, C. O. Miller 4, E. M. Hicks 3, J. S. Speed 3, W. H. Trout 3, W. E. Nesbit 2, A. G. Hoen 2, R. L. Rhodes 2, S. S. Gale 1, M. D. Hoge Jr. 1, C. S. F. Lincoln 1, R. H. Wooling 1.

Texas: W. W. Waite 22, W. L. Hart 3, H. W. Crouse 2, W. Wilson 2, Brown 1, F. L. Paschal 1.

New Jersey: G. N. J. Sommer 23, T. W. Harvey Jr. 3, J. L. Fewsmith 3, F. E. Chidester 1, G. K. Dickinson 1, Orange Memorial Hospital 1.

Illinois: L. L. Iseman 4, J. H. Bacon 4, R. T. Edwards 2, M. K. German 2, R. E. Larsen 2, G. W. Bartelmez 1, R. Dodds 1, E. C. Dudley 1, E. Dunn 1, H. F. Dunn 1, M. A. Fitzpatrick 1, S. C. Glidden 1, L. Hektoen 1, F. Holland 1, W. S. Lemon 1, Mitchell 1, J. F. Percy 1, W. Ryan 1.

South Carolina: G. T. Tyler 15, D. K. Briggs 4, L. Peters 2, C. O. Bates 1, W. M. Burnett 1, D. Furman 1, F. Jordan 1, Powe 1, P. G. Saussure 1.

Wisconsin: A. F. Fuchs 6, C. R. Bardeen 5, W. G. Darling 3, A. Egdahl 3, C. H. Bunting 1, G. L. Kaumheimer 1, A. S. Thompson 1, J. L. Yates 1.

Maine: W. Tobie 14, G. M. Elliott 4, S. P. Warren 4, A. C. Ferguson 1, L. B. Hatch 1, B. Hunt 1, E. H. King 1, C. M. Swett 1.

Ohio: H. G. Sloan 4, W. Howard 3, C. A. Bowers 2, H. McE. Knower 2, C. A. Lamont 2, D. W. Boone 1, J. M. S. Heath 1, C. C. Jones 1, H. N. Mateer 1, R. G. Perkins 1, H. Robb 1, F. Schmitta 1, D. W. Steiner 1.

Minnesota: B. J. Merrill 7, W. S. Miller 4, C. A. Roeder 3, E. H. Loufbourrow 2, F. C. Baier 1.

Iowa: J. L. Crawford 6, G. B. Ward 5, J. McMorris 2, M. Emmert 1, J. T. Miller 1, A. P. Stoner 1.
Kansas: C. E. Caswell 11, M. Hahn 2, M. T. Sudler 1.
North Carolina: R. B. Slocum 5, J. A. Ackerman 1, A. G. Carr 1, F. W. Griffith 1, F. H. Russell 1.
Canada: J. V. Graham 2, S. H. Quance 2, F. B. Bowman 1, D. A. Campbell 1, R. W. Large 1, R. L. McCrady 1, J. J. Sheehan 1.
Tennessee: N. I. Ardan 3, W. B. Burns 2, W. T. DeSantelle 2, A. E. Douglass 2.
Colorado: C. B. Ingraham 2, H. Sewall 2, W. Boget 1, F. N. Cochems 1, W. D. Fleming 1, C. Powell 1, M. R. Stratton 1.
Florida: L. A. Peek 4, E. G. Birge 2, J. C. Dickinson 1.
Indiana: A. G. Pohlman 4, R. E. Troutman 2, N. W. Cady 1.
Kentucky: J. R. Cottell 2, J. D. Hunt 2, H. A. Cottell 1, J. F. A. Flexner 1, M. Flexner 1.
Utah: H. Jeidell 7.
Missouri: H. A. L. Rohlfing 3, A. C. Ames 2, A. C. Eycleshymer 1.
China: O.T. Logan 3, H. S. Houghton 1, C. H. McCloy 1, Li Yuin Tsao 1.
Georgia: T. E. Oertel 2, J. R. B. Branch 1, C. W. Crane 1, C. A. Rhodes 1.
Oregon: W. J. Weese 3, E. B. Hughes 1.
Idaho: C. L. Dutton 4.
Montana: A. Poska 4.
Korea: R. G. Mills 2, J. W. Hirst 1, T. H. Daniel 1.
Alabama: W. A. Burns 1, H. P. Cole 1, F. A. Lupton 1.
New Hampshire: F. E. Kittridge 3.
Rhode Island: F. A. Coughlin 2, E. A. Stone 1.
Japan: S. Kioshita 3.
Arizona: J. I. Butler 1, C. E. Palmer 1.
Arkansas: M. D. Ogden 1, H. Scott 1.
Louisiana: E. Dreyfus 1, L. J. Genella 1.
North Dakota: W. H. Moore 1.
Nebraska: J. R. Blackman 1.
Washington: H. A. Wright 1.

CHAPTER II.

CARE AND UTILIZATION OF THE COLLECTION.

When a specimen is brought to us in a fresh state, as frequently occurs, we fortunately are free to use our judgment in methods of fixation and preservation. If the embryo is perfectly fresh or possibly living, we use, of course, the most refined fixation, preferably corrosive sublimate with 5 per cent glacial acetic. When the specimen is not perfectly fresh we generally transfer it to a 10 per cent solution of formalin. In all of the circulars sent out, physicians are advised to preserve all abortion material, as soon as possible, in this solution; consequently, when delivered to us, specimens, if not crushed, are generally found to be so well preserved that any part is suitable for refined histological technique. In order to render the physician's task easier, we always send upon request a number of containers filled with a 10 per cent solution of formalin in water. Physicians in active practice frequently allow their abortion material to accumulate, preserving it in these containers, and when half a dozen or more are filled they send them to the laboratory or notify us by telephone, and a messenger is sent for them. Specimens from physicians out of town are, of course, sent by express or parcel post. Although contributors are instructed to ship by express C. O. D., they apparently often find it more convenient to send their material by parcel post, for many specimens come to us in this way.

After a specimen reaches the laboratory it is at once given a serial number. It is thus identified in our card catalogue, everything relating to it bearing the same number. The specimen is transferred to another bottle or jar containing the same kind of fluid in which it arrived—generally 10 per cent formalin. This jar is not only numbered on the outside, but the serial number of the specimen is placed within, and if the embryo is large enough, a metal tag, bearing its number, is attached to one of the extremities. This makes it possible to store several of the larger specimens in one jar. Likewise, all correspondence concerning the specimen receives this serial number and all data from the wrappers are transcribed upon our permanent records. Photographs are made of all suitable specimens and an objective description recorded on the form shown in figure 2, giving first the dimensions of the entire mass, then the measurements and a description of the villi and chorion, after which the ovum is opened and a note made of its contents. The embryo also is measured, the standard measurement for very young specimens being the greatest distance in the natural posture from crown to rump. This is known in our records as the CR measurement. Older embryos are measured straight and other measurements and weights also are taken. The age of the embryo is estimated on the basis of weight, crown-rump, and foot length, and the estimate so obtained is compared with the menstrual age. One or more photographs are then made and the whole memorandum, together with the clinical history as supplied by the physician and any other data whatsoever, is placed in

the permanent files. Special examinations which may be required or suggested are made subsequently and a summary of our records sent to the donor.

When the collection was taken over by the Carnegie Institution of Washington it was found necessary to open a book in which are recorded all data relating to specimens, a page being devoted to each. As these volumes have proved to be of great value in keeping track of the collection, we have designated them as the *Key*. A specimen page of the Key, which records embryo No. 460, is reproduced in

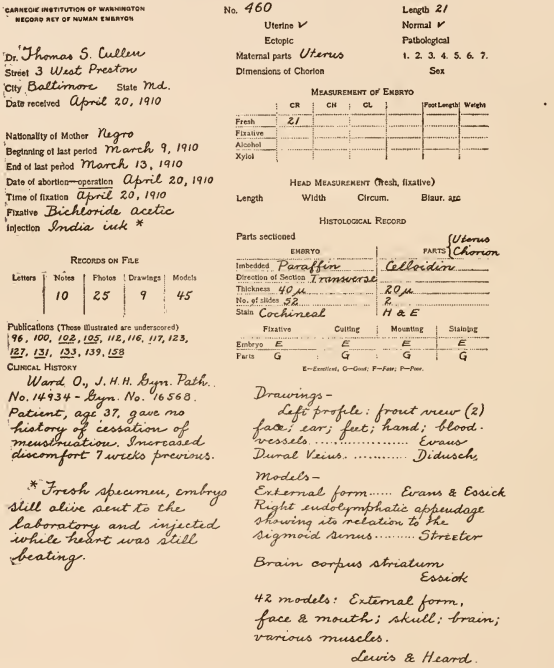

CARNEGIE INSTITUTION OF WASHINGTON
RECORD KEY OF HUMAN EMBRYOS

Dr. Thomas S. Cullen
Street 3 West Preston
City Baltimore State Md.
Date received April 20, 1910

Nationality of Mother Negro
Beginning of last period March 9, 1910
End of last period March 13, 1910
Date of abortion—operation April 20, 1910
Time of fixation April 20, 1910
Fixative Bichloride acetic
Injection India ink *

RECORDS ON FILE

Letters	Notes	Photos	Drawings	Models
	10	25	9	45

Publications (Those illustrated are underscored)
96, 100, 102, 105, 112, 116, 117, 123, 127, 131, 133, 139, 158

CLINICAL HISTORY
Ward O., J. H. H. Gyn. Path. No. 14934 - Gyn. No. 16568. Patient, age 37, gave no history of cessation of menstruation. Increased discomfort 7 weeks previous.

* Fresh specimen, embryo still alive sent to the laboratory and injected while heart was still beating.

No. 460 Length 21
Uterine ✓ Normal ✓
Ectopic Pathological
Maternal parts Uterus 1. 2. 3. 4. 5. 6. 7.
Dimensions of Chorion Sex

MEASUREMENT OF EMBRYO

	CR	CH	GL		Foot Length	Weight
Fresh	21					
Fixative						
Alcohol						
Xylol						

HEAD MEASUREMENT (fresh, fixative)
Length Width Circum. Biaur. axe

HISTOLOGICAL RECORD
Parts sectioned (Uterus / Chorion)

EMBRYO	PARTS	
Imbedded Paraffin	Celloidin	
Direction of Section Transverse		
Thickness 40 μ	20 μ	
No. of slides 52	2	
Stain Cochineal	H & E	

Fixative	Cutting	Mounting	Staining
Embryo E	E	E	E
Parts G	G	G	G

E—Excellent, G—Good, F—Fair, P—Poor.

Drawings—
Left profile: front view (2) face; ear; feet; hand; blood-vessels ..... Evans
Dural Veins. ..... Didusch.

Models—
External form ..... Evans & Essick
Right endolymphatic appendage showing its relation to the sigmoid sinus ..... Streeter

Brain corpus striatum
Essick

42 models: External form, face & mouth; skull; brain; various muscles.
Lewis & Heard.

FIG. 1.—Specimen page from "Key," showing manner in which records of embryos are entered.

figure 1. The data collected are entered in the first column. Only the number of letters received and the number of photographs made are recorded here, this being sufficient to show any interested person what may be found in the permanent file. In the latter, each note is stamped with the catalogue number of the specimen and

the date of filing, so that notes entered in successive years can easily be arranged in sequence. In the upper part of the second column of figure 1 are recorded the dimensions and general character of the specimen, which, of course, necessitates a general classification, for at this time it must be determined whether or not the embryo is normal or pathological. Since the diagnosis is made entirely upon its general appearance and form, it does not follow, when an embryo is classified as

CARNEGIE INSTITUTION OF WASHINGTON
DEPARTMENT OF EMBRYOLOGY
DESCRIPTION OF SPECIMEN

No.

Uterine | Size of Abortion Mass | Date of Accession
Ectopic | Size of Chorion | Fixation on Arrival
No Pregnancy | Size of Chorionic Cavity | Preservation

Measurement of Embryo (natural curve, straight)

CR CH GL FOOT LENGTH HEAD

FRESH | LENGTH
FIXATIVE | WIDTH
ABSOLUTE ALCOHOL | HORIZ. CIRC.
XYLOL | TRANS. CIRC.

Weight of Embryo | Weight of Placenta | Size of Placenta | Cord Length | Sex

FRESH ..... MALE
FIXATIVE ..... FEMALE
UNDETERMINED

CLASSIFICATION

NORMAL — GRADE

PATHOLOGICAL
1. VILLI
2. CHORION WITH COELOM
3. CHORION WITH AMNION
4. NODULAR
5. CYLINDRICAL
6. STUNTED
7. MACERATED, MUMMIFIED

CROSS REFERENCE
OVARY
TUBE
UTERUS
SCRAPINGS
IMPLANTATION
PLACENTA OR CHORION
DECIDUA
INJECTED
RACIAL
TWINS
LOCALIZED ANOMALY

EXAMINED BY ..... DATE .....

FIG. 2.—Blank upon which preliminary description of specimen is entered.

normal, that it necessarily is so, but only that it is normal in form. This point will be discussed later.

In order to facilitate the tabulation of the Key, we have found it necessary to make all descriptions of a specimen on another form (fig. 2), which is so constructed that any data entered are easily transferred to the Key. This information is

arranged from the card catalogue, a plan we have found essential in order that any given type of specimen may be located easily. By this time the specimen is fully recognized as normal or pathological, and it has also been determined whether new records or drawings should be made for future reference. The photographs, negatives, letters, notes, and drawings are then filed in numerical order in suitable metal cabinets in a fire-proof vault.

An effort is made to cut into serial sections, as soon as possible, all small embryos that are well preserved. Miscellaneous specimens are likewise constantly being sectioned—for instance, an ovary, villi, portions of a chorion, or parts of larger embryos. In order that this may be done without confusion to the investigator, we have found it helpful to record each block under consideration upon a form somewhat similar in character to figures 1 and 2; this we call the *histological record*, which may be compared to a bill of lading. This sheet is dated and the part of the specimen to be cut is indicated thereon, as are also the directions for embedding, cutting, staining, etc. After the work has been done, the technician returns the slides, with the histological record, to the investigator interested in this particular specimen, who checks up the sections and enters the grade upon the histological record, which is then placed in the permanent file.

Preparations of many specimens for the microtome are constantly under way. Since most of the specimens are delicate and can not be touched, we have had very satisfactory results from passing them through the graded alcohols in shell vials, closely stoppered with absorbent cotton. Within each vial is a loose tag bearing the number of the specimen. Experience has taught us that if there is very careful gradation only five grades of alcohol are necessary, beginning with 60 per cent, then 70 per cent, and so on. With the firm cotton stopper the entrance of the alcohol is so gradual as to equal an infinite number of gradations. For instance, if the specimen is changed from a 60 per cent to a 70 per cent solution, the stopper should be so tight that the diffusion can not become complete for several hours. When passing from lower to higher grades it is preferable to invert the vial. If this were not done, the stronger solution would not enter so quickly, as a 60 per cent fluid has a higher specific gravity than a 70 per cent, and hence there would be a slower mixture. In passing from stronger alcohol to water, on the other hand, the vial should be right end up. The underlying idea of this procedure is based upon the fact that if the ovum is thrown into strong alcohol, the chorion and outer layers of the embryo become greatly shrunken, while the deeper tissues are well preserved, as the alcohol diffuses slowly towards the center of the embryo. After dehydration the specimen is embedded in either celloidin or paraffin, stained, and cut according to the directions given on the histological record, and is then ready for permanent filing.

We have found it convenient to segregate the specimens into two groups. The first includes all embryos which have been cut into serial sections. These are filed according to length, so that any one wishing to study structures in the 4-mm. stage, for instance, will find all such embryos together in the cabinet. There is, however, a very large amount of miscellaneous material which we have been compelled to file merely in numerical sequence, and this constitutes the

second group. In order to expedite the work of locating a specimen, each is entered upon the card catalogue according to its length in millimeters, the groupings being a millimeter apart. All normal embryos of the same length are entered upon the same card, with notations as to whether or not they have been cut into serial sections. The pathological specimens are arranged upon cards according to type, but the specimens of a given type or group are also arranged in order of size. In this way it is quite easy to locate a specimen of a given size in any group after it has been sectioned. It can be seen at a glance, therefore, that we have here a list corresponding to all the embryos in the collection, both those which have been cut and those which have not. There are similar cards of all drawings, models, and photographs, and these, in a general way, are arranged according to their anatomical topography. For instance, on one card will be found left profiles, on another right profiles, on another hands, etc.

It is by no means a simple matter to catalogue the miscellaneous material. We have found it necessary to carry a card for ovaries, another for tubes, and so forth, as shown in the second column of figure 2. In the course of time we shall add cards for partial series and for the different tissues and organs of the larger fetuses.

As will be seen from the appended bibliography, our earliest studies in embryology were made from the viewpoint of gross anatomy. The first paper deals with the entire anatomy of an embryo 7 mm. long, and therein are recorded several important discoveries. (As stated before, the model made for this study was by far the most elaborate piece of modeling that had as yet been undertaken.) Following this were papers written for the Reference Handbook, which are more general in character. Finally, the names of collaborators began to appear in the list, the first paper being by J. B. McCallum, on the histogenesis of striated muscle. As the interest of new investigators was enlisted, the scope of the work gradually broadened to include almost the entire field of anatomy, and the 159 papers[1], which are dependent largely upon our collection, may be classified as follows: 18 were written for the purpose of propaganda, as efforts have been made from time to time to gain the interest of physicians who might be in a position to send specimens. It must be admitted, however, that these individual appeals brought few results. After such an appeal we would, perhaps, receive two or three specimens. Then there would be a period of quiescence, and we would have to content ourselves with studying again with greater care the detailed anatomy of small portions of an embryo, since material for more extensive surveys was lacking. But as the collection gradually enlarged, papers on embryometrics were published. These number 14 in all, and include such questions as the age of embryos and curve of growth. As might be expected, most of the studies have been on anatomy, although a single specimen calls for a great deal of time in order to work out the form and relation of the organs. The papers on embryo-anatomy fall naturally into subdivisions which have been recognized by anatomists for centuries. There are 9 papers on topographical embryology, 10 on osteology, 9 on myology, 25 on

[1] These 159 papers include only such as appeared before 1918. A considerable number have been published since then.

angiology, 16 on splanchnology, 15 on the genito-urinary system, and 7 on the cœlom. The study of brain morphology is, to a certain extent, a science in itself, and there are 24 papers on neurology. Only 9 publications on histogenesis have appeared, but the histogenetic standpoint is considered in many of the other papers enumerated above.

As the collection grew we found an increasing number of specimens which, though peculiar in form, were at first believed to be normal, but which upon closer study proved to be pathological. Thus we were unwittingly carried into the field of abnormal development. In fact, the great problem which confronts us always, in the study of a new specimen, is to determine whether or not it is normal. The experience of embryologists elsewhere has apparently been identical with our own, for frequently one observes in the literature an account of a human embryo, believed at first to be normal, which, upon further consideration, proved to be pathological. Hochstetter has stated that we have no right to consider an embryo normal unless it has been removed by a surgeon at hysterectomy, but our studies along this line have shown that a quite appreciable number of hysterectomies disclose pathological embryos. The criterion of His, who used the comparative method of von Baer in determining the normality of human embryos, is probably more reliable than that of Hochstetter. I believe, therefore, that the best check in the study of the human is a knowledge of comparative embryology.

There are 14 papers in the list that deal with pathological embryology. The first (No. 21) included all specimens up to No. 162, which were believed to be pathological. As we have found the two fields closely related, in these studies we have naturally drifted from pathology into teratology, there being 10 papers on this subject.

Of the 500 papers emanating from the Department of Anatomy of the Johns Hopkins Medical School, there are (in addition to the above-mentioned 159 dealing with human embryology) 115 on experimental embryology. A study of human embryology can not be of great scientific significance unless it be extended through comparative studies and an effort be made to determine, if possible, the causal relations between the developing parts. From the beginning, therefore, experimental studies have been made upon a great variety of subjects, the most important being on organ-forming substances and the influence of the eye-vesicle upon the development of the lens from the ectoderm. We may also at this point call attention to the brilliant studies of Harrison upon the development of the nerves, which demonstrate conclusively the validity of the neuron doctrine. In making these experiments he developed an ingenious method by which the living isolated cells could be seen under the microscope and their growth followed during a number of days. Later, this work was extended to the study of growth of all kinds of isolated tissues in the warm chamber, now well known as tissue culture.

In nearly all studies on embryo-anatomy it is necessary to resort to methods which will enable one to see the structure and form of organs in their serial sections. As far as possible this is always done by observing the whole embryo or parts of one dissected under the dissecting microscope. A valuable specimen, however,

can not be treated in this way. Such a specimen is cut into sections and from the sections an effort is made to reconstruct the anatomy. In the first publication the anatomy of the embryo was worked out by Born's (1883) method of reconstruction, but unfortunately at that time this method gave little more than the external form, the finer structures being lost in the model. The plan of dissecting the model was then tried, and it soon became clear that success in reconstruction depended very largely upon one's power to visualize the structures from the serial sections, and to some extent upon inventive ability in eliminating a part of the model, as deeper structures can not be shown without removing the superficial ones. Gradually we evolved what we term *dissectible wax models*, which, however, are somewhat clumsy and usually warp in warm water. Finally, Dr. Bardeen (1901), who is skilled in work of this kind, discovered that excellent results could be obtained by making a foundation model in wax and then projecting and elaborating it as a drawing by the graphic method of His (1892), thus combining the good features of two very valuable methods.

At first our record of sections was made by drawing them with the camera lucida or, better still, in a dark room by the aid of a magic lantern. This, however, is a very laborious and time-consuming task, and has a tendency to check the mental activity of the investigator, for unfortunately the work can not be done successfully by a technical assistant. When the collection was transferred to the Carnegie Institution we availed ourselves of the opportunity to install an accurate projection apparatus patterned somewhat after the one used by His (1892). With this apparatus sections of embryo No. 460, previously referred to, were photographed on glass negatives with an enlargement of 50 diameters. Thus it was possible to make several prints. As the photographs were taken with a 50-mm. planar lens, they show all the details wonderfully well.

As everything which we wished to reconstruct had to be transferred to wax, it was highly desirable that the final model should be composed of some temperature-resisting substance. A method has therefore been devised whereby all the structures desired are eliminated from the wax. Thus, in a block of wax the model is represented in outline by a hole or a series of holes, according to the number of structures to be reproduced, and these holes are subsequently filled with plaster of paris. When this hardens and the wax is removed, the finished plaster model is liberated.

This process of modeling depends solely upon absolute accuracy in superposing the wax plates to correspond to the original sections of the embryo. Hence a perpendicular line must be established, and this is done as follows: The wax plates of the sections are placed one upon another until a complete model of the embryo is built up (fig. 3), the construction being guided by photographs of the embryo made before it was cut. Thus it is possible to duplicate accurately the external form of an embryo on an enlarged scale. After this is done it is a simple matter to mark the wax plates in a perpendicular direction—that is, by right-angle lines drawn upon every plate through its axis. These constitute what we call *guide-lines*, the instrument for marking which was invented by Dr. W. H.

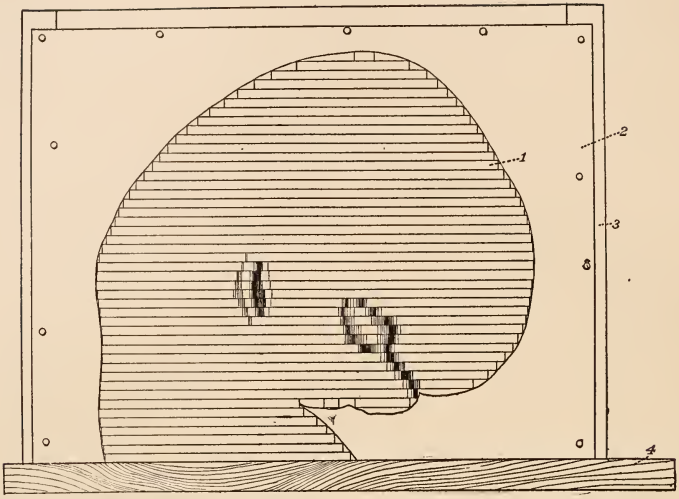

FIG. 3.—Method of piling with cardboard outline as guide: *1*, external form piled in wax plates; *2*, cardboard outline guide; *3*, posts for attaching same; *4*, baseboard.

Lewis (1915) and is known as the *Lewis guide liner* (fig. 4). After the guide-lines have been drawn on each wax plate they are transferred to the photographs or drawings. This is done by superposing each wax plate upon its photograph or drawing and marking the end of the guide-lines. When the wax plate is removed, these points are connected by lines similar to those on the plates. After the two principal guide-lines have been established, it has been found convenient to use secondary guide-lines, 5 cm. apart, which run parallel to the primary ones over the entire surface of the photograph.

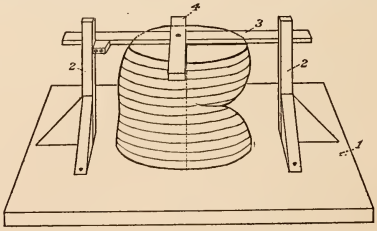

FIG. 4.—Method of making guide lines: *1*, baseboard; *2*, perpendicular posts; *3*, straight edge; *4*, piece at right angles to it.

In order to make a reconstruction of any portion of an embryo it is necessary first to transfer the outlines of that structure from the photograph to the wax plates by means of carbon paper and a glass point used as a pencil. These outlines are then cut and removed from the wax and the plates squared off along the

secondary guide-lines sufficiently far outside of the proposed model not to conflict with its casting.

In order that these finished plates, which we call *mold plates*, may be kept in exact apposition, they are piled in a rectangular corner made of plate glass (fig. 5). While this is being done it is necessary to cut certain artificial channels as vents, so that the air will escape from the openings when the plaster is poured in.

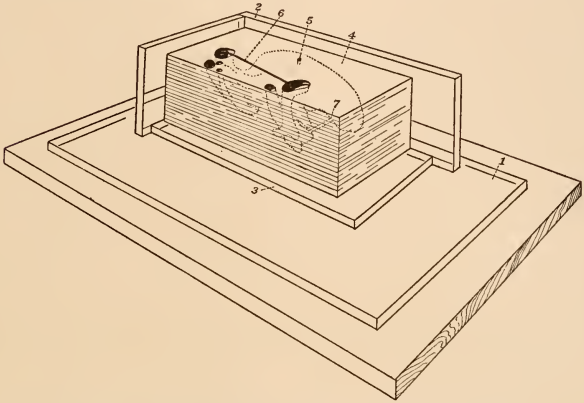

FIG. 5.—Method of piling wax mold: *1*, baseboard; *2*, perpendicular right angle corner; *3*, glass plate; *4*, wax mold; *5*, vent; *6*, galvanized iron wire bridge; *7*, gate for plaster between parts of mold.

It is also well to bridge loosely attached parts with copper wire, which is done by heating the wire and laying upon the wax plates as they are being piled up. The entire mass forms a mold which, to distinguish it from the others, is called a *plate mold*. This is cast with plaster of paris, and after the plaster has set the wax is removed by heating. Sometimes it is necessary to proceed farther and make a *break mold* over the first cast, after which it is possible to make as many duplicate casts as desired. In the above description the main outlines of this valuable method of reconstruction, as now practised in this laboratory, have been given.

Numerous general studies have also been made in embryometrics, in which linear, gravity, and time values are considered. Furthermore, the technique of gross anatomy has been applied to differentiate, by means of injection, the arteries, veins, and lymphatics of the whole clarified embryo. Similar specimens can be prepared to show the entire cartilaginous and bony systems. Thus many embryos frequently are considered in a single publication, especially those illustrating causes of abortion and the production of moles and monsters. Attention is therefore called to the numbers following the references in the appended list of publications. These represent the catalogue numbers of the specimens studied.

It will be noted that certain specimens are referred to frequently, showing that these have been of more general use than others. While these numbers may seem somewhat confusing as they here appear, references to a given embryo are found together in the Key, and this makes it quite easy to find the published description of that embryo. Where the description is accompanied by illustrations, the specimen number is printed in bold type. A comprehensive view of the entire bibliography shows that the papers are sometimes general but often special in character. Whenever the line of thought is general, it is necessary to consider the topic in many different embryos, and one topic is frequently represented by several collaborators. In other words, our department is a large coöperative effort on the part of many contributors and collaborators.

Our first papers were published in the Journal of Morphology and the Johns Hopkins Hospital Bulletin and Reports, as well as in the foreign journals. We had hoped at that time that the excellent Journal of Morphology would continue, and that it would publish all of our best papers; but unfortunately it could not be financed, and thus for a time we had no adequate outlet for our work. At the Christmas (1900) meeting of the American Association of Anatomists, held in Baltimore, a committee was named to consider the advisability of founding a new journal for the publication of serious anatomical studies. In May following, three trustees (Huntington, Mall, and Minot) were appointed to launch this enterprise. In November of that year the first number of the American Journal of Anatomy appeared, and at the next meeting of the Anatomists, held in Chicago, it was voted to substitute the new journal for the Proceedings of the Association, without additional expense to the members. In this way national support was at once assured. A glance over the first ten volumes of the Journal discloses the fact that about 30 per cent of the papers emanated from the Anatomical Laboratory of the Johns Hopkins Medical School. In other words, our collection was one of the chief incentives for its publication. In rapid succession other journals were established and published in Baltimore; first, the Journal of Experimental Zoölogy in 1904, then the Anatomical Record in 1906. The stimulus given by these national efforts brought about the revival of the Journal of Morphology by the Wistar Institute in 1908, the opening volume consisting of a monograph entitled "A study of the causes underlying the origin of human monsters" (Mall). These serial publications mark the conversion of our studies of embryology from a local to a national enterprise.

About this time coöperative effort was regenerated by Professor Keibel of Freiburg, and during one of his visits to Baltimore it was agreed that the leading embryologists compile all known facts regarding human development. This compilation was undertaken by 15 embryologists (1 Canadian, 1 Swiss, 2 German, 3 Austrian, and 8 American) and resulted in the production of a two-volume work published in both German and English. One-half of this was produced by the American contributors, and 6 of these 8 used our collection of embryos almost exclusively. The work as a whole certainly does represent progress, and it has also brought our collection into scientific position; but the editors were not satisfied

with their effort, believing it was possible to produce a better work. Before this could be done, however, it was deemed necessary to organize our forces more thoroughly, and to bring this about a plan for the study of human embryology was drawn up by one of the editors[1], which embraced the following features: (1) Much larger collections must be made; (2) much better histories of the various specimens must be obtained; (3) the necessary material must be placed at the disposal of the most competent investigators.

This plan received the full indorsement of leading embryologists, including Keibel and Waldeyer, and was presented to the officers of the Carnegie Institution of Washington, who responded generously with an initial grant of $20,000 to carry on the work for one year as an experiment. At the end of that time a department of embryology of that Institution was established. The Department of Publications of the Carnegie Institution has been of the greatest value to us in our work, for it publishes adequately certain studies which, on account of their expense, could not appear in the journals. These publications, known as the "Contributions to Embryology," are brought out in series at irregular intervals. The first, "On the fate of the human embryo in tubal pregnancy," fills an entire volume. The individual papers appearing therein since then will be found in the appended bibliography.

[1] Mall.

PUBLICATIONS BASED ON STUDIES OF THE CARNEGIE COLLECTION.

(The numbers following each publication represent the catalogue numbers of the specimens described therein. Where the description is accompanied by illustrations the catalogue number is indicated in bold type.)

1. Mall, F. P., 1891. A human embryo twenty-six days old. Jour. Morph., vol. 5, p. 459–480.
   2
2. ———, 1891. Development of the lesser peritoneal cavity in birds and mammals. Ibid., p. 165–179.
   2
3. ———, 1893. A human embryo of the second week. Anat. Anz., vol. 8, p. 630–633.
   11
4. ———, 1893. Early human embryos and the mode of their preservation. Johns Hopkins Hospital Bulletin, vol. 4, p. 115–121.
   2, 6, 11, 12
5. ———, 1893. Cœlom. Ref. Handb. Med. Sci. Supplement, vol. 9, p. 184–189.
   2
6. ———, 1893. The heart. Ibid., p. 391–395.
   2
7. ———, 1893. Development of the thymus. Ibid., p. 875–877.
   2
8. ———, 1893. Development of the thyroid. Ibid., p. 879–881.
   2
9. ———, 1893. Human embryos. Ibid., p. 268–269.
   2
10. ———, 1893. Development of the human cœlom. Jour. Morph., vol. 12, p. 395–453.
    2, 3, 4, 5, 6, 8, 9, 10, 11, 12, 13, 14, 16, 17, 18, **19**, 20, 21, 22, 24, 28, 29, 32, **34**, 37, 42, **43**, **45**, 48, 53, 55, 57
11. ———, 1897. Ueber die Entwickelung des menschlichen Darmes und seiner Lage beim Erwachsenen. Arch. f. Anat. u. Physiol., Anat. Abth., Supplementband, p. 403–432.
    2, **6**, **9**, **10**, **12**, **34**, **45**, **48**
12. Mall, F. P., 1898. Development of the ventral abdominal walls in man. Jour. Morph., vol. 14, p. 347–366.
    2, **12**, **22**, **43**, **74**, **76**
13. ———, 1898. The value of embryological specimens. Maryland Med. Jour.
    1, 2, 5, 6, 11, 12, 16, 17, 18, 19, 22, 23, 26, 27, 28, 30, 31, 34, 35, 42, 45, 46, 49, 52, 57, 72, 76, 79, 80, 81, 87, 88, 92, 94, 95, 96, 98, 99, 105, 106, 109, 116, 117, 118, 121
14. ———, 1898. Development of the internal mammary and deep epigastric arteries in man. Johns Hopkins Hospital Bulletin, p. 232–235.
    2, **43**, **76**
15. ———, 1898. Development of the human intestine and its position in the adult. Ibid., p. 197–208.
    2, **6**, **9**, **10**, **11**, **12**, **34**, **45**, **48**
16. MacCallum, J. B., 1898. On the histogenesis of the striated muscle fiber, and the growth of the sartorius muscle. Ibid., p. 205–215.
    64, 65, 98
17. Hendrickson, W. F., 1898. The development of the bile capillaries as revealed by Golgi's method. Ibid., p. 220–221.
18. Mall, F. P., 1899. Supplementary note on the development of the human intestine. Anat. Anz., vol. 16, p. 492–495.
    34, 45, **79**
19. Barker, L. F., 1899. The nervous system. D. Appleton & Co., New York.
    2, **6**, **9**, **12**, **18**, **19**, **43**
20. Clark, J. G., 1900. The origin, development and degeneration of the blood vessels of the human ovary. Johns Hopkins Hospital Reports, vol. 9, p. 593–676.

21. Mall, F. P., 1900. A contribution to the study of the pathology of early human embryos. Ibid., p. 1–68.
1, 2, 5, 6, 10, **11**, **12**, **13**, **14**, 16, **17**, 18, **19**, **20**, **21**, **22**, 23, **24**, **25**, 26, 27, 28, 29, 30, 31, **32**, 33, 34, 35, **37**, 42, 45, 46, 49, 52, 54, 55, 57, **58**, 60, **69**, **70**, 71, 72, 76, **77**, 78, **79**, **80**, **81**, **82**, **87**, **88**, 93, **94**, 95, 96, 97, 98, 99, **104**, 105, **106**, 109, **110**, **115**, 116, 117, 118, 121, **122**, **123**, **124**, **127**, **128**, 129, **130**, **132**, **133**, **134**, **135**, **136**, **137**, 138, **141**, **142**, **143**, 144, 145, 146, **147**, **148**, 150, 152, 153, 159, 161

22. Berry, J. M., 1900. On the development of the villi of the human intestine. Anat. Anz., vol. 17, p. 242–249.
6, **9**, **34**, **45**, **48**

23. MacCallum, J. B., 1900. On the muscular architecture and growth of the ventricles of the heart. Johns Hopkins Hospital Reports, vol. 9, p. 307–335.

24. Mall, F. P., 1901. On the development of the human diaphragm. Johns Hopkins Hospital Bulletin, p. 158–171.
2, **12**, **43**, **74**, **76**, **80**, **109**, **113**, **114**, **116**, **136**, **144**, **148**, **163**, **164**

25. Lewis, W. H., 1901. Observations on the pectoralis major muscle in man. Ibid., p. 172–177.
22, **43**, 90a, **109**, **129**, **163**

26. Harrison, Ross G., 1901. On the occurrence of tails in man with a description of the case reported by Dr. Watson. Ibid., p. 96–101.
43, 144, **370**

27. Mall, F. P., 1901. Age of human embryos. Ref. Handb. Med. Sci., 2d ed., vol. 3, p. 794–797.
1, 2, 5, 6, 11, 12, 16, 17, 18, 19, 22, 23, 26, 27, 28, 30, 31, 34, 42, 45, 46, 49, 52, 57, 72, 76, 79, 80, 81, 87, 88, 92, 94, 96, 99, 105, 106, 109, 116, 117, 118, 121, 138, 144, 145, 146, 148, 149

28. Bardeen, C. R., and W. H. Lewis, 1901. Development of the limbs, body-wall, and back in man. Amer. Jour. Anat., vol. 1, p. 1–35.
2, **12**, **22**, **43**, **76**, **106**, **109**, 144, **148**, **163**, **167**, **175**

29. Mall, F. P., 1901. Comparative development of the cœlom. Ref. Handb. Med. Sci., 2d ed., vol. 3, p. 166–171.
2

30. ———, 1901. Development of the human cœlom. Ibid., p. 171–189.
2, 3, 4, 5, **6**, 7, 8, **9**, **10**, **11**, **12**, 13, 14, 17, 18, **19**, **21**, **22**, 23, 24, 28, **34**, **42**, **43**, **45**, 48, 57, 58, 123, 130, 134, **137**, 143, 147

31. Long, Margaret, 1901. On the development of the nuclei pontis during the second and third months of embryonic life. Johns Hopkins Hosp. Bull., p. 123–126.
45, **75**, **86**, **95**

32. Lewis, W. H., 1902. The development of the arm in man. Amer. Jour. Anat., vol. 1, p. 145–183.
2, **12**, **22**, **43**, **76**, **80**, **109**, **163**, **164**

33. Mall, F. P., 1901. Pathological human embryos. Ref. Handb. Med. Sci., 2d ed., vol. 3, p. 797–809.
11, **13**, **14**, **21**, **24**, **25**, 29, **32**, **37**, 54, 55, 58, 60, 69, 70, 72, **77**, **78**, **79**, 81, 82, **87**, 93, 94, 97, 104, 110, 115, 122, 123, **124**, 128, 130, 132, 133, **134**, 135, 136, 137, 141, 142, 143, 147, 149, 150, 152, 153, 161

34. MacCallum, J. B., 1902. Notes on the Wolffian body of higher mammals. Amer. Jour. Anat., vol. 1, p. 245–259.
2, 75, **76**, 109, 128, 144, 163, **164**

35. Mall, F. P., 1902. Development of the heart. Ref. Handb. Med. Sci., 2d. ed., vol. 4, p. 573–579.
2

36. Sudler, M. T., 1902. The development of the nose and of the pharynx and its derivatives in man. Amer. Jour. Anat., vol. 1, p. 391–416.
2, **12**, **22**, **43**, 106, **109**, **144**, **163**, **175**

37. Mall, F. P., 1903. Second contribution to the study of the pathology of early human embryos. Contr. to Med. Research. Dedicated to Victor C. Vaughan, Ann Arbor, Mich., p. 12–28.
13, 20, 25, 29, 32, 54, 55, 69, **70**, **71**, **77**, 82, 93, 110, 115, 123, 124, 130, 132, 134, 135, 136, 141, 142, 143, 147, 153, 158, 159, **162**, **166**, 174, 177, 180, 181, 182, 185, 188, 189, 190, 191, 195, 196, 198, 200, 201, 204, 205, 207

38. Williams, J. W., 1903. Obstetrics.
19, **82**

39. Lewis, W. H., 1903. Human embryology. New Internat. Encycl. New York.
2, **12**, **22**, **109**, **163**

40. Mall, F. P., 1903. Notes on the collection of human embryos in the Anatomical Laboratory of the Johns Hopkins University. Johns Hopkins Hosp. Bull.
1 to 35 inc., 37, 42, 43, 45, 46, 48, 49, 52 to 55 inc., 57, 58, 60, 64, 65, 69 to 72 inc., 74 to 82 inc., 86, 87, 88, 90a, 92 to 99 inc., 104, 105, 106, 109, 110, 113 to 118 inc., 121 to 124 inc., 127-130 inc., 132 to 138 inc., 141 to 150 inc., 152, 153, 158, 159, 161 to 164 inc., 166, 167, 174, 175, 177, 180, 181, 182, 185, 188, 189, 190, 191, 195, 198, 200, 201, 204, 205, 207

41. ———, 1903. On the transitory or artificial fissures of the human cerebrum. Amer. Jour. Anat., vol. 2, p. 333–339.
1, 2, 4, 5, 9, 12, 18, 19, 22, 43, 45, 48, 57, 74, 76, 80, 86, 88, 95, 96, 100, 105, 106, 109, 113, 114, 116, 118, 138, 139, 144, 146, 148, 149, 151, 163, 164, 169, 170, 175, 179, 196, 206, 218

42. Pearce, R. M., 1903. The development of the islands of Langerhans in the human embryo. Amer. Jour. Anat., vol. 2., p. 445–455.
22, 23, 34, 42, 45, 48

43. Gage, S. P., 1903. Serial order of segments in the fore-brain of three and four weeks human embryos. Science, n. s., vol. 17, p. 486.
148

44. ———, 1904. The mesonephros of a three weeks human embryo. Amer. Jour. Anat., vol. 3, p. VI.
148

45. Mall, F. P., 1904. Development of the thymus gland. Ref. Handb. Med. Sci., 2d ed., vol. 6, p. 568–570.
2, **12**, **109**, **163**

46. ———, 1904. Development of the thyroid. Ibid., p. 570–574.
2, **109**, **163**, **175**

47. Lewis, W. H., 1904. Development of the fœtus. Ibid., p. 450–457.
2, **12**, **22**, **109**, **163**

48. Meyer, A. W., 1904. On the structure of the human umbilical vesicle. Amer. Jour. Anat., vol. 3, p. 155–156.
2, 11, **12**, 18, 22, 76, 80, 113, 145, 163, 167, **175**, 176, 184, 187

49. Streeter, G. L., 1904. Peripheral development of the cranial and spinal nerves in the occipital region of the human embryo. Amer. Jour. Anat., vol. 4, p. 84–116.
2, **144**, **148**

50. Mall, F. P., 1904. On the development of the blood-vessels of the brain in the human embryo. Ibid., p. 1–18.
2, 74, 109, 144, 145, 163, 225, 234, 234b, 235, 237, 238

51. Pohlman, A. G., 1904. Concerning the embryology of kidney anomalies. Amer. Med., vol. 7, p. 987–990.
175

52. ———, 1905. Abnormalities in the form of the kidney and ureter dependent on the development of the renal bud. Johns Hopkins Hosp. Bull., p. 51–60.
2, 22, 43, 76, 114, 144, 163, 164, 175, 221

53. ———, 1904. Has a persistence of the Mullerian duct any relation to the condition of the cryptorchidism? Amer. Med., vol. 8, p. 1003–1006.
22, 88

54. ———, 1905. A note on the developmental relations of the kidney and ureter in human embryos. Johns Hopkins Hosp. Bull., p. 49–51.
2, 22, 43, 45, 48, 74, 75, 80, 84, 88, 113, 114, 144, 163, 172, 211, 224

55. Gage, S. P., 1905. The total folds of the fore-brain, their origin and development to the third week in the human embryo. Amer. Jour. Anat., vol. 4, p. IX.
12, 148, 209

56. Bardeen, C. R., 1905. Studies of the development of the human skeleton. Ibid., p. 265–302.
2, 10, 17, 22, 45, 57, 74, 75, 76, 79, 84, 85, 86, 97, 109, 144, 145, 163, 175, 188, 216, 226, 229

57. ———, 1904. Numerical vertebral variation in the human adult and embryo. Anat. Anz., vol. 25, p. 497–519.
6, 7, 9, 10, 17, 22, 43, 45, 57, 74, 75, 79, 80, 86, 94, 96, 100, 106, 108, 144, 145, 175, 178, 184, 188, 207, 211, 216, 224, 226, 229

58. ———, 1905. Development of the thoracic vertebræ in man. Amer. Jour. Anat., vol. 4, p. 163–174.
2, 17, 22, 23, 44, 45, 76, 79, 80, 84, 96, 106, 108, 109, 144, 145, 163, 175, 184, 186, 216, 221, 241

59. Gage, S. P., 1905. A three weeks human embryo with especial reference to the brain and the nephric system. Ibid., p. 409–443.
12, 80, 148, 164, 209

60. Brödel, Max, 1905. The embryology of the vermiform appendix. In Kelly and Hurdon: Vermiform Appendix and its Diseases. Saunders, Philadelphia, p. 55–58.
9, 10, 28, 52, 89, 202

61. Jackson, C. M., 1905. On the topography of the pancreas in the human fœtus. Anat. Anz., vol. 27, p. 488–510.
43, 114

62. Streeter, G. L., 1905–06. Concerning the development of the acoustic ganglion in the human embryo. Verhandl. d. Anatom. Gesell. Anat. Anz., vol. 4, and Amer. Jour. Anat., vol. 5, p. I.
2, 22, 86, 109, 144, 148, 163

63. Mall, F. P., 1904. Catalogue of the collection of human embryos in the Anatomical Laboratory of the Johns Hopkins University, Baltimore. (Printed privately.)
1 to 253 inc.

64. Hill, Eben C., 1906. On the Schultze clearing method as used in the Anatomical Laboratory of the Johns Hopkins University. Johns Hopkins Hosp. Bull., p. 111–115.

65. ———, 1906. On the embryonic development of a case of fused kidneys. Ibid., p. 115–117.
43, 144

66. Streeter, G. L., 1906. Development of membraneous labyrinth and acoustic ganglion in the human embryo. Amer. Jour. Anat., vol. 5, p. VII.

67. Gage, S. P., 1906. Total folds of the brain tube in the embryo and their relation to definite structures. Ibid., p. IX.

68. Mall, F. P., 1906. A study of the structural unit of the liver. Ibid., p. 227–308.
2, 6, 9, 10, 12, 22, 76, 80, 109, 117, 148, 163, 186

69. ———, 1906. On ossification centers in human embryos less than one hundred days old. Ibid., p. 433–458.
22, 42, 53, 59, 156, 167, 168, 202, 214, 240, 263*b*, 263*b*[1], 263*b*[2], 263*c*, 266, 271, 272, 274, 282, 284, 288*b*, 300, 306*a*, 306*b*, 306*c*, 326, 329, 333

70. Gage, S. P., 1906. The notochord of the head in human embryos of the third to the twelfth week, and comparisons with other vertebrates. Science, vol. 24, p. 295.

71. Streeter, G. L., 1907. On the development of the membraneous labyrinth and the acoustic and facial nerves in the human embryo. Amer. Jour. Anat., vol. 6, p. 139–165.
2, 22, 75, 86, 109, 144, 148, 163, 175, 229, 371

72. Mall, F. P., 1907. The collection of human embryos at the Johns Hopkins University. Anat. Rec., vol. 1, p. 14–15.

73. Bardeen, C. R., 1907. Development and variation of the nerves and the musculature of the inferior extremity and of the neighboring regions of the trunk in man. Amer. Jour. Anat., vol. 6, p. 259–386.
2, 22, 109, 144, 145, 163

74. Streeter, G. L., 1907. Development of the interforebrain commissures in the human embryo. Anat. Rec., vol. 1, p. 55
3

75. Mall, F. P., 1907. A study of the causes underlying the origin of human monsters. (Third contribution to the study of the pathology of human embryos.) Jour. Morph., vol. 19, p. 3–368. Also monograph published by the Wistar Institute of Anatomy, Philadelphia, 1908.
1, 2, 5, 6, 10, 11, 12, 13, 14, 16, 17, 18, 19, 20, 21, 22, 24, 25, 26, 27, 28, 29, 30, 31, 32, 35, 37, 42, 45, 53, 54, 55, 57, 58, 60, 69, 70, 71, 72, 76, 77, 78, 79, 80, 81, 82, 87, 88, 93, 94, 95, 96, 97, 99, 104, 106, 109, 110, 115, 116, 118, 122, 123, 124, 127, 128, 129, 130, 132, 133, 134, 135, 136, 137, 140, 141, 142, 143, 144, 145, 147, 148, 150, 152, 153, 154, 155, 156, 158, 159, 160, 161, 163, 164, 166, 168, 169, 173, 174, 175, 176, 177, 178, 180, 181, 182, 185, 186, 187, 188, 189, 190, 192, 194, 195, 196, 198, 199, 200, 201, 202, 203, 204, 205, 206, 207, 208, 209, 211, 212, 213, 214, 215, 216, 217, 221, 223, 224, 226, 227, 228, 229, 230, 232, 233, 239, 240, 241, 242, 243, 244, 245, 246, 247, 248, 250, 251, 252, 253, 255, 256, 257, 258, 259, 261, 262, 263d, 264, 268, 269, 270, 274, 275, 276, 278, 279, 280, 282, 285, 286, 288a, 289, 290, 291, 292a, 293, 295, 297, 298, 299, 301, 302, 304, 307, 308, 309, 310, 311, 312, 316, 317, 318, 320, 321, 323, 324, 325, 328, 329, 330a, 330b, 334, 336, 338a, 339, 340, 341, 342, 343, 344, 345, 346, 347, 348, 353, 357, 358, 360, 361, 362, 363, 364, 365, 366, 367, 369, 373, 375, 377a, 378, 379, 384, 388, 389, 391, 395, 396, 398, 399, 400, 402, 403

76. Bardeen, C. R., 1908. Vertebral regional determination in young human embryos. Anat. Rec., vol. 2, p. 99–105.
2, 109

77. Streeter, G. L., 1908. The nuclei of origin of the cranial nerves in the 10 mm. human embryo. Anat. Rec., vol. 2, p. 111–115.
148

78. Bardeen, C. R., 1908. Early development of the cervical vertebræ and the base of the occipital bone in man. Amer. Jour. Anat., vol. 8, p. 181–186.
22, 144

79. Retzer, Robert, 1908. Some results of recent investigations on the mammalian heart. Anat. Rec., vol. 2, p. 149–155.

80. Evans, H. M., 1908. On an instance of two subclavian arteries of the early arm bud in man and its fundamental significance. Ibid., vol. 2, p. 411–424.
148

81. Essick, E. R., 1909. On the embryology of the corpus pontobulbare and its relation to the development of the pons. Ibid., vol. 3, p. 254–257.
22, 45, 81, 382

82. Sabin, F. R., 1909. The lymphatic system in human embryos with a consideration of the morphology of the system as a whole. Amer. Jour. Anat., vol. 9, p. 43–91.
6, 22, 74, 82, 84, 95, 96, 106, **109**, 128, **144**, **172**, 224, **296**, **350**, **353**, 382, **397**, 413, 423, 424

83. Mall, F. P., 1910. Die Alterbestimmung von menschlichen Embryonen und Feten. Keibel-Mall Handbuch der Entwicklungsgeschichte des Menschen, Leipzig, vol. I. Eng. ed. Philadelphia, p. 185–207.
1, 5, 6, 8, 9, 10, 11, 12 inc., 15, 16, 17, 18, 19, **22**, 23, 26, 27, 28, 30, 31, 33, 34, 35, 38, 39, 40 to 54 inc., 56, 57, 59, 61, 62, 64 to 68 inc., 71, 72, 74, 75, 77, 79, 80, 84 to 90d inc., 92, 93, 94, 96, 97, 98, 99, 100, 105, 106, 108, 109, 113, 114, 116, 117, 118, 120, 121, 125 to 131 inc., 136, 138 to 141 inc., **144**, 145, 146, 148, 149, 151, 152, 153, 155, 156, 160, **163**, 164, 167, 168, 169, 170, 171, 172, 173, 175, 176, 178, 183, 184, 186, 187, 188, 192, 193, 194, 199, 200, 202, 203, 206, 208, 210, 211, 213, 214, 216, 217, 219, 221, 224, 227, 229, 231, 239 to 242, 245, 248, 249, 256, 259, 260, 263a, 263b, 263b[1], 263b[2], 263c, 266, 267, 269, 272, 273, 274, 278, 282, 283a, 283b, 283c, 284, 288b, 288c, 296, 300, 301, 305, 306a, 306b, 306c, 306d, 306f, 306g, 306h, 308, 313, 314, 315, 317, 318, 319, 322, 326, 327, 329, 331, 337, 349, 350, 351, 352, 353, 354, 355, 356, 360, 361, 362, 363, 368, 371, 372, 373, 374, 375, 376, 377b, 377c, 377d, 380, 382, 383, 384, 387, 388, 389, 390, 391, 392, 393, 394, 397, 403, 405, 406, 409, 410, 411, 412

84. ———, 1910. Die Pathologie des menschlichs Eies. Ibid., p. 208–248.
12, 21, 32, 77, 78, 79, 80, 115, 122, 124, 128, 133, 135, 162, 201, 243, 250, 256, 257, 258, 278, 285, 286, 292a, 293, 297, 304, 310, 323, 328, 340, 343, 360, 364, 367, 379

85. Bardeen, C. R., 1910. Die Entwickelung des skeletts und des Bindesgewebes. Ibid., p. 296–456.
2, 12, 22, 76, 79, 80, 84, 108, 109, 144, 145, 163, 175, 184, 186, 241

86. Lewis, W. H., 1910. Die Entwickelung des Muskelsystems. Ibid., p. 457–526.
2, 22, 109, 144, 163

87. Mall, F. P., 1910. Die Entwicklung des Cöloms und des Zwerchfells. Ibid., p. 527–552.
2, 12, 43, 74, 76, 80, 109, 113, 116, 136, 144, 148, 163, 164, 239, 391

88. Dandy, W. E., 1910. A human embryo with seven pairs of somites measuring about 2 mm. in length. Amer. Jour. Anat., vol. 10, p. 85–98.
391

89. Minot, C. S., 1910. Laboratory Textbook of Embryology. Philadelphia.
391

90. Streeter, G. L., 1911. Die Histogenese des Nervengewebes. Keibel-Mall Handbuch, Bd. 2, Leipzig and Philadelphia, p. 1–156.
2, 22, 109, 144, 163, 220, 234

91. Mall, F. P., 1910. A list of human embryos which have been cut into serial sections. Anat. Rec., vol. 4, p. 355–367.
1 to 10 inc., 12, 13, 17, 18, 19, 22, 23, 34, 43, 44, 45, 48, 57, 74, 75, 76, 80, 84, 86, 87, 88, 95, 96, 100, 106, 108, 109, 112, 113, 114, 116, 120, 128, 134, 136, 144, 145, 146, 148, 163, 164, 170, 172, 175, 179, 184, 186, 187, 199, 208, 209, 211, 216, 219, 220, 221, 224, 227, 229, 231, 234, 239, 240, 241, 242, 245, 248, 249, 250, 253, 256, 267, 268, 278, 289, 293, 296, 306a, 314, 317, 318, 338a, 349, 350, 351, 352, 353, 368, 371, 372, 380, 382, 383, 384, 387, 388, 389, 390, 391, 397, 404, 405, 406, 409, 422, 423, 424, 431, 432, 447, 449, 452

92. Wilson, L. B., and B. C. Willis, 1911. A comparative study of the histology of the so-called hypernephromata and the embryology of the nephridial and adrenal tissues. Jour. Med. Research, vol. 24, p. 73–90.
144, 353, 371, 406

93. Lieser, H., 1911. Studies on the development of the human larynx. Amer. Jour. Anat., vol. 12, p. 27–66.
22, 43, 109, 128, 144, 317

94. Lewis, F. T., 1911. Die Entwicklung des Darmes und der Atmungsorgane. Keibel-Mall Handbuch, vol. 2, Leipzig and Philadelphia, p. 282–482.
391

95. Minot, C. S., 1911. Die Entwicklung des Blutes Ibid., p. 483–517.
350, 353

96. Evans, H. M., 1911. Die Entwicklung des Blutgefässsystems. Ibid., p. 551–688.
2, 6, 43, 57, 80, 108, **109**, **144**, **145**, 148, 163, 229, **349**, **353**, 368, 382, **390**, **391**, **448**, **449**, **453**, **460**

97. Sabin, F. R., 1911. Die Entwicklung des Lymphgefässsystems. Ibid., p. 688–724.
6, 22, 57, 74, **86**, **96**, 106, **109**, 128, 144, 163, 172, 224, **296**, 317, 350, 353, 382, 397, 409, 423, 424, **448**

98. Pohlman, A. G., 1911. The development of the cloaca in human embryos. Amer. Jour. Anat., vol. 12, p. 1–23.
2, 12, 22, 43, 76, **80**, 87, 109, 113, 114, 116, 128, 148, **164**, 175, 186, 209, **221**, 240, 241, 256, 296, 317, 350, 353, 371, 383, 391, 397, 409

99. Whitehead, R. H., and J. A. Waddell, 1911. The early development of the mammalian sternum. Ibid., p. 89–106.
109, 144, 175, 296, 423, 424

100. Mall, F. P., 1911. Report upon the collection of human embryos at the Johns Hopkins University. Anat. Rec., vol. 5, p. 343–357.
1 to 500 inc. (No illustrations.)

101. Essick, C. R., 1912. The development of the nuclei pontis and the nucleus arcuatus in man. Amer. Jour. Anat., vol. 13, p. 25–54.
22, 75, 84, 86, 95, 99, 128, 145, 172, 184, 199, 211, 219, 227, 368, 382, 405, 484, 490, 491, 508, 509

102. Mall, F. P., 1912. On the development of the human heart. Ibid., p. 249–298.
2, 3, 33, 43, 46, 80, 86, 90a, 90b, 90c, 90d, 109, 113, 116, 136, 144, 163, 175, 239 241, 249, 283b, 296, 317, 318, 353, 356, 360, 368, 380, 384, 386, 390, 397, 406, 409, 422, 423, 424, 426, 431, 432, 434, 460, 463, 470

103. Lowsley, O. S., 1912. The development of the human prostate gland with reference to the development of other structures at the neck of the urinary bladder. Ibid., p. 299–346.
34, 54

104. Mall, F. P., 1912. Bifid apex of the human heart. Anat. Rec., vol. 6, p. 167–172.
90b, 118, 283b, 353, 360, 434, 455

105. Sabin, F. R., 1912. On the origin of the abdominal lynphatics in mammals from the vena cava and the renal veins. Ibid., p. 335–342.
460

106. Mall, F. P., 1912. Aneurysm of the membranous septum projecting into the right atrium. Ibid., p. 291–298.
113, 164, 353, 391, 463

107. Huber, G. Carl, 1912. On the relation of the chorda dorsalis to the anlage of the pharyngeal bursa or median pharyngeal recess. Ibid., p. 373–404.
221, 371, 389, 406

108. Mellus, E. L., 1912. The development of the cerebral cortex. Amer. Jour. Anat., vol. 14, p. 107–117.
491

109. Williams, J. W., 1912. Obstetrics. 3d ed., N. Y.
19, 82, 164, 278, 550

110. Lowsley, O. S., 1913. The human prostate gland at birth with a brief reference to its fetal development. Jour. Amer. Med. Assn., vol. 60, p. 110.
34

111. Mall, F. P., 1913. A plea for an institute of human embryology. Ibid., p. 1599–1601.

112. Sabin, F. R., 1916. The origin and development of the lymphatic system. Johns Hopkins Hosp. Reports, n. s., vol. 17, p. 347–440.
86, 163, 353, 397, 460

113. Mall, F. P., and E. K. Cullen, 1913. An ovarian pregnancy located in the Graafian follicle. Surg., Gyn. and Obst., vol. 17, p. 698–703.
550

114. Mall, F. P., 1913. Report on Embryological Research. Carnegie Inst. Wash. Year Book No. 12.

115. Evans, H. M., 1914. An appeal to surgeons for embryological material. (Printed privately.)
391, 626, 763

116. Sabin, F. R., 1913. Der Ursprung und die Entwickelung des Lymphgefass-systems. (Ergebnisse der Anatomie und Entwickelungs-geschichte.) Anat. Hefte, Abth. II, p 1–97.
86, 163, 353, 460

117. Mall, F. P., 1914. On stages in the development of human embryos from 2–25 mm. long. Anat. Anz., vol. 46, p. 78–84.
2, 5, 9, 19, 22, 43, 74, 80, 106, 109, 127, 128, 144, 156, 163, 167, 175, 208, 221, 229, 240, 241, 245, 248, 256, 296, 317, 349, 353, 350, 368, 371, 372, 387, 388, 389, 390, 397, 405, 406, 409, 422, 423, 424, 431, 447, 453, 460, 463, 485, 492, 500, 511, 536, 544, 547, 552, 558, 562, 566, 576, 584a, 590, 617, 623, 626, 630, 632

118. Bardeen, C. R., 1914. The critical period in the development of the intestine. Amer. Jour. Anat., vol. 16, p. 427–436.
2, 6, 9, 10, 34, 43, 45, 79

119. Bremer, L., 1914. The earliest blood-vessels in man. Ibid. p. 447.
391

120. Bioelow, P., 1914. Cœlom. Ref. Handbook Med. Sci., 3d ed., vol. 3, p. 138–148.
2, 6, 9, 12, 18, 19, 22, 34, 43, 45, 391

121. Evans, H. M., 1914. An appeal to physicians for embryological material. (Printed privately.)
391, 626, 763

122. Beitler, F. V., 1914. Still-born children. State Dept. Health of Maryland, Bureau of Vital Statistics.

123. Mall, F. P., 1914. Annual report of the Director of the Department of Embryology. Carnegie Inst. Wash. Year Book No. 13, p. 107–115.
1 to 811 inc.

124. ———, 1915. Department of Embryology. Reprinted from "Scope and Organization" of the Carnegie Institution of Washington.

125. Meyer, A. W., 1914. Curves of prenatal growth and autocatalysis. Arch. f. Entwicklungsmech. d. Organ., Bd. 40, p. 497–525.

126. Mall, F. P., 1915. On the fate of the human embryo in tubal pregnancy. Contributions to Embryology, No. 13, Carnegie Inst. Wash. Pub. No. 221, p. 5–103.
109, 154, 175, 179, 183, 196, 197, 256, 294, 298, 307, 314, 324, 338c, 342, 350, 352, 361, 367, 369, 378, 387, 389, 390, 396, 402, 415, 418, 422, 426, 430, 431, 432, 448, 449, 456, 458, 472, 473, 477, 478, 479, 481, 484, 487, 488, 495, 496, 497, 503, 507, 513, 514, 515, 517, 519, 520, 524, 535, 539, 540, 553, 554, 561, 567, 570, 575, 576, 597, 602, 612, 634, 640, 657, 659, 667, 670, 678, 676, 685, 686, 694, 697, 706, 720, 726, 728, 729, 734, 741, 742, 754, 762, 763, 765a, 766, 772, 773c, 775, 777, 782, 784, 787, 790, 794, 804, 808, 809, 809b, 809c, 815, 825, 835, 836, 838, 846, 851, 867, 874, 881, 882, 889, 891, 892, 898, 899, 900b, 900c, 900d, 900e, 900f, 900g, 900j, 904, 908, 910, 911, 919, 927, 928, 932, 934, 938, 939, 945, 953, 967a, 967b, 967c, 974, 977, 990, 992, 995, 998

127. Clark, E. R., 1915. An anomaly of the thoracic duct with a bearing on the embryology of the lymphatic system. Contributions to Embryology, No. 3, Carnegie Inst. Wash. Pub. No. 222, p. 45–54.
460

128. Essick, C. R., 1915. Transitory cavities in the corpus striatum of the human embryo. Contributions to Embryology, No. 6., Carnegie Inst. Wash. Pub. No. 222, p. 95–108.
144, 350, 409, 431

129. Wallin, Ivan E., 1913. A human embryo of thirteen somites. Amer. Jour. Anat., vol. 15, p. 319–331.
1201a

130. Meyer, A. W., 1915. Fields, graphs, and other data on fetal growth. Contributions to Embryology, No. 4, Carnegie Inst. Wash. Pub. No. 222, p 55–68. (Many of our embryos considered.)

131. Streeter, G. L., 1915. The development of the venous sinuses of the dura mater in the human embryo. Amer. Jour. Anat., vol. 18, p. 145, 178.
84, 95, 96, 128, 144, 145, 199, 224, 234a, 296, 349, 350, 382, 448, 449, 458, 460, 544, 588, 613, 632, 886, 940, 966

132. Lewis, W. H., 1914. Development of the fetus. Ref. Handbook Med. Sci., 3d ed., p. 373–384.
2, 12, 22, 91, 109, 163

133. ———, 1915. The use of guide planes and plaster of paris for reconstruction from serial sections: some points on reconstruction. Anat. Rec., vol. 9, p. 719–729.
460

134. Mall, F. P., 1915. The cause of tubal pregnancy and the fate of the inclosed ovum. Sur., Gyn. and Obst., vol. 22, p. 289–298.
154, 196, 298, 307, 314, 324, 361, 367, 378, 396, 415, 418, 430, 472, 477, 478, 479, 488, 495, 507, 513, 514, 515, 517, 519, 520, 524, 539, 540, 553, 554, 561, 567, 570, 575, 602, 659, 673, 685, 686, 694, 720, 726, 729, 734, 741, 754, 762, 765a, 766, 772, 773, 775, 777, 784, 787, 794, 804, 808, 809b, 809c, 815, 825, 835, 838, 846, 874, 881, 882, 891, 892

135. Kingsbury, B. F., 1915. The development of the human pharynx. Amer. Jour. Anat., vol. 18, p. 329–386.
105, 213, 301

136. Mall, F. P., 1915. Development of the heart. Ref. Handbook Med. Sci., 3d ed., vol. 5.
2

137. Lowsley, O. S., 1915. The prostate gland in old age. Annals of Surgery, vol. 62, p. 716–737.

138. Jenkins, George B., 1916. A study of the morphology of the inferior olive. Anat. Rec., vol. 10, p. 317–334.
491, 619, 625

139. Streeter, G. L., 1916. The vascular drainage of the endolymphatic sac and its topographical relation to the transverse sinus in the human embryo. Amer. Jour. Anat., vol. 19, p. 67–89.
96, 448, 449, 458, 460, **632, 1018, 1131**

140. Miller, W. S., 1914. Digestive tract. Ref. Handbook Med. Sci., 3d ed., vol. 3.
6, 9, 10, 45

141. Cullen, Thomas S., 1916. Embryology, anatomy and diseases of the umbilicus. W. B. Saunders Company, Philadelphia and London.
2, 86, 317, 391

142. Mall, F. P., 1917. Annual report of the Director of the Department of Embryology, Carnegie Inst. Wash. Year Book, No. 14, p. 111–125.

143. ———, 1916. The human magma réticulé in normal and in pathological development. Contributions to Embryology, No. 10, Carnegie Inst. Wash. Pub. No. 224, p. 5–26.
12, 21, 78, 79, 94, 104, 122, 135, 136, 148, 164, 211, 230, 244, 250, 261, 270, 278, 318, 391, **402**, 463, 470, 486, **512, 531, 533**, 543, **545, 560, 576**, 584a, **588, 604**, 605, **636, 651g, 660**, 763, 779, 813, **836, 991, 1117**, 1189

144. ———, 1916. The embryological collection of the Carnegie Institution. Circular No. 18. (Printed privately.)

145. Evans, H. M., and G. W. Bartelmez, 1917. A human embryo of seven to eight somites. Anat. Rec., vol. 12, p. 355.
1201

146. Streeter, G. L., 1917. Histogenesis of the otic capsule. Anat. Rec., vol. 12, p. 417.
22, 84, 86, 95, 172, 353, 588, 1018, 1373, 1400–30

147. Wheeler, T., 1917. Study of a human spina bifida monster with encephaloceles and other abnormalities. Anat. Rec., vol. 12, p. 431.
862a

148. Mall, Franklin P., 1917. Organization and Scope of the Department of Embryology, Circular No. 19. (Printed privately.)

149. ———, 1917. Note on abortions with letters from the Health Commissioner of Baltimore and from the Chief of the Bureau of Vital Statistics of Maryland regarding registration and shipment of embryos to the Carnegie Laboratory of Embryology at the Johns Hopkins Medical School. Baltimore. Circular No. 20. (Printed privately.)

150. ———, 1917. Annual report of the Director of the Department of Embryology, Carnegie Inst. Wash. Year Book No. 15, p. 103–120.
1 to 1458 considered.

151. Sabin, F. R., 1915–16. The method of growth of the lymphatic system. The Harvey Lectures, Series XI, p. 124–145.

152. Streeter, G. L., 1917. The development of the scala tympani, scala vestibuli and perioticular cistern in the human embryo. Amer. Jour. Anat., vol. 21, p. 299–320.
84, 199, 886, **1018, 1400–30**

153. Mall, Franklin P., 1917. Cyclopia in the human embryo. Contributions to Embryology, No. 15, vol. 6, Carnegie Inst. Wash. Publication 226, p. 5–33.
12, 148, 163, **201**, 391, 470, **559**, 836, **1165, 1178a**, 1178b, 1201.

154. Young, H. H., and E. G. Davis, 1917. Double ureter and kidney with calculous pyronephrosis of one half; cure by resection. The embryology and surgery of double ureter and kidney. Jour. Urol., vol. 1, p. 17–32.
371, 453, 800, 873, **988**, 1075, **1197, 1354**

155. Gage, S. H., 1917. Glycogen in the nervous system of vertebrates. Jour. Compar. Neurol, vol. 27, p. 451–464.

156. Mall, Franklin P., 1917. On the frequency of localized anomalies in human embryos and infants at birth. Amer. Jour. Anat., vol. 22, p. 49-72.
6, 10, 12, 31, 80, 81, 94, 112, 124, 128, 164, 182, 186, 189, 201, 212, 226, 228, **230**, 242a, 242b, 249a, 249b, 250, 276, 293, 295, 302, **306a**, 314, 316, 328, 335, 338a, 338c, 344, **364**, 365, 370, 371, 413, 433a, 466, 499, 510, **511**, 552, 558, **559**, 584a, 622, 627, 646, 649, 651a, 651f, 653, 676, 710, 732, 740, **749**, 768b, 768c, 779, 785, **789**, 796, 797, 802, 808, **813**, 839, 842, 862, 862a, 862b, **868, 874b, 982, 996, 1140b, 1289, 1295g, 1315, 1330, 1477, 1523, 1690, 1749**
(1000 specimens—from 1 to 900g—treated statistically.)

157. Streeter, George L., 1917. The factors involved in the excavation of the cavities in the cartilaginous capsule of the ear in the human embryo. Amer. Jour. Anat., vol. 22, p. 1–25.
86, 95, 96, 296, 409, 453, 455, 575, 695, 719, 721, 886, 1373

158. Weed, Lewis H., 1917. The development of the cerebro-spinal spaces in pig and in man. Contributions to Embryology, vol. 5, No. 14, Carnegie Inst. Wash. Pub. No. 225, p. 7–16.
75, **144, 199**, 390, 405, **406, 409**, 431, 448, **453, 460, 544, 576, 617**, 632, 695, **721**, 745, 782, **836**, 849, 870, 900*h*, 928*e*, **1008**, 1131, 1134

159. Williams, J. Whitridge, 1917. Obstetrics. 4th ed. D. Appleton & Co., New York and London.
19, 88, 164, 278, 550, 782

CHAPTER III

CLASSIFICATION.[1]

In the now historically very interesting "Prolegomena of the development and metamorphosis of the human ovum" contained in the excellent "Graphic Illustrations of Abortion" published by Granville in 1834, some attempt was made to group the abortuses there reported. The first 6 specimens are spoken of as "lanuginose" ova of several types; the next 3 are designated as denuded or diaphanous; a few are spoken of as opaque; one as "uviform," that is, hydatiform; and several as moles of various kinds. Most of the rest of the 38 specimens were given long individual descriptive names, although several were spoken of as "coriaceous" and others as "avellanated." A case of tubal and the well-known case of ovarian pregnancy are among these specimens.

In speaking of the uviform ovum, Granville emphasized that hydatiform degeneration is a very rare occurrence and gave a very good short characterization of it, saying that although, in this instance, three months had elapsed since pregnancy supervened, nature evidently had spent most of this time "playfully modelling, forming, and cutting out what would appear an artificial plaything, so fantastical it looks."

Panum (1860), from a study of collections of monsters found in various European laboratories, and also from extended experimental work with eggs, formulated a more elaborate classification of deformities, but did not concern himself particularly with the routine material from abortions. It may be recalled, however, that he also spoke of amorphous and cylindrical chick embryos, and that these groups of Panum's practically were equivalent to the nodular and cylindrical embryos of His, Giacomini, and Mall. Panum's group of *monstruositates totales cylindricæ* among abnormal chick embryos were described as young specimens with formless heads and somewhat deformed, rather rod-like bodies, which he ascribed to lowering of the incubator temperature.

His (1882), while considering only younger abortuses, did not recognize the occurrence of empty chorionic and amnionic vesicles, saying that, aside from the two or three specimens in which these cavities were filled with solid blood-clots which made the finding of an embryo impossible, he never saw vesicles devoid of an embryo. This observation is particularly interesting, because empty chorionic vesicles, after all, are not very uncommon and one can hardly escape the conclusion that his failure to see them was due to the fact that physicians sent only the specimens containing embryos. This is not at all unlikely, for they knew, of course, that His's interest centered so very largely upon the form of early human embryos.

All younger embryos abnormal in form, below 15 mm. in length, were classified by His as nodular, atrophic, and cylindrical. Sometimes he also spoke of some of the atrophic forms as flexed or kinked because of the marked drooping of the

[1] Uncredited quotations are from notes or circulars written by Mall.

head upon the chest noticed in some of them. Since these three types of early embryos seem to recur, His emphasized that it was very probable that normal development can be disarranged easily at certain definite stages in prenatal life, a surmise confirmed by contemporary experimental embryology. In the opinion of His, this faulty development almost invariably led to abortion at the end of the second or the beginning of the third month, which period had been noted by A. Hegar (1863) as the time of most frequent abortion of early specimens. It is striking, indeed, that not a single abortus from the later months of pregnancy, which His regarded as capable of continued growth, ever came to his attention.

Giacomini (1888, 1893) also described several nodular atrophic embryos and very significantly stated that he never met with nodular or atrophic forms in rabbits. In these animals he found only advanced deformities, and these he regarded as often merely being the result of death of the fetus with subsequent retention. Hence he did not consider them at all comparable to those found in man. Giacomini also stated that he could experimentally produce all forms of nodular and cylindrical embryos in rabbits, and believed that the atrophic forms were due to changes after death, although he preferred not to emphasize this opinion.

Later, when Giacomini studied these anomalous forms microscopically, he concluded that a classification based on gross appearance only really tells nothing about the nature of the process which has inhibited development, of the time when the changes began, or of their localization and distribution. Hence he emphasized the necessity of a microscopic examination for purposes of scientific classification. He further stated that both the flexed (or kinked) and the cylindrical forms of His could be classed under the atrophic and declared that abortuses can be placed into two main groups, those with and those without an embryo. In 1895 Giacomini further suggested two subdivisions under each of these groups. He divided those without an embryo into (1) specimens with only the embryo missing, and (2) those with little else than the chorion present. Since Giacomini believed that the embryo and even the amnion can migrate from the chorionic vesicle and the hole through which they pass close again by healing, he further differentiated specimens in which the embryo had migrated out entirely, those in which it had reached the cœlom externum, those in which the embryo and amnion had migrated from the chorion, and finally, those in which the active migration of the embryo and amnion had everted the chorion. Since the idea of an active migration of the embryo, not to mention that of some of the adnexa, from out the chorion, does not hold, these four types of empty chorionic vesicles require no further consideration. Specimens in which embryos were present Giacomini classed as nodular and atrophic, after His, the latter class including both the cylindrical and the flexed forms of His. Giacomini's great merit lay in recognizing a group of specimens without an embryo, in making a careful microscopic study, and especially in undertaking experimental work in order to elucidate some of the problems which presented themselves to him in a study of abortuses. These aspects of his work will be referred to again in later chapters.

Although other anatomists, and also some clinicians like Giacomini, took up the problem suggested particularly by the work of His, no one followed it with more devotion that Mall. In saying this I am not ignoring the able and extensive treatises on teratology, such as those of Ahlfeld, Ballantyne, Dareste, Saint Hilaire, Schwalbe, and Taruffi. These treatises are more specifically concerned with the problems presented by malformations, while His, Giacomini, and Mall gave especial attention to questions presented by all abortuses, and Giacomini and Mall especially to such as Mall later grouped as pathologic. I realize that I thus raise the question of the relation of uterine pathology to teratology, but that is unavoidable. Moreover, as everyone knows, it is still decidedly unsettled. This attitude was taken also by Mall (1908) when he wrote:

"Whether the early pathological embryos are young monsters of so extreme a degree that they will not continue to grow, is now the most important question of the capital problem in teratology."

In this monograph Mall did not attempt to classify the 163 pathologic embryos collected during a period of 15 years. Nevertheless, as his collection grew, some classification became highly advisable. In referring to this matter later, he wrote:

"In considering a large number of specimens from a scientific standpoint, their classification[1] is one of the most important things. All of our specimens are placed in one of two great divisions—normal or pathological. As stated before, the normal ones usually are easily segregated because, for the sake of expediency, we have decided to regard as normal all embryos and fetuses which are normal in form, although they may be inclosed in diseased chorions. These normal specimens are first arranged according to size and subsequently also according to age."

All normal embryos and fetuses further are placed in one of three grades, according to the preservation of their body form. The basis of this gradation is wholly gross morphologic. Moreover, it would perhaps be more correct to say that the deciding factor is not the degree of normality of form which may once have existed, but the extent to which it is preserved. If the form is preserved perfectly, the embryo or fetus is placed in the first of these grades unless it has a localized anomaly. However, abnormal specimens also are found among the group of normals, and, as already indicated, some of the normal specimens no doubt have developed upon a somewhat diseased endometrium, but so far we have been unable to recognize these in the early stages of development.

All specimens the form of which is excellently preserved are put into grade 1 of the normal, but if the external form is changed slightly, either by external forces, by maceration, or by developmental abnormalities, they are put into grade 2. All other specimens regarded as normal in form, *with or without anomalies*, fall into grade 3. Abnormalities are noted especially by cross-references, but no separate category of abnormal embryos is maintained. Hence, under this plan, a double monster, such as No. 2107, with six extremities, some of which also are monstrous, with one set of deformed genitalia, and with totally fused trunks, becomes classified

[1] For the earlier classification of the specimens in the Mall Collection see Mall (1900, 1903, and 1904).

as a normal fetus with localized anomalies. Nor is provision made for such specimens in the pathologic group. Since an embryo or fetus may be entirely, or at least approximately, normal in form, even if somewhat macerated, it follows that macerated specimens also are found in these grades of the normal. But, as will appear later, maceration soon changes the form of the embryo. Hence it follows that none except perhaps extremely small specimens can be markedly macerated and still apparently retain their normal form. In these the maceration which is present may become evident upon microscopic examination only.

None of the specimens in grades 2 and 3 is perfect in form, and these grades contain relatively more macerated specimens than grade 1. A splendid example of a normal, slightly macerated fetus is No. 782; although obtained at hysterectomy, it undoubtedly is macerated, yet in spite of this fact it is found in grade 1. This fetus probably died some time before operation, perhaps in consequence of endometritis. The embryonic tissues are markedly macerated in spite of the fact that the entire uterus was placed in formalin immediately. Since the chorionic cavity was not infected, this maceration must have taken place under absolutely aseptic conditions, yet it nevertheless is quite evident.

A series of embryos that really does not belong within these two grades of normal specimens are those with localized anomalies. These, of course, really are abnormal, though not necessarily pathologic in the sense of being themselves diseased. They may, however, be the products of disease elsewhere or have arisen from defective ova or spermatozoa. The division of normals also contains specimens not perfect in form merely because they have sustained fractures or have been mutilated, and since no separate group is maintained for those possessing hereditary abnormalities, some of these too are included among the normal.

Specimens which are not included in any of the above three grades of normal embryos or fetuses are classed as pathologic. This does not imply, however, that they themselves necessarily are diseased. In fact many (most?) of these specimens probably were the victims of accident, interference, or untoward conditions, and hence may have been entirely normal at the time of death. In this division also are found empty normal chorionic vesicles from which the embryo was expelled after the membranes had ruptured, or in which the embryo had become disintegrated in consequence of maceration changes due to interference or to other causes. It also contains specimens of fetuses which, for one reason or another, died after the escape of the amniotic fluid, and which then were retained for some time in utero after being expelled from the chorion. The same thing is true of some normal specimens which died in consequence of degenerative changes in the chorion or the placenta. All these specimens, although possibly wholly normal in development, might, if retained long enough, even under aseptic conditions, fall into the pathologic division. This division, as well as that for the normal embryos, no doubt also contains embryos and fetuses which have been affected by maternal uterine or constitutional diseases, especially by endometritis or lues. Since, as already stated, abnormal embryos or monsters are not grouped by themselves,

some of these also are included in the pathologic division, though most of them are classed as normal with localized anomalies. Moreover, it has been found that—

"A certain number of specimens can not be classified satisfactorily in any of the groups, either normal or pathologic. For example, we have in our collection 4 specimens of cyclopia. One is in an embryo which is perfectly normal, except that it contains a single eye; the second is a stunted embryo which is more or less macerated; the third is a fetus compressus, and the fourth is a double monster. These have been entered in our catalogue as follows: Normal with cyclopia; stunted with cyclopia; fetus compressus with cyclopia; double monster with cyclopia. These varieties naturally include all specimens usually designated as monsters. The double monster mentioned above, curiously enough, becomes recorded as a normal twin embryo with cyclopia, but it is difficult to avoid this contradiction with the method of classification we have adopted."

The pathologic division, which does not comprise the greater number of specimens, is subdivided into seven classes, largely on the basis of the degree of *destruction* of the ovum or embryo. This holds unless we are to assume that the chorionic and amniotic vesicles can develop regardless of the presence of a cyemic primordium. Particularly in the first three groups, the degree of destruction of the cyema is the determining factor, for in all of the specimens in these groups it is missing. (1) The first group among the pathologic is composed of small remnants of specimens which usually are found to consist of villi only; most of these are derived from tubal pregnancies. (2) The second group is composed of small specimens which are represented by chorionic vesicles wholly devoid of contents save blood and the disintegration products of the embryo and amnion, blood, coagulum, or magma. (3) In the third group are placed specimens in which, in addition to the chorion, the amnion, in part or in its entirety, is present. These specimens usually are somewhat larger.

Although the *absence* of the cyema is the determining factor for the inclusion of a specimen in the first three groups in the pathologic division, its presence, no matter in how modified a form, is the criterion which places the specimen in one of the last four groups of this division. In general, it may be stated that the specimens in the last four groups are classified according to the degree of the change which they have undergone. "If the embryo is affected so as to appear as an amorphous nodule, it is placed in group 4; but if a cephalic or caudal extremity still can be recognized, it is placed in group 5." The word *affected*, as used here by Mall, does not, however, carry with it the idea of dismemberment by force, for a *macerated* fragment of a normal embryo manifestly should not be classed here. However greatly the form of an embryo may have been modified, this modification must not have resulted from the mechanical removal of a portion of its substance. It is true that it is often impossible to determine whether a given modification in form has thus arisen. Sometimes, indeed, it is impossible to distinguish, by external examination alone, the stump of a cord or the yolk-sac from a nodular embryo, for in the main the classification of a specimen is determined by inspection alone with or without the aid of low magnification. Some of the speci-

mens in the nodular group also contain rudiments of the extremities, for even with these present it has not always been possible to recognize the cephalic or caudal extremity by inspection alone. Since the position of the extremities ordinarily would suffice to make such recognition possible, it is necessary to recall in this connection how pronouncedly the body-form of the nodular embryos often is changed. In addition to such specimens, the nodular group contains three other kinds, such as stumps of the umbilical cord, isolated yolk-sacs, and sessile nodular embryos, many of which have nothing that could properly be regarded as a cord.

In specimens classed in the fifth group of the pathologic division the embryo is destroyed almost entirely, but its head end can still be recognized. Hence it is designated as cylindrical, but the use of this term does not imply that these specimens are hollow, or wholly without limb-buds even.

"In this group are often included specimens of embryonic remnants which, upon close examination, prove to be the naked umbilical cord. As soon as such specimens are detected they are distinguished by a second entry—*cord*. Unfortunately, these two types of specimens, although out of relation, fall together in our catalogue, but this discrepancy can not be avoided without giving up our plan of retaining the first entry of a specimen."

Indeed, specimens in which the body of the embryo has been so modified as to represent a rod are often indistinguishable upon inspection alone, not only from remnants of the cord, but also from rolled-up decidual or from cyemic remnants or polyps.

In the next or sixth group of the pathologic division, "the embryo can easily be recognized, but it is unusual in appearance, the head, extremities, or some other part of the body being atrophic, and for this reason this type is termed *stunted*. Usually all the parts are more or less degenerated. Most of these embryos are small, but they also can be classified according to their length. The histories show that these embryos are much older than normal ones of the same size, indicating that an arrest of development must have taken place." In these specimens the normal proportions also have changed. Moreover, since the adjective *stunted* implies a physiologic cause, it is necessary to add that in some of them the stunting, no doubt, is apparent only and is the result of distortion incident to, if not consequent upon, maceration. In such cases, then, the stunting is in no sense the consequence of an interference with the nutritive supply of the embryo.

Specimens of pathologic embryos and fetuses, mainly the latter, not included in the above six groups, are classed in group 7. "This last group is composed mainly of large specimens which are atrophied, dried up, or macerated. If the tissues are soft and edematous we call the specimen macerated; if it is dried up and atrophic we call it *fetus compressus*. In the course of time we may find that these two forms should be classed separately, but for the present it appears as if one is the forerunner of the other."

Anyone who reflects upon this classification will easily recognize its shortcomings. These were not overlooked by Mall. In the handling of a large series

of specimens, a simple, serviceable, even if rough classification is extremely useful. Moreover, under present circumstances, the first examination must be a gross and also a rather superficial one, unless technical assistance adequate to make a final diagnosis within a few days of the receipt of the specimen is available. This not having been the case, it has been found that a certain amount of shifting becomes inevitable unless the groups are to become mixed. The shifting necessitated by further examination is indicated in table 4. However, as the histories become

TABLE 4.—*Showing the shifting within the groups necessitated by microscopic examination.*

No. of group.	No. originally in group.	Specimens transferred to—							Final number in each group.
		Group 1.	Group 2.	Group 3.	Group 4.	Group 5.	Group 6.	Group 7.	
1	17	0	70 593	573	.....	.....	.....	.....	16
2	42	644	.....	771*a*	.....	.....	.....	.....	48
3	22	.....	.....	.....	.....	.....	.....	.....	45
4	54	941	21 123 147 770 791	130 469 143 531 180 658 257 803	.....	839	325 788*a*	.....	63
5	73	0	93	279 960*a* 483 976 518 985 556 584*b* 689 701 723*b* 814	25 433 32 446 37 441 166 528 189 610 198 674 692 244 795 253 807 275 830 291*a* 943	.....	104 232 365 653 771*b*	.....	48
6	74	.....	.....	.....	161 264 309 433*a* 573	115 413 142 414 246 419 347 399	.....	124 649 797	80
7	71	.....	.....	605	.....	150 205 289 400 655	188 601*c* 739 334 635*e* 802 348 651*a* 962 375 681 983*a* 521*f* 732 993	.....	53

more complete, and the data which they contain also more reliable, and especially as our knowledge of chorionic and placental pathology becomes fuller, an entire reclassification may become advisable, if not inevitable. This, however, should not be cause for regret, for it is in the line of progress. Indeed, it was not unanticipated, and the revision indicated in table 4 was made at the request of Mall. It would seem, moreover, that a modification in classification is indicated also by the main thesis of Mall, that faulty implantation is the cause of abnormalities. Yet under the present classification, as Mall himself explained, cyemata with marked abnormalities frequently are classed as normal. Moreover, normal specimens are included among the pathologic division, which, strangely enough, contains no group of abnormals. This difficulty can be remedied easily, but how soon other difficulties indicated above can be overcome or be eliminated will depend

very largely upon the further development and utilization of this already unique collection and upon the degree of coöperation which can be secured from clinicians and administrators.

After considerable reflection upon this classification, and some experience in its daily application to material as received from physicians, I shall permit myself certain suggestions, especially since they were invited by Mall himself. It would seem that a division of all conceptuses into the long-established classes of normal and abnormal has certain advantages. This would be true even if it were as difficult to discriminate between the normal and the abnormal or atypical as between the normal and the pathologic. A careful structural examination can always decide the former, at least after the establishment of an arbitrary limit for the range of normal variation. But until we can recognize the earliest morphologic and cytologic changes resulting from pathologic conditions, it often must remain impossible to decide between the normal and the pathologic. That day seems to lie far in the future—much farther, indeed, than the possibility of a final determination regarding the normality or abnormality in form of early cyemeta or chorions.

A division into normal and abnormal also would avoid the awkward necessity of classifying monsters as normal and of putting all specimens composed of normal villi, of normal empty, damaged, chorionic vesicles, and of normal ruptured chorionic and amnionic vesicles into the pathologic division. A grouping into the normal and abnormal also would enable us to frankly recognize the fact that normal specimens may become decidedly macerated, but should therefore not be grouped among the pathologic. Furthermore, it would enable us to recognize the possibility, first emphasized by Giacomini, that normal cyemeta possibly may be changed so as to perfectly simulate the atrophic and stunted forms.

The division of abnormals also could be understood as including not only specimens resulting from anomalous development, *i. e.*, true malformations, but also those which have been affected by disease. Some of the latter, if not anomalous also, would fall in the group of normals, as they rightly should. Moreover, unless it can be confidently assumed that abnormal ova and spermatozoa have no existence, some of the cyemata now classed as pathologic evidently are not the direct products of disease. A specimen certainly may be abnormal without being pathologic and pathologic without being abnormal in form.

Phisalix (1890) also called attention to the fact that an embryo which is pathologic is not necessarily abnormal. A fetus that dies *in utero* while the mother is suffering from an infectious disease may well be, and often is, pathologic, but it is not necessarily abnormal. Neither is a specimen necessarily pathologic which dies under fortuitous circumstances and is retained sufficiently long so that maceration changes very materially alter its form. Likewise, fetuses which die as a result of extreme twisting or strangulation of the cord, or from premature separation of the placenta, or from some other accident of pregnancy, are not necessarily pathologic. Yet all these, if retained sufficiently long, might, under the present classification, fall into this division.

Although we know very little about the existence of abnormal ova, the relative frequency with which anomalous forms of spermatozoa occur would alone seem to make decidedly venturesome the assumption that there is no such thing as germinal anomalies. In view of the fact that we frankly recognize the occurrence of hereditary anomalies, germinal causes certainly can not be excluded. Yet I presume it would be difficult to refer to such specimens as pathologic unless we extended the customary meaning of this term very materially.

After grouping all specimens among the abnormal and the normal, each of these classes could then be subdivided very much as the group of pathologic specimens under the Mall classification—*i. e.*, fragments of villi or vesicles may be either normal or abnormal; and I think it will be possible to show that the same may be true, certainly of the macerated, and probably also of most of the stunted cyemeta, for death in these may have been due purely to mechanical or other causes, which have not resulted in any abnormality of development, the changes in external form being the result of postmortem antepartum changes, as suggested by Giacomini.

By the addition of three groups before that composed of villi only, all abortuses would seem to be provided for. These groups would be composed of those containing syncytial remnants only, those containing trophoblast only, and those containing both syncytium and trophoblast. However, since as Müller (1847) emphasized, normal embryos may be found in diseased vesicles and abnormal embryos in normal vesicles, it also will be necessary to classify vesicles and cyemata separately whenever both do not fall into the same group.

CHAPTER IV.

ANALYSIS OF ABORTUSES CLASSED AS PATHOLOGIC.

GROUP 1. SPECIMENS COMPOSED OF VILLI ONLY.

A. Uterine.

Among the series of over 2,000 abortuses in the Carnegie Collection I have so far been able to find only a few specimens which undoubtedly fall into the category of intrauterine absorption. Among these are Nos. 698, 970, 1640, and 1926. Nevertheless, not even in these cases had total absorption occurred, and from evidence to be considered I have really come to doubt whether absolutely complete absorption occurs in man in any but the earliest stages of development or under the rarest conditions.

As stated by Mall, specimens of the first class of the pathologic division, *i.e.*, those composed of villi only, are obtained very largely from tubal pregnancies. Nevertheless, Mall emphasized that "a very large number belonging to this group would be found in uterine pregnancies also if our methods of collection and study were as reliable as they are for tubal pregnancy." Of the 353 uterine specimens classed as pathologic among the first 1,000 accessions, only 17, or 4.8 per cent, are composed of villi only, as compared to 35, or 32.4 per cent, of 108 tubal specimens. That is, specimens composed of villi only are nearly seven times more common among tubal than among uterine gestations. However, this is due almost wholly to the fact that the uterine specimens are fairly representative of the whole period of gestation, while the tubal specimens are derived almost wholly from the first two months of pregnancy. Specimens composed of villi only would form about the same proportion among uterine abortuses contained in the first two groups of the pathologic, as among the tubal, but they form only 12.9 per cent of all uterine specimens contained in the first four groups of this division. Hence the inference that the great majority of tubal conceptuses come to an early death seems indicated by these facts alone.

That villi *only* are so frequently found in tubal pregnancies is probably due also to the occurrence of tubal abortion, in consequence of which the conceptus may be ejected from the tube but some of the villi left attached, and more especially to the effect of repeated hemorrhage. The conceptuses often are strangulated as a result of hemorrhage which detaches them completely and then leads to their disintegration. Although the villi may be, but probably are not, inherently more resistant than the rest of the chorionic vesicle, some of them usually survive, because in the absence of a decidua which becomes detached, they remain attached to the implantation site, thus retaining their connection with the source of nourishment. In uterine specimens this is impossible, for the entire decidua is cast off. For these, and probably also for other reasons, Mall found that villi almost always can be detected by microscopic examination of serial sections of the implantation

cavity in cases which clinically are tubal pregnancies, even if they can not be detected by the most careful inspection of the gross specimen or by microscopic examination of frozen sections of portions of the implantation site.

Whether or not the surviving elements of a conceptus are villi only depends very largely upon the age of the conceptus and upon the sequence of events responsible for its death. Indeed, if the entire conceptus is erupted from its implantation cavity by a sudden severe hemorrhage, it is very unlikely that the villi will be the surviving elements, unless the conceptus is extremely young. The same thing would be true of a conceptus which a severe general inflammatory process had suddenly detached. For in both of the assumed cases the villi would undoubtedly succumb to the destructive processes earlier than the chorionic membrane, the syncytium, or the trophoblast. If, on the other hand, the infectious process gains entrance into the cavity of the chorionic vesicle itself, the latter and the embryo rapidly disintegrate and are destroyed, while some of the villi may long remain in a state of relatively good preservation.

From these considerations it is evident that it would be possible to form three other groups of specimens in addition to those composed of villi only—those composed of remnants of both trophoblast and syncytium, or of one or the other alone. That such specimens actually occur will become evident in the course of this discussion. At present they are included in group 1. However, it is not for this reason alone that the designation "*villi only*" does not fully describe the first group in the pathologic division. Three specimens in this group, for example, are hydatiform moles, one of which, No. 323, forms a large, compact mass, a portion of which is shown in section in figure 6. Another is composed largely of blood-clot surrounded by decidua, and still another consists largely of a decidual cast with mere traces of syncytium, trophoblast, and perhaps of portions of one or two villi. Furthermore, since it is practically impossible to examine all specimens in their entirety in a complete microscopic series, there is some possibility that the portions examined may not form an adequate basis for the correct classification of the specimen. Hence, for this reason also some specimens are bound to get into incorrect categories. Nor is it without significance that no provision is made among the normal specimens for a group of villi only. Under the present classification all of these are placed in the pathologic division. This would seem to imply that normal villi are never aborted alone in uterine pregnancy or found alone in tubal pregnancies or in tubal abortions. Yet material from curettage, or from abortions the result of interference by the patient herself, no doubt may contain none but normal villi. I have seen the question raised nowhere, but it seems doubtful whether, except perhaps in the earliest stages, villi can ever develop wholly normally in a tube. Hence the above objection to the present classification might be waived for tubal but not for uterine specimens.

Among the possible causes of the destruction of conceptuses, inflammatory conditions, as indicated by infiltration, as a rule seem largely predominant. They existed in the great majority of the uterine specimens, protocols of which are

attached, and sooner or later seem to lead to fetal death. It is interesting that fetal death in these cases is not the result of invasion of the conceptus, or even of its villi, by the inflammatory process itself. It is possible that the production of toxins may be a factor, but the morphologic evidence seems to point to interference with the nutritive supply through decidual and chorionic changes. It is not difficult to see that the accumulation of pus in the region of attachment of the villi, or even the accumulation of large masses of leucocytes, must seriously interfere with the free intervillous circulation. Obstruction to the blood-current, if sufficiently severe, would also lead to the death of the cyema, and finally to that of the chorionic vesicle itself in consequence of interference with the indispensable gaseous interchanges.

No matter how severe the infection of the uterus was found to be, or how large the accumulations of pus at the region of implantation, well-preserved villi never were found infiltrated with cells of maternal origin. When infiltration was present within the stroma the latter, and especially the epithelium of the villi, could be shown to be degenerate. If, on the other hand, the infectious process was introduced directly into the chorionic vesicle, the latter soon disintegrated and the infection extended into the stroma of the villi also. An insuperable difficulty encountered in connection with the question of infection in many cases is the inability to determine positively whether the infection existed within the uterus before implantation occurred, or whether it was incidental to mechanical interference. An examination of the material seems to show that the final effect upon the villi, and of course also upon the membranes of the embryo, rarely may be the same in both cases. This probably is due to the fact that a young conceptus may be loosened partially only, at the time of interference or of infection, thus establishing conditions which lead to its death. As a rule, however, in these cases maceration changes are likely to be much more rapid than under conditions of a chronic endometritis pre-existent to the conception. Nevertheless, mild general or a severe local preimplantation endometritis no doubt could produce results wholly comparable to those resulting from a mild general uterine infection incident to mechanical interference, especially in the case of young conceptuses. It is conceivable that in the case of a low-grade endometritis, the fertilized ovum may undergo a perfectly normal development for a restricted period, and then suffer from more or less sudden interference with its development through exacerbation or extension of the infectious process, just as might be the case under other conditions. Ordinarily, however, it would seem that the changes within the conceptus should be more gradual, and also much more general under conditions of a chronic endometritis than under those of accidental or incidental infection. Nevertheless, the changes in the villi sometimes appear wholly comparable in both cases. The stroma in many of them finally undergoes what Mall has called *mucoid degeneration,* with complete disappearance of the mesenchyme and final disintegration of the epithelium. The blood-vessels generally become effaced at a very early day before the stroma has undergone any important changes. Rarely, as the en-

dothelium degenerates, it leaves a faint, more or less incomplete outline marked by the degenerating nuclei. Consequently it happens that the surviving remnants of a vessel may be represented merely by a small number of poorly preserved nuclei.

The epithelium of the villi usually is preserved longer, but finally the syncytium may fuse with the Langhans layer, forming a dense coagulum. Or the pycnotic nuclei of both layers may retain their relative positions, ultimately becoming resolved into fine granules which Mall, in several of his publications and also repeatedly in the protocols, has spoken of as *nuclear dust.* This fine granulation seems to herald beginning calcification. Later the granules may fuse with each other and with the necrotic cytoplasm, forming a hyalin band at the periphery of the villus, which stains heavily with eosin and also with iron hematoxylin. It alone may make the outline of the pre-existent villus evident. Fibrosis of the villi is seen but rarely in these early specimens, and when it occurs, hyalin degeneration is not infrequently present in the form of trabeculæ or a framework in the midportion of the villus. Remnants of the syncytial masses or of trophoblast usually survive everything else.

Since no decidua and very little trophoblast were found upon the villi of several young conceptuses, it seems doubtful in some cases whether good implantation occurred at all, as suggested by No. 1843, shown in figure 7. In these specimens the villi nevertheless seem to undergo considerable development, but the embryo, after it becomes dependent upon the circulation, finally dies, probably by asphyxiation, and then the processes of maceration, digestion, and absorption begin. In other cases it also seems likely that the young ovum becomes embedded quite normally, but that strangulation results from severe hemorrhage which loosens the attaching villi, thus interrupting the intervillous circulation. Since the resulting stagnation of the blood must make impossible the indispensable chemical interchanges upon which the life of the cyema depends, the latter probably dies first.

It is decidedly interesting that considerable hemorrhage, sufficient to result in the death of both cyema and chorionic vesicle, can occur while the whole conceptus is still surrounded by the early decidua capsularis without rupture of the latter. Such a specimen was discovered in No. 698, which is in the final stages of absorption. In this unique specimen (received from Dr. N. E. B. Igelhart), which has a menstrual age of 56 days, there remains only the merest trace of a chorionic vesicle in the form of a striated coagulum, a few questionable "shadows" of villi, several small fragments of syncytium, and a few detached accumulations of trophoblast. The place of the conceptus is occupied by blood-clot formed into an elongated body 50 by 20 by 13 mm. This body is completely surrounded by an intact decidua capsularis. The latter is easily recognized, both in the gross and in the microscopic specimen, and the decidua vera, which also is intact, can be seen clearly with the unaided eye in every detail of its relations, as shown in figure 8. This indeed is a unique specimen and especially significant in connection with No. 970, to be discussed in the next group, and with certain better-preserved specimens recorded in the literature. The failure of complete absorption of the last few small remnants of this conceptus is probably due to the fact that the small

remnants of degenerated trophoblast and syncytium which remained were no longer able to inhibit menstruation. Hence the decidua of pregnancy, together with these few small remnants of the conceptus, was expelled *in toto* at the time of onset of the next period, and it may be extremely significant that this occurred exactly two menstrual months after the beginning of the last period. Since 3 other specimens of a series of 16, composed of villi only, were aborted at the time of recurrence of the regular period, the idea that abortion occurs oftener at that than at any other time would seem to receive some confirmation. Moreover, it would appear quite natural that a decidua which has subserved its functions would be more likely to be shed at this time and that an unabsorbed conceptus which had been converted essentially into a foreign body should then be expelled.

It is impossible to decide how far the development of this conceptus had progressed before its death, but the extent of absorption shows beyond any doubt that the latter would have been absolutely complete before the advent of the next or third period had the second period also been inhibited. Since in the assumed case the decidual cast then would have been expelled after the ovum had been completely absorbed, this decidual cast might have directed attention to the possibility of the existence of a tubal rather than a uterine pregnancy. In view of the facts here revealed, such a sequence of events might well give the impression of the existence of an early tubal pregnancy which had undergone spontaneous retrogression without ever having given rise to the characteristic symptoms. In this connection I am reminded of the fact that gynecologists have been of the opinion that some tubal pregnancies undergo spontaneous cure. In many of these cases the healing probably follows tubal abortion, but specimens in this collection also indicate the possibility of another sequence of events. In some instances, for example, the small intratubal blood-clot in which a small conceptus becomes enclosed at the time of hemorrhage seems to undergo reduction within the tube. Under these circumstances the conceptus, which was separated from its implantation site, may then undergo retrogression, maceration, disintegration, and finally may be completely absorbed, and the tube heal. Nor does it seem impossible that the chorionic vesicle may remain and undergo a similar fate within the tube in cases in which the cyema alone is aborted.

Of the 16 specimens finally classed in group 1, all of which were examined both macroscopically and microscopically, 7, or 43.7 per cent, show hydatiform degeneration. In each of these specimens the abortion very probably was not induced. In 5 of these specimens in which some or all of the decidua accompanied the specimen, it showed changes indicative of endometritis. In 4 of these the infiltration was marked and in one it was slight. One specimen counted as showing hydatiform changes was extremely degenerate, however, and unaccompanied by decidua, and may therefore perhaps be rejected, thus leaving 6 specimens, or 37.5 per cent, definitely showing hydatiform degeneration.

The decidua was included in 13 of the 16 specimens in this group, but the material was very necrotic in one case and too little of it accompanied another. The infiltration was slight in one of the remaining 11, and very marked in the other

10 cases. Hence, although infiltration of the decidua was present in only 10, or 62.5 per cent, of the 16 specimens of this group, the decidua showed definite signs of inflammation in every one of the 10 in which it was present and sufficiently well preserved. Some decidua, in fact, contained considerable masses of purulent material. The infiltration was often very marked locally, small accumulations of leucocytes being scattered about more or less at random; but this form of infiltration frequently was accompanied also by an infiltration more or less general and uniform in character, and by other changes. Whether or not these infiltrations were confined to the decidua I am not able to say, for uterine musculature was not included. In most cases, however, the process had the appearance of a low-grade chronic inflammation. In only a few was a severe infection very evidently present.

Of the abortuses composed of villi only included in the first 1,000, all but 3 had a maximum length of less than 50 mm. One measured 68 mm., another 100 mm., and a third 120 mm. However, since considerable allowance must be made for distortion, for variations in the length of villi, and for maceration, as well as for increase in size due to the surrounding decidua and blood-clot, it is evident that the measurements of the abortuses are often too large to represent, even approximately, the true age, not only of the accompanying cyema, but of the chorionic vesicle or placenta as well. It is evident also that, in case of abortuses composed of villi only, the measurements, even if not affected by the presence of blood-clot and decidua, could in no sense be more than roughly indicative of the age of the specimen unless the chorionic membrane were preserved sufficiently to retain its form and size. Furthermore, since the specimens in this group include material from curettage also, a discussion of their size as related to their anatomical or menstrual age can have no value.

The largest specimen in this group is a hydatiform degeneration, containing no trace of the cyema. Such a specimen can not with propriety be designated as villi only; nevertheless, the exigencies of the situation make its inclusion here of some practical value. In other instances one could speak of the size of the mole, perhaps, but unless composed of solid masses of villi, moles really belong in the second group. In still other instances, such as No. 698, the main mass of the abortus was composed of decidua, so that although only what was originally taken for the chorionic vesicle was measured, this measurement nevertheless is wholly erroneous, for it is impossible to exclude the blood-clot, which, in this case, very greatly affects the size of the specimen.

Unfortunately, menstrual age is not a reliable criterion of the true age of the specimens in this group, the state of preservation of which alone indicated that many of them were retained a considerable length of time after their death. The latter is indicated, not only by the disproportion between the size of the abortus and the menstrual age, but also by the degenerative changes present in the specimens themselves. The longest menstrual age (218 days) is found in specimen No. 70, in which the size of the conceptus or cyema indicates an anatomical age of only 50 days.

Upon attempting to correlate the clinical data with the objective examination, it was found that in one case in which abortifacients were held responsible for the termination of pregnancy, an intense infection was present. This was true also in four other cases, in which it was specifically stated that infection was absent, a conjunction of things to be referred to again.

B. Tubal.

In contrasting the tubal specimens composed of villi only with similar specimens from the uterus, the lesser number of villi contained in the tubal cases is very striking. It may be recalled that the number of villi found in uterine specimens varies from none to large hydatiform masses weighing several pounds. But even aside from the latter, which properly do not belong in this group, villi found in uterine specimens are far more numerous, as a rule, than in the tubal cases. One of the main reasons for this difference lies in the fact that the tubal specimens as a whole undoubtedly are much younger and hence less resistant. Their youth may be explained very largely by the anatomical conditions under which development proceeds in the tube and in part probably also by the efforts at abortion which probably are inaugurated very early through the occurrence of tubal peristalsis. It is not unlikely that this peristalsis may expel most of the villi, with the surrounding blood-clot, into the peritoneal cavity, leaving behind only a few stragglers. In the absence of anything truly comparable to decidual development within the tube, the villi at best must be embedded less securely and also may degenerate faster when once detached. Moreover, in the absence of such a nidus as the hypertrophied endometrium, the whole development of the conceptus necessarily must be retarded.

Most of the villi in tubal specimens lie isolated in the contained blood-clot; hence matting of the villi was practically absent and calcification and coagulation necroses were not seen, facts which suggest the occurrence of early interference with development. Sometimes a few villi which lay near each other were decidedly necrotic, but they were not fused into a large, solid mass by degeneration or by inflammatory products in any of the cases in this group. This fact and the appearance of the clots would seem to suggest that there often is a constant trickling of blood from the distal extremity of the tube, so that old clots form slowly, new blood being added more or less constantly, thus prolonging the life of some villi, or at least of the chorionic epithelium. In several cases the villi were quite well preserved, though fibrous, but by far the greater number were decidedly degenerate. Except in instances in which the whole villus was necrotic, the epithelium was preserved better than the stroma, a fact which probably may be explained by the presence of fresh blood. In all except the necrotic specimens, the epithelium not only was well preserved, but also was not infrequently very active, as noted in several instances by Mall (1915). Considerable masses of trophoblast were present in a number of instances, and smaller syncytial masses (or more frequently syncytial buds) also were seen. Usually some portions of both were extremely well preserved, and in one instance large masses of degenerate trophoblast completely filled

the interplical spaces and the mucosal diverticulæ along a considerable sector of the tube. In two other instances the degenerate trophoblast which bordered, and to some extent invaded, the musculature reminded Mall of Hofbauer cells.

The stroma of the villi was non-vascular in practically all instances, and only a few small remnants of the degenerating vessels remained in some. To some extent absence of vessels may be due to the youth of the specimens, but in the main it is probably due to other factors. Even the villi that were capped by considerable trophoblast and syncytium and which still were implanted in the musculature were often non-vascular, and their stroma, as noted by Mall, was usually mucoid. In contrasting the changes in the stroma of the villi found in tubal with that of the same group of uterine specimens, the more degenerate character of the stroma in the former is very evident. Moreover, not a single villus with a fine, clear, glassy, translucent stroma was seen in this group, nor were any present which had a well-preserved young cellular stroma, or others in which the formation of more than a few Hofbauer cells was in progress. The whole appearance was rather that of a rapid destruction, although most of the clots in which the villi were embedded were relatively fresh. Considerable portions of the clots often contained a fibrin network, but all were unorganized, and no instances of an ingrowth of connective tissue from the tubal wall were seen, in spite of the fact that a few of the clots were relatively old and necrotic.

In two instances in which no portion of the tube had been cut, the presence of infection in it was made probable by the appearance of the contained clots. In most of the latter the leucocytes were congregated more or less, or were formed into small clumps even. Phagocytosis of the fetal membranes by the leucocytes or by other cells was not noticed, although leucocytes had accumulated at the periphery or even had entered into the interior of the stroma of degenerate villi. No embryonic remnants whatever were found in the sections of a portion of one tube, and degenerate trophoblast and syncytium only were present in two. This fact, however, does not imply that phagocytosis was responsible for the absence of villi.

Out of the 33 specimens originally in this group, 2 were found to contain remnants of the chorionic membrane and of the amnion, and hence were transferred to groups 2 and 3 respectively, and 10 were added. In 3, or 9 per cent, of the 42 cases remaining, no infiltration, either of the clot or the wall of the tube, was noticed. In 12, or 28.6 per cent, the infiltration was marked, and in 17, or 40.4 per cent, it was slight.

Changes simulating those of lues were noticed in no tubal conceptuses in this group, but several excellent examples of hydatiform degeneration were found in Nos. 415, 602, 686, 772, and 889. According to Seitz (1904[c]), the occurrence of hydatiform moles was observed in connection with tubal pregnancies by Freund, Matwejew and Sykow, Otto, and Wenzel. Others no doubt have observed it since then, but as only a few villi are contained in a single cross-section of the tube, and but few cross-sections of each specimen were examined in our series, one can

not be certain of one's diagnosis in every instance. If more villi were present this difficulty would be obviated, although it must be remembered that a large series of specimens necessarily supplement each other. Furthermore, the changes in many villi are so typical, both as to outward form and structure, as to be undoubted. Since many of the villi were decidedly degenerate, one could hardly expect to find much proliferation of the endothelium, but remarkable specimens, such as that in figure 9, were occasionally found. In some cases the presence of hydatiform degeneration became probable only through comparison of the villi in question with those found in many undoubted cases of hydatiform degeneration examined previously.

Two unusually fine specimens of hydatiform degeneration were transferred to this from group 2. No. 367 was a fine, clear, partly cystic specimen in which syncytial buds were invading the stroma of some of the villi. Although only vestiges of the vessels remain, the trophoblast is well preserved and syncytial buds are found on some of the trophoblastic nodules. The outlines of many villi are very sinuous and the epithelium is well preserved. In some respects this is one of the most unusual specimens I have found in the entire series, both of ectopic and uterine specimens. In the other specimen, No. 720, some of the implanted villi which remain show hydatiform degeneration, and many of them have fine, long syncytial buds. Although no vessels were seen in this specimen, the trophoblast nevertheless is abundant.

In the 5 cases above mentioned the presence of hydatiform degeneration was undoubted, and in 6 others its presence was highly probable, making 11 cases, or 26.2 per cent of the entire group. This is a somewhat lower incidence than in the uterine cases in this group, which was 37.5 per cent. Either the tube-wall or the contained clot gave evidence of the presence of infection in 8 of these 11 cases. If we exclude one case in which the tube was not included in the section, we get a percentage of infiltration of 80. Moreover, since only a few sections of each specimen were examined, and since the evidences of an old infection are not always easily detected in a markedly dilated and altered tube, it is not improbable that infiltration was present in more of these cases of hydatiform degeneration, as was the case in the uterine specimens. The existing infiltration was intense in one and slight in the other half, and since only one case not included among those showing hydatiform degeneration had an apparently normal tube, infiltration hence was almost constantly present also in the entire series of cases included in the group of the tubal specimens.

Although the alleged menstrual age ranged from 6 to 113 days, only a rough correspondence between it and the structure of the specimens was found to exist. The specimen with the longest duration contained only a few questionable degenerate syncytial remnants, and in No. 900*g*, which had a menstrual age of 69 days, no embryonic remnants whatever were found. No. 967*c*, which had a menstrual age of 70 to 100 days, contained only a few degenerate villi, although the same thing was true also in other instances with a much shorter duration.

Group 2. CHORION WITHOUT AMNION OR CYEMA.

A. Uterine.

The absence of the amnion in these specimens seems to be the result of destruction by lysis. However, absence of it in young specimens also might be due to failure of formation. The latter was the opinion of Giacomini (1888), who nevertheless believed that deformities of the amnion are rare. The only specimens in which the absence of the amnion could be ascribed to failure of development is No. 1843, donated to Stanford University by Dr. Falk, of Modesto, California. This is a very young specimen, however, and it is not impossible that a small cavity found in it represents the early amniotic cavity, as suggested by Meyer (1919*e*). Moreover, it may be doubted whether the human embryonic disk could develop far if formation of the amnion were inhibited. It is true that Panum (1860) and Dareste (1883) both reported cases of absence of the amnion in the chick and that Dareste emphasized that all the cephalic or the caudal portions may be absent. But since it is possible that the process of formation of the amnion is a totally different one in man, the direct application of these observations upon the chick to man is open to question. Panum and Dareste both believed that the anomalies of the amnion, observed by them in the chick, were secondary and the opinion of Giacomini was based largely upon the failure to secure absorption of the amnion experimentally in rabbits.

Specimens of human abortuses in which the amnion has undergone partial destruction are very common. Moreover, all degrees of destruction are represented in these cases, and since the cyema, too, is usually lacking, the assumption that absence of the amnion is due to failure of formation naturally would necessitate a similar conclusion regarding the embryo. This would leave one in the position of assuming that a chorionic vesicle which never had contained an embryo or amnion nevertheless might develop independently and attain some size.

Since the absence of the cyema in some of these vesicles is undoubtedly due to the mechanical injury incident to interference with a purely normal gestation, it follows that some of them were unquestionably normally developed chorionic vesicles and hence do not belong in the pathologic division. The difficulty lies in identifying them. Nevertheless, the structural characteristics of some are suggestive, even if not wholly unequivocal. In one instance, for example, in which a small nodule was seen upon opening an apparently intact ovum, this nodule was found to be composed of fragments of villi which could have been introduced into the chorionic vesicle only at the time of interference, or accidentally when it was opened in the laboratory. In another instance the chorionic vesicle contained foreign material when opened. Besides, the splendid preservation of the tissues of some specimens also shows that they were obtained in a practically normal, fresh, and unmacerated condition, which rarely is the case in any but instances of induced abortions, whether they be therapeutic, accidental, or criminal.

As already indicated, there is no hard and fast line of demarcation between the first three and later groups of the pathologic division. Indeed, it is not always

easy to determine, even histologically, whether or not cyemic remnants are present, for it is sometimes impossible to decide whether a small hyalin or webbed mass contained within the chorionic vesicle is or is not a remnant of the cyema itself. Then, too, some of the specimens included in this group contain clumps or small accumulations of erythroblasts, which probably had their source in the blood-vessels of the body of the embryo, although they may also have come from the vessels of the cord or of the chorionic membrane itself. In most instances these cells really are cyemic remnants, yet their presence has not excluded the specimens from this group of empty vesicles. Moreover, in another instance (No. 663), considerable remnants of the yolk-sac were found, although nothing could be positively identified as a remnant of either embryo or amnion. In other cases either of the last two structures or both may be represented by a very degenerate fragment, which is merely a so-called shadow or (better) gossamer form. Indeed, the entire chorionic vesicle is sometimes reduced to a mere gossamer form, as illustrated by No. 606 shown in figure 11.

From these things it is evident that group 2 nevertheless includes chorionic vesicles which contain free erythroblasts within their cavities or remnants of the yolk-sac and even of the amnion itself. However, since all specimens in the first three groups differ from each other only in the degree of destruction of the embryo and fetal membranes, this overlapping is a matter of no serious consequence for any except statistical deductions. Moreover, since the whole of a specimen is examined only seldom in a complete series, it follows that some of them will be classified incorrectly for this reason alone. No. 771*a*, for example, contains an undoubted remnant of the amnion, and hence belongs in the next group. No. 644 is composed of villi only, and therefore falls into group 1. Since No. 663 was found to contain numerous undoubted remnants of the yolk-sac, it is not at all unlikely that some embryonic masses which could not be identified certainly as such were nevertheless contained in this specimen, which would then be classified in group 4. This particular specimen is contained in a very degenerate hyalin abortus measuring 35 by 15 by 10 mm. The conceptus is composed of an extremely folded and almost structureless chorionic vesicle and of included and isolated cyemic remnants. As so often is the case, this abortus was much larger than the contained chorionic vesicle, which measured only about 5 by 3 mm. in section.

Hence, if Nos. 29, 664, and 771*a* are excluded from this group, only 40 uterine specimens remain, to which must be added three transferred from other groups. It is stated that in one case (No. 970) the specimen was obtained at autopsy, and in another (No. 865) at hysterectomy, and that in a third the abortion was induced.

In three instances (Nos. 71, 278, and 771*a*) it was stated that the patients had a chronic endometritis, and in one case (No. 865) the patient was said to suffer from "an old pelvic inflammation," but showed "no evidence of venereal disease." In two cases reported as having a chronic endometritis (Nos. 71 and 278) the clinical diagnosis was confirmed by microscopic examination. In the case in which an old pelvic inflammation but no venereal disease was said to have been present,

it was found that a severe endometritis with abscess formation was nevertheless indicated histologically. Only five cases (Nos. 661, 663, 753, 876, and 986) were reported as having no infection, but four of these contained evidence of the existence of an intense endometritis, accompanied in two instances (Nos. 876 and 986) by abscess formation. The specimen from the fifth case (No. 663) was so very necrotic that a positive diagnosis could not be made, but it is unlikely that a severe infection was present. Infiltration of the endometrium was present in 30 of the 48 cases, including 2 doubtful ones. This makes a percentage of 62.5, but since the decidua was not included in 20 cases, was too degenerate for study in 3 of the rest, and especially since only a relatively small portion of each abortus was examined microscopically, it is very probable that this percentage of evidence of infection, high as it is, nevertheless is entirely too low. Omitting the doubtful cases, the decidua was found infiltrated in 28 of 29 cases, or in 99.6 per cent. In 82.8 per cent of these the infiltration was marked. In 5 cases the infiltration of the endometrium was comparatively slight, but in 24 it was severe. In one case infection was found to be present within the chorionic vesicle, and although no decidua accompanied this specimen, it is unlikely that the infection was confined entirely to the vesicle. In 4 cases both the interior of the vesicle and the decidua undoubtedly were infected, and in 2 (Nos. 435*a* and 750) no decision could be reached.

Twenty specimens, or 41.6 per cent, were identified as showing hydatiform degeneration, 3 cases being doubtful and 2 others probable. In 15 of these cases in which the decidua was included it showed inflammatory changes. These changes were marked in 12 and slight in 3 cases.

Among the alleged causes of the termination of pregnancy in the cases not accounted for otherwise, we find that a fall was mentioned in case No. 71, in which evidences of chronic endometritis were present; anxiety is given as the proximate cause in No. 664, and fright in No. 883, both of which cases show the presence of an intense infection, which in one was so severe that the chorionic vesicle was destroyed almost completely. Two of the 3 abortions reported as having been spontaneous (Nos. 750 and 829) show the presence of a severe infection. In 4 instances in which the uterus was considered to be normal, evidence of infection was found in 2. In No. 883 it was found to be severe and in No. 978 it was mild. Although only one of these 39 specimens was said to have been induced, it is more than likely that this is true of more of them, although it seems exceedingly unlikely that an ovum could become implanted, and decidual formation actually progress in a normal way in so infiltrated and abnormal an endometrium as is present in many of these specimens. The anatomical condition of some of the chorionic vesicles among the non-infected group suggests that some of these abortions also were induced.

The histological changes found in this group differ in no essential respect from those present in group 1. Mall also found that the changes in the villi of the chorionic vesicle from an ovarian pregnancy (see No. 550 in the next group) showed

essentially the same changes as uterine specimens developing "under faulty implantation or infection." Maceration changes are present in all specimens, but vary extremely in degree. Coagulation necroses are absent, except in small areas, and beginning "infarct" formation was present only in portions showing especially severe infection. In the latter the destruction apparently had been very rapid and hence the degenerative changes differ somewhat from those produced by a low-grade chronic endometritis pre-existent to the implantation.

In most of the specimens, as noted by Mall, two forms of degeneration of the villi exist side by side, a fibrous and a "mucoid" transformation of the stroma. The former usually affects but few villi, the latter affects many. Sometimes the degenerate stroma, instead of being "mucoid," was finely granular. In some cases many villi show intense so-called granular hyperplasia. Blood-vessels were absent in both the chorionic membrane and the villi of many of the specimens, a fact which is especially significant in connection with the duration of the changes under consideration. In one instance (No. 596) many of the vessels were in the last stages of degeneration; another specimen showed the presence of numerous small abscesses between the epithelium and the stroma of the chorionic membrane. In those specimens in which the cavity of the chorionic vesicles had been infected, the chorionic membrane was not only decidedly thickened as a result of the loosening up of the fibrous tissue, but also was undergoing a very rapid destruction. In these instances it is not uncommon to find the infectious process invading the stroma of the villi from that of the chorionic membrane, but as long as the chorionic epithelium was found intact an extramural infection, no matter how severe, was never noticed to have caused an inflammatory reaction in the villi or in the chorionic membrane, not even in cases in which the latter was surrounded by a wall of polymorphonuclear leucocytes.

The content of these amnionless chorionic vesicles was usually a coagulum, which was generally amorphous or finely granular, but rarely also finely webbed or reticulated, reminding one of the "corps réticulé" of Velpeau (1855). The only histological elements which this magma contained were small fragments of or cells from the chorionic membrane and clumps of erythroblasts, composed either of individual or of coalescing cells, or the degeneration forms of these or of other embryonic cells. Some foreign materials and remnants of the yolk-sac rarely also were present, and fibrosis of the decidua, which is to be discussed separately, was quite common.

It was especially interesting that this group also contained specimens illustrating the process of intrauterine destruction and absorption of early conceptuses. In one specimen (No. 606) measuring 18 by 13 by 6 mm., all the tissues, even including the last or smallest remnant of the nuclei, had been destroyed completely. Not a single cell contour was preserved; not even by coagulum, as is frequently the case in non-degenerate deciduæ. Yet in spite of these things, the form and relative proportions of the entire vesicle, with its surrounding villi, were preserved so well that in describing the gross specimen, Mall noted: "In appearance the

specimen is normal," although under later microscopical examination he found it "difficult to make out any structure whatsoever. In fact, even the nuclei of the chorionic membrane have disappeared entirely, leaving only a fine reticular structure." One might say of this specimen, a photograph of some of the villi of which is shown in figure 11, that only an extremely finely textured, disordered web of hyalin material composes the apparently intact chorionic vesicle and the enveloping villi. What we really have here is a cast of the entire chorionic vesicle, including villi, which is formed by hyalin degeneration products that have preserved the form of the vesicle in every detail. From these things it is evident that only a little longer retention of this vesicle *in utero* would have sufficed to effect its complete disappearance. It does not therefore follow, however, that the disintegration products necessarily would have been completely absorbed. They might, to be sure, have been expelled, at least in part, with the decidua.

The finding of this specimen recalled a personal communication made to me by Professor Mall which suggests that a small cyema received some years ago probably was in a similar structural condition. This specimen was found apparently well-preserved and normal in form when the intact chorionic vesicle was opened in the laboratory, but had completely disintegrated a few moments later.

An exceedingly interesting specimen bearing upon this question of intrauterine destruction and absorption of conceptuses is one received from Dr. R. W. Hammack, of Manila. This specimen, No. 970, which was referred to in the preceding chapter, was found in the uterus at autopsy. The uterus contained some blood-clot, and the decidua was described by Mall as being "covered with hemorrhagic nodules measuring in general about 10 mm. in diameter. One of these, located medially, is larger than the rest, and a narrow block of tissue cut out of it and sectioned was found to contain part of an ovum. The ovum with its villi measures 3 by 5 mm. The cœlom is filled with a homogeneous substance, through which are scattered individual cells and also some strands of tissue from the chorionic membrane. The villi are about 0.5 mm. in length and covered with an active trophoblast. This layer of trophoblast ramifies into the adjacent tissue, is intermingled with a great deal of fibrinoid substance and cells, and penetrates the blood-sinuses. There are many buds of syncytium and considerable inflammatory reaction in the surrounding tissues. Towards the lumen, the ovum is covered with decidua reflexa, marked off with a layer of fibrinoid substance. The sections examined show no trace of an embryo." On account of the swollen condition of the chorionic membrane and the lack of sharpness of the mesenchyme, it is evident that pronounced degeneration of this conceptus has occurred. However, the internal limits of the chorionic membrane are well defined and the mesenchyme has become decidedly loosened, disordered, and degenerated. Groups of mesenchyme cells have wandered out into the magma, which contains cellular detritus also. The stroma of most of the villi is decidedly degenerate and in some cases is represented by a coagulum containing cellular remnants surrounded by necrotic epithelium. The syncytial islands are ill preserved and the trophoblast also is degenerate. The entire ovum

is surrounded by a decidedly hemorrhagic, degenerate, and inflammatory decidua and mucosa. Although some evidences of maceration seem to be present in the latter, they are relatively slight and can in no way account for the condition of the chorionic vesicle, the whole appearance of which suggests rapid degeneration. The extent of this degeneration is indicated by the entire absence of the cyema itself, by the appearance of the remaining tissues, and by the absence of remnants of the amnion and yolk-sac. All these things make it impossible that the embryo was well preserved up to the time of the death of the patient and the subsequent autopsy.

The presence of a severe infection in the endometrium naturally directs attention to the possibility of the destruction of the amnion and cyema of this specimen directly from this cause. However, since there is no infection of the cavity of the chorionic vesicle, such an assumption becomes untenable. Besides, the character of the changes in the chorionic vesicle itself makes it quite evident that this degeneration was produced by other conditions than a severe sudden infection. A low-grade endometritis may have been not only a contributory but the prime factor, but, in view of the severe hemorrhage which surrounds the vesicle and which must have produced rapid stasis and hence asphyxiation of the conceptus, it is unnecessary to assume any other contributory cause whatsoever; for, as No. 698 so well illustrates, hemorrhage alone, no matter what its cause, is entirely sufficient to effect the complete destruction of either embryo or vesicle, or of both. Nor is it necessary to assume that such a severe outpouring of blood from the tapped vessels in the uterine mucosa is necessarily or even probably pathologic. Indeed, it may be purely accidental and the result of a number of physical factors, none of which necessarily is related to diseases of either the ovum or the endometrium, or of the maternal organism as a whole.

A very interesting specimen belonging to this group is No. 1224, a portion of which is represented in figure 10. This specimen was received in an unopened uterus removed by hysterectomy for cervical myoma. The conceptus, which measures 36 by 25 by 13 mm., was collapsed, free in the uterus, and embedded in mucus. The only content of the chorionic vesicle was a dark-grayish coagulum which contained no remnant of the embryo or of the amnion. This amorphous magma included only a few isolated cells, yet in spite of this fact the trophoblast, which had markedly proliferated, was well preserved over large areas and many of the vessels in the chorionic membrane were filled completely with erythroblasts. A few degenerate masses of trophoblast and fused degenerate villi also were present. Some of the villi show evidences of maceration, others of mucoid hydatiform degeneration, as shown in figure 12, although they still may contain vessels. Some, however, are represented by a hyalin outline only. Both the stroma and the epithelium of many of the villi are well preserved, however, and the same thing holds for the chorionic membrane.

The decidua shows slight general and very marked local infiltration. Some remarkably dense periglandular and perivascular zones of infiltration are present.

The regenerated mucosa, too, is infiltrated and contains islands composed exclusively of round cells. In view of the condition of the decidua, the clinical observation of the presence of a weakly positive Wasserman reaction may have special significance. Besides maceration effects evident in the chorionic vesicle, many of the villi show changes undoubtedly hydatiform in character. It is decidedly unlikely that the cause of this intrauterine destruction, and probably also of the absorption of the embryo, is to be sought in the presence of the cervical myoma. Indeed, it is unlikely that the latter played any rôle other than that of obstruction of the cervical canal, and so furthered absorption of the conceptus. We have here, then, perhaps an evidence of the effect of endometritis upon the implanted ovum. Since the latter contained no evidence of violence, and since it was wholly unopened and noninfected, and above all, since the infiltration within the decidua suggested a chronic rather than an acute condition, such a conclusion would seem to be justified, although interference with the gestation can not be excluded absolutely.

The dimensions of the abortuses in this group (in many instances, at least) convey a very incorrect idea of the actual size of the conceptuses. This is due to the fact that the main bulk of the specimen often is blood-clot and decidua. Besides, chorionic vesicles which originally were recorded as having a certain diameter, later were recorded in three dimensions, because they appeared approximately spherical. In still other cases, such as No. 71, the chorionic vesicle is folded so extensively that accurate measurements are impossible. Then, too, the increase in size of the vesicles, in consequence of maceration and infection, also must be borne in mind in considering the true size of the normal specimen from which they may have arisen. Although the large dimensions of some of the abortuses suggest that their menstrual age is considerable, most of them really are relatively young. The longest menstrual age recorded for any of those among the first 1,000 specimens is 280 days. However, an inspection of the specimen with this age, as well as a microscopic examination of it, suggests that the menstrual history is not a reliable criterion, even if we assume, as suggested by Mall, that in this instance the chorionic vesicle grew somewhat after the death of the embryo. A comparison of the histologic picture in this specimen with that found in placentæ retained only approximately as long, shows a very marked contrast indeed, largely because of the absence of the inevitable age changes present in the latter.

B. Tubal.

Any lingering doubts as to the correctness of the conclusion that a very large percentage of the tubal specimens composed of villi only when received really belong in the class of hydatiform degenerations were dispelled quickly by the examination of this group. This is due largely to the fact that instead of isolated or detached villi in more or less advanced stages of degeneration and embedded completely in blood-clot, the preparations contain sections of whole chorionic vesicles, sometimes entirely free from blood. Some of them were implanted almost perfectly in the wall of the tube, and although many of them were folded extremely and collapsed more or less, small areas of several were nevertheless

implanted undisturbed. The villi in some of these implanted specimens were so characteristic, and the whole picture so exquisite, that these specimens rightly belong among the very finest instances of hydatiform degeneration found among all specimens, both tubal and uterine.

Many of the tubal specimens are remarkable indeed, and this is true in particular of a case of double-ovum twin pregnancy received from Dr. Cecil Vest. In this specimen the two chorionic vesicles, the intervillous spaces of which were devoid of blood, lay in almost the same transverse diameter of the tube, and hence had distended the latter considerably. Both were implanted quite well over the entire area of contact, which included the whole perimeter of the tube. The chorionic vesicles were flattened at the region of mutual contact, which divided the tube somewhat unequally, as shown in figure 13, one of the original drawings. Although the cyema and the amnion had long disintegrated completely, and although the chorionic membrane itself is thin, covered by degenerate epithelium and also disintegrating, the epithelium of the villi not only is well preserved, but is accompanied by large masses of trophoblast and considerable syncytium. Syncytial buds are found on the chorionic membrane also. The tubal mucosa is largely, and the tubal wall partly, destroyed by the invading trophoblast. Only a few small vestiges of the walls of the villous vessels remain, and the stroma of all of the villi has undergone changes characteristic of hydatiform degeneration. One villus also contains an epithelial cyst resulting from epithelial invagination with subsequent isolation of the distal extremity, a process to be referred to again in connection with the uterine specimens. Since most of these villi still are implanted in the tube, there no longer can be any question as to the conditions under which hydatiform changes in the stroma of the villi are inaugurated. As illustrated in previous instances in which isolated and small groups of villi were still implanted, the advent of degeneration of the stroma usually, if not always, occurs, in part at least, before the villus is detached. Hence it is not merely a maceration change.

As shown in section in figure 14, some exceedingly fine hydatiform villous trees were found among the specimens in this group. Scaffoldings or frameworks, formed by the proliferating sycytium arising from the epithelium of the chorionic membrane, were also seen. Since syncytial buds were found far out on proliferations of trophoblast which capped the villi, and also in the center of trophoblastic nodules, the origin of the syncytium from the Langhans layer would seem to be exceptionally well illustrated. In some cases a detached hydatiform villus was fastened to two portions of the tube-wall. It is well to remember, however, that these attachments may have been gained, and indeed probably were gained, before the separation of the particular villus from the chorionic vesicle.

In most of the cases of tubal specimens belonging to this group and not showing hydatiform change, the few isolated villi were so degenerate, or necrotic even, that no diagnosis of any kind would seem to be justified. In these instances the partly or wholly collapsed chorionic vesicle also was very degenerate and usually folded extremely, the folds radiating more or less from the unfolded portion of the

vesicle. Not rarely the apposed fibrous surfaces of these folds had been fused so intimately that they simulated villi very closely indeed and could easily be mistaken for them. Both isolated villi and chorionic vesicles were almost invariably embedded in blood-clot, and in some instances hyaline outlines only remained of the villi. Villi with a dense, fibrous, non-vascular stroma were seen in a few instances only, and they usually were found in the presence of severe infections.

Infiltrations of the tube-wall or of the clot were found in 20 (or 57.1 per cent) of the specimens in which it was cut, as compared with 93.3 per cent of infiltration of the deciduæ in the uterine series. Of the former, 65 per cent showed slight and 35 per cent marked infiltration. In by far the majority of cases the picture was that of a low-grade chronic, rather than of a severe acute infection. Moreover, in several instances the infiltration was so slight that one possibly might attribute it to the effect of the pregnancy itself. Chronic changes, especially in the mucosa of the tube, were quite common, however.

Of the 37 cases in this group, 17, or 46 per cent, showed the presence of undoubted hydatiform degeneration. In one additional case its existence was doubtful. Of these 17 cases of hydatiform degeneration, 12, or 70.6 per cent, came from tubes which were infiltrated. In 4, or 23.5 per cent, of these cases, the infiltration was marked, and in the rest it was slight. Although the incidence of infiltration is high, it is decidedly lower than in the corresponding uterine group, in which it was 100 per cent. The incidence of infiltration of the tube-wall or of the clot, usually sufficiently pronounced to be indicative of infection, was 70.6 per cent, as compared with 93.3 per cent in the corresponding uterine group. Nevertheless, the incidence of hydatiform degeneration was somewhat higher in the tubal cases, in which it was 46 per cent, as compared with the uterine, in which it was 40 per cent. Furthermore, the fact that many of these tubes showed the effects of chronic rather than of acute changes seems to suggest that the mere presence of an infection is not enough to cause the advent of hydatiform degeneration. These changes would seem to result rather from the modifications produced in the decidua and in the tube by the infectious process, and it is not unlikely that the greater incidence of hydatiform degeneration in the tube may, as already suggested, be due in part to the absence of a nidus comparable to the endometrium, for it is not unlikely that even a somewhat fibrous decidua may offer better conditions for implantation than a perfectly normal tube.

Some fibrous villi were found, and matting and gluing of the villi occasionally were present. Degenerative changes in the nuclei of the syncytium, up to and beyond the stage designated by Mall as "nuclear dust," were noticed in several specimens, which probably had been retained longer after isolation within the blood-clot so as to inaugurate calcification. Contrary to what one might assume, the length of the period of recurring hemorrhages is not a reliable guide to the condition of the villi. Indeed, one can not say even that the longer the duration the greater the degeneration and necrosis, for repeated hemorrhage apparently may and does occur as a result of only partial detachment of the chorionic vesicle.

However, if the latter is detached completely by the first hemorrhage, and if the salpingectomy is not performed until weeks later, the detached villi necessarily will be found necrotic, especially if they are embedded in a clot rather than bathed in fresh blood. In one case, with a history of recurrent hemorrhages during a period of 44 days, only a few necrotic, detached villi were found in the sections examined; and in a second case in which the period of hemorrhages had lasted 18 days, none but incipent changes were present in the vessels of the villi. The chorionic vesicle was ruptured in this, as in a number of other cases, a fact which probably may be attributable, in part, at least, to tubal peristalsis.

Group 3. CHORION WITH AMNION.

A. Uterine.

As stated in Chapter III, fetal vesicles without an embryo, except a few specimens filled completely with coagulum which might make the finding of an embryonic remnant difficult or impossible, never came to the attention of His (1882). Yet Müller (1847) had spoken of moles with a cord only or with a cord with a fringed or free end, and even of cords without a trace of an embryo. Such abortuses, according to Müller, usually are from the second and third months. The singularity of his experience was regarded by His as noteworthy, and he added that "one would *a priori* expect that an embryo which has died *in utero* would be dissolved completely at body temperature in the fluid in which it is contained, as certainly would seem to be the case *extra uterum.*"

Rokitansky (1842-1846) also believed that the embryo might disappear, for he wrote:

> "The entire fetus may be atrophic, the consequence of the cachectic state of the mother; but those cases are of greater importance which result from disease of the membranes, the placenta, and the cord; and, if occurring in the earliest period of embryonic life, may cause the embryo to disappear entirely, or so far as to leave but few traces."

Seiler (1832) also reported finding an empty ovum, and Robin (1854) called attention to a "rapport sur un cas de mort et de dissolution de l'embryon, par suite a'hemorrhagie des membranes de l'œuf," observed by M. Boussi and published by Robin in 1846. Hence it would seem that the experience of His was exceptional, although the report of Robin would indicate that specimens devoid of an embryo were regarded as rather rare.

It was emphasized by Müller (1847) that the amnion often is preserved in macerated ova. Not infrequently it is covered or even completely embedded in coagulum, as stated by Rokitansky (1861). Since, as Müller rightly emphasized, the amnion may be firmly adherent to the chorion, it is not always possible to tell by inspection of the gross specimen alone whether or not it is present. This difficulty is due also to the fact that the internal surface of the chorion is often exceedingly smooth and the chorion itself very thin. As stated further by Müller, the amnion may be torn, fused with the embryo or with the chorion, or be destroyed completely. As illustrated by several specimens in the next group, it may also

be detached completely from the chorion and bear only a small sessile embryo. Whether or not the amnion can be recognized in the gross specimen depends not alone upon age or upon whether it has fused with the chorion, but also upon the condition of the other content of the chorionic vesicle. If the contained fluid is a clear liquid of the character of the normal amniotic fluid, it is usually very easy to detect the amnion, but if the fluid is exceedingly turbid from degeneration products of the embryo and blood, the recognition of the amnion becomes much more difficult, especially if the latter is partly disintegrated. This difficulty is increased still further if the chorionic vesicle and the amnion are filled with a flocculent magma or with a dense, blood-tinged coagulum. The ease of recognition of the amnion depends also upon the degree of distension of the amnion itself. Nevertheless, even if it be distended and splendidly preserved, but fused together with the chorion, detection becomes possible only upon microscopic examination. Since fusion of the fibrous layers of both chorion and amnion in these abortuses is often so intimate that no line of demarcation can be detected between the two membranes even by means of the microscope, the presence of the amniotic epithelium remains the only criterion.

Very often, too, the amnion is not preserved in its entirety, but is represented by tags of membrane only. Whenever it is practically coextensive with, but not adherent to, the chorion it is easily recognized, because it is distended and also because of the presence of a narrow extra-amniotic or peri-amniotic space containing a clear fluid and some strands of "magma." Rarely, the amnion has collapsed completely and lies in folds forming small masses which it is not always possible to distinguish from small cyemic or cordal remnants by inspection alone.

Since, as His (1882) stated, the amnion is folded closely around embryos 1 cm. in length, remains only a few millimeters distant when an embryonic length of 15 mm. is reached, and is coextensive with the chorionic cavity at a length of about 25 mm., the ease of its recognition depends also upon the age of the particular specimen, although its relative size is subject to considerable variation. Moreover, in the case of very young conceptuses, a further difficulty in identification by the unaided eye is introduced through the presence of a thin, distended yolk-sac.

Although the amnion is an exceedingly delicate membrane, it is undoubtedly true, as stated by Müller, that it may be preserved, for a considerable period after the death of the embryo, in conceptuses of not altogether too early an age. Nevertheless, its destruction no doubt is much more rapid before it is fused with the chorion. This is true particularly in case of intrachorionic infections which quickly lead to disintegration of the amnion if they occur in the period before fusion with the chorion has occurred; after this period, on the contrary, the amniotic epithelium, unless degenerate, seems to act as a formidable barrier to the passage of the infection into the chorionic membrane, in the same manner as does the chorionic epithelium in cases of extramural infection. If the chorionic vesicle is infected previous to the fusion of the fetal membranes, the infection can easily enter the stroma of both the amniotic and chorionic membranes and destroy them, especially the amnion, in a relatively short time, thus leaving villi only.

That a severe endometritis might not result in thickening by fibrous proliferation of the fetal membranes is well illustrated by No. 922, in which both membranes were extremely thin, especially as compared to their size, although the infection of the endometrium was severe.

The resistance to infection, especially, perhaps, of young conceptuses, seems very striking and recalls the experimental work of Maffuci (1894), but the apparent failure of the tissues of young conceptuses to react toward infection as do the tissues of the maternal organism is still more striking. However, this apparent absence of defensive proliferative reactions on the part of embryonic tissues may be due partly to the immaturity and the inadequately differentiated nature of some of the tissues.

In two specimens included in this group (Nos. 651*e* and 682), Mall found remnants of the yolk-sac and the cord respectively; and in No. 645 also an epithelium-lined cavity in the chorionic membrane, probably allantoic in origin. The presence of these structures did not, however, affect the classification of the respective chorionic vesicles. Nevertheless, these observations are interesting because, like other similar observations previously mentioned, they indicate that the yolk-sac and a portion of the cord or the allantoic stalk may persist even after the destruction of the amnion and embryo has become complete. That the embryo and amnion disintegrate relatively easily was emphasized also by Mall (1908).

The amniotic conditions in some of the specimens of this group *seem* to imply a growth of the chorionic vesicle after the death of both embryo and amnion. Since the early amnion is related very intimately to the embryo, and since its growth probably is very largely dependent upon the maintenance of the normal composition of the amniotic fluid, a slightly continued growth of the chorion would seem to be not improbable. But since the composition of the amniotic fluid must change soon after the death of the embryo, it is probable that such an exceedingly delicate and non-vascular structure as the amnion can not long survive. None of these things is true, however, of the chorion, which often retains its connection with its nutritive supply through the fastening villi, and hence is not seriously affected at once by the degenerative changes within the contained vessels. Instances in which the amniotic vesicle is only a fraction—say one-fifth or even one-eighth—as large as the chorionic vesicle, are not very rare, and others in which, at the time of abortion, the relative proportions of these membranes are wholly unlike the normal, are not uncommon. In one instance, for example (No. 1962), which came under my direct observation, the dimensions of the chorionic vesicle were 61 by 44 by 34 mm., but the largest diameter of the slightly collapsed amnion was only 19 mm. In this case the peri-amniotic and intra-amniotic fluids were entirely normal in gross appearance and contained no suspended matter whatever. The embryo was detached but intact and was represented by a small irregular nodule 3.5 mm. long. From this it will be seen that although the amnion was relatively too large for the embryo, it nevertheless was too small for the chorion. That the small size of the amnion was not due to retraction seems to be indicated by the absence of any thickening in its walls. Indeed, the latter were entirely transparent,

so that the whole amniotic cavity could be carefully inspected without opening the vesicle. In view of these facts, no other explanation for the abnormal proportions between the two vesicles seems possible than the assumption of the growth of the chorionic vesicle after the death of the embryo and amnion. It also is possible that both embryo and amnion may have been retarded and the chorion accelerated in its growth, but the great disproportion between the embryo and amnion makes even this assumption, as sole cause of the disproportion, rather improbable.

It is not at all surprising that the idea that the fetal membranes can continue to grow independently after the death of the embryo was once quite generally held, for the disproportion between the size of the membranes and that of the contained embryo is often very striking. Seiler (1832) also stated that the embryos in aborted ova usually are too small. In most of the cases the disproportions may be due largely or wholly to the existence of a genuine or of a pseudohydramnios, but in others this apparently is not the case. The fact that the yolk-sac, too, may be entirely too large in comparison with the embryonic disk also seems to suggest that it, too, is somewhat independent in its development, and since the amnion usually is non-vascular, it is not at all unlikely that its growth is not inhibited immediately after the death of the embryo. Yet such growth probably could not be long continued before the amnion is fused with the chorion, for with death of the embryo and consequent change in composition of the amniotic fluid further growth probably would become difficult. But after fusion of the amnion with the chorion, the former obtains a more or less independent source of nutrition and consequently is affected less by a change in composition of the amniotic fluid. That the chorion may remain well implanted some time after the death of the embryo can not be doubted, and although cessation of the fetal circulation probably would seriously interfere with its proper nutrition, this interference would not necessarily prevent some growth on its part. This would be true especially of early conceptuses in which the circulation had not as yet been long established. However, that the chorion can undergo considerable independent development is open to grave doubts, and it may be recalled that it used to be held quite generally that the placenta also grew after the death of the fetus. Schickele (1907) also doubted the occurrence of growth of the chorion after the death of the embryo.

Most of the specimens in this, as those in the two previous groups, are small. This becomes evident especially if it is recalled that, as stated in the previous chapter, the main bulk of these abortuses often is due to blood-clot, decidua, and even to the products of inflammation. This is splendidly illustrated by No. 77, which measured 70 by 40 by 30 mm., although the contained chorionic vesicle was only about 22 mm. large. Similar instances are Nos. 408 and 564.

The same pathologic conditions which were present in group 2 recur here with somewhat the same frequency. In the case of No. 813 the chorionic cavity, which measured 70 by 25 mm., had an extremely thickened wall, which, in connection with other changes present, suggested changes produced by lues, although the history carried the comment "No venereal disease." This specimen contains

evidences of the presence of an old inflammatory condition also, and in spite of the small size of the conceptus has a menstrual age of 200 days. Since the coalesced fetal membranes are extremely thick—indeed, the thickest of any specimens of this size that came to my attention—one might assume that the chorionic vesicle probably grew after the death of the embryo. That some growth occurred is not at all impossible, but it does not seem likely that this growth was considerable. The decidua is very necrotic and a considerable number of inflammatory areas are present. Consequently, it seems more likely that the fibrosis of the membranes and of some of the villi is the result of other things than retention only. As is well known, extremely long retention of the dead conceptus has long been regarded as very common in lues. This specimen is interesting also because if the fetus had been present, no matter in how macerated or mummified a condition, the conceptus, instead of falling into this group, would have been classified in group 7. The same thing is true no doubt of other specimens also, and seems to suggest that an attempted classification on an etiological basis may throw more light on the genesis of the various morphological types here described, even if it would be largely tentative.

Of the 44 specimens out of the first 1,200 accessions which fall into this group, 24, or 54.5 per cent, showed evidences of infiltration. But, since the decidua often was not included in the sections, and generally also not in the respective gross specimen, these percentages can not represent the true state of affairs. It is true that the same thing may be said if the incidence of infection, as indicated by infiltration, is determined upon the basis of those cases only in which the decidua is present, for all cases in which the chorionic vesicle, unaccompanied by decidua, contains evidences of infection are then excluded. Nevertheless, that the decidua in all such specimens, if present, would be found infiltrated can scarcely be doubted, for all these chorionic vesicles are small. If we take the 54.5 per cent of the cases in which the decidua was present and not too degenerate, we find that 100 per cent of them showed infiltration. In 16 of these specimens, or 66.6 per cent, the infiltration was marked, and in 8, or 33.3 per cent, it was slight. The sections of one specimen showed no evidences of infiltration, and in a second specimen the decidua was too degenerate. In 7 instances, Nos. 408, 468, 922, 771*a*, 814, 960*a*, and 985, of those suggesting infection, its presence was noted in the history. One of these was a case of peritonitis; another, that of an old gonorrhea with salpingitis; two of leucorrhea, one since girlhood; two of endometritis; and one of gonorrhea and syphilis. In three cases, Nos. 159, 813, and 976, the infiltration was severe locally and may have been both luetic and pyogenic in character. In one of the cases of probable lues the presence of this disease was suspected by the physician, and although a Wasserman test was found negative, changes suggestive of lues were present in the chorionic vesicle.

Fifteen of the cases, or 34 per cent, showed the presence of undoubted hydatiform degeneration. In some of these cases the change apparently was incipient, and in 3 cases not included in the 14 no definite conclusion could be

reached; 2 of them, Nos. 651*d* and 652*e*, were received at the same time from the same physician, Dr. G. C. McCormick, Sparrows Point, Maryland. Other similar specimens were also received from Dr. McCormick. In one of these specimens, No. 651*e*, a remnant of the yolk-sac still was present. Since all these specimens of hydatiform degeneration will be discussed separately, no further comment is necessary here, except to add that in every case the microscopic findings were confirmed by an examination, by means of the binocular microscope, of portions or the entire gross specimen itself. The changes in the decidua will be discussed in greater detail separately, and aside from what has already been stated, it suffices here to say that, in addition to the other changes, fibrosis of the decidua was noticed in a large percentage of the specimens.

B. Tubal.

Of the 3 tubal specimens remaining in this group little can or need be said. The walls of the tubes were infiltrated, the mucosa showed inflammatory changes, and the clots were infected in two specimens. Nothing was left but a few non-vascular, fibrous, and necrotic villi. In one specimen the chorionic membrane was thickened somewhat and densely fibrous. The epithelium, syncytium, and trophoblast of some villi also were degenerate, and the villi themselves somewhat matted. Until the larger series of cases contained in the rest of the collection and falling into this group can be studied, a comparison of these few with the corresponding uterine group can be of no value.

Group 4. CHORIONIC VESICLES WITH NODULAR CYEMATA.

A. Uterine.

Panum believed that certain small nodules, which he called *monstruositates amorphoides*, resulted from pathologic changes in the original form of the embryos, which changes converted them into more or less compact, rounded masses. He further believed that even older chick embryos could become transformed into amorphous masses and represented some of these; also, that these changes in form arose during the life of the embryos and were to be explained by regression of the organs and fusion with neighboring ones, as a result of disturbances in nutrition.

Giacomini (1889) stated that, although he could produce atrophic embryo forms in the rabbit by the use of experimental methods similar to those described by him in man, he did not regard these forms in man and in the rabbit as wholly comparable.

His (1891) stated that he found 5 nodular embryos in 45 cases. This is an incidence of 11.1 per cent, but Mall (1917[c]) found 51 nodular specimens among 396 pathologic, or a percentage of 12.9 per cent. In view of His's small series, it is striking that these percentages are so nearly alike, and it might seem that nodular forms occur with considerable constancy.

Giacomini (1894) claimed to have studied the first nodular specimens microscopically in 1893, and stated that the nodular forms have not been studied much because they are more difficult to understand. Giacomini, who stated that atrophic forms occur chiefly in the tubes and in peritoneal implantations, apparently used

the term *nodular* as synonymous with *amorphous*, for he characterized nodular embryos as "specimens in which no organs are visible." Furthermore, he believed that nodular specimens are without a cord.

With the exception of a portion of a full-term specimen which we owe to the generosity of Dr. Morris Slemons (No. 1682, fig. 15) and which was described by him in 1917, none of those in this group measures over 5 mm. in length. Indeed it is unlikely that any other specimen strictly belonging here exceeds a length of 4 mm. Consequently, all embryos from among the first 1,000 accessions which unquestionably are nodular in character have a maximum length of less than 4 mm. But this group is distinguished not only by the small size of the embryos, for that might imply that they merely are very young. The latter is the case, but their menstrual ages nevertheless are much greater than their size would indicate; nor are they all in any sense immature, normally developed embryos which merely have been universally and equally retarded in their growth. They undoubtedly have been retarded, but this retardation has been decidedly unequal. Moreover, they not only have been stopped in a very early stage of development, but they had not reached that stage in a wholly normal way.

Although one would not suspect it from external appearances alone, this group of the pathologic is by far the most interesting. Some of these specimens show an astonishing simplicity in form and structure. Perhaps it was this fact which caused His (1891) to doubt whether they really were remnants of the whole embryo. His query is justified by the form and microscopic structure of many of them, as is so well illustrated by Nos. 2288, 1369, and 651*g*, shown in figures 16, 17, 18.

Next to the small size of the cyemata in these abortuses, the disproportion between their size and that of the chorionic vesicles in which they are contained is what attracts one's attention. This lack of correspondence is so great that the chorionic vesicle may be not only 10 or 20, but even 50, 60, or 70 times as large as the cyema; nor should the occurrence of such disproportions be surprising, for if the cyema can wholly vanish it stands to reason that infinite disproportions must occur as it becomes smaller and smaller in size, to finally disappear altogether. For, even if the body of the cyema eventually were to disappear by solution, it would still be true that its development could be checked at any time between the appearance of the first rudiment and the completion of growth at the time of birth. A similar disproportion in size not infrequently exists between the amnion and cyema. The amnion not infrequently is entirely too large for the embryo, but nevertheless much smaller than the chorion. Hence it seems that the amnion, too, must have considerable power of independent growth in spite of the absence of vessels in its walls. In some instances it was found to contain blood-vessels, however, and in several cases large cyst-like dilatations were present, some of which may have been the result of fusion of portions of the adjacent walls.

The body is by no means the most resistant of the strictly cyemic structures, however. The umbilical vesicle or the cord, or indeed the allantoic stalk of the amnion, may survive it. Such cases do not belong in this group, but since it is

impossible to recognize the true nature of a small nodule upon gross inspection alone, it is often impossible to make a correct classification except by careful microscopic examination of the stained sections. Consequently, some of these doubtful specimens are bound to get into the wrong category, for they must be classified when received, and largely upon the basis of inspection by the unaided eye and slight magnification with the hand-lens or the binocular microscope. Hence, it was later found that 13 of the specimens placed in this group do not belong here. None of these 13 specimens contained a cyema, and in the case of 2 others a decision was impossible, even upon microscopic examination of stained sections of the specimens.

Although some of these small nodular cyemata measure but a few millimeters in length, they nevertheless should show considerable differentiation had they undergone normal development. This, however, is not the case, for some of them are composed simply of undifferentiated mesenchyme, with or without a cavity, and a slightly differentiated outer layer. None of them have even approximated the differentiation of a normal specimen of the same size, wholly regardless of age. In certain cases the rudiments of some of the organs can be recognized, but others have undergone partial or complete dissociation, making recognition of individual organs impossible. Usually a somewhat undifferentiated portion can be recognized as belonging to the central nervous sustem; the cœlom is frequently indicated, and some myotomes; liver and heart tissue can be detected. Nevertheless, most of them are small sessile nodules showing little differentiation. In some instances these nodules are composed of one kind of tissue only, usually mesenchyme, wholly uncovered by what could be spoken of as either ectoderm or epidermis. In others, however, epidermis is present, and the specimens containing heart and liver tissues are those which border upon the next group.

Although 4 or 5 mm. long, these nodules generally show less differentiation than a normal specimen of the length of 2 or 2.5 mm. As is well known since the description of a 4.5 mm. embryo by His, specimens of this length should show considerable development of the central nervous system with differentiation into its various main divisions. The eye and ear should have begun to form, and the maxillary and mandibular processes should be present. The dorsal segmentation also should be very evident, and the differentiation of the circulatory, urogenital, and digestive systems should be considerable. That the cyemata in the nodular group fall behind the stage of development reached by normal specimens of corresponding length quickly becomes evident, even upon cursory examination. Not rarely the amnion upon which these small nodules are sessile has become detached from the chorion. In two cases the latter was absent altogether, but its absence must undoubtedly be attributed to mechanical causes.

The histologic condition of some of these small specimens is well characterized by the term "dissociation," introduced by Mall. Phisalix (1890) also spoke of the tissues of some of the embryos being "*desagregre.*" As I understand this term, it refers to the disorderly mingling of the tissues which belong to different organs, so that the outlines of these organs no longer can be distinguished. This

implies that such cyemata had once reached a higher stage of development, and that they then underwent retrogressive changes. However, this does not necessarily imply that the tissues composing the different organs have migrated out actively, mingling with each other after the manner of cells in tissue cultures. In the case of dissociation, as implied above, the disorganization of the cyema has been a passive rather than an active process, occurring during and being incidental to the process of maceration and disintegration. When the dissociation is at all marked, sections of specimens, when examined microscopically, are rather uniform cytologically.

The decidua was included in only 23, or 37.1 per cent, of the specimens belonging in this group, and infiltrated in all of these; 69.5 per cent were listed as marked infiltrations and 31.5 per cent as mild. Although these percentages are practically the same as in the preceding group, the infiltration is milder. In the former group severe infections predominated and abscess formation was relatively common. In this group, on the contrary, the infection, as judged by the character of the infiltration present in the decidua, was milder in all save a few cases which plainly suggest mechanical interference with the gestation. This may be one reason why the cyemata, though rudimentary, nevertheless are present. All of the cases of infection, except these, could, I believe, be designated quite correctly by the term *chronic endometritis.* I came to this conclusion largely from a study and comparison of those specimens in which the presence of a chronic endometritis had been diagnosed clinically. Indeed, it is quite inconceivable that such an inhibition of normal growth as existed in the nodular embryos could possibly occur in the presence of a sudden severe infection. The latter could destroy only portions of a normally developed cyema, for it would quickly die.

The homocytic nature of some of these specimens also impressed Giacomini (1888), who spoke of a lymphoid transformation of the embryo. In 1894 Giacomini also spoke of a "uniformity of the elements which are like lymphoid cells so that one might think at sight that one dealt with a lymph follicle." Giacomini found this lymphoid transformation both local and general and stated that the elements which composed the organs in a case observed by him were transformed into round cells. However, he did not regard this transformation as wholly passive, for he, like His, believed in post-mortem cell proliferation. While emphasizing that a microscopic examination is indispensable for an understanding of abortive forms of embryos, His (1891) added that we are not far wrong if we speak of certain small accumulations of pycnotic cells found in abortive forms as a "Brut von Wanderzellen." Although His described dissociated specimens and regarded an invasion of abortive forms by round cells as undoubted, he nevertheless stated that, although not all cells may be dead, one can not regard abortive forms of embryos as living.

In later years Mall used the term *dissociation* in another sense, and apparently also felt that more or less independent and continued development might take place after the death of the embryo, much after the fashion of a tissue culture *in vitro.*

One of the most interesting of these nodular embryos is No. 788*b*, received from Dr. Anfin Egdahl, shown in figure 19. This is one of double-ovum twins in which the chorionic vesicles were wholly distinct. The smaller of the twins is but 2 mm. long, with a greatest diameter of about the same dimension. The mate, on the contrary, is relatively a normally formed, somewhat stunted fetus, with a crown-rump length of 17 mm. The abortus containing the chorionic vesicle with the little nodule was somewhat larger than the one containing the fetus, although both chorionic vesicles were covered by approximately the same quantity of decidua. The dimensions of the chorionic vesicle belonging to the stunted embryo were 60 by 45 by 40 mm., and those of the one containing the nodular embryo 65 by 55 by 40 mm. The greater size of the latter was due probably to the greater distension of the chorionic membranes, which are thinner and possess only poorly developed villi. The other vesicle, on the contrary, shows very definite placental development, although one of its dimensions actually was smaller than the corresponding dimension of the chorionic vesicle belonging to the small nodule. Both specimens evidently were very decidedly macerated when aborted.

As shown in figure 20, this small nodule contains a large cavity lined by epithelium, within which there is a large mass of cells, probably erythroblasts. The exterior is covered by ectoderm, and the wall, which varies greatly in thickness, is composed largely of mesenchyme containing blood-cells, particularly erythroblasts, some of which lie in exceedingly thin-walled vessels. In the thickest region a degenerate rudiment of the central nervous system and a mass of somewhat differentiated cells, which may be rudimentary myotomes, are indicated. At one point on the periphery there is also a small, round knob, which looks like the remnant of the cord, and at another point a small, denser, and more differentiated protuberance which may be an early limb-bud. The caudal and cephalic extremities can not be differentiated even with the microscope.

The other fetus, shown in figure 21, which is to be described in group 6, is a relatively well-formed specimen of 27 somites. It is somewhat atrophic and the head adheres to the chest, but in development it is far in advance of its nodular mate. Since the latter measures only 2 mm., it is evident that the respective chorionic vesicle is much too large, and since it is wholly inconceivable that this small nodule could ever have reached, even approximately, the stage of development represented by its mate, it would seem that the accompanying chorionic vesicle must have continued to grow some time after the death of the small embryo which never reached any special differentiation. Furthermore, since there is no very evident difference in the degree of the degeneration of the chorionic vesicles, it is not unlikely that the one containing the minute nodule survived almost as long as the other. The villi and membranes of both are non-vascular and the stroma clear, suggesting hydatiform degeneration.

The decidua is well preserved but infiltrated. However, a severe infection could not cause a gradual inhibition of growth. A mild process, on the other hand, can conceivably exert a general inhibition over a considerable period of time, and thus possibly lead to all the changes, remarkable though they be, which

are found in these specimens. However, it is necessary to bear in mind that such errors in development as are here described need not necessarily be the product of the environment in which the conceptus finds itself, but may in fact be changes or abnormalities which resulted from defects inherent in the spermatozoa, in the unfertilized ovum, or in the fertilized ovum even. However, in order not to interrupt the description of this group, a consideration of this question is postponed until all the groups have been considered.

Although the nodular embryos themselves are so very abnormal in form and structure, there was very little indeed in the outward form and gross appearance of the corresponding chorionic vesicles to prompt special comment at the time of the first description. Sometimes it was noted that the villi were unusually long and thread-like, or that they were absent over considerable areas; but nothing else attracted attention as a rule. Some of the chorionic vesicles are translucent, but this is true also of many in other groups. Upon closer examination, however, the presence of numerous "*appendici durate*" can be determined in many specimens, and upon magnification of about 11 diameters with the binocular it was found that a very surprising number of chorionic vesicles included in this group showed the presence of a very marked and wholly typical hydatiform degeneration of the villi. In many instances the appearance of these villi is an exceptionally artistic one. The characteristic vesicles can be seen in all degrees of development, even when they were too small to have attracted attention upon inspection of the gross specimen with the unaided eye. Indeed, it was not until my attention was directed especially to the possible meaning of certain forms of degeneration so frequently seen and usually referred to as "hyaline" or "mucoid" in the protocols, that the relationship between the two was established. These degenerations, and especially the absence of vessels in most of the specimens examined, had also attracted my attention earlier in the year, while engaged with a study of Hofbauer cells in abortuses.

Under microscopic examination it was found that the most constant and interesting change in the stroma of the villi in this group of nodular cyemata is the occurrence of hydatiform degeneration which is present in 29 per cent, including two doubtful cases. In order not to confuse matters, it is necessary to add that the term is being used in its literal meaning, entirely aside from any clinical implications. As a rule, the stroma of these villi tends to become clear or is clear, or is even replaced completely by a clear fluid. This change is usually designated as a hyaline or mucoid degeneration in the protocols, and sometimes also as fibrous degeneration. As emphasized by Mall, the use of the word "mucoid" does not imply that the material is mucous, although Mall noticed that it frequently stains blue with hematoxylin. As is well known, however, true mucin nevertheless has been found in small amounts in the fluid contained in the vesicles of hydatiform moles.

In the early stages of hydatiform degeneration the stroma of the villi may still contain remnants of blood-vessels, but usually these are completely absent. In these or somewhat later stages the nuclei are pycnotic and may be quite well

preserved long after cell outlines can no longer be recognized. Later they become very irregular and finally disappear completely, leaving only a glassy substance which fills the otherwise well-preserved epithelial shell. The latter usually stands out in marked contrast to the degenerated stroma. The epithelium not only is well preserved, but the syncytium is often absent and the trophoblast shows signs of marked activity. Usually it is increased in amount and "*appendici durate*" are relatively common.

During the process of this degeneration even the very young villi become swollen, so that their unusual caliber, and also the great variation in size of different portions of the same villus and of different villi at once attract attention. The walls are often smooth, buds are absent, and the villi are sparse though long.

Since none of the specimens of this group had been designated specifically as hydatiform moles, and especially since an inspection of the gross specimens did not confirm the existence of what currently passes for hydatiform or cystic degeneration of the chorion, the contrast between the microscopic and gross pictures was at first puzzling. However, under low magnification with the binoculars (about 4 to 20 times), every one of the specimens which was found to show the characteristic changes in the villi under higher magnification was also found to contain villi or groups of villi, the form of which was typical of hydatiform moles. In some instances it was necessary to remove a small group of villi and carefully separate them by teasing before the typical gross changes could be observed. In other instances in which a severe infection apparently had supervened upon the hydatiform degeneration, or in which the villi were glued for other reasons, no good preparations could be made by this means. However, it was found that an examination of the cut surfaces of the chorionic vesicles, especially when embedded in celloidin, under similar magnification would always easily reveal the presence of this degeneration. In one specimen, for example, which was obtained by hysterectomy, the chorionic vesicle was still embedded within the uterus and the implantation cavity extended around the greater portion of its periphery. The microscopic examination of a section from this uterus showed the presence of the characteristic degenerations, and upon examination numerous groups of typical vesicles could be seen lying in the cut surface of the densely matted villi. In view of these facts, I can no longer entertain any serious doubt as to the nature of these changes. It stands to reason, however, that the very incipient histologic changes undoubtedly could not be verified by gross examination, for neither the structure, the optical properties, nor the form of the villi in such specimens would have changed sufficiently from the normal to become evident under low magnification.

B. Tubal.

Since two of the four specimens originally placed in this group belong in groups 1 and 2 respectively, only two remain here. The tube of one was not included in the sections, but the walls of the other tube were infiltrated and the villi exemplified a fine case of hydatiform degeneration in its early stages. Some of them which were still implanted evidently were being detached by the hemorrhage, and both

the fragment of the embryo and the torn chorionic vesicle were being extruded from the tube, for they lay some distance distal to the site of implantation. No remnant of a cyema, definitely recognizable as such, remained in No. 342, but a small conical mound of cells, located at the distal extremity of the cord, nevertheless may have been a remnant of it. The few sections of a portion of the cyema found in No. 874 suggest that the development of this specimen apparently had not been changed greatly.

Group 5. CYLINDRICAL CYEMATA.

A. Uterine.

The cylindrical specimens forming this group comprised 7.5 per cent of the first 1,200 accessions or 18.9 per cent of the pathologic. Hence the frequency of the cylindrical cyemata is far greater than that of the nodular, although it must be remembered that the group of cylindrical contains some specimens which are not embryos at all, but merely remnants of the cord.

As already stated, this group is not separated from the preceding or succeeding group by any definite division. Transition forms could easily be found. However, since the limb-buds begin to appear at a length from 4 to 5 mm., it is evident that the specimens in this group also must be small, for as soon as limb-buds have fairly developed an age is reached in which stunting becomes evident and the specimen then falls into the next group. The inference is not that stunting becomes evident in the extremities only, but that it is quite easy to recognize it here with the unaided eye. Not all the specimens of this group are less than 4 or 5 mm. in length, however; for even when they are exceedingly atrophic or when miniature limb-buds are present, it is sometimes impossible to distinguish the cephalic from the caudal extremity in the presence of an atrophic cephalic region. Consequently, some specimens rightfully belonging in the next group remain among the cylindrical; and since the classification is determined very largely by gross appearances, portions of the umbilical cord also are frequently classed in this group. On many of these not a remnant of the cyema can be found, even upon microscopic examination. But since the absence of remnants of the body of the cyema may be due solely to mechanical interference, it follows that some specimens of wholly normal conceptuses become included in this group.

The largest cyema is No. 710, which has a length of 13 mm. The next is No. 288*a*, which is 11 mm. long. Both of these fetuses are macerated and the organs are greatly dissociated. Had they been better preserved, stunting could have been recognized and they would undoubtedly have been classed in the next group. These considerations, and the further fact that extremities were present, seem to suggest that the causes which contribute to the death of these cyemata apparently do not wholly prevent the development of the extremities or retard their growth appreciably beyond the retardation felt in other parts of the body. This conclusion does not imply, however, that the changes produced in the external form and structure of cylindrical cyemata may not have been pronounced. A reference to figures 22 to 28 will show that this is the case. To what extent

such changes in form as there represented may be the result of maceration alone will be considered in a later chapter.

That lysis of the entire conceptus, even including cyemata belonging in this group, may become complete is indicated by such a specimen as No. 2197, shown in figure 29. The cyema of this specimen not only has become markedly modified in external form, but upon microscopic examination is composed of nothing but a web containing remnants of nuclei, the whole forming a perfectly homogeneous mass. In view of this fact, the external form of this specimen really was remarkably preserved.

An interesting specimen belonging in this group is No. 587, represented in figures 30 and 31. While studying this specimen attention was attracted by the small cavity in the wall of the main chorionic vesicle, which contained the cylindrical cyema. Upon further examination it became evident that this smaller cavity was surrounded by a degenerate chorionic membrane which was not a diverticulum of the main vesicle, and that in fact we were dealing with a twin pregnancy similar to No. 1840, to be referred to later. The larger of these two chorionic vesicles, in the villi of which the smaller is contained, measures 58 by 38 by 29 mm., but the smaller measured only 9 by 6.5 mm. in the fixed condition. The latter contained no trace of the cyema at the time of examination, and the very degenerate condition of the chorionic wall, and especially of the amnion, makes it decidedly unlikely that the small though not necessarily rudimentary cyema which it may have contained earlier in its history was lost before it came to my attention. The photograph of the portion of this abortus shown in figure 31 suggests, and an examination of the gross specimen confirms, the surmise that the smaller vesicle was located at the point indicated by the leader in figure 30, the photograph originally taken of the specimen, which shows the presence of the cylindrical cyema. Since a degenerate decidua still separates the villi of the respective vesicles in the area of most intimate contact, it is evident that the larger vesicle must have captured the smaller, as it were, by surrounding it. It thus probably hastened its strangulation and death, which may, however, have been fully assured by the existence of an inflammatory decidua. The only content of the smaller chorionic vesicle is coagulum (magma) with some faint traces of the amnion in the form of coagulum. The villi of the smaller specimen are almost completely degenerate, and the stroma of the villi of the larger, which is non-vascular, has undergone mucoid degeneration.

From what has been said, it is evident that we have here not an evidence of superfetation but double-ovum twins, one of which survived for a considerable period beyond the time of death of the other. Moreover, although both ova may have begun their uterine development equally well, the smaller must soon have been throttled or surrounded by the larger. Or the smaller, perchance, may have become implanted in a more unfavorable portion of the decidua and therefore have succumbed earlier. Since it is wholly unlikely that any portion of the cyema was preserved in the smaller vesicle, this specimen becomes classified in group 3 or 2, accordingly as we do or do not recognize a trace of the amnion in the fine line of coagulum which extends along the interior of the chorionic membrane. The

larger, on the other hand, falls into *this* group. It may be recalled that a similar instance of twins falling into different groups was mentioned in the discussion of group 4, and two more instances will be mentioned in the succeeding group.

The disproportion between the size of the cyemata and that of the chorionic vesicle, though pronounced, is not so great in this as in the preceding group. What was said there regarding the relation of the dimensions of the abortus to those of the chorionic vesicle applies here also. As all the specimens of this group contain cyemata varying from 2.5 to 13 mm., it is evident that the amnion must have developed considerably in some of them. Subsequent retrogression of the cyema or hydramnios, then, left the amnion proportionately too large as compared with the cyema, for (so far as I am able to see) there is little retrogression in the size of the amnion, even when that of the cyema is considerable or total. The amnion generally was relatively too large, although rarely it was folded about the cyema very intimately. When large it frequently was greatly folded, with adjacent folds adherent to each other, and in one instance a small vesicle so constituted could easily have been mistaken for a yolk-sac. The amnion in this case had undergone decided structural changes.

The number of chorionic vesicles wholly encased in blood or in blood and decidua was relatively small. The layer of blood which was interposed between the decidua and chorion varied from 1 to 10 or more millimeters in thickness. Whether the condition of this blood is of any value in determining the time that has elapsed since the detachment of the conceptus and its expulsion from the uterus, I am at present not able to say. The contrast between the states of preservation of the blood and the contained conceptus naturally was sharp in many cases. Often the blood was preserved well, even in instances in which the stroma of the chorionic vesicle was very degenerate. The conceptuses in this group have progressed somewhat in development beyond those in the preceding group, both as to external form and the internal organs, but in general the changes noted in the cyema and its appendages, or in the chorion or amnion, or even in the decidua, did not differ in kind from the changes noted in the previous groups. However, since the specimens in this group are somewhat older, it would seem to follow that the duration of these changes must have been somewhat longer. Nevertheless, the rate of change must have been much slower. Hence a longer duration does not necessarily imply the production of a more pronounced change. It is also not impossible that, with increasing maturity, the tissues may become more capable of resistance and thus affect the rate of change produced by a given cause of constant intensity.

As was true of some of the nodular cyemata, so also several of the cylindrical were sessile, being attached directly to the amnion, sometimes by their caudal extremities, apparently without the instrumentality of an umbilical cord. But, as a rule, a short umbilical cord is present, even if not wholly normal in form, structure, or relations. Indeed, the cord quite frequently is distended greatly, and microscopic examination usually shows that the condition of the umbilical vessels, even when present, is not normal. In many instances they are absent altogether and

the tissues of the cord, like those of the cyema itself, have undergone great changes. Rarefaction of the mesenchyme and cavity formations are very common. Portions of the allantoic stalk were frequently preserved, although sometimes in a form so greatly modified as to make their recognition doubtful.

The yolk-sac also frequently was present, though changed so very much that recognition of it could not always be certain. It frequently had a greatly thickened, fibrous wall which was fused completely with the chorion.

The decidua was present in only 31.2 per cent of the 48 specimens in this group and was infiltrated in 80 per cent of these, excluding 2 doubtful cases. This infiltration was marked in 58.3 per cent and slight in 41.7 per cent of the specimens. Abscess formation was relatively rare. The infiltration also was less marked than in the preceding groups, especially in the first three, and cases suggesting interference were rare, although several were noted.

Hydatiform degeneration was present in 38.5 per cent, with a probable additional 6.3 per cent. Infiltration of the decidua was present in only 3 or 4 of these specimens, but not much reliance can be placed upon this small number.

Since the decidua was absent in 6 of the 10 cases in which it was definitely stated in the history that there was no venereal disease or evidence of it, it is impossible to throw any further light on these specimens; for, as already stated, infiltration does not occur in the chorionic vesicle until the latter is extremely degenerate. Hence, in the absence of the decidua, one can only draw inferences as to its condition from changes in structure of the chorionic vesicle. Since hydatiform degeneration was present in 4 of these 6 cases, the inference that the decidua of these, if present, would also have shown infiltration is justified. In 4 of the 9 cases in which the absence of venereal disease was reported, and in which the decidua was present, the latter undoubtedly was infiltrated. This infiltration was mild in 2 cases and severe in 2. In one of these instances in which it was especially emphasized that the patient stated that she had never had leucorrhea, and in another in which it was stated that leucorrhea was present but that the patient had never had venereal disease, the infiltration was very marked. Further confirmation of the clinical diagnosis was found in three cases of lues and in one of endometritis.

In two cases of this group in which the alleged cause of the abortion was respectively a blow in the abdomen and a fall, severe infection and even abscess formation were present; and in a third, in which an accident was blamed, hydatiform degeneration was recognized, and hence endometritis probably existed. In a fourth case in which abortifacients were supposed to be responsible for the termination of pregnancy, a mild endometritis and changes suggestive of lues were present; and in a fifth instance, in which the abortion was attributed to quinine, the specimen plainly suggested that it came from an induced abortion. The sixth case, which was said to be spontaneous, had the microscopic appearance of an old retained specimen.

The structural changes noticed in the decidua, in the chorionic vesicle, and in the amnion, did not differ in kind from those seen in previous groups. Calcifica-

tion was present in small areas in only a few specimens, which had the characteristics of old retentions. Coagulation necrosis, or so-called "infarct" formation, so common in the next group, was rare here; but fibrosis and cytolysis of the decidua were as common in this as in the other groups. Rarely, the decidua was so fibrous as to simulate the degenerate chorionic membrane very closely.

B. Tubal.

Since 2 of the 5 specimens originally placed in this group were found to contain no embryo, only 3 remain. Of these, No. 697 contains a very small nodule of embryonic tissue, the appearance and structure of which suggest that it very probably belongs in the preceding group of nodular cyemata. However, since the sections of this nodule do not form a complete series, one can not be absolutely certain of this. Another specimen, No. 346, also belongs to the group of nodular cyemata, for neither the caudal nor the cephalic end can be distinguished with the naked eye. This leaves only one specimen, No. 729, in the group of cylindrical tubal cyemata. Since the only remnant of the cyema itself found in this specimen is a small group of cells on the end of the umbilical cord, the existence of a cylindrical cyema in this case can be a matter of surmise only, for the condition of the cord has not been found to be a reliable criterion for distinguishing between the previous existence of a nodular or a cylindrical cyema. Moreover, since Mall thought it probable that the cyema was normal, this specimen can be retained in this group only if we desire to classify portions of the cords as cylindrical cyemata. From these considerations it follows that the group of cylindrical cyemata is left without a true representative from among the tubal pregnancies found in the first 1,200 accessions. This does not mean, however, that cylindrical forms can not or do not occur among tubal pregnancies.

Infiltration of the tube was present in 3 of the 5 specimens originally placed in this group in which it was included in the sections. Hydatiform degeneration was found in 3 specimens, but the tubes of 2 of these have not been examined microscopically. One of these 3 cases was a very fine example of hydatiform degeneration. A second was very clearly an early case, but too few villi were included in the third to make a definite decision possible.

Group 6. STUNTED CYEMATA.

A. Uterine.

It was emphasized in Chapter III that stunting, in a physiological sense, can not be limited to cyemata in any particular group; but since the difficulty of recognition increases with the decrease in the size of the specimen, it is only rarely that stunting can be detected by inspection alone in cyemata below the stage of limb formation. Furthermore, if the limbs themselves are to be used as a criterion, limb formation must not merely have begun, but must have proceeded far enough, and normal growth must have been inhibited sufficiently to effect a change in form clearly recognizable with the unaided eye. This, however, does not imply that the effect or the recognition of stunting is confined to the limb-buds. Rarely, it is noticeable quite early in the entire caudal or cephalic extremities, or even in

the head itself. This is illustrated by Nos. 2173 and 2233, shown in figures 32, 33, and 34. As is evident from these illustrations, the last cyema borders very closely upon the cylindrical in form.

The word "stunting," as here used, also implies a disproportion in normal form, not merely a reduction in size of the entire specimen. Hence none of the stunted specimens are merely undersized, normally proportioned fetuses; for although an equal, universal retardation in growth is conceivable, it is unlikely that such a thing really occurs. Such an assumption would imply that all organs and tissues are equally resistant to interference with the blood or nutritive supply, or to toxins or other influences. It may seem strange, indeed, that no fetuses beyond the length of 20 mm. are included in this group. This fact would seem to imply either that the causes productive of stunting which may be operative up to this time cease to be effective later, or that portions of the cyema have become so resistant that they can no longer become affected in such a way as to produce stunting. It has long been recognized, however, that stunting of an organism can occur as the result of various influences at any time throughout its period of growth in post-natal life. Hence an assumed increase in resistance of the tissues sufficient to withstand all influences affecting such young fetuses as those here concerned can hardly be offered in explanation for the absence of stunted fetuses among those more than 20 mm. long. Nor can one assume that the causes operative until this stage is reached, or at some particular time before this stage of development has been reached, always come into abeyance when a fetal length of 20 mm. has been attained.

If, on the other hand, we assume that the various tissues or organs are affected only during a transitional sensitive period, perhaps in certain formative stages, we are in conflict with the facts; for upon this assumption we should be able to group the stunted fetuses by the effects produced upon their tissues, organs, or systems of organs even, but this does not seem possible. Nor are the organs affected serially in the order of their development; for, entirely aside from certain things to be discussed in a subsequent chapter, some changes present within these stunted cyemata are quite universal and comparable, no matter at what stage complete inhibition of further development has occurred. Moreover, what impresses one most is not the striking modifications of external form, pronounced as these at times are, but the marked structural changes within the organs themselves. To what extent these changes may be attributed to maceration with consequent disintegration, or to dissociated or uncorrelated growth, and whether or not true stunting can be simulated by the effects of maceration alone, will be considered more fully in a succeeding chapter. The explanation for the absence of stunted fetuses beyond a length of 20 mm. is not only the failure to recognize stunting in them, but that maceration changes often become so pronounced that they mask the changes which have been characterized as stunting. When such is the case the specimen is placed in the next group.

Although gradual death of cyemata or of entire conceptuses in consequence of interference with the source of nutrition has not as yet been established, such a phenomenon is not only possible but highly probable. Death of the cyema or of the

entire conceptus in consequence of chronic endometritis, or in consequence of other chronic changes, or even perhaps in consequence of toxins, seems likely, however. Hence, although the cyemic circulation be maintained in the main, lack of nutrition nevertheless might occur locally and show itself first in outlying cyemic parts, as in the tips of the extremities or in the facial relief, in which places slight changes in form easily become evident. However, the fact that the present group of stunted cyemata is limited to a comparatively early age very seriously contradicts such an assumption, and the well-known fact that ill-nourished, stunted, viable infants are born with certain constitutional diseases would seem to imply the occurrence of stunted forms in all groups of pathologic cyemata and perhaps also the occurrence of stunted chorionic vesicles as well.

Excellent examples of stunting are No. 2473, a 13 mm. fetus, and No. 675, a 10 mm. fetus, represented in gross and in median section in figures 35 and 36. The head of No. 675 has been so deformed as to look like that of a frog, and the whole outward form has become rounded. Since this specimen was retained long after death, marked maceration changes had occurred, and it is a question to what extent the changes in form here shown can be attributed to maceration alone. The limb-buds in these stunted embryos soon become more rounded, smoother, and shorter, or even somewhat clubbed, losing all details of form as illustrated by No. 2233, represented in figure 34. The head loses its natural curves and becomes atrophic or reduced; the maxilla is often beaked and the mandible depressed greatly, thus producing gaping. In some cases the mandibular region may fuse with the chest, as represented in figure 37 (No. 788*a*), and with increase in flexure the eyes may come to lie practically opposite the liver. The caudal region looks stubbed or flattened, the caudal process being less evident. Both local and diffuse epidermal thickenings are not uncommon, and sloughing of the epidermis is frequently preceded by bleb formation. The umbilical cord is often distended, especially near its attachment to the abdominal wall, and at this point decided bleb formation is common.

Müller (1847) also noticed instances of bleb formation on the umbilical cord and stated that Albinus and Sandifort called them "processus infundibuliformis" when they occurred at the point of attachment of the cord to the abdomen. Müller further stated that Ruysch described a cord so full of "hydatids" that he spoke of it as being a "concatenatio vesiculorum."

The internal organs of the specimens become distended, lose their clear outlines (as illustrated by No. 983*a*, shown in figure 38), blood-cells seem to pass out from the vessels in all directions, the normal cell relations are disturbed, cytolysis occurs, nuclei of various cell types become pycnotic and circular in outline, until all areas of the specimen seem to be composed of one type of cell only. This is due to the fact that all nuclei have assumed a similar form and appearance, but in more advanced stages these nuclei, too, disappear and only a homogeneous necrotic mass remains to represent the fetal tissues.

The length of the fetuses in this group varies from 4.5 to 20 mm., and the menstrual age from 30 to 127 days. But neither the former nor the latter can be regarded as more than roughly indicative of their true age; for, although 30 days is

approximately the correct age for an embryo of 4.5 mm. long, 127 days is entirely too old for one with a length of 20 mm. Specimens of approximately the same alleged menstrual age are found to differ widely in length, and fetuses of approximately the same length may differ greatly in menstrual age. Nor can these discrepancies be attributed to the unreliable character of the menstrual histories, for specimens with identical menstrual ages often vary considerably in size. This is illustrated splendidly in cases of double-ovum twins. In one of these instances (No. 1840) the fetuses have a length of 15.9 and 38.5 mm. The larger of these twins is normal in every respect and macerated but slightly, but the smaller is greatly macerated and stunted. Since both these specimens are of identical age, they illustrate how misleading even a reliable menstrual history may be.

In a second case, that of No. 788 *a*, *b*, one is a nodular cyema described under group 4 and the other a stunted specimen included in this group. The organs of the latter or larger fetus, though dissociated, are all well outlined, and the vertebral disks especially well defined, in spite of the fact that it must have been dead a considerable period of time. The umbilical vessels are degenerate and the limbs atrophic. The menstrual history unfortunately is not known, or it would be possible to make some conjecture at least as to the probable length of retention *in utero* after fetal death. However, if we assume that the large fetus is smaller than it should be, as undoubtedly is the case, and take its anatomical age to be that of a length of 20 mm., it would have a normal menstrual age of about 7 weeks. The small nodule (788*b*), which was only 2 mm. long, does not show a development corresponding to that of a normal specimen of this length, and on the basis of size would have an age of less than one month. This, however, does not necessarily imply that it died at that time. Indeed, the relative preservation of the tissues of the two fetuses makes this very unlikely, although we must remember that such a small nodule as 788*b* could probably be preserved for a long time in such a large quantity of sterile amniotic fluid as that in which it was contained.

Another instance which shows the misleading character of the menstrual histories, even when known, is that of No. 1914, a case in which a large mass of hydatiform cysts accompanied a normal, living fetus of 7 months. A still better illustration is the case of Slemons (1917[a]), in which a nodular mass, apparently a twin, accompanied a normal viable fetus. Since it is not improbable that such specimens as some of these have been taken to establish the occurrence of superfetation, they will be mentioned in a later chapter.

In the other three cases of twins included in this group the cyemata fall into the same instead of into different groups. In two instances (Nos. 207 *a*, *b*, and 341 *a*, *b*) this may be due to the fact that they are single-ovum twins, even if they are not of the same size. In the third case (No. 330 *a*, *b*), although from double ova, both fetuses were of the same length. The appearance of these conceptuses indicates that they were retained for a considerable period after fetal death, and the history confirms this. Syphilis was suspected in this case and bleeding began six weeks before the abortion occurred. Furthermore, the sizes of these fetuses, as well as the condition of the tissues themselves, clearly indicate that both had probably been dead some time before hemorrhage began.

Whether or not twin cyemata fall into the same group of the pathologic very evidently depends upon whether they have been subjected to identical influences. That the exact conditions under which they develop may easily vary is evident, and that they may be variously affected previous to implantation is also possible. Nor does the occurrence of twins which fall into different groups necessarily imply that the processes responsible for the physical differences were necessarily or essentially different from those which are responsible for the disproportion in size of normal, full-term twins. It may be simply a matter of degree. In the case of 788 *a*, *b*, for example, the deciduæ were infiltrated, but not to the same degree.

A few of the specimens in this group are of particular interest because of the great disproportion that exists between the size of the fetus and that of the chorionic vesicle. In No. 135, for example, in which the fetus was 9 mm. long, the dimensions of the chorionic vesicle were 105 by 65 by 65 mm. Since the villi practically were absent and the surrounding layer of decidua was very thin, the above dimensions practically are those of the amnion also, for it had fused with the chorion. Although the wall of this abortus is composed of these three layers, it nevertheless is almost papyraceous. Microscopic examination shows it to be decidedly degenerate and to contain many leucocytes. The amnion, too, is very degenerate, although its epithelium is still present. Even if mechanical distension were the chief factor in the enlargement of this vesicle, it is unlikely that it was solely responsible for the disproportion between the chorionic vesicle and the size of the fetus. Part of this disproportion is attributable to some recession in the size of the embryo, and more to the failure of the latter to develop normally. To what extent the chorionic vesicle grew after the death of the fetus must remain a matter of conjecture; but in view of its very degenerate character, it seems unlikely that it could have grown much. The absence of the menstrual history unfortunately leaves us without data that might be of some assistance in arriving at a conclusion regarding this matter. Although the organs of this fetus have lost their clear definition, and although dissociation and maceration are marked, yet on the whole it is preserved better than one would expect from an examination of the chorionic vesicle. Though epidermal blebs are present, not all the epidermis has sloughed. Indeed, in some places the superficial layer has formed marked local thickenings which now and then are so definitely circumscribed that they could probably be designated as warts or papillæ. Similar, although more diffuse, epidermal thickenings are found also in No. 201, a fetus of 20 mm. The same phenomenon apparently was observed by Rokitansky (1861), who spoke of papilla-like growths of the epidermis in a fetus.

The most interesting thing seen in the stroma of the villi of this group was the presence of epithelial vesicles at various depths from the surface in No. 276. Although many of these vesicles which are not well preserved could easily be confused with degenerating vessels, in the case of others this is impossible, because their relations to the epithelium can be established easily. The epithelial lining of many of them is fairly well preserved, and in some instances the vesicles can

be shown to communicate with the surface by means of an epithelial invagination. Most of them, however, lie isolated in the stroma.

In looking about for a possible explanation for the presence of these vesicles, it became evident that they had their origin in epithelial invaginations. The opposite walls of these invaginations apparently become fused proximally and their strands of epithelium then connect the vesicles with the surface. Further examination of the sections of the villi in this specimen shows that instead of having a fairly regular border, the epithelium is decidedly crenated or folded, quite in contrast with the usual condition of things. Hence it would seem that proliferation of the epithelium has resulted in foldings into the stroma of the villus, instead of accumulations on the surface. The presence of proliferation of the epithelium in this case seems to lend further confirmation to the presence of hydatiform degeneration.

Out of 73 specimens originally placed in this group, 16 were found to belong elsewhere, and 23 were added, making 80, from which 1 must be subtracted because of twins in one chorionic vesicle. The decidua was present in 45.5 per cent and infiltrated in 88.9 per cent of these, excluding 2 in which infiltration was doubtful. This infiltration was marked, even up to abscess formation, in 56.2 per cent of the specimens and slight in the rest. Hydatiform degeneration was present in 24 per cent, excluding 5 in which its occurrence was probable. Infiltration was present in 90 per cent of the specimens in which the decidua was included and not too necrotic for examination.

In attempting to correlate the clinical histories with the objective examination, it was found that the clinical diagnosis of infection is confirmed in 4 out of 5 cases. In the fifth case the decidua was not included, but since hydatiform degeneration was present, infiltration can be assumed and the clinical diagnosis of infection be regarded as confirmed in this case also. Of the 6 cases which were reported as showing no evidence of venereal disease, the decidua was not included in one and was too degenerate to assist in the diagnosis in a second case. Of the remaining 4 cases, 3 show the presence of a severe and 1 of a mild infiltration.

Although mechanical interference with the course of the gestation seldom was reported in this series, several specimens were noted in which abortion probably was induced. In one case in which the termination of pregnancy was attributed to fright, the decidua, unfortunately, was not included; but since the chorionic vesicle showed hydatiform degeneration, the decidua undoubtedly was infiltrated. In a second case in which fright was given as the alleged cause, Mall noted that the decidua was "markedly inflamed." In a third case, in which the termination of pregnancy was attributed to work, death of the conceptus must have occurred long before. As stated in the introduction, I fully realize that this contradiction between the alleged cause and the findings may be apparent only, for it is entirely possible that exertion, psychical disturbances, or an accident may precipitate an abortion which is more or less imminent at the time.

The structural changes encountered in this group do not differ in kind from those present in previous groups. However, the incidence of infiltration of the

decidua was more than twice as high as in group 5, and was divided equally between the severe and the slight cases. The presence of hydatiform degeneration was somewhat more common, although the percentage of these cases in which the decidua was included was somewhat lower. In 90 per cent of the latter the decidua was infiltrated.

Although they frequently were not especially noted, "appendici durate" seemed somewhat commoner in specimens of this than in those of the previous groups.

B. Tubal.

The small number of stunted tubal cyemata among the first 1,200 accessions is especially interesting, because the average length of these specimens is only half as great as the average length of those in the corresponding uterine group. After certain specimens had been excluded only 6 stunted tubal specimens remained. The corresponding uterine group, on the other hand, contained 61 specimens. But in spite of the small number of stunted embryos in the tubal group, the significance of the fact, nevertheless, is clear. It is only very rarely that a tubal pregnancy lives beyond the earliest stages of development, while in the uterus, on the contrary, this is relatively very common. This conclusion is not based upon a comparison of the relative number of specimens found in these two groups of uterine and tubal pregnancies alone, nor upon the comparative size of the specimens, but upon the respective percentages that the total number of specimens in the uterine and tubal groups of the stunted form among the entire series of specimens in the pathologic division which were examined. Although the stunted embryos form 19 per cent of the total number of uterine specimens, stunted embryos form only 5.7 per cent of the total number of the tubal specimens. This marked difference scarcely can be explained in any other way than as suggested above.

Although 11 specimens originally were placed in this group of stunted tubal cyemata, 5 were found to fall elsewhere. One (No. 338c) was a uterine specimen, being accompanied by considerable decidua. Two others (Nos. 196 and 934) belong in group 4. The former has a length of only 3 mm., and the latter, although 6 mm. long, was recorded as having no extremities, and described as looking like a grain of wheat. Moreover, the anatomy, especially of No. 934, is that of a nodular rather than of a stunted cyema. One specimen (No. 992) belongs in group 3, and another (No. 881) can not properly be classed as stunted, in view of the fact that it was only 3 mm. long.

Of the 6 remaining specimens, 5 lay in tubes the walls of which were infiltrated intensely in the case of 2, and but slightly in 3 specimens. In the sixth case too little of the tube was included to serve as an adequate basis for examination.

Hydatiform degeneration undoubtedly is present in 4 of these 6 cases, or in 66.6 per cent. In another specimen (No. 477) some villi seem to show incipient changes indicative of hydatiform degeneration, but since marked maceration changes also are present, one can not be certain of this case. Too few villi were

included with the remaining specimen to make a positive diagnosis justifiable, but the structure of those present did not suggest a hydatiform change.

The cyemata were all macerated and some were fragmented. In two specimens (Nos. 838 and 882), Mall stated that limb-buds were not present. Since the respective specimens were 6 and 8 mm. in length, it is evident that they should have been present, and their absence must be attributed either to inhibition of growth or to disintegration. In the absence of a complete series of sections, this point unfortunately can not be decided. It was possible to recognize outlines of various organs in one specimen only, and since most of the specimens were very young, they had a structure comparable to that of the nodular and cylindrical, rather than of the stunted uterine group. Maceration and dissociation were very marked, as a rule.

Group 7. FETUS COMPRESSUS.

A. Uterine.

The term *fetus compressus* was used by Mall in a much more general sense than usual. It has been customary to restrict this term almost wholly to one twin which died early and became softened and compressed by the living, well-developed companion. Instances of a single fetus similar to a true fetus compressus are recorded in the literature, however. Strahl and Henneberg (1902), for example, stated that they found such a specimen, although the presence of abnormal pressure exerted directly upon it by the uterus could not be established. Hohlweg (1903) also implied that Küstner thought that cases of fetus compressi could occur in single pregnancies, and I am quite certain that I am representing Mall correctly when I say that his observations were to the effect that quite typical fetus compressi occur not rarely in single pregnancies in the presence of abundant amniotic fluid. Although Schickele (1907) regarded macerated forms from the second months as rare, His (1891) emphasized that the softness of aborted forms easily results in abnormal folds and flexures, and Waldstein (1913) stated that von Winckel found deformities of the extremities extremely common in tubal embryos.

As previously intimated, this group is a very inclusive one. In some respects it really is a group of left-overs not characterized by maceration alone. Specimens in any of the preceding four groups may be, and indeed they nearly all are macerated. However, since many of those in the normal division also are macerated, the presence of maceration can not be regarded as distinguishing any group. Differences in the degree of maceration may and do exist; but since maceration becomes evident externally much more quickly in older fetuses, gross appearances often are a very unreliable guide for the determination of the degree of maceration. One thing, however, is true of all specimens in this group, except such as are composed of material from curettage, and that is that maceration often is present even in specimens composed solely of fragments of wholly normal embryos or fetuses.

Some of the specimens are macerated and swollen and others are shriveled and mummified. The latter Mall distinguished as fetus compressi. The use of this term does not imply, however, that they have necessarily been subjected to

pressure, although such usage is at variance with the historical meaning and the usual application of the term. Moreover, very macerated fetuses, the forms of which have not been very materially changed, are not included. These things must be borne in mind in order to avoid misunderstanding. It is true that some of the so-called fetus compressi look as though they had been subjected to pressure, and in some instances, even of single pregnancy, there is no doubt whatever about this. Other fetuses look compressed, although a quantity of liquor amnii seemingly sufficient to prevent direct uterine pressure still surrounds them. The head is collapsed from side to side, the hands and feet are flattened, and the trunk also is collapsed. In most of these cases the appearance of compression is apparent only, and probably resulted from the softening and collapse of the tissues consequent upon maceration and dehydration under aseptic conditions. The skull sometimes is practically devoid of brain tissue and decidedly flattened, all the tissues have become degenerate and necrotic, and those of adjoining parts have often fused more or less, so as to obliterate the natural boundaries.

If, as stated, mummification sometimes may occur while the fetus is contained in a large amount of fluid, it would seem to have to result from chemical changes in the amniotic fluid. Indeed, it not only is conceivable but inevitable that the composition of the amniotic fluid is changed soon after the death of the fetus. As is well known, death of the membranes makes them more permeable, and hence offers greater facility for the absorption of fluid, thus leading to the greater concentration of the liquor amnii, with consequent dehydration of the fetus. It is evident, however, that absorption must be slow, for otherwise the amniotic fluid, although rarely large in quantity, would soon be absorbed and the fetus would subsequently be subjected to direct pressure from the uterine wall. Sometimes, indeed, such is the case, and then the macerated or mummified fetus may be rolled up firmly into a ball, as illustrated by Nos. 921 and 1041, shown in figures 39 and 40. In the last case the decidua, placenta, and membranes were wrapped tightly around the fetus, the whole constituting a firm, rounded mass.

It is difficult to characterize this group as a whole, because it contains such diverse things as portions of a cord, material from curettage, embryonic fragments of mutilated normal specimens, as well as macerated fetuses falling among the groups of the nodular, cylindrical, stunted, or normal. Figures 41 to 50 inclusive afford some idea of the diversity existing among the specimens of this group. This diversity is extreme, not only in form, size, and age, but also in the matter of preservation. No. 1245 (fig. 41) is a good illustration of fragments. Whether they came from specimens which developed under normal or pathologic conditions it was not always possible to state, even upon microscopic examination, for the decidua was not always included. No. 1806 (fig. 43), though classed in this group, was originally described as normal in form and could be placed among grade 3 of the normal division, for some specimens in this grade show even greater maceration.

Specimen No. 651*a* (fig. 58) and to a lesser degree No. 1301 (fig. 44) illustrate beginning changes in form which, though slight, are quite characteristic of many of the specimens of this group, and when present always exclude them from the

division of normals which it should be recalled contains specimens with developmental anomalies. Besides being macerated, both these specimens are characterized by a peculiar sag or droop of the extremities present on the left side only in No. 1301. This is noticeable first in the arms. These distortions, though slight in these fetuses, are shown in a much more advanced stage in No. 1931 (fig. 51), a considerably older fetus which had been retained longer after death. Although this specimen is only 35 mm. long, it unquestionably is anatomically older than No. 1301, which measured 50 mm., a difference largely attributable to the presence of marked maceration. Nos. 1925, 1239, and 1515, shown in figures 48, 49, and 50, are merely older and still more macerated and deformed specimens, No. 1515 being in the early stages of dismemberment.

In order to illustrate the fact that many specimens in this group of the pathologic division are quite comparable to some of those in grade 3 of the normal division, I have selected a number of roughly corresponding stages and placed the photographs parallel, for the sake of comparison, in figures 53 to 63 inclusive. Anyone familiar with the material here concerned will know that photographs are not adequate evidence for illustrating the classification of a specimen; but even an inspection suggests, and the microscopic examination supports, the statement that there is no sharp dividing-line between some of the specimens in the third grade of the normal division and others in this group of the pathologic division. Specimens found in the pathologic division often are better preserved in every way and wholly without developmental anomalies, while some specimens in the normal division are macerated and have pronounced anomalies. Indeed, this is what one should expect, for whatever the cause or causes of the changes represented by specimens which have been classified in group 7, these changes must have a beginning. However, these beginnings undoubtedly would not be clearly recognizable by the unaided eye or perhaps not even with the aid of the microscope. Consequently, the same person may classify one specimen differently from succeeding similar ones, merely because various aspects or characteristics of it impress themselves more upon him at different times. These cases apparently would constitute a border-line group as far as the morphological changes are concerned.

The lengths of the specimens in this group included among the first 1200 accessions range from 1 to 210 mm., and those of all those in the entire collection from 1 to 286 mm. This range is due partly to the fact that the idea of the group developed as the material accumulated. Moreover, a number of different individuals were engaged at widely different times in the classification of the material. For these and for other reasons this group also has been reviewed in accordance with the wishes of Mall. It is interesting that the reclassification has affected almost solely the swollen, macerated specimens and only a few so-called fetus compressi. Hence it is evident that there is practical unanimity of opinion among those concerned as to the gross characteristics of a fetus compressus, even if some of these were placed in the normal division. This unanimity of opinion is explained largely by the fact that the term is applied almost wholly to larger

fetuses. The smaller specimens disintegrate completely before the stage of mummification is reached, while in older fetuses the skin, the cartilages, even when still wholly unossified, and the ligaments, as well as the fibrous tissue as a whole, resist disintegration more. The smaller specimens soon become so soft that they literally fall to pieces before they can become dehydrated and mummified. This is illustrated splendidly by Nos. 379 and 717. It is recorded by Mall that the former fell to pieces upon being handled, and of No. 717 it was stated that a slight amount of shaking would cause the entire specimen to disintegrate.

All the small specimens found in this group undoubtedly could be classed among the other groups of the pathologic or normal divisions, for they have been placed in this group merely because they are macerated more completely than the specimens usually classed in the normal divisions. The exclusion of these would limit this group to fetuses beyond the length of 25 to 30 mm. At this time a stage of development much more resistant to disintegration is reached, and the changes in form regarded as peculiar to this group can then arise. As recorded by Mall, small specimens macerated so thoroughly that they almost fall apart, even when handled in fluid, sometimes have undergone very slight changes in form and could be placed in the other groups.

It is an old story that the outward appearances of the specimens in this group often are grotesque. This is true particularly of the so-called fetus compressi. These strange appearances are very largely attributable to the distorted extremities, the gaping mouth, and the pointed features. There is no limit to this distortion, as No. 1925, shown in figure 48, illustrates. Sometimes the greatly and abnormally bent extremities become adherent, as in case of the legs of No. 1859, shown in figure 64, and in other instances, as in Nos. 1860 and 627, bleb formation of considerable size occurs and later the skin may slough or become rolled up and fused so as to form marked welts. Sometimes it may hang in shreds from the fingers and toes or from other parts of the body. These strands of sloughed epidermis may then simulate amniotic bands, and when accumulated about the fingers and toes may hide them completely, giving the appearance of a mittened hand. However, epidermal thickenings, local or diffuse in character, are sometimes present, as shown in figure 65. These give one the impression that they result from epithelial proliferation rather than merely from fusion of accidentally apposed cells. Fusion of adjacent surfaces of the digits is also common, and occasionally the upper or lower extremities may be united quite firmly in places through fused areas of epidermis, as is illustrated by No. 1859.

The contortions of the extremities are due not merely to the relaxation of the joints and consequent abnormal mobility, but result also from a bending of the cartilaginous shafts of the bones, even up to or beyond an angle of 90°. The smaller cartilages of the hands and feet may lose their distinct outlines, and under conditions of advanced maceration may fuse somewhat with one another. Rarely, areas of coagulation necrosis are also seen at the distal extremities of the terminal phalanges. Degeneration of the precartilage and cartilage opposite the ossified areas may also be complete, thus presenting the appearances of bones with

extremely enlarged cartilaginous extremities. Although no measurements were taken and no exact comparisons made with normal specimens, it is not unlikely that the extremities of some of these developing cartilages are somewhat enlarged, although not necessarily as the result of growth.

A survey of a considerable number of these fetuses shows that the distortion of the extremities, and indeed also those of the trunk, are purely haphazard. They seem to follow no law, except perhaps that of gravity, but often are in diverse directions in the different extremities of the same fetus. Whether or not the initial sag is in the same general direction in all the extremities depends considerably upon the age of the fetus. Below a length of 25 to 30 mm. the limbs still extend stiffly from the body, and in these specimens both pairs of the extremities usually droop, as represented by Nos. 651*a* and 1710, shown in figures 58 and 66. After the extremities assume their normally flexed posture the abnormal positions which they then take become far more diverse. This is well illustrated by Nos. 1751 and 1931, shown in figures 67 to 68. Similar distortions are present also in the digits, as shown in figure 69. Nor do fetuses of corresponding ages necessarily show the same degree of distortion, or possess distortions in the same general direction, even if they show approximately the same degree of maceration. However, the degree of distortion nevertheless is roughly correlated to the degree of maceration and the duration of the post-mortem intrauterine retention. Fresh and unmacerated specimens never show the characteristic distortion.

The haphazard character of these distortions seems to indicate quite conclusively that they did not result from contractures arising during the gradual death of the fetus. To be sure, the loss of tone accompanying gradual death or following it must finally become extreme, but since the specific gravity of the amniotic fluid, even when altered, is so little if any less than that of the fetus itself, it is difficult indeed to see just why marked changes in the position, even if not in the form, especially of the extremities, can occur without the instrumentality of external pressures.

The umbilical cord of many of these specimens, especially of the fetus compressi, is abnormally and often extremely twisted and thin. As is well known, this twisting is unlike that normally present, though it seems always an accentuation of it. I have never seen it occur in a direction opposite to that normally present in a given cord. That most of the extreme torsion of the cord is purely a post-mortem and not an intra-vitam phenomenon is indicated by the fact that these extremely tortuous cords always can be untwisted easily up to the point of the customary twisting. The excessive tortuosity also varies more in degree, and a single turn does not always involve the same length of cord in fetuses of approximately the same age, even when about the same amount of twisting is present in the entire cord. Indeed, a single turn may occupy different lengths of the cord of the same fetus, and it is not uncommon to find only a portion of the cord twisted and the rest of it wholly untwisted, a fact which probably can be attributed in part to the varying degree of maceration.

While observing the nature of this twisting more closely, it became evident to me that it probably was not produced intra-vitam, but rather resulted from post-

mortem passive fetal movements. Had this twisting occurred during the life of the fetus and been the cause of its death, one would expect to find some adjustment to it on the part of the growing tissues. Such an adjustment, however, does not exist. The tissues are necessarily displaced mechanically, but no adhesions between adjacent turns were observed save such as easily could be attributed to maceration changes. Since no external forces save those of the uterine contractions can reach a dead fetus, it seems that this twisting, even if not always present, must result from uterine contractions. Since these contractions in many instances may have been more pronounced and prolonged than usual until abortion finally occurred, the greater twisting present in these cords could easily be explained in this way. If we assume that in a given uterus this peristalsis occurs in a uniform direction, and that in a small percentage of uteri it may occur in an opposite direction, torsion in different directions could be accounted for. I realize fully that direct observations upon the living uterus are necessary to make this supposition valid, but in any case it is difficult to conceive of any other agent than uterine contractions that possibly could rotate a dead fetus. It also is evident that this rotation probably would have to occur very largely before marked absorption of the amniotic fluid had occurred and entirely before the fetus became embedded in a mass of coagulum, such as is illustrated by No. 261, a specimen with a very tortuous cord.

Although it is conceivable that coils of the cord could cause the amputation of an extremity, this probably could occur only in comparatively early stages of development and hardly so late in fetal life as implied in figure 187 of Broman (1911). It is also noteworthy that, although coils of the cord about the extremities were frequently found, not a single instance of partial amputation or of macerated amputated extremities is contained among over 2,000 specimens in the Carnegie Collection.

It does not seem unlikely that the location of the placenta *in utero* may be instrumental in determining both the amount and the extent of torsion, but until more is known regarding uterine peristalsis all this remains merely a matter of surmise. The tubal and ovarian specimens unfortunately do not throw much light on this question, for they usually are very young and too macerated or damaged. Only one of all the tubal specimens, among both normal and pathologic, contained in the Carnegie Collection, had a cord sufficiently long to be of any value in this matter, and in this specimen definite torsion was present. This fact does not prove, however, that peristalsis is not a factor in torsion, for tubal peristalsis could produce similar results.

Not infrequently the cords show marked bleb formation, as illustrated in Nos. 1475 and 1523 (figs. 54 and 70), but bleb formation, which is present elsewhere in many of these specimens, is not peculiar to the group, for it is common also in younger cords and fetuses, and may also be localized elsewhere on the body, as in Nos. 1523 and 2261 (figs. 71 and 72). In other instances, as in No. 590, the entire cord is decidedly swollen, or alternately swollen and constricted, and in still others it is practically without a turn and wholly without knots, although long and filamentous. Coils of the cord about various portions of the

fetus seem to be very common in this group of macerated fetuses, and probably can be attributed to the same factors which produce the twisting. This, however, does not imply that the structural changes in these cords are different from those present in other groups or that torsion was the cause of fetal death. It is largely, if not wholly, a matter of degree of difference, and this degree is determined very largely by the age of the fetus, the length of retention, and perhaps by the irritability of the uterus. The greater tortuosity of these, as compared with normal cords, as stated above, can be explained in the same way.

The decidua was present in 45.3 per cent of the 53 specimens remaining in this group. It was infiltrated in 17, or 70.8 per cent. The infiltration was marked in 29.1 and slight in 70.9 per cent. Although decidual infiltration was present in 88.9 per cent of all cases in group 6 in which the decidua was included, this was the case in only 70.8 per cent of the cases in group 7. The percentage in this group is lower than in any other save group 5, suggesting that the infiltration is not entirely dependent upon the length of retention *in utero* after fetal death.

Hydatiform degeneration could be recognized in only 10.9 per cent of the cases. The decidua was infiltrated in the 2 cases in which it was present, but since the number of cases concerned is so small, no special importance can be attached to this fact did it not accord with the findings in the other groups. All chorionic vesicles in which this change was noted were in relatively early stages of development.

In trying to correlate the clinical histories of the uterine specimens with the objective examination, nothing especially interesting was revealed. The correspondence between the two is no better in this than in the other groups. In general it may be said, however, that the specimens of this group have been retained longer after death, and that this fact is supported by the great frequency of the presence of calcification and coagulation necroses, or so-called "infarct" formation, which was relatively common in the placenta. The greater maceration of the specimens clearly is evident from inspection alone. Subchorial hematomata were present in several specimens, and chorionic cysts were noticed in one. Changes reported by Welch (1888) as hyaline metamorphosis of the placenta were present in a fair percentage, especially in the older and longer retained placentæ, and will be considered further in a subsequent chapter.

The frequency of divergence from the normal form on the part of the fetuses in abortuses also impressed Granville (1834), and Panum (1860) stated that he found the frequency of double malformations among museum collections to be twice that in actual life. Panum found cyclopia in 16 of 618 human deformities, 25 among 143 simple deformities in sheep, and 37 in 91 deformed fetuses. He also believed that various deformities of the jaws in certain quadrupeds probably are due to intrauterine pressure. He came to this conclusion, it seems, because of his experience while incubating eggs. However, according to Panum, spina bifida occurs much more commonly in man than in animals, and he expressed the opinion that the study of comparative teratology may contain the open sesame for a comprehension of many, even if not of all, abnormalities.

His (1882, 1891) found 22 per cent of 62 aborted specimens pathologic, and J. Kollman (1889) stated that it is generally known that one-half of all abortuses are pathologic. Giacomini (1894) claimed that as many as 80 per cent of all abortuses are abnormal, and Phisalix (1890) declared that normal specimens are rare among abortuses; but Mall (1917[c]) found only 39.6 per cent pathologic conceptuses among the first 1,000 accessions in the Carnegie Embryological Collection. However, cyemata classed as pathologic formed only 26.8 per cent among these accessions, the rest being composed merely of vesicles classed as pathologic.

Because of the presence of certain changes in the chorionic vesicle, Crosti (1896) concluded that the cause of abortion is primary in the vesicles. Giacomini (1894) declared, however, that it was impossible to decide whether the change noticed by him was primary or secondary, and emphasized particularly that the decidua should be studied because of its great influence on early development. His (1882) concluded that all abortive forms are primary, but later (1891) decided in favor of a secondary origin, a view held also by Mall (1917[c]). One would hardly seem justified in assuming, however, that all cyemic abnormalities or malformations are secondary in origin, for such an assumption would completely ignore or deny the existence of true hereditary anomalies such as polydactyly, hyperphalangism, etc. However, the mere possibility of the occurrence of anomalies of secondary origin makes the identification of these extremely desirable and important, although some of the achievements of experimental teratology seem to suggest that it may remain impossible to distinguish between anomalies which are primary and those which are secondary in origin.

Since the extension of our knowledge of the subject of human embryology necessarily has been from the older to the younger, it was inevitable that attention should be first directed especially to placental changes. Hence the literature upon the subject of placental pathology is extensive, while that upon the pathology of the cyema and chorion and also upon the decidua is small or even fragmentary. However, now that our knowledge of extremely early conceptuses is being extended much more rapidly, we soon shall be able to recognize the normal with more certainty, which alone will be a great step in advance.

Giacomini (1894) stated that many observers have noticed that abnormal changes arise in the membranes as soon as the development of the embryo is interfered with. He described these changes as the formation of vesicle-like structures in relation to both amnion and chorion.

A very interesting question is that of the invasion of the conceptus by cells of maternal origin. As long as the chorionic epithelium remains intact I never have seen any evidence of it, not even in the stroma of villi which were directly in contact with an abscess. These observations also are in accord with those of Nattan-Larrier and Brindeau (1905[b]). Nor have I ever seen anything suggesting direct invasion of the fetal circulation by cells from the maternal circulation. When one recalls the intimate relationship of the two circulations, it is surprising that such an invasion does not occur, for it would seem to be especially easy, but it is only after the chorionic epithelium is destroyed that maternal leucocytes seem

to gain access to the stroma of the villi. Indeed, the only invasion of the stroma which I have ever seen in preserved villi is due to invaginations of and extensions from the Langhans layer, for the presence of large numbers of Hofbauer cells hardly can be regarded as an invasion, even if these cells themselves are not fixed in position.

Besides lytic and degenerate changes due to retention or putrefaction, the occurrence of Hofbauer cells and other appearances suggesting tissue-cultures, thickening of the amnion and chorion was also frequently present. Amniotic villi and fusion of adjacent amniotic folds were seen quite frequently, but the rarest of all changes encountered were such strange appearances on the surface of the amnion as represented in figures 73 and 74. As indicated by the accompanying scales, both of these chorionic vesicles were small. Upon microscopic examination of these amnions it was seen that the hummocky appearance was due to local thickenings formed by increase in the connective tissue of the amnion. The amniotic epithelium was never found to be involved in these thickenings, and since only two specimens were observed I am at a loss for an explanation of this peculiar condition.

If the condition of the uterine mucosa at the time of implantation of the impregnated ovum may show variations in structure at all comparable to those frequently seen in the deciduæ accompanying abortuses, then it is easily conceivable that the fate of the conceptus may be determined by the structure of the implantation site. Not infrequently a small area of the decidua surrounding an abortus shows all the transitions represented in figures 75 to 77. Figure 75 shows the fine, large, clear, polygonal decidual cells slightly infiltrated and hence rather homogeneous in appearance. Figure 76 shows considerable infiltration and autolysis, but there are marked changes in the cell-form which remind one of the condition of the post-menstrual endometrium, as described by Hitschmann and Adler (1908). The decidual cells in these areas seem to take on the character of fibroblasts, and this characteristic is brought out still more in figure 77. In some specimens the decidua is composed of a decidedly fibrous mass, which reminds one at once of connective tissue. I do not know how far these changes of fibrosis may be present before implantation occurs or before placental differentiation has taken place; but if at all pronounced they can scarcely fail to affect profoundly the nutrition and growth of the conceptus.

It also may be urged that fibrosis of the decidua is but an effect of the death and retention of the conceptus rather than of pathologic conditions pre-existent to the advent of pregnancy, but the many instances in which the decidua is very degenerate and also infiltrated would seem to argue against such an assumption. Besides, many deciduæ surrounding specimens retained for a considerable period of time do not show comparable changes, and (as Orloff, Iwanoff, and L. Fraenkel have shown) restoration of the mucosa actually may begin before the conceptus is expelled from the uterus. In the few cases I have seen of partial regeneration of the mucosa, the decidua was not markedly fibrous. Infiltration of the decidua may possibly arise after the death of a conceptus, but that it is frequently present

long before this time would seem to be indicated by the fact that it does not apparently bear any definite relation to the duration of the retention. Moreover, the existence of endometritis is in itself evidence of the latter fact.

B. Tubal.

Although one of the six tubal specimens among the first 1,200 accessions was 80 mm. long, the others were relatively small. One (No. 535) was composed of a fragment including only the upper two-thirds of the trunk. The length of No. 685 apparently was estimated from the development shown in the few cross-sections, which showed it to have been macerated and disintegrated. Two specimens were 20 and 22.5 mm. long, respectively, and the other measured 8 mm. Hence it is evident that the average length of the uterine specimens falling in group 7 was very much greater, for their length was almost always above 25 mm., instead of below, as is the case with tubal specimens. This difference between the two groups is attributable, no doubt, verly largely to the different conditions under which development proceeds. As already indicated, mummification probably is impossible below a length of 3 mm. Consequently, such specimens in tubal cases could occur only if the surgeon failed to intervene and if both the patient and the fetus survived the rupture of the tube and its sequelæ. Moreover, in the case from which the 80 mm. tubal fetus was obtained, the specimen would never have lived to reach such a length had the patient come into experienced hands earlier, as is evident from the history. Furthermore, since Mall recorded that all the changes in this fetus "can be accounted for by the death of the fetus, which must have occurred at the time of rupture of the tube," it is clear that he regarded this specimen simply as a macerated normal fetus. The placenta which accompanied this fetus is of particular interest, because it illustrates an atypical form of hydatiform degeneration not previously seen. Although cross-sections of many of the villi are enlarged and have the clear stromata characteristic of certain stages of hydatiform degeneration, many of them contain vessels which, though relatively small in caliber, also contain blood-cells. Giant cells are quite common, and epithelial vesicles also are present in the stroma of the villi.

Upon examining the placenta with the unaided eye, and also under low magnification with the binocular, the villi again appear quite atypical and different from any examined so far. Some of them are very fine, long, and filamentous, but others, which are far more numerous, lack the typical hydatids, though bulbous. Many of them look blunt and swollen and possess enlargements lacking the tapering ends so well shown in cases typical of hydatiform degeneration. This modification in form of the villi may have resulted from the crowding to which they were subjected by the surrounding tube.

Regarding No. 478, which is 22.5 mm. long, Mall wrote: "It looks normal but unnatural." This fetus is very dark and hemorrhagic, and evidently is deformed by pressure, either within or without the tube, or probably even after its removal from the amniotic cavity, which the protocol states was contained in the

blood-clot. Of another specimen (No. 535) it is stated that it also was apparently normal, and consequently these 3 may be regarded as macerated normal fetuses, which leaves only 3 others. Of these, No. 307 had no head in any true sense, for the place of the head was taken by an empty fold which overhung the chest, and gave to cross-sections of the cephalic extremity of the embryo a form resembling the head of a grasshopper. Marked maceration and dissociation were present throughout the entire body of the specimen. The other two specimens (No. 685 and No. 846) were small, macerated, and dissociated fetuses, No. 685 being also disintegrated. Although No. 846 had not been cut serially, it was very similar in structure to No. 685, and it is not unlikely that both of these specimens also could be regarded as macerated normal cyemata; or, if we emphasize the hydatiform degeneration, we may prefer to group them as macerated, stunted, or cylindrical.

Hydatiform degeneration was present undoubtedly in two specimens, and probably in four. In a fifth (No. 846) the appearance was that of a very degenerate and macerated hydatiform change. This does not necessarily imply, however, that the cyemata contained in all these chorionic vesicles were abnormal, for I have found hydatiform degeneration in a number of chorionic vesicles, the cyemata in which appeared perfectly normal and which had been regarded and classified as such. Moreover, since relatively few villi were contained in any of these specimens, it is possible that the hydatiform degeneration, especially in these, although also in some of the specimens in other groups, may have been purely local instead of general in character. Furthermore, the villi contained in the clots which surrounded the specimens in this group usually were very macerated and necrotic even, so that the true picture was often decidedly masked. Marked infiltration of the wall of the tube was present in 2, or 40 per cent, of the 5 specimens in which it was included in the section. In the other 3, or 60 per cent, the infiltration was slight.

SUMMARY.

Uterine.—As shown in table 4 (Chapter III), the number of specimens in the different groups varied from 17 in the first to 74 in the sixth. The other groups contained almost an equal number of specimens. The percentage of instances in which the decidua was included in the specimens varied from approximately 44 to 76.8 per cent, the first and last groups being comparable in this respect. The high percentage of presence of the decidua in the first group is due to the fact that implanted villi remain attached to the decidua until the latter is expelled, but this explanation manifestly can not hold for the high percentage of its presence in the specimens in group 7. Here it probably is due to the fact that a sluggish but contracting uterus often molds into a ball the secundines, the chorionic vesicle, and the contained fetus, together with the decidua and blood-clot, the ball being finally expelled as a unit. In the younger specimens, and especially in undelayed abortion, this is less frequently the case, and decidua and conceptus are more frequently expelled separately. In some instances, too, the decidua is purposely removed by the practitioner in order to expose the contained conceptus and free it from the surrounding clot.

The variation in the percentages showing infiltration of the decidua is considerable, ranging from 45.5 to 100 per cent. In the first three and in the sixth group the percentage ranges from 90 to 96. It is 100 per cent in the fourth group and 46 and 50 per cent in the fifth and seventh groups, respectively. There is also considerable variation in the incidence of slight as compared with intense infiltration. The former ranges from 11 to 86 per cent, and its incidence is approximately comparable in the first, second, and third groups, in which it ranges from 11 to 19 per cent. Slight infiltration was most frequent in group 5, that of cylindrical embryos, where it was present in 86 per cent. Its incidence was quite comparable in the stunted fetuses (group 6), but very low in group 7. The relatively high incidence of intense infiltration in this group, unless largely secondary, is surprising, in view of the fact that many of these specimens have been retained so long and are so degenerate. That intense infiltration is so frequent in group 1 is not surprising, and its presence likely leads to an early termination of the gestation, no matter whether the endometritis existed previously to the gestation or was incidental to or consequent upon interference.

The occurrence of such a decided variation in the presence of infiltration of the decidua would seem to be the best possible evidence that this infiltration has a pathologic significance. Were the leucocytes, upon the presence of which the opinion regarding infiltration was mainly based, a constant constituent of the normal decidua, they should have been present in all specimens. This could fail to be true only if this infiltration occurred in the earlier months of pregnancy alone.

A slight increase in the frequency of the occurrence of hydatiform degeneration is seen in the first three groups, in which it rises from 69 to 85 per cent, being lowest in group 5 and next lowest in the last group. The gradual increase in its presence in the first three groups is easily explained by the fact that some time is necessary for its development, and that it is difficult to recognize it in its early stages or in macerated fragmented villi. The decline in its occurrence in the last groups may be due to abortion of the conceptus soon after the development of the degeneration. Its relatively extreme rarity in full-term births can be explained similarly. The most interesting thing in this connection is the fact that the decidua was infiltrated in every instance in which it was included in the cases of hydatiform degeneration occurring in the first four groups. Since the last three groups contained so few specimens, the percentages for each group are of very little value, but the presence of infiltration seems to be far less common in the specimens in these groups. This may be due to the fact that some low-grade infections spontaneously disappear, but not before they have seriously damaged the conceptus, which may then be retained for some time.

The occurrence of changes suggestive of lues rises gradually from zero in the first group to 10 per cent in groups 3 and 7, the incidence being roughly comparable in groups 4, 6, and 7, although group 5 contains only about half as many as these three groups.

Tubal.—Approximately 73 per cent of all the tubal specimens classed as pathologic in the first 1,200 accessions fall into the first two groups, which

are composed of villi only and of empty whole or of fragmented chorionic vesicles. This leaves only 27 per cent to be distributed among the other five groups of the pathologic division. Furthermore, the preponderance of the specimens falling into the first two groups actually is even more pronounced than this, for not a single tubal specimen formed of villi only is included among the accessions below No. 415. This is due mainly to the fact that Fallopian tubes containing what appeared to be blood-clot only were not retained in the earlier days of the collection.

If we assume that the incidence of specimens containing villi only was the same among the first 400 as in the last 800 of the first 1,200 accessions, then the total number of specimens composed of villi only rises from 39 to 78, and the percentage of those in the first two groups from 73 to 78. These percentages stand in very marked contrast to those in uterine abortuses, in which specimens composing the corresponding groups form only 18.4 per cent of all the. pathologic. Since all the specimens contained in these two groups necessarily are young, and hence also relatively small, it is evident that it probably would be incorrect to attribute to the unusual conditions within the tube this difference between the relative number of the uterine and tubal specimens contained in the first two groups. It would seem that the tube, although small, is sufficiently large and sufficiently distensible to permit growth to proceed sufficiently actively to assure development beyond the stage represented by the specimens composing these two groups. Consequently, it seems that the death of the embryo, with subsequent disintegration of it and of the surrounding amnion, and in almost half of the cases also of the chorionic vesicle itself, must be due to other things than a mere lack of space within the tube. Nor can the large percentage of young tubal specimens be attributed solely to the diagnostic skill of the surgeon, for in this case the chorionic vesicles falling into group 2 not only should contain an amnion and an embryo, but the whole conceptus should still be in a splendid state of preservation. This, however, is not true of any of these specimens, not even in the instance of twin tubal pregnancy already referred to, although in this case both chorionic vesicles are still implanted within the tube-wall throughout the whole area of contact.

The high incidence of hydatiform degeneration, especially in these groups, as well as the presence of infiltration of the wall of the tube, probably points directly to the real cause for this difference, which very likely is to be found in the absence of a nidus sufficiently favorable for implantation and growth. Nevertheless, development within the tube must proceed under more unfavorable mechanical conditions than within the uterus, for the latter probably undergoes expansion more spontaneously, *pari passu* with the growth of the conceptus. The tube, on the other hand, undoubtedly does not do so to the same degree, but becomes distended while its walls are being eroded by the trophoblast. Consequently (as so well illustrated in the case of No. 825, a twin tubal pregnancy), the tube, by virtue of its elasticity alone, must subject the contained, growing conceptus to considerable pressure. Nor is it only the elastic recoil of the tube-wall that the

growing conceptus must overcome, for the latter is periodically, or at least intermittently, subjected to the force exerted by tubal peristalsis whenever the tube attempts to rid itself of its unusual guest.

It is interesting that there does not seem to be the least evidence that the tubal musculature regularly undergoes a marked hypertrophy in these cases. Although I have examined carefully a series of specimens with regard to this point, I have never been able to find any indication of a protective reaction on the part of the tubal musculature or of the other tissues which were being invaded and destroyed by the proliferating trophoblast. Aside from a certain amount of hyperemia and of infiltration, which may be provoked by the presence of the conceptus within the tube, the latter seems to be largely passive, except for the intermittent attempts at tubal abortion. These may be provoked very largely by the destructive and irritative effects of the trophoblast, and only to a minor degree through mechanical distention incident to the increase in size of the conceptus, for this distention necessarily is an extremely gradual one. This, however, does not affect the fact that if more or less sudden hemorrhage rapidly distends the tube, the latter probably may be thrown into violent peristalsis through this agency alone and also undergo marked hypertrophy, under conditions of gradual distention by clot alone.

The tissue changes observed in the tubes were far less varied than those seen in the uterus. This was due partly to the absence of anything comparable to the decidua, and also to the absence of specimens that had been retained an unusually long time. Densely fibrous villi were not common; hyalin degeneration was rare, and calcification, except perhaps in its incipient stages, was not observed. Since the villi were scattered about in the blood-clot, coagulation necroses, or matting, were practically absent. Marked maceration changes were exceedingly common, however, and most evident where the surrounding blood was least well preserved. Almost all save a few specimens were contained in much clot, but since nothing comparable to a detachable decidua intervened between the implanted villi and the tube-wall, such villi frequently had been left *in loco*, even when they had undergone marked degeneration. In several specimens the degenerate muscle-cells, together with the degenerate trophoblast overlying them, from which they could not be distinguished, formed a considerable layer between the tips of the villi and the tube-wall. In others this layer appeared roughly like a decidua, although a layer of fibrinoid was never seen.

Aside from the many instances of splendid hydatiform degenerations, no other change than a fibrosis of the stroma of the villi was encountered. This fibrosis seemed to be more common in cases of severe infection, especially if evident also in the contained clot. Hofbauer cells, when present at all, were few, and instances of villi which were filled with them were not found. Aside from maceration, the changes in the stroma and in the vessels of the villi were limited to hydatiform degeneration and fibrosis. The syncytium and trophoblast often gave evidence of having been very active, however, a fact which may be due largely to the recurring accessions of fresh blood which bathed the chorionic vesicle, and which not only nourished but probably also stimulated both villi and syncytium to

proliferation. The tendency to decidual separation, with the onset of hemorrhage, would seem to make the conditions of the uterus much less favorable in this regard. Since most of the tubal specimens were very young, changes suggestive of lues were seen but once.

A comparison of the summaries of the findings in uterine and tubal abortions shows that a marked parallelism exists between them. The incidence of infiltration, of hydatiform degeneration, and of the presence of infiltration in cases of the latter, is remarkably similar. In 315 uterine specimens the incidence of infiltration of the decidua was 79.9 per cent, while infiltration of the tube wall was present in 78.8 per cent of the tubal specimens. In spite of the remarkable agreement between them, these percentages tell only a part of the truth, for they do not express the differences in intensity of infiltration or the presence of abscess formation. My impression is very definitely to the effect that, as a whole, the uterine infiltrations were far more severe than those of the tube. Many of the latter were so slight that one possibly might regard them as due to the pregnancy itself; not that normal pregnancy is necessarily accompanied by infiltration, but this might especially be the case if pregnancy occurred in abnormal surroundings, as it does in the tube.

Hydatiform degeneration was present in 31.2 per cent of the uterine and in 51.6 per cent of the tubal specimens. The higher incidence of hydatiform degeneration in the tubes may be due to the fact that three-fourths of all the tubal specimens fall into the first two groups, while only 57.1 per cent of the uterine do so. It is, of course, in the early stages of development that hydatiform degeneration is particularly frequent. Moreover, in comparing the incidence of hydatiform degeneration in the first four groups of the tubal and uterine specimens, we find that they are practically identical. That for the tubal is 41.4 per cent and that for the uterine specimens actually somewhat higher, or 42.1 per cent. Furthermore, the incidence of infiltration in all cases of hydatiform degeneration in the tubal specimens is 78.8 per cent and in the uterine 79.9 per cent. This shows not only that a parallelism between the two groups exists in regard to these changes, but that there is also a parallelism between the incidence of hydatiform degeneration and infiltration in the specimens in each group. It will be seen that in the first four groups the incidence of infiltration of the decidua in the uterine specimens is just about as much higher than infiltration of the tube in the tubal specimens as the incidence of hydatiform degeneration in the uterine specimens is higher than that in the tubal. This is not what one would expect *a priori*, but it is interesting that the greater incidence of hydatiform degeneration in the first four groups of the uterine specimens also is in harmony with the slightly greater incidence of the presence of infiltration in these specimens.

A similar parallelism is found to exist also between the incidence of infiltration in all the tubes, portions of which were examined, and its incidence in the decidua. It was 88.5 per cent in the former and 81.5 per cent in the latter. Hence, infiltration was found somewhat more commonly present in the tubes than in the decidua. This fact might seem to stand in contradiction to the relationship between infiltra-

tion and hydatiform degeneration just referred to, but such is not necessarily the case. It is accounted for, in a large measure, by the greater frequency of very poorly preserved deciduæ, which often make the determination of infiltration exceedingly difficult. The tubes, on the other hand, always are sufficiently well preserved, even if not perfectly so, to make a decision in this matter comparatively easy.

Although the series of cases showing hydatiform degeneration is unprecedentedly large, only 315 uterine and 104 tubal specimens were included in this study. This, of course, is too small a series for statistical purposes, but the relatively small size of these groups is compensated for to a remarkable degree by the very striking parallelism existing between them. This parallelism was found to exist not only between the incidence of hydatiform degeneration and of infiltration in the first few groups of the tubal and uterine specimens, but also between these two, and seems to indicate an extremely close relationship between infiltration and hydatiform degeneration. It is not unlikely, however, that it is not so much the presence of an infection itself as the changes induced by it, especially in the decidua, which may be the real cause for the advent of hydatiform degeneration.

DESCRIPTION OF SPECIMENS.

Readers will notice direct contradictions between the first and last portions of some of the following descriptions. This is due to the fact that the first portion of the description is based upon the gross appearance alone and the second upon histologic examination in addition. Things taken for embryonic rudiments were not always found to be such. Moreover, since Mall wrote the original protocols at widely different periods, some of the descriptive terms, among which are *fibrous*, *hyaline*, and *mucoid*, are not always used in exactly the same sense. With changing conceptions old terms also took on a new meaning. In the earlier protocols the term *dissociation* is used largely, if not wholly, in the sense of disintegration, but later it takes on the further idea of an uncorrelated or helter-skelter growth. Hence, in the earlier protocols a nodular embryo is said to be completely dissociated when it shows practically no differentiation whatever, having a homogeneous structure. The boundaries of any organs which may have been there have become effaced so completely that the individual organs can no longer be recognized.

The chief items in each protocol have been numbered for the sake of convenience. The figures mark (1) the name and address of the physician who was the donor, (2A) the dimensions of the abortus or chorionic vesicle, (2B) the length of the embryo or fetus, (3) the relevant clinical data, (4) notes on the gross specimen, (5) notes from the microscopical examination of a portion of the specimen, and (6) comments or some significant facts bearing upon the abortus. In some instances the dimensions of the abortus also represent those of the chorionic vesicle, both with free and matted villi. It was not the purpose to make a final diagnosis, but merely to call attention to facts which might throw an interesting sidelight upon the condition of the conceptus.

These protocols are not presumed to be complete descriptions of the specimens. To have made them such would have required considerably more revision and would often have been superfluous for the present purpose. In many cases the decidua and the chorionic vesicles really require further description, but since my attention was directed especially to them, and since their condition was particularly noted in the discussion, this deficiency in the protocols in no way prejudices the discussion.

The clinical histories we owe to the donors of the specimens; the original descriptions of the first 827 specimens were made by Dr. Mall himself, and the later gross descriptions are based on original notes by various associates of Dr. Mall, expecially Drs. Evans and Streeter. A few protocols were entirely rewritten by Dr. Wheeler at Dr. Mall's request.

GROUP 1.

No. 223.

(1) Max Brödel, Baltimore, Maryland.
(2) A 40×18×15 mm.
(4) At the point of attachment to the uterus the "fibroid mass" is very rich in villi. At its rounded end it is composed wholly of blood.
(5) The entire mass is surrounded by a layer of pus and necrotic decidua. In certain portions the intervillous spaces are filled with degenerating trophoblast. Where the trophoblast cells are far removed from the blood they are often necrotic. Some villi contain numerous Hofbauer cells and the stroma of many suggests a rapid degeneration of a rather fibrous non-vascular stroma.
(6) Marked infiltration of the decidua.

No. 290.

(1) S. P. Warren, Portland, Maine.
(2) A 50×15×10 mm.
(3) The specimen is said to be from a six weeks' gestation and the abortion is believed to have been induced by some emmenagogue.
(5) Sections were cut from different portions of this irregular mass and the remnants of a few villi, more or less infiltrated with leucocytes, were found. The bulk of the specimen is composed of decidua, mucous membrane, blood, fibrin, pus, and a few degenerate, necrotic villi.
(6) Marked infiltration of the decidua.

No. 323.

(1) V. Van Williams, Baltimore, Maryland.
(2) A 120×90×65 mm.
(4) The specimen was brought fresh to the laboratory and was found to be composed of enlarged villi and vesicles, most of which measure 5 mm. and a few fully 20 mm. in diameter. On one end the specimen is fibrous, and from there the villi extend into a bloody mass.
(5) The latter villi are very irregular in form, the mesoderm being hyaline, with numerous spindle-shaped nuclei. Between the villi there are great masses of necrotic trophoblast, some blood, and occasionally small masses of leucocytes. A few of them contain irregular clefts with cells, a clear fluid, and some coagulum.
(6) Slight infiltration and decided hydatiform degeneration.

No. 395.

(1) R. M. Pearce, Albany, New York.
(2) A 17×10×7 mm.
(3) Dr. Pearce writes: "I am sending you today a small encapsulated mass, found among curettage material, which appears to be a young ovum. I have refrained from attempting to determine definitely whether or not it contains an embryo, for fear of injuring a specimen which might be of value to you. The specimen was removed six weeks after the last menstruation. The uterus was emptied because the patient had eclampsia three years ago, and since then has had premature delivery of two dead children. The specimen is preserved in 10 per cent formalin."
(4) The whole mass was cut into serial sections, but no embryo was found.
(5) The sections show it to be composed of a few very degenerate villi and inflammatory decidua. Most of the villi are also fibrous and degenerate. A few, however, contain blood-vessels filled with blood; others contain obliterating vessels. The fragmentary wall of the chorion is very fibrous and the growth of the syncytium is very irregular. Undoubtedly the ovum "collapsed" some days before the uterus was scraped. The whole specimen is buried more or less in a slimy mass rich in leucocytes, which indicates that the uterine mucosa was markedly inflamed.
(6) Marked infiltration.

No. 565.

(1) Dr. W. A. Duvall, Baltimore, Maryland.
(2) A 50×20×20 mm.
(4) The solid mole appeared to be composed of mucous membrane of the uterus, fibrin, and blood. Its macroscopic appearance was much like that of the decidua.
(5) Sections show that it is composed almost entirely of decidua containing spaces lined with fibrinoid substance. These seem to be degenerating uterine glands. There are isolated villi which have undergone marked degeneration, and also a few buds of syncytium. Portions of the mass are very markedly degenerated, there being large groups of pycnotic nuclei in certain necrotic areas.

No. 644.

(1) Edwin B. Fenby, Baltimore, Maryland.
(2) A 45×29×35 mm.
(3) Patient a rather frail, nervous woman, 35 years old, who, since January, had been nursing a sick child. Last regular period December 15. February 15 she felt badly; menses appeared and continued with intermissions until March 9, when her physician curetted.
(4) The specimen consists of a pear-shaped mass, the small end of which includes long, delicate, bulbous villi, some of which had the appearance of blood-clot.
(5) Transverse section of the block shows that its interior is filled entirely with blood. Around the periphery are villi and remnants of a degenerate decidua showing very extensive inflammatory reaction. Most of the villi are necrotic, but a few of them still seem to be preserved. These have undergone fibrous and mucoid degeneration, and occasionally are capped by trophoblast which has undergone almost complete fibrinoid changes. Extremely degenerate portions of the chorionic wall are present throughout the clot.
(6) Marked infiltration and hydatiform degeneration.

No. 698.

(1) N. E. B. Iglehart, Baltimore, Maryland.
(2) A 50×20×13 mm. Decidual cast with some syncytium and trophoblast.
(3) Patient 38 years of age, mother of three children, this being her first abortion. Last period April 11 to 14; abortion June 6. No history of infection.
(4) The specimen looks like a solid irregular mole and measures 50×20×13 mm. On sectioning, it is found filled with blood, with a space between the inner wall and the decidua.
(5) Transverse sections of the same suggest that it is composed entirely of decidua and clot. What appears to be the chorionic wall is the decidua capsularis, the interior of which is filled entirely with blood. Between the slight traces of the chorionic wall and the blood-clot containing them a few small masses of syncytium and trophoblast are found. The ovum apparently has been destroyed almost entirely, so that the sections remind one very much of the type of pregnancy found in the uterine tube.
(6) Marked infiltration.

No. 749.

(1) Dr. G. C. McCormick, Sparrows Point, Maryland.
(2) A 100×100×100 mm.
(3) Patient aged 19 years, married five months and thought she was pregnant four months. Symptoms resemble placenta prævia. Irregular. Hemorrhage for two months.
(4) The specimen is a hydatiform mole in several pieces, which, when placed together, form a large mass 100 mm. in diameter. The exterior is covered with numerous wart-like prominences from 1 to 3 mm. in diameter, and with hypertrophic villi, some of which are 40 mm. in length and over 10 mm. in diameter. Most of these are attached to the main wall of the chorion by thread-like processes. No embryo was found.
(5) The villi are very large and most of them have undergone mucoid degeneration, the interior not staining well by any of the methods used. The trophoblast is mostly necrotic, but at points it seems to be active. The mesenchyme of some of the villi appears to be more or less fibrous and contains large nests or groups of cells appearing to come from degenerating blood-vessels. There are also masses of Hofbauer cells in these villi, which are covered by a fairly active trophoblast.
(6) Hydatiform degeneration; decidua absent.

No. 861.

(1) C. W. R. Crum, Brunswick, Maryland.
(2) A 35×25×15 mm.
(3) Woman, aged 40, married 16 years. Eleven pregnancies: eight full-term children; abortion between first and second child; two abortions since last child, now 2½ years old. Last menstrual period February 14 to 18 and abortion March 29 following. No infection apparent in condition of uterus. No venereal diseases. Family fertile.
(4) The specimen consists of two irregular masses which measure 11×10×5 mm. and 35×17×11 mm., respectively. The large mass is firm and at several points villi, which attain a length of 7 mm., protrude from it.
(5) These have undergone fibrous as well as mucoid degeneration and are matted together by an inflammatory exudate which contains great masses of leucocytes. The trophoblast is scanty.
(6) Severe infection; some hydatiform degeneration.

No. 866.

(1) Thomas S. Cullen, Baltimore, Maryland.
(2) A 26×20×9 mm.
(3) Patient aged 36, married 17 years. Seven pregnancies: children 16, 14, 10, and 7 years; miscarriages 1910, 1913, and this one, March 16, 1914. Patient missed no menstrual period. In July 1913 there was flooding and afterwards a little continuous bleeding until the abortion. Last periods March 6 and one month before abortion. Uterus slightly enlarged. No venereal diseases.
(4) The specimen measures 26×20×9 mm. and is covered with villi, which are so flattened over the greater part of the surface as to form an almost smooth exterior, but a portion of the circumference of the specimen supports thin, shaggy villi from 5 to 7 mm. in length. The ovum is solid, and on being cut open no chorionic cavity is apparent.
(5) The completely degenerated villi which are outlined by fibrinoid only are matted together with fibrin. The extensive trophoblast is necrotic. It appears as though the specimen had been completely detached for some time before the abortion, and that it must be far older than the history suggests.
(6) Necrotic early confluent hydatiform degeneration.

No. 914.

(1) Benjamin O. McCleary, Baltimore, Maryland.
(2) A 40×10×10.
(3) First pregnancy of a woman aged 24 years, married in 1910. Last menstrual period May 12 to 16, 1914, and abortion June 17 following. Condition of uterus negative. Venereal diseases negative. Fertility of family good.
(4) The specimen is a firm elongated abortus 40×10×10 mm.
(5) It is composed of a large piece of hemorrhagic and inflamed decidua, scattered through which are large strands of fibrinoid substance and a few villi which have undergone mucoid degeneration. There is some trophoblast.
(6) Marked infiltration.

No. 920.

(1) Hiram Fried, Baltimore, Maryland.
(2) A 50×50×50 mm.
(4) The specimen consists of large hemorrhagic fragments which together constitute a mass about 100 mm. in diameter. One of these fragments forms a shell 50 mm. in diameter, which contains a cavity about 30 mm. in diameter.
(5) Sections through its wall show it to be composed of blood-clot, throughout which are scattered occasional villi more or less completely dissociated. In some of them the mesenchyme is fibrous. Some of the remnants of the villi are surrounded by two zones of nuclei—the remnants of the two epithelial layers—and lie in masses of leucocytes, thus giving an appearance such as is frequently seen in tubal pregnancy.
(6) Severe infection.

No. 929.

(1) R. A. Hammack, Manila, Philippine Islands.
(3) Patient aged 22 years. Two pregnancies, both ending in abortion, this being the second. Normal period was delayed about one month before abortion. No history of infectious diseases.
(4) The specimen consists of numerous small fragments of blood, measuring together about 30 mm. in diameter,
(5) Sections through a piece of what appears to be chorionic tissue proved it to be a scrap of uterine mucous membrane and a large clot of blood, a portion of which is fairly rich in leucocytes. A few very small fibrous villi are found, and attached to them are very small, irregular clumps of trophoblast.

No. 941.

(1) John Wade, Baltimore, Maryland.
(2) A 30×20×10 mm.
(4) The embryonic mass measures 60×40×20 mm., and sections, as well as careful inspection, show it to be composed mostly of decidua. On one side of it an ovum, measuring 30×20×10 mm., was found, completely filled with dense reticular magma, and a small vesicle 3

mm. in diameter was closely adherent to the chorion. On opening, it appears to contain granular débris. In general its walls are tough, and at its attachment to the chorion there is a small nodule, probably the umbilical vesicle. The villi of the ovum are well formed, but long and slender.

(5) Sections show that they have undergone mucoid degeneration and are matted together with a great mass of inflamed decidua.

(6) Marked infiltration.

No. 994.

(1) A. F. Ries, Baltimore, Maryland.

(2) A 68×26×24 mm.

(3) Patient aged 25 years, married about 7 years. Four pregnancies: normal birth five years ago, another three years ago, an abortion in May 1913, at four months, and this abortion. Beginning of last period, September 5, 1914. Abortus protruding from mouth of cervix November 25; curetted November 28. Fertility of family good.

(4) The abortus measures 68×26×24 mm. and consists of villi and a pointed hemorrhagic mass. Probably this lay within the cervix. The villi are of very irregular shape, some of them long and shaggy, and have attached to them numerous opaque nodules which, in some cases, are more than a millimeter in diameter—the trophoblastic nodules or appendici durate.

(5) Sections of the mole show the villi to be matted together with a large mass of fibrinoid substance, to contain considerable numbers of leucocytes, and to have undergone mucoid degeneration in many cases. Between the villi there is more or less fresh blood, within which are buds of syncytium showing a quite active growth.

(6) Marked infiltration and early confluent hydatiform degeneration.

No. 1015.

(1) A. F. Ries, Baltimore, Maryland.

(2) A 41×37×31 mm.

(3) The patient had a miscarriage 10 years ago, this being the third one. Menses appeared "on and off" from July to November 26, with alternate weekly flowing. On the latter date the bleeding was profuse and abortion occurred on December 7.

(4) Specimen consists of "a hard, firm mass, which on section gives no evidence of pregnancy. Apparently a tumor."

(5) Microscopic examination reveals a mass of necrotic dicidua and villi.

GROUP 2.

No. 20.

(1) J. W. Williams, Baltimore, Maryland.

(2) A 20×14.6 mm.

(4) From the exterior the ovum appears to be quite normal, with well-developed villi, which are represented better near one end and look somewhat swollen and matted. Within the cœlom, however, there is a great quantity of magma, within which were buried several nodules. These were removed and sectioned.

(5) Sections revealed no amnion lining the chorion, and the small nodules are only masses of magma which contain no cells. The villi, the stroma of which is clear, are covered by the usual quantity of trophoblast. They are non-vascular and slightly macerated. At isolated points between the villi are small masses of a granular substance which present the appearance of coagulated albumin.

(6) Probably early hydatiform degeneration. Decidua not included.

No. 21.

(1) T. S. Cullen, London, Canada.

(2) Chorion 12×9×5 mm.; vesicle within, 5.5×3.5 mm.

(4) From external appearances, the ovum is apparently normal, with well-developed villi branching a number of times. Upon opening the chorion it was found that the cœlom was filled with a quantity of magma réticulé, within which was embedded a very large transparent vesicle.

(5) The main vesicle is brought into contact with the chorion by means of a small secondary vesicle; both are inclosed by a layer of mesoderm within which are numerous blood-islands. The smaller vesicle is lined with a layer of large, spindle-shaped cells. The cavities of both vesicles contain cells which are scattered throughout the magma. There are no blood-vessels in the chorion. The syncytial layer is diminished but well formed upon the tips of the villi. Here in many places it accumulates in layers, forming masses. Both chorion and yolk-sac are very degenerate. The amnion is absent. The yolk-sac has finger-like extensions, some of which may represent cyemic remnants, but this is unlikely.

(6) Decidua not included.

No. 29.

(1) W. D. Booker, Baltimore, Maryland.

(2) A 30×30×30 mm.

(4) The ovum was covered by a few atrophic villi, and within no trace of an embryo could be found. The cœlom was filled with a cheesy mass of granular magma as usual. After the magma had been searched through most completely, the portions of the chorion which might have a remnant of the embryo attached were stained and cut into serial sections, but nothing whatever could be found.

(5) Sections of the chorion show that its walls and villi are fibrous and thickened. The amnion is absent. A few villi show mucoid degeneration, but the stroma of most of them is fibrous and macerated. Some few show very intense so-called granular hypertrophy or, better, hyperplasia. Many are non-vascular. Appendici durate are numerous, and groups of degenerate villi are contained within degenerate masses of trophoblast. The latter and fusion of the villi are most numerous opposite areas of greatly thickened chorion. Leucocytic infiltration is wholly absent.

(6) Decidua absent.

No. 55.

(1) W. T. Watson, Baltimore, Maryland.

(2) A 35×20×14 mm.

(3) Last period, January 18 to 22; abortion March 13.

(4) The specimen is a very fleshy mass containing a sharply defined, spherical cavity, 15 mm. in diameter, with smooth walls, but no trace of an embryo.

(5) Sections showed that the sharply defined cavity was the cœlom, as its walls were formed by the chorion. The thick, fleshy mass is composed of villi, syncytium, blood, fibrin, and pus. The fibrous walls of the chorion, which contain remnants of blood-vessels and decidua, are invaded by leucocytes and partly disintegrated. The main bulk of the villi and syncytium stains poorly and appears necrotic. The stroma is fibrous, more or less degenerate, invaded by leucocytes, and covered in part by very active syncytium. The cavity of the cœlom is partly filled with a granular magma, in which are embedded some cells. The whole picture is that of severe infection. Very little decidua is present, and this is fibrous, infiltrated, and necrotic.

(6) Marked infiltration of the decidua; severe infection.

No. 70.

(1) C. M. Ellis, Elkton, Maryland..

(2) A 45×30×28 mm.

(3) Patient had regular periods until July 28, 1896, when she missed one. On October 20 she had a profuse hemorrhage; after this there was no flow until February 4, when this specimen passed.

(4) The gross specimen is very solid because of the large amount of clot at one end, at which groups of characteristic hydatids are found.

(5) Sections show it to be composed of a mass of distended and cystic chorionic villi undergoing mucoid de-

generation characteristic of hydatiform mole. Between the villi there is a large quantity of blood, with an excessive amount of trophoblast, which on one side forms a large mass. Within the center of the specimen there is a small collapsed chorion with poorly defined walls. The specimen was not cut into serial sections, so it is impossible to state whether or not the embryo has been entirely destroyed, but in all probability this was the case.

(6) Marked infiltration; hydatiform degeneration.

No. 71.

(1) G. H. Whitcomb, Greenwich, New York.

(2) A 10×9×5 mm.

(3) Dr. Whitcomb writes: "The specimen is from a woman 23 years old, who had been married three months before the abortion occurred. She had been troubled with chronic cystitis and endometritis, but menstruated regularly. After marriage she had two menstrual periods, but the third failing to appear, she concluded she was pregnant. Seven days after the lapsed period she slipped while descending the stairs, and this was followed by some tenesmus. Four days later I examined her and found a free flow of unstained mucus from the uterus, with tenderness, hyperæmia of the pelvic organs, and irregular pains. An examination of the urine on the following day showed it to be loaded with pus and blood, and it contained also the ovum. Two days later the decidua was discharged. The specimen was preserved in 50 per cent alcohol. Shortly after this the woman became pregnant again and went to full term." From the above data the abortion occurred 40 days after the beginning of the last menstrual period.

(4) When the ovum came to the laboratory three years later it was well preserved and had not been opened. The villi were even but slightly deficient on one side. Within there was a small amount of magma réticulé, and at the bottom of one of the halves of the chorionic vesicle there was found a very small nodule.

(5) The nodule, which was embedded and cut into sections 20 microns thick, appears to be of foreign material. The syncytium of the chorion is normal, except for maceration changes. There are no blood-vessels.

(6) Decidua absent.

No. 82.

(1) H. F. Cassidy, Baltimore, Maryland.

(2) A 75×60×40 mm.

(3) "Last period began June 3, 1896, and the tumor was passed March 8, 1897, 40 weeks later."

(4) The specimen was brought to the laboratory fresh. It was pear-shaped, purulent on the pointed end, and the interior appeared to be composed of fresh blood-clots.

(5) Sections of the large, solid mass, mainly composed of clot, show that it contains a collapsed ovum with folds of the fibrous chorion extending throughout the specimen. On one side of the specimen there are a few slender villi. Most of the folds of the chorion are composed of double walls, usually in apposition and occasionally completely blended. All of the chorionic membrane and some of the few remaining villi are composed of relatively well preserved, dense, fibrous connective tissue. There is no amnion. Along the main central body of the chorion large quantities of fresh blood are found. The rest of the tumor is composed of blood-clots and nests of leucocytes and of syncytium. The syncytial nests, located in great part along the chorion, are preserved better where they come in contact with fresh blood, but are necrotic elsewhere. At no point does the syncytium invade the chorionic membrane. It is impossible to interpret this specimen without assuming that the chorion continued to grow long after the death of the embryo.

(6) Infection. Decidua absent.

No. 93.

(1) H. F. Cassidy, Baltimore, Maryland.

(2) A 40×20 mm.

(4) The specimen contained a cavity into which projected a large tongue of fleshy tissue. Within the latter there is a blood-clot, as well as a sharply defined cavity.

(5) Sections through different portions of the specimen show the outer sac to be the decidua and the tongue of tissue, the chorion. Within the central cavity of the tongue (cœlom) lies the greatly macerated amnion. It can not be stated definitely whether or not remnants of the embryo are present, as the specimen was not cut into serial sections. The walls of the chorion are thickened and irregular, and around it are packed hypertrophied villi, with great quantities of blood between them. Covering the villi is a layer of blood and fibrin separating them all from the decidua. The latter is fibrous and shows decided general infiltration.

(6) Marked infiltration.

No. 123.

(1) H. J. Boldt, New York.

(2) Ovum 17×14 mm., with vesicle 1.8×1.5×1 mm.

(3) "The last menstrual period prior to the abortion occurred August 14 or 15. Abortion September 10. The whole ovum was placed in 95 per cent alcohol within 10 minutes after abortion."

(4) The entire ovum was covered with villi, apparently normal, but surrounded by a layer of pus and blood. After opening it, the cœlom was found filled with a mass of coagulated fibrinous albumin, the magma réticulé, within which no embryo could be seen. The two halves of the ovum were then stained, which brought out prominently a small vesicle embedded in the magma. This vesicle had a rounded opening upon one side, with a long pedicle upon the other, which extended towards, but was not attached to, a small mound on the inside of the chorion. Vesicle and chorion were both cut into serial sections.

(5) The sections of the vesicle appear to be those of the normal umbilical vesicle. The opening on the side is undoubtedly due to a tear, judging by its broken edges.

(6) Marked infiltration of the decidua.

No. 147.

(1) A. C. Pole, Baltimore, Maryland.

(2) Ovum 30×27×20 mm.

(3) "Last period began January 1, and the specimen was discharged March 23."

(4) The ovum is only in part covered with villi, the remaining portion of the chorion being clear and transparent. The cœlom is completely filled with magma, which has turned very white in the alcohol in which the specimen was preserved. On one side of the chorion and closely attached to it, there is a small vesicle and an irregular mass which may represent the remnants of the embryo. The magma contains some degenerating erythroblasts.

(5) Sections of the chorion show that the mesoderm is very fibrous and rich in cells. The vesicle within is about a millimeter in diameter, and is located 2 mm. from the chorion, but not attached to it. Its walls are composed of only one layer of cells on one side of the vesicle, while on the opposite side there is a second layer of mesoderm 0.5 mm. thick, in which are embedded numerous blood-vessels filled with blood. There are also a few blood-vessels in the chorion in the immediate neighborhood of the vesicle, which are likewise filled with blood.

(6) Decidua not included.

No. 153.

(1) E. W. Stick, Glenville, Pennsylvania.

(2) A 50×20×20 mm.

(3) Last period began April 30; abortion July 15.

(4) The mass is pear-shaped and proves to be a ruptured chorion partly inverted and embedded in an organized clot of blood and fibrin. The chorion is, of course, ruptured, and at the point of rupture there is a mass of blood which forms the large end of the pear-shaped mass. There is no amnion within the degenerate chorion, nor could the

embryo be found. A portion of mucous membrane of the uterus is attached to the chorion. This shows marked inflammatory infiltrations and fibrosis.

(5) The villi of the chorion are swollen, show marked mucoid degeneration, and the stroma of many of them has undergone a kind of coagulation necrosis. The stroma is non-vascular and Hofbauer cells are common. The trophoblast cells are generally normal in appearance. There are many leucocytes, especially within the decidua, considerable areas of which are purulent. Except for relatively small regions, the chorionic membrane, although devoid of endothelium and disintegrated in places, is but slightly invaded, in spite of the fact that it is surrounded in part by a narrow zone of leucocytes.

(6) Marked infiltration and hydatiform degeneration.

No. 173.

(1) L. R. Jump, Tesla, California.

(2) A 25×15×10 mm.

(3) Marriage December 15, 1899; last menstrual period December 20; abortion February 12. Several other masses about the same size, which appeared to be composed of blood-clots, were passed at this time.

(5) Upon section the specimen was found to be composed of a collapsed ovum well covered with villi. The chorionic membrane is almost wholly destroyed. Within the cavity of the cœlom there is an irregular, ill-defined mass of blood-clot. The small sclerotic fragments of accompanying decidua are markedly infiltrated.

(6) Severe infiltration; early hydatiform degeneration.

No. 181.

(1) D. S. Lamb, Washington, District of Columbia.

(2) A 18×18×10 mm.

(4) The ovum is filled with reticular and granular magma, and no remnants of an embryo could be found, although every particle which might contain it, with the adjoining chorion, was cut into serial sections.

(5) The mesoderm of the chorion and villi is edematous and shows mucoid degeneration. The epithelial covering is poorly developed, often being composed of but one layer of cells.

(6) Decidua absent.

No. 185.

(1) F. R. Sabin, Baltimore, Maryland.

(2) A 40×25×15 mm.

(3) The abortion occurred seven weeks after the beginning of the last menstrual period.

(4) The specimen was brought to the laboratory in formalin. Upon opening, it was found that the cœlom was filled with reticular and granular magma. No trace of an embryo could be found, although the entire ovum was cut into serial sections.

(5) The main wall of the chorion is decidedly thickened and completely filled with leucocytes with nuclei in all stages of fragmentation. They form a fairly sharp border on the cœlom side, making the chorion appear as the wall of an abscess. The leucocytic invasion must have been merely from the cœlom side, for the villi are not affected to any extent. Some of them are edematous; others show marked mucoid degeneration.

(6) Severe infiltration of the decidua and infection of the chorionic vesicle.

No. 190.

(1) C. M. Ellis, Elkton, Maryland.

(2) A 25×22×12 mm.

(4) The ovum is filled with magma, within which no trace of an embryo can be found, although the entire specimen was stained and cut into serial sections.

(5) The chorion and villi are apparently normal, except for slight maceration and hydropic degeneration. Some villi contain blood-vessels.

(6) Decidua absent.

No. 191.

(1) C. M. Ellis, Elkton, Maryland.

(2) A 16×11×11 mm.

(3) The specimen is from a supposedly induced abortion, and had been in Dr. Ellis's collection for 10 years before it was sent to us.

(4) The cavity of the specimen is filled with a small amount of granular magma, and the villi are matted. No embryo was found.

(5) The chorionic wall is somewhat fibrous, as are also the cores of the villi. The trophoblast may be normal, and there is no indication of surrounding inflammation.

(6) Probably macerated, induced. Decidua absent.

No. 195.

(1) D. S. Lamb, Washington, District of Columbia.

(2) A 30×30×30 mm.

(4) The specimen was well covered with villi and contained some reticular magma. No embryo could be found, although the entire ovum was cut into sections. The mesoderm of the chorion appears normal and is rich in blood-vessels filled with blood, but that of the villi is non-vascular and rather clear.

(6) Dedicua not included.

No. 204.

(1) D. S. Lamb, Washington, District of Columbia.

(2) A 14×12×8 mm.

(4) The specimen, said to be three weeks old, was found filled with a mass of granular magma.

(5) The whole ovum was stained and cut, but no trace of an embryo could be found. The chorion and villi appear normal.

(6) Decidua not included.

No. 233.

(1) W. P. Miller, Hagerstown, Maryland.

(2) A 70×45×40 mm.

(4) The irregular mass appears to be an ovum filled with blood.

(5) Sections, however, show that there is a mixture of distorted villi, blood, syncytium, decidua, and pus. Most of the villi are completely degenerate, their place being occupied by detritus mixed with leucocytes. The decidua shows marked infiltration and fibrosis.

(6) Severe infiltration.

No. 243.

(1) Max Brödel, Baltimore, Maryland.

(2) A 30×20×10 mm.

(4) The specimen is pear-shaped, with smooth, thin walls, over which are scattered a few thin villi.

(5) The latter and the chorionic membranes show maceration changes.

(6) Normal macerated. Decidua absent.

No. 255.

(1) Max Brödel, Baltimore, Maryland.

(2) A 20×20×10 mm.

(5) The villi are matted; some are fibrous, but others mucoid. At points the syncytial layer is well mixed with leucocytes, which also have invaded some of the villi as well as the mesoderm of the non-vascular chorion. The whole chorion was cut into serial sections, but no trace of an embryo or remnants of amnion were found.

(6) Infected. Decidua not included.

No. 278.

(1) E. M. Stanton, Albany, New York.

(2) A 6×4 mm.

(3) This specimen was found accidentally in curettings from a woman supposed to have chronic endometritis following pregnancy. There is nothing in the history by which the age of the specimen could be estimated. Before

the specimen was sent, part of it had been cut into sections, and the accompanying record stated that no embryo had been found.

(4) The part received at the laboratory contained a chorionic vesicle 3×2.5 mm., filled with magma, in which was a cavity about 1.5×1 mm.

(5) Sections showed that the cavity was natural, but not sharply defined, with nothing to indicate that an embryo had been in it. On the contrary, it was found that the magma réticulé was filled with a loose network of mesoderm cells, which unite one side of the chorion with the other. These cells are directly continuous with those of the mesoderm and resemble them in every particular. At one point there is a small group of epithelial cells, which may represent what was originally the embryo. Otherwise the chorion and villi are normal in appearance, being encapsulated in decidua which has in it some uterine glands. All in all, this specimen reminds one very much of Peters's ovum. There is some general infiltration in the decidua, and also a few accumulations of leucocytes are present in the mucosa. The specimen shows some maceration. We consider this specimen one in which the embryo has been destroyed, leaving a normal chorion.

(6) Slight infiltration.

No. 280.

(1) Thomas H. Magness, Baltimore, Maryland.

(2) A 40×25×25 mm.

(4) Within the mole, which is said to be five or six weeks old, there is an irregular cavity with smooth walls measuring 10×5×5 mm.

(5) Sections were cut of the thick hemorrhagic walls. These showed the walls of the chorion to be thin, with considerable reticular magma attached to them on the inside. No amnion was found. The villi, though not very large, are well developed, contain remnants of blood-vessels, and are covered with a mass of necrotic syncytium. The blood and mucus over the syncytium is filled with leucocytes which invade the mesoderm of many of the villi. The latter are very degenerate and are surrounded by severe leucocytic accumulations. The exterior of the clot which surrounds the villi is formed by a thick wall of densely packed leucocytes, which replaces the decidua almost completely. It is probable that the whole ovum had been dead for several weeks, the embryo and amnion having been destroyed entirely.

(6) Severe infection and rapid degeneration.

No. 299.

(1) W. B. Burns, Memphis, Tennessee.

(2) A 16×12×10 mm.

(4) The specimen, which apparently is normal, is filled with a mass of dense magma réticulé.

(5) Serial sections failed to show even a remnant of an embryo. The structure of the chorion and villi is normal, possibly a little edematous from maceration. No blood-vessels are present.

(6) Possibly a very early hydatiform degeneration. No decidua.

No. 310.

(1) W. T. Watson, Baltimore, Maryland.

(2) A 18×14×14 mm.

(4) The specimen is covered with villi, which on section proved to be markedly changed.

(5) The mesoderm has undergone mucoid degeneration and contains vacuoles in which there are free nuclei. The epithelial layer is irregular. The villi are vacuolated, contain some blood-vessels, and are covered with a fairly active and preserved trophoblast. The interior of the ovum is filled with magma réticulé, at the periphery of which degenerated erythroblasts—Hofbauer cells of Minot—are found. Many of the villi also contain numerous Hofbauer cells. There is no trace of embryo or of the amnion. The degenerate decidua is decidedly infiltrated.

(6) Marked infiltration; hydatiform degeneration.

No. 358.

(1) C. M. Swett, Bangor, Maine.

(2) A 30×16×10 mm.

(3) Pregnancy of six weeks' duration.

(4) The outer surface of the ovum is smooth, and the specimen runs out into a pedicle which undoubtedly was attached to the uterus.

(5) Sections show that the villi are matted together, and that much blood and syncytium is between them. Around this there is a fibrous decidua containing many leucocytes and necrotic areas. The mesoderm of the chorion is swollen from maceration, and some of the villi are rather fibrous. No blood-vessels are present in the latter. The cœlom measures 8×6×6 mm. and is lined by a layer of reticular magma, but contains no trace of amnion or embryo.

(6) Marked infiltration.

No. 435a.

(1) F. A. Conradi, Baltimore, Maryland.

(2) A 30×20×15 mm.

(4) The ovum is filled with a dense reticulated magma and contains a cavity measuring 20×15×10 mm.

(5) The ovum, which was cut into serial sections, contains no embryo or amnion. The villi are non-vascular and atrophic, having undergone degeneration, partly mucoid and partly fibrous. They are covered with very little trophoblast. The chorionic wall is fibrous, and numerous cells are scattered throughout the dense magma. The degenerate remnant of decidua which is present suggests the presence of an infection.

(6) Suggestive of hydatiform degeneration; too little decidua.

No. 593.

(1) Abraham Poska, Hobson, Montana.

(2) Ovum 30×25×20 mm.

(3) Patient said she did not know she was pregnant having had her last menstrual period four weeks before the abortion.

(4) The ovum, which is covered with large villi, has a pedicle. The entire specimen measures 45×25×20 mm. The interior apparently is solid, and upon cutting it open no cavity is found, nor can a remnant of the embryo be seen.

(5) Sections of the pedicle show it to be markedly infiltrated, much blood and pus being scattered through the tissue. Several villi present here are degenerate, but those on the main body of the specimen are large and beautifully branching. Sections through these include their points of attachment, which consist of chorionic membrane practically destroyed by an invasion of leucocytes. Apparently an abscess destroyed the main body of the ovum almost entirely. The villi are disintegrating, for the mesenchyme is breaking down. The spaces are becoming larger and the nuclei fewer. The stems of the villi are being invaded by leucocytes, but there are small remnants of embryonic blood-vessels. The trophoblast is scanty.

(6) Marked infiltration and early hydatiform degeneration.

No. 594.

(1) Abraham Poska, Hobson, Montana.

(2) A 47×40×30 mm.

(3) There were several severe hemorrhages previous to the abortion, which were interpreted by the patient as frequent menstrual periods. She passed much clotted blood.

(4) The specimen, which is solid, is composed mostly of blood containing a solid ovum with a long, narrow, slit-like cœlom. No remnant of the embryo could be found.

(5) The folds of the swollen, hemorrhagic chorion have coalesced in certain areas, and at points numerous large ridges of mesenchyme have grown into the cœlom. These folds contain a great many Hofbauer cells. The chorionic

wall is thickened, edematous, and also contains some Hofbauer cells and blood-vessels filled with blood. A very few villi are present, and these are undergoing mucoid degeneration, but most of them are fibrous. The degenerate, transformed remnants of the decidua show extensive leucocytic infiltration, but in general the leucocytes do not reach to the chorionic wall. There is some coagulation necrosis.

(6) Marked infiltration.

No. 596.

(1) T. C. Smith, Washington, District of Columbia.

(2) A 25×20×15 mm.

(3) Last menstruation February 21, this being her first pregnancy. Patient claimed at the time of her abortion that this was her regular menstrual period.

(4) The ovum is covered almost entirely with villi which branch three or four times, and which on one side are much less numerous and atrophic. Upon opening the ovum it was found to be lined with a smooth surface, but although examined under the most favorable conditions in direct sunlight, no trace of an embryo could be found. On one side there appeared to be a small mass of reticular magma, and it was thought possible that the embryo might be within it. Since the specimen was perfectly white and transparent, however, it would have been almost impossible to miss the embryo had it been there.

(5) Upon section, the wall of the chorion appears to be normal in structure, but the villi have undergone partial mucoid degeneration. The trophoblast is not plentiful, but there are numerous nodules of it and tufts of syncytium. Within the nodules of trophoblast there is some fibrinoid and, often, scattered groups of vacuolated syncytium. Although the entire ovum was embedded in paraffin and cut into serial sections, no embryo was found. Fine examples of vessels in the last stages of degeneration are found in some of the villi. No decidua is included in the sections.

(6) Early hydatiform degeneration. Decidua absent.

No. 606.

(1) C. S. Parker, Baltimore, Maryland.

(2) A 18×13×8 mm.

(4) Part of the ovum is covered with branching villi, quite uniform in size and 2.5 mm. long. The entire specimen projected would measure about 18×13×8 mm. Viewed in direct sunlight, no trace of an embryo could be seen, but it may have been lost with the missing portion of the specimen.

(5) The entire specimen was cut into serial sections, which do not show any trace of an embryo. However, the chorion and villi are so badly macerated that it is difficult to make out any structure whatever. In fact, even the nuclei of the chorionic membrane have disappeared entirely, leaving only a fine reticulated structure.

(6) Almost complete lysis. Decidua not included.

No. 661.

(1) G. L. Wilkins, Baltimore, Maryland.

(2) A 45×25×25 mm.

(3) Patient is a recently married woman who had missed one period. No history of uterine or venereal disease. Patient decidedly anemic.

(4) The specimen is a smooth, pear-shaped mass, with a stem 25 mm. long. The walls are thick and spongy, and within there is an irregular cavity about 8 mm. in diameter, which is lined with a smooth membrane and filled with delicate reticular magma. It was thought that the embryo might be present.

(5) Sections show that the very thickened fibrous chorion is encircled by a large hemorrhagic mass containing many villi and buds of syncytium, surrounded by a thin layer of markedly inflamed decidua. The chorionic wall, which is markedly fibrous, contains numerous blood vessels filled with bood. The magma is very dense and directly in contact with the chorionic wall. In the center of the cœlom the magma is partly granular and contains a few Hofbauer cells. No trace of an amnion could be found. Most of the villi are decidedly fibrous, but a few show mucoid degeneration, with fenestration of the stroma. The former retain some vessels.

(6) Marked infiltration.

No. 663.

(1) Lindsey Peters, Columbia, South Carolina.

(2) A 30×15×10 mm.

(3) Patient 30 years of age. Five pregnancies: first, term, child still living; second, twins at term, one child living; third, stillbirth at term; fourth, term, child living; fifth resulted in this abortion. Last menstrual period, January 18 to 22; abortion, March 15. No infection of uterus; position normal.

(4) The specimen is a smooth, almond-shaped body containing a small cavity filled with reticular magma. No remnants of an embryo could be seen. The specimen had been opened when received.

(5) The chorion and some of the villi are fibrous; others are mucoid and are attached to the inflamed decidua by means of an extensive blood-clot. There is very little fibrinoid substance or trophoblast, but numerous buds of syncytium intermingled with fibrin and many leucocytes. No amnion could be found.

(6) Marked infiltration and some hydatiform degeneration.

No. 702.

(1) George H. Hocking, Govans, Maryland.

(2) A 50×20×20 mm.

(3) Patient is 42 years old and has two children, the younger aged 6 years. Last menstrual period April 16, but on May 20 there was a slight flow of a dark color. On June 3 the mass was expelled without pain or special discomfort.

(4) The specimen apparently is solid, measuring 50×20×20 mm. It appeared to be composed of numerous clots and had a smooth external surface. Within it was composed mostly of blood and contained a cavity a centimeter in diameter, filled with reticular magma. In the center of the magma there was an opaque body, 5 mm. in diameter.

(5) Sections of the specimen do not show any remnants of an embryo or amnion. The chorionic wall is loosened up and destroyed almost completely for a considerable extent. Large quantities of blood are present between the villi. The entire mass is encircled by an intensely inflammatory necrotic decidua. The non-vascular villi mostly have undergone mucoid degeneration. The intervillous spaces are filled with blood and the trophoblast is necrotic.

(6) Intense infiltration.

No. 723b[3].

(1) L. L. Iseman, Chicago, Illinois.

(2) A 45×25×25 mm.

(4) Chorionic wall smooth and thin.

(5) Sections show it to be composed of necrotic membrane and a few necrotic villi. The intervillous spaces are engorged with fresh blood. A necrotic, somewhat infiltrated decidua encircles the chorion, marked off on the inner side by a layer of fibrinoid substance. No trophoblast.

(6) Marked lysis of the decidua and slight infiltration.

No. 736.

(1) R. B. Varden, Mercersburg, Pennsylvania.

(2) A 35×16×16 mm.

(4) Almond-shaped hard mass measuring 35×16×16 mm., and entirely filled with hard, coagulated blood. Towards one end there is a cavity 7×4 mm., lined with smooth membrane.

(5) This cavity is in a collapsed ovum filled with reticular magma and some blood-vessels in the chorion which

do not stain with the Heidenhain method. The chorionic wall and most of the villi are fibrous and locally thickened. The latter are degenerate, surrounded by necrotic zones, and anastomose freely. A strand of reflected mesenchyme bridges one end of the cœlom. A few buds of syncytium protrude into the extensive mass of surrounding blood. The entire specimen is encircled by considerable fibrous substance, as well as by an outer, markedly inflammatory, and in part necrotic decidual zone.

(6) Marked infiltration.

No. 750.

(1) J. M. Jackson, Pittsburgh, Pennsylvania.

(2) A 20×15×15 mm.

(3) Patient aged 23 years; married March 25, 1913; no previous pregnancies; last menstrual period June 6 to 10, 1913, and abortion August 19 following. First intercourse two weeks after June 10 (Jewish law). Conditions of uterus normal; no veneral diseases. Family fertile.

(4) The entire mass consists of a blood-clot, decidua, and a large piece of an ovum, which together measure 45×30×25 mm. The ovum alone measures 20×15×15 mm., and is covered with numerous knob-like villi. The main wall of chorion is very thin and transparent, and when opened was found to be lined with a delicate membrane. One half of the specimen is filled with an extremely delicate reticular magma, and although the inspection was made under favorable conditions, no trace of an embryo was found. After the specimen was thoroughly examined, it became more and more doubtful whether an amnion was present.

(5) Sections later showed that it was absent. Small fragments of decidua which were in the specimen were decidedly fibrous. The chorionic membrane and villi have undergone fibrous and mucoid degeneration. The trophoblast is scanty, and there are a few buds of syncytium, surrounded by a small amount of mucoid substance, between the largely non-vascular villi.

(6) Some hydatiform degeneration and probably chronic endometritis. Decidua fibrous.

No. 753.

(1) L. A. Peek, West Palm Beach, Florida.

(2) A 45×30×25 mm.

(3) Patient 23 years old; married about a year; first pregnancy. Usually about 32 days between menses. First day of last period, May 19; abortion August 1 following. No infection of the uterus; no venereal diseases.

(4) The specimen was found to consist of blood-clot containing a cavity about 12 mm. in diameter, lined with smooth membrane. No trace of embryo or amnion could be found.

(5) The sharply defined cavity of the cœlom is surrounded by a thin, somewhat macerated chorionic membrane. The magma is granular and contains disintegrating cells. In the fresh blood a few fibrous and mucoid villi are contained. Outside there is a decidedly hemorrhagic and inflamed, partly necrotic decidua. In many respects the chorionic wall resembles that of No. 752, group 6.

(6) Marked endometritis; lysis in decidua.

No. 765*b*.

(1) J. B. Harvie, Troy, New York.

(2) A 55×35×20 mm.

(3) Patient unmarried; one miscarriage 18 months before the present one.

(4) The specimen, which was expelled spontaneously while the patient was being etherized in the hospital, measures 55×30×20 mm. and appears to be composed of a collapsed, very hemorrhagic chorion. No trace of an embryo could be found.

(5) The cavity of the ovum, which is small (about 10 mm. in diameter), is infected, and the chorionic membrane is practically destroyed by a severe inflammation. The villi, which are packed together, show mainly fibrous and some mucoid degeneration. A great quantity of mucoid substance is found between them. In this numerous buds of syncytium and some small abscesses are contained. The surrounding trophoblast and decidua are markedly inflamed and the latter necrotic in several portions.

(6) Marked infiltration; hydatiform degeneration.

No. 770.

(1) C. S. Parker, Baltimore, Maryland.

(2) A 12×9×6 mm.

(3) Negro patient, aged 30 years, married 12 years. Six births at terms and three or four abortions. Copulation September 22. Menstrual period due September 28, appeared September 30, lasting 9 days. Abortion October 5, probably induced. Vaginal discharges not foul-smelling. No venereal diseases. Husband's family fertile.

(4) Specimen consists of chorion with a few blood clots attached. It is covered uniformly with villi, all of which are equally developed. The ovum measures 12×9×6 mm. It was opened with great care and found to be well filled with granular and reticular magma. The magma was removed in a single mass, and on one side of the chorion an irregular body about 2 mm. long was found. This was at first thought to represent the embryo, but when cut into serial sections was found not to be such.

(5) The chorionic wall and villi are quite normal in form and the trophoblast is plentiful. The specimen is somewhat macerated, but it appears as though there is some mucoid substance, in addition to the trophoblast, between the villi. The nodular mass looks much like an extension of mesenchyme into the cœlom, with strands of empty blood-vessels on either side of it. There is an epithelial tube-like structure, which might pass for the allantois or for the central nervous system. Adjacent to this structure is an umbilical vesicle, the blood-vessels of which communicate freely with those of the chorion.

(6) A normal, slightly macerated specimen. Decidua not included.

No. 791.

(1) Ira L. Fetterhof, Baltimore, Maryland.

(2) A 30×20×20 mm.

(3) The specimen is said to be two months old.

(4) The ovum, which measures 30×20×20 mm., is entirely covered with villi about 4 mm. long, and from one end arises a pedicle about 15 mm. long. The interior is filled with a delicate reticular magma, and on one side is an irregular body, 3 mm. long, which is adherent to the chorion.

(5) This small nodular mass is not well formed, and appears to be largely disintegrated. Apparently it is composed of two bodies, between which there is a clear body, no doubt representing the yolk-sac. Sections of the chorion show that the wall is somewhat thickened. The villi are mostly mucoid and filled with a clear mesenchyme without any blood-vessels. The trophoblast is composed mostly of small patches arising directly from the surface of the villi, and at points it forms rounded nodules, the centers of which are sometimes necrotic. There is a small mass of mucoid substance between the villi.

(6) Hydatiform degeneration. Decidua absent.

No. 829.

(1) Austin Miller, Portersville, California.

(2) A 38×38×30 mm.

(3) Woman about 30 years of age, married 5 years. Two previous pregnancies at term. Last menstruation about November; abortion January 20. Uterus normal. No venereal diseases. Family fertile.

(4) This specimen consists of a white, shaggy ovum, measuring 38×38×30 mm. About one-half of it is devoid of villi, and in the denuded area a perfectly trans-

parent chorion can be seen. On the opposite side the shaggy villi reach probably 10 mm. in length. They are extremely complex, branching many times, and almost all of the stems have a clear, bulbous appearance. The ovum, which was opened through a careful slit in the denuded area, contained a voluminous cavity filled with a fluid, and was crossed by extremely delicate strands of reticular magma. An embryonic remnant was not found. In the part of the wall where the most luxuriant villi occur, many circular, opaque white nodules, about 1 mm. in diameter, could be seen.

(5) The villi seem to have undergone mucoid degeneration. The trophoblast is scanty and mostly takes the form of buds of syncytium and nodules which have undergone partial fibrinoid degeneration. These nodules of trophoblast are frequently vacuolated.

(6) Hydatiform degeneration. Decidua absent.

No. 865.

(1) Walter Tobie, Portland, Maine.

(2) A 50×20 mm.

(3) Woman aged 35 years, married 10 years. Six pregnancies: five abortions and one birth at 7 months, dead. Beginning of last menstrual period uncertain; said to have been about 1½ to 2 months pregnant. At operation amputation of uterus at cervix; double salpingo-oophorectomy and appendectomy. No definite history of venereal disease. Dilatation and curettage, with ventral suspension, 4 years before. Said to have had tubal pregnancy one year ago. Family fertile on both sides and easily pregnant.

(4) The specimen consists of the uterus with both tubes and ovaries. The uterus measures 65×58×58 mm. It was cut six times in the antero-posterior plane, disclosing an implanted ovum 55×20 mm., apparently beginning to dislodge, the portion pointing toward the cervix being free. The small slit in the chorion measures about 26×3 mm.

(5) The right ovary measures 32×18 mm. and contains six old corpora and a small carcinoma measuring 10×12 mm. in cross-section. This shows to the right in figure 78, and upon higher magnification is seen to be studded with numerous small cell-nests which are barely visible in the mounted section with the unaided eye. Practically all of these nodules are discrete, as shown in figure 79, and all look decidedly quiescent, for very few nuclear figures suggesting mitosis were seen. All these cell-nests are well defined and none are edematous in character. Some of them contain a few small areas of calcification, and some of the latter are contained also in the ovarian stroma of the carcinomatous nodule.

The left ovary, shown in section in figure 80, which contains several old corpora and a recent one, measures 35×19 mm. and is cystic. The largest of these cysts, which by reference to the original specimen is found to be approximately spherical, measures 11.5×9 mm. on section. It is devoid of contents and immediately outside of the lining epithelium a small teratoma is found. Examination of the original specimen shows that this teratoma extended somewhat farther into the lateral half, and that the greater part of it still is contained in the more medial portion of the ovary (which is embedded in celloidin) and lies in the dorso-medial area of this portion. As shown in figure 81, it is represented by a grayish-white cartilaginous plaque, 8 mm. long by 1.5 mm. thick, with a markedly triangular process extending outward from its medial side. An examination of the stained sections shows this teratomatous mass to be composed of cartilage, at one extremity of which small plaques of bone are found. Surrounding this there is some adipose tissue which contains a number of tubules cut mainly in cross-section which from their appearance suggest those of suderiparous glands, but which probably are sebaceous. At the opposite extremity a considerably larger lobulated mass of glandular tissue is found, which seems to be sebaceous in nature. A few small tubules also are found near these lobules, which are partly separated from each other by trabeculæ of fibrous tissue. No remnants of epidermis, but some of a few hairs were found. A few degenerate hair-follicles also are present, and considerable accumulations of round cells are found near some portions of the teratoma.

After cutting the uterus into blocks, it was found that part of the ovum is detached and protrudes from the cervix. A portion of the chorion is well implanted and to the naked eye shows mottling. These spots, when cut into sections, are shown to be composed partly of hypertrophic degenerated villi, mostly with a mucoid stroma, some of which are very rich in Hofbauer cells. The villi, which are of all shapes and sizes, are matted together with fibrinoid substance and a great quantity of leucocytes and pus. At points the leucocytes burrow into the trophoblast and also enter the mesenchyme of the villi. Most of the trophoblast is necrotic and contains a great many plaques of nuclear dust. The leucocytes have entered the cavity of the ovum and line the inside of the chorion, which is undergoing fibrous degeneration. Neither amnion nor embryo was found.

(6) Severe infiltration; hydatiform degeneration.

No. 876.

(1) C. W. R. Crum, Brunswick, Maryland.

(2) A 46×30×23 mm.

(3) Patient aged 25, married in 1909. Five pregnancies: two children at term, followed by three abortions; August 1913, January 1914, and this one, April 19, 1914. Last menstrual period February 3 to 8. On February 15 patient was nauseated as in early pregnancy. No infection of uterus. Temperature normal. Retroversio uteri. No venereal diseases. Family fertile.

(4) The specimen consists of an irregularly shaped, firm abortion mass which measures 46×30×23 mm. Villi protrude at one end, but most of the surface seems to be firm decidual tissue. The specimen contains a perfectly smooth-walled cavity measuring about 32×22 mm. in diameter, with no trace of an embryonic rudiment.

(5) Sections of the wall show that the chorionic membrane is of normal texture, but thickened. Some of the villi are somewhat fibrous, but most of them show marked mucoid degeneration. Some are intermingled with active trophoblast, which in some instances contains fibrinoid substance and coagulated blood. The surrounding decidua is markedly inflamed and contains abscesses.

(6) Marked infiltration; hydatiform degeneration.

No. 883.

(1) G. H. Hocking, Govans, Maryland.

(2) A 37×26×20 mm.

(3) Patient aged 34 years, married May 4, 1905. Two pregnancies; birth at term February 2, 1906, and abortion April 21, 1914. Slight flow which continued until abortion on April 21. Condition of uterus negative. No venereal diseases. Family small.

(4) The specimen consists of a small, pear-shaped, mass measuring 37×26×20 mm. It is friable, and on being opened, a smooth-walled, oval chorionic cavity 20×9 mm. is disclosed. This is filled with a coagulated albuminous material containing cellular elements. The remains of the embryo could be seen.

(5) Sections show that the cavity of the cœlom is almost obliterated. On one side there are curious globules of degenerated pus which stain with eosin. The chorionic membrane and villi have undergone mucoid degeneration, and the latter are embedded in a clot of blood. There is a great deal of leucocytic infiltration, especially in the degenerated inflamed decidua. Leucocytes have invaded the mesenchyme of the chorionic membrane as well as that of the villi, and numerous small pus cavities are found between the chorionic epithelium and the stroma of this membrane.

(6) Severe endometritis and intra-chorionic infection; some hydatiform degeneration.

No. 968*a*.

(1) D. P. Quezon, Manila, Philippine Islands.
(2) A 60×45×25 mm.
(3) Specimen from young Filipino woman.
(4) The chorionic sac, which measures 60×40×25 mm., had been cut into irregular pieces, and was found intermingled with blood clot. In addition, about 50 c.c. of free masses of blood were separated from the chorion.
(5) The chorionic membrane appears normal, but the villi are almost wholly non-vascular and many show mucoid degeneration. The trophoblast is active and the tips of the villi are well implanted in the large piece of decidua. Where the two come into contact the fibrinoid substance is very evident. The chorionic vesicle contains no blood-vessels, but a great many Hofbauer cells. In the decidual fragments which have undergone fibrinoid changes there is considerable infiltration.
(6) Slight infiltration; hydatiform degeneration.

No. 970.

(1) R. W. Hammack, Manila, Philippine Islands.
(2) Chorion 3×5 mm. with cœlom. *In situ.*
(3) The specimen came from a Filipino girl, aged 16 years, who had taken hydrochloric acid with suicidal intent four days before her death. At the autopsy acute broncho-pneumonia, congestion of the kidneys, and hyperplasia of the endometrium were diagnosed, which led the physicians to suspect early pregnancy.
(4) The description of the uterus at the time of autopsy is as follows: "Uterus large and soft and the serosa red. The folds of the vaginal mucosa are present. The entire vagina is purplish red; cervix slightly enlarged and soft. In the fundus the mucosa is red, greatly thickened, soft and irregular. On the posterior wall beneath the mucosa is a firm, slightly movable nodule, a little less than 10 mm. in diameter. This was not opened. The cavity of the uterus is enlarged; the musculature is very slightly thickened and pink. The Fallopian tubes are of normal size, moderately hyperemic. The right ovary contains a large corpus luteum. The left ovary contains a small cyst, 20 mm. in diameter, containing reddish fluid."

The specimen received at the laboratory consists of vagina and uterus, with both tubes and ovaries, all in one mass. The uterus had been opened, and adherent to the mucosa were masses of blood. The entire uterine mucosa is covered with hemorrhagic nodules measuring in general about 10 mm. in diameter. One of these, located medianly, is larger than the rest, and a narrow block of tissue cut out of this and sectioned was found to contain part of the ovum. All of these sections were saved, and an adjoining block was taken and cut into serial sections in celloidin. Even this did not contain the entire ovum, but careful examination of the next block revealed the remainder.

(5) The ovum with its villi measures 3×5 mm. The cœlom is filled with a homogeneous substance, through which are scattered individual cells and also some strands of tissue from the chorionic membrane. The villi are about 0.5 mm. in length and covered with an active trophoblast. This layer of trophoblast, which ramifies into the adjacent tissue, is intermingled with a great deal of fibrinoid substance and cells, and penetrates the blood-sinuses. There are many buds of syncytium and considerable inflammatory reaction in the surrounding tissues. Towards the lumen the ovum is covered with decidua reflexa, marked off with a layer of fibrinoid substance. The sections examined show no trace of an embryo. On account of the swollen condition of the chorionic membrane and the lack of sharpness of the mesenchyme, the specimen does not appear normal.

Sections through the corpus luteum show it to be lined by a layer of lutein cells about 2 mm. in thickness. There is no central cavity, although the surrounding ovarian tissue is very hyperemic. There is no blood within the central cavity, but regarding this point it is impossible to make a definite statement, as both ovaries had been cut into before the specimen reached the laboratory.
(6) Slight infiltration; intra-uterine absorption.

No. 978.

(1) G. C. McCormick, Sparrows Point, Maryland.
(2) A 31×16×15 mm.
(3) Patient aged 39 years; married October 8, 1902. Six pregnancies: five at full term and this abortion, November 13, 1914. Last menstrual period September 19 to 23. Condition of uterus good. No venereal diseases. Family fertile.
(4) The specimen consists of a shrunken chorionic sac, partly embedded in blood-clot. The whole mass measures 31×16×15 mm. On opening the sac the interior was found to be filled with caseous magma. No embryo could be seen.
(5) The chorion is composed partly of well-formed villi and partly of a hemorrhagic mass. Sections through the latter show that the blood is penetrated by villi which have undergone fibrous and mucoid degeneration. There are also numerous buds of syncytium in addition to masses of syncytium which have undergone necrosis. The decidua is thin, necrotic, and somewhat inflamed. Clumps of erythroblasts lie along the inner surface of the chorionic membrane. Neither the latter nor the villi contain preserved blood-vessels.
(6) Marked infiltration; some hydatiform degeneration.

No. 986.

(1) W. C. Stick, Hanover, Pennsylvania.
(2) 45×28×17 mm.
(3) Patient aged 24 years; married in 1912. Two pregnancies, both ending in abortion, May 27, 1914 (specimen No. 905), and this one, November 19, 1914. Last menstrual period began about September and lasted for six weeks. No infection of uterus. Venereal diseases negative. Family fertile.
(4) The specimen consists of an irregularly flattened sac 45×28×17 mm., to which is attached a blood-clot. On one end there is an oval area measuring 27×27×22 mm., which is covered with chorionic villi. On opening the chorion it was found to be filled with a pronounced layer of thick, creamy material which could be pulled off only with difficulty. The particles thus detached proved to be very tough.
(5) Sections of the chorion show that it is covered with villi which have largely undergone mucoid degeneration. They are largely non-vascular and some of them are fibrous. Between the villi are numerous islands of trophoblast and also considerable stringy matter in which masses of syncytium are buried. The overlying decidua is marked by a zone of fibrinoid substance and contains numerous small abscesses.
(6) Severe endometritis with abscess formation; probably very early hydatiform degeneration.

GROUP 3.

No. 77.

(1) A. Horn, Baltimore, Maryland.
(2) A 70×50×30 mm.
(4) When the specimen was cut in half there was found within it a spherical cavity 20 mm. in diameter, lined with a smooth, fibrous membrane and filled with a clear fluid which permitted a careful inspection of its interior. On one side of the cavity was a small elevation 1 mm. in diameter and 0.25 mm. high.
(5) Sections are made of the walls of the specimen through the elevation, which proved to be a fibrous thickening of the amnion at its junction with the chorion. There are no blood-vessels in any portion of the chorion which have not undergone mucoid and fibroid degeneration and contain some Hofbauer cells. Except for a new nuclear remnants, the stroma of some villi is completely

degenerated. Between the villi there is a great quantity of trophoblast, fresh blood, and fragmented leucocytes. When fresh blood and syncytium come in contact there are many fragmented leucocytes. Slight infiltration of the decidua is present. The latter is also fibrous.

(6) Mild infiltration; hydatiform degeneration.

No. 130.

(1) P. G. de Saussure, Charleston, South Carolina.

(2) Ovum 15×10×6 mm., with vesicle 4×3×1.5 mm.

(3) "The specimen was passed by the patient while urinating, 14 days after the beginning of the last menstrual period. She had no idea that she was pregnant, and thought that the specimen was a piece of mucous membrane from the bladder. It was hardened entirely in 50 per cent alcohol."

(4) When received the specimen was only half covered with villi, the other half having apparently been stripped off. There was also a tear in the chorion through which a vesicle was protruding. Upon lifting the ovum this vesicle fell out. The ovum was then carefully cut open and was found to contain a considerable quantity of magma réticulé. Within this there was a long pedicle, measuring 7×2 mm. There was also a space in the magma large enough to hold the vesicle which had escaped. Both ovum and vesicle were cut into serial sections.

(5) The serial sections of the ovum show that the amnion is still unbroken. Its greatest measurements are 10×4 mm., into which extends the umbilical cord. At the end of the cord there is a mass of tissue, mostly broken down, the remains of the embryo. This mass is ragged, without any form corresponding to an embryo, and had the amnion been torn no doubt it would have fallen out. The blood-vessels of the cord are gorged with nucleated blood-cells, but they do not extend into the embryo. The chorion is normal in appearance. The umbilical vesicle is pear-shaped and completely closed. At no place is there a break to show its attachment to the cord. Although considerably macerated, the sections show the characteristic structure of an umbilical vesicle.

No. 143.

(1) W. C. Stick, Glenville, Pennsylvania.

(2) Large double sac, 15×10 mm., attached to the wall of the chorion.

(4) The chorion appears normal. The double, cyst-like body has thin walls and is filled with a clear fluid. The specimen has been in strong alcohol for nearly 20 years.

(5) Serial sections show a very degenerate chorion to which the double vesicle is attached. The structure of the walls of the two sacs is identical with that of the mesoderm of the chorion with all of the epithelial cells fallen off. The two sacs do not communicate; the larger has smooth walls; the smaller has numerous small vesicles, about 1 mm. in diameter, opening into it, and the cluster of vesicles are directly blended with the mesoderm of the chorion. The specimen undoubtedly belongs to the vesicular forms, peculiar only on account of its size.

No. 159.

(1) W. W. Golden, Elkins, West Virginia.

(2) Fragments of chorion with amnion.

(3) "From a woman in good health who had aborted about a year before during the third month. During the second month of the pregnancy from which the present specimen was obtained there was a slight flow of blood without any pain. It continued for 2 days; 10 days later it recurred and continued for 24 hours. Three days later it recurred again, became profuse, and the abortion followed. The supposed duration of pregnancy is 10 weeks. No indication whatever of endometritis. Both father and mother are perfectly healthy and are very anxious to have children."

(4) The specimen consists of portions of the mucous membrane of the uterus, large portions of the chorion, the amnion, but no embryo.

(5) The decidua is markedly infiltrated, and leucocytes have invaded portions of the chorion. The syncytium is very active, and at numerous points the syncytium and leucocytes have invaded the mesoderm of the chorion. Some villi show a good deal of "granular hyperplasia" and are being fused into a solid mass. The membranes are greatly thickened and composed of a dense connective tissue. The vessels are largely obliterated. The amnion is curled up and thickened, and its walls have undergone hyaline degeneration. The amniotic epithelium has proliferated, forming islands at many points.

(6) Mild infiltration.

No. 180.

(1) C. W. Dodge, Rochester, New York.

(2) Ovum 20×15×10 mm.; vesicle 2 mm.

(3) The woman was a patient of Dr. Edward Mott Moore, of Rochester. On March 28 her right ovary was removed. She left the hospital on April 15 and coitus occurred on May 13. On June 19 menstruation appeared and this ovum was expelled.

(5) Sections of the chorion show that its mesoderm is of normal thickness, but that it is fibrous and rich in nuclei. Throughout the main wall of the chorion, but not in the villi, there are numerous blood-vessels filled with blood, showing that at one time an embryo may have existed. The villi are normal in form, with a very extensive syncytial layer of cells over them. At points this forms large islands which can easily be seen with the naked eye. Within, immediately over the vesicle, an island of this kind, a millimeter in diameter, arises from the main wall of the chorion and sends processes up between the villi. The mesoderm just below this island is thinner than the rest, making it appear as if the violent growth of the syncytium took everything before it, but that in the attempt to produce new villi the fibrous mesoderm of the chorion would not follow. At many points between the villi there is a slimy mass of albumen, well infiltrated with leucocytes and numerous small islands of syncytium, some of which can be followed back to their origin from the villi. The vesicle is composed of but one layer of cells, that of the mesoderm with blood-islands embedded within it. No trace of an entoderm can be made out, although the lumen of the vesicle extends into a pedicle which, as a single strand of cells, attaches itself to the chorion.

No. 257.

(1) A. W. Lankford, Baltimore, Maryland.

(2) Ovum 55×40×40 mm., containing a pedicle 14×2 mm., to which is attached a nodule 4×0.5 mm.

(4) A large portion of the chorion is covered with well-formed and apparently normal villi. One portion is hemorrhagic and another fibrous, appearing as though it had protruded through the os.

(5) Sections through this portion show that the villi are atrophic and have undergone fibrous degeneration. The chorion is thickened and the decidua infiltrated with leucocytes. The inside of the thickened chorion is lined with epithelial cells which are continuous with those over the cord; it appears as if the amnion had become completely blended with the chorion. The cord is also fibrous with some spots which have undergone mucoid degeneration. It contains three large blood-vessels—a vein and two arteries—which show perivascular infiltration and fibrosis. The body at the end of the cord is simply its continuation, with the umbilical vein running through its entire length.

(6) Marked endometritis.

No. 279.

(1) Dr. Kemp, Baltimore, Maryland.

(2) A 100×60×60 mm.

(4) Part of the chorion is hemorrhagic; the rest appears normal. Sections show that some of the villi are nearly normal, but with a deficient amount of syncytium, even where they are well-embedded in blood. The amnion and a worm-like process (30 × 5 mm.), which proves to be the umbilical cord with its three blood-vessels, are present. The latter are well-developed and fully 1 mm. in diameter. There are also numerous vessels in the villi of the chorion. The tissue of the chorion is hyaline and contains a diminished number of nuclei.

(6) Marked infiltration and early hydatiform degeneration.

No. 408.

(1) J. Park West, Bellaire, Ohio.

(2) A 50×30 mm.

(3) The specimen came from a delicate, anemic woman who had been sick for a week with peritonitis. She menstruated normally June 10 to 14, then slightly for a day and a half, and considerably for three days before the specimen was expelled August 13.

(4) The solid specimen was cut through lengthwise and found to be composed mostly of a hemorrhagic mass containing a collapsed cavity lined with an amnion and measuring 12×4 mm. The chorionic membrane is greatly thickened and very necrotic.

(5) The solid mass is filled with necrotic and fibrous villi matted together in an irregular manner, and of many nests of trophoblast which in places are reduced to masses of nuclear dust. Beginning calcification is present. At numerous points the villi are invaded by trophoblast, showing that the latter continued to grow long after the death of the villi (?). At the periphery of the mole there is an extensive infiltration with leucocytes, indicating an inflammatory process of the uterus.

(6) Marked infiltration.

No. 429.

(1) Elizabeth Dunn, Chicago, Illinois.

(2) A 45×25×10 mm.

(4) The cavity of the vesicle is filled with a smooth membrane—the amnion. The chorion measures 45×25×10 mm. and the amniotic cavity 35×15 mm. Sections of the chorion, as well as two small nodules which accompanied it, were cut, but no remnants of the embryo could be found.

(5) The villi are matted together and degenerate, and many are irregular and atrophic. The amnion is in apposition with the chorionic membrane. Apparently we have here a specimen from which the embryo has escaped after it had been well developed, and which, on account of the detachment of the chorion, became necrotic. There is but little decidua, and this shows inflammatory reaction.

(6) Decidua infiltrated.

No. 468.

(1) J. M. Jackson, Pittsburgh, Pennsylvania.

(2) A 14×11×5 mm.

(3) The specimen was discharged spontaneously a week after the cessation of one menstrual period. The mother has the following history: At about the age of 18 she acquired a gonorrheal infection which was not treated, and about a year later she was treated for an infection of one tube and ovary, at which time the vaginal and cervical discharges were examined, but no gonococci were found. After a later exacerbation of the tubal trouble, one ovary and tube were removed by the abdominal route. Three years later she married, and after two years of sterility became pregnant. Pregnancy normal, and fetal life was determined up to within three days of delivery. No fetal heart-beat could be heard thereafter, and after an easy labor a slightly macerated dead child was born. The placenta was adherent and the microscopic appearance presented a gritty, granular area at the adherent portion. Specimen No. 468 was discharged one year later. She is now pregnant for the third time at six months.

(4) The specimen is evidently a collapsed ovum, measuring 14×11×5 mm. Its external surface is smooth and on it blood-vessels are coursing. Along the edge of one surface club-shaped villi (?) are seen. The specimen is very hard from the alcohol. On opening, a fine mold-like magma fills the cavity, from which it can be extracted, hanging together so as to form a cast of the cavity. The cavity is smoothly lined. No embryo could be seen. The fragments were then stained in cochineal, and the specimen afterwards cut in serial sections, but still no trace of an embryo was found.

(5) Sections of the chorion show that the ovum is lined by an amnion which is more or less adherent to the chorionic wall. The latter and the villi are very fibrous and matted together with blood and pus, indicating that there had been a very extensive inflammatory reaction within the uterus. The decidua is decidedly fibrous in places. Practically no trophoblast is attached to the decidua.

(6) Severe infiltration.

No. 469.

(1) Joseph M. Jackson, Pittsburgh, Pennsylvania.

(2) A 27×30×10 mm.

(3) Father had several attacks of gonorrhea before marriage, at which time he was supposed to be well. Never had syphilis. Mother is a sound, healthy, robust woman, age 26 years, married 6 years. Her family history is bad; many cases of tuberculosis on both sides of her line. She has one healthy child 4 years old. One miscarriage almost 3 years ago at 2 months; no ascertainable cause. The present specimen was discharged spontaneously 3 weeks after skipping one regular period. She is now pregnant for the fourth time and has gone 2 weeks over one period. She has no symptoms of adnexal and no evidence of tubercular trouble. Menstruation normal, but of unusually foul odor.

(4) Collapsed ovum 27×30×10 mm., covered completely on one side and partially on the other by branching villi about 3.5 mm. long, although some along one lateral margin are fully 6 mm. long. A large, relatively bare area, 20×15 mm., exists on one side, where the small scattered villi are seldom branched and not over 1.5 mm. long. On opening the ovum, no distinct cavity is met, as many white "cheesy" trabeculæ obscure it. No evidence of an embryo is found. The magma is very extensive, completely filling the exocœlom, and may be described as reticular with much white granular or cheesy substance in its meshes.

(5) On one side of the chorion a shaggy body, about 3 mm. long, was found embedded in the magma. This, with the adjacent chorion, was cut into serial sections. These show that the body seen before cutting was the umbilical vesicle, all of which is filled with round cells. No embryo could be found. The chorionic wall and villi are somewhat fibrous, and the trophoblast is scanty. At points it seems to be invading the mesoderm of the chorion. Some of the villi contain blood-vessels. No amnion, or only a remnant of it, is present. The magma, which forms a thick layer within the chorion, is composed of fine granules, through which are scattered numerous small round cells.

No. 483.

(1) Charles A. Lamont, Canton, Ohio.

(2) A 20×12×6 mm.; B 3 mm.

(3) The patient is a primipara, age 33 years. Last menstruation October 23; previously had been invariably regular. On January 3 she noticed a slight flow which increased at times, but had little pain until the night of January 5. The following morning the ovum was expelled.

(4) The specimen consists of a smooth sac which proved to be the amnion, and upon which the embryo is sessile. This sac contained a granular deposit and a cylindrical embryo 3 mm. long, the external form of which is irregular.

(5) Sections show extensive changes within. The central nervous system is irregular and the otic vesicles are

lacking. The eye-vesicle can still be made out and the heart can be outlined. Within the body the spinal cord is irregular and contains a lumen which at points appears to communicate with the pharynx. In other portions of the body the cord is absent. The amnion is attached along the entire length of the body.

No. 498.

(1) Guy L. Hunner, Baltimore, Maryland.
(2) A 40×40×40 mm.
(3) "Patient aged 30 years, with one child 6 years old and no miscarriages. Physician first saw patient June 10, 1909, because of backache, dragging feeling, and slight piles. Menstruates every 5 or 6 weeks, stops 1 day, then a scant flow for 3 or 4 days. I found uterus far back in pelvis and containing a small round fibroid fundus. Correction of position and introduction of pessary. January 28 period began with terrible bearing down in lower abdomen. No flow until February 1. A large clot and free flow on February 2; no more until Monday, February 6. Another terrible cramp and some blood. This period was 3 weeks late; is often 1 week over time. Pessary removed about 1 week before. Examination: Uterus far back in pelvis, easily brought forward. Size of 2 months' pregnancy, but rather too firm feeling. Cervix soft, enlarged. Breasts enlarged, firm colostrum. Diagnosis: Probable pregnancy; fibroid. Patient was advised to keep quiet and report in 1 month. On March 1, after pains during the night, passed the specimen."
(4) The chorion is partly covered with villi and entirely encircled by the decidua. In the portion of the chorion which is devoid of villi there is a large space between the chorionic membrane and decidua. The interior of the ovum is lined by a smooth membrane—the amnion—and between it and the chorion there is a gelatinous mass of reticular magma about 1 mm. in thickness and distributed equally around the whole circumference of the ovum. No remnant of the embryo could be found.
(5) Sections through the wall include the amnion, the chorion, a thick layer of fibrinoid substance with cells, and a layer of decidua. The latter is infiltrated with leucocytes. The chorion is thin and the villi are atrophic and well separated, having undergone fibrous and hyaline degeneration. There is considerable trophoblast, some large masses of which are degenerate. There are also small nodules of necrotic trophoblast scattered between the villi and fusing with the chorionic epithelium. There is a great deal of blood in the magma which lies between the amnion and chorion, into which numerous strands of mesoderm cells from the chorion radiate. Between the blood and the chorionic membrane there are some Hofbauer cells, which also are found within the mesenchyme of the chorion and its villi, which also contain some blood-vessels.
(6) Mild infiltration; early hydatiform degeneration.

No. 505

(1) Thomas S. Cullen, Baltimore, Maryland.
(2) A 70×35×25 mm.
(4) The mole has a thick wall and contains a smooth cavity measuring 50×20×10 mm. A small nodule was found attached to the lining membrane, but serial sections show that it contains no embryonic remnant.
(5) Sections of the chorion and amnion show that both are fibrous. The wall is degenerate, many of the villi having undergone fibrous degeneration, while a few are mucoid. Others show "granular hyperplasia." Some of the villi contain large central cavities. There is considerable fresh blood between the villi which seems to nourish them. The main wall of the chorion is necrotic in places and has been invaded by leucocytes. There are many islands composed of degenerate trophoblast and areas of villi are matted and fused.
(6) Severe endometritis.

No. 518.

(1) Thomas C. Smith, Washington, District of Columbia.
(2) A 50×45×40 mm.
(3) The specimen came from a patient whose period was two weeks overdue.
(4) The ovum is covered with well-formed villi which appear to be normal in shape as well as in their mode of branching.
(5) Sections show masses of trophoblast between the villi, many of which have undergone necrosis. The villi and chorionic wall contain numerous large blood-vessels, showing that at one time a normal embryo must have been present. The cord-like structure seen within is 10 mm. long and 1.5 mm. in diameter. This proves to be the umbilical cord and contains a very large cavity, the tissue of which is more or less dissociated. Scattered through this tissue are a few very pronounced groupings of cells which appear much like syncytium or trophoblast. It is remarkable that this large, cord-like structure contains no blood-vessels.
(6) Hydatiform degeneration. Decidua absent.

No. 531.

(1) C. A. Rhodes, Atlanta, Georgia.
(2) A 19×19×19 mm.
(3) The specimen is from a multipara. This was her sixth pregnancy, menses having been 17 days overdue.
(4) One side of the spherical specimen is covered with a crescent-shaped group of villi, and the rest of it is nearly naked, only a few very small villi being present. Within the chorionic vesicle there is a delicate reticular magma and a detached umbilical vesicle suspended in the center of the cœlom. There are also very opaque particles present.
(5) The sections stained by the Mallory method show beautifully the continuity of reticular magma with the mesenchyme. The chorionic villi are covered with a relatively small amount of trophoblast and contain remnants of many blood-vessels. The walls of the free umbilical vesicle are dissociated, and numerous strands of cells radiate from it into the adjacent magma. In addition to this, another vesicle was found closely attached to and directly continuous with the chorionic wall. This probably is a rudimentary amnion.

No. 533.

(1) J. L. Fewsmith, Newark, New Jersey.
(2) A 35×30×30 mm.
(3) The patient missed one period which should have occurred on May 17. She aborted June 15.
(4) The ovum is pear-shaped and well covered with villi and some decidua. In general its external surface is irregular and ragged. The cœlom is well filled with a dense reticular magma containing two irregular bodies, one 6 mm., the other 5 mm. long. The latter lies in the amnion (?), the former in the middle of the exocœlom.
(5) Sections were cut of these bodies and of the chorion, but they did not stain well. The chorionic wall is macerated and nonvascular and some of the delicate villi arising from it are macerated and coalesce; others are extremely degenerate. The trophoblast is scanty. The round body, which appeared to be abnormal, was cut into sections and found to be inclosed by a tough membrane which does not stain. Its interior is filled with a granular mass uniform throughout. Apparently we have here a portion of the amnion with remnants of the yolk-sac, but without any remnants of the embryo. The decidua is very degenerate.
(6) Very early hydatiform degeneration.

No. 555.

(1) G. C. McCormick, Sparrows Point, Maryland.
(2) A 30×20×20 mm.
(3) Specimen said to be of a few weeks' gestation.

(4) The entire mass measures 45×30×30 mm., and contains a cavity lined with a smooth membrane. This cavity is separated from the chorion by a delicate reticular magma.

(5) The chorion and villi are fibrous, and many of the latter are embedded in blood and disintegrating. The trophoblast is necrotic, and its nuclei are turning into dust, while the stroma is being invaded by leucocytes. The decidua shows marked general infiltration and some necrosis.

(6) Marked infiltration.

No. 556.

(1) E. J. O'Shaughnessy, New Canaan, Connecticut.

(2) A 30×30×30 mm.

(3) Patient has one child, 13 months old. Since birth of child menstruated only once, September 3. Coitus only once, about October 15. Abortion November 28. Patient induced, or tried to induce, abortion by taking 12 gr. calomel and 20 gr. quinine about a week before.

(4) The mole is the usual fleshy variety, with a cavity lined by the amnion. The whole mass is 50×30×30 mm., within which is a cavity 30 mm. in diameter. In this hangs a peculiar mass about 20 mm. wide, with a ragged ending, which is probably the cord. It appears as if the ovum had been injured mechanically in some way, and that the embryo had been broken off.

(5) Sections of the chorionic wall show it to be fibrous, and many of the villi are also undergoing mucoid degeneration. The trophoblast is scanty and mostly necrotic, the greater portion containing nuclear dust. Where it comes into contact with the decidua, however, it appears to have been growing with some activity. The fibrinoid substance over the villi is very extensive, and this in turn is partly covered with a degenerate decidua infiltrated with leucocytes.

(6) Slight infiltration of the decidua.

No. 564.

(1) Josiah S. Bowen, Mount Washington, Maryland.

(2) A 35×25×25 mm.

(3) The ovum was found protruding from the uterus and was removed with the curette. This is the second time the patient has been curetted.

(4) The specimen was perfectly smooth, but with spotted surface. The larger part of it is solid. In the smaller end there is a cavity measuring 20×10 mm., which is filled entirely with granular magma. Deep down on one side there is a smooth, pear-shaped opaque body, about 1.5 mm. in diameter and about 4 mm. long, which appeared to represent the head of the embryo. The solid part of the ovum is composed of an extensive mass of villi.

(5) Part of the chorion containing the suspicious mass shows no trace of an embryo in serial sections. There are, however, numerous other large cheesy masses within the amnion which probably represent the disintegrating embryo, but which are without structure. The chorionic wall and villi are very fibrous, and some villi show granular infiltration. There is considerable fresh blood within the intervillous spaces. The trophoblast is quite abundant and active. The decidua has a great deal of fibrinoid substance upon its chorionic side, and is extensively infiltrated with leucocytes, showing that the uterus was markedly inflamed. There is a degenerate, thickened amnion.

(6) Marked infiltration.

No. 584b.

(1) Henry Rohlfing, St. Louis, Missouri.

(2) A 37×31×21 mm.

(4) About two-thirds of the ovum is covered with long, irregular villi, branching two or three times, while the remaining part is denuded. Within there is an extensive mass of reticular magma. By varying the illumination, the faint outline of a sac with a transparent body within was suspected.

(5) Sections show the chorion and villi to be somewhat macerated and hyaline. There is no trophoblast, but a few buds of syncytium. The cœlom is filled with a dense reticular and granular magma, and its serial sections reveal the stub end of the umbilical cord about 2 mm. in diameter, around the edges of which are attached large folds of collapsed amnion. The outline of several blood-vessels within the cord can be followed, and within the amniotic cavity there is a débris of cells, showing that the embryo has disintegrated.

(6) Decidua not included.

No. 605.

(1) Charles S. Parker, Baltimore, Maryland.

(2) A 45×50×25 mm.

(3) The specimen was aborted after uninterrupted menstruation; an unsuspected case of pregnancy, believed to be illegitimate.

(4) The ovum is covered by a uniform layer of villi which branch two or three times, and on one side is a small patch of decidua. The interior is partly filled with coarse strands of reticular magma, to which are attached numerous granules. On one side of the specimen is an umbilical cord surrounded by ragged amnion. The tip of the cord has what looks like a piece of intestine and stomach attached to it. The larger granules attached to the reticular magma would seem to be remnants of the embryo, parts of which appear to be normal.

(5) Sections include part of the amnion and the attachment of the cord to the chorion. The amnion is disintegrating, macerated, and the tissues of the chorion are dissociated and also macerated. The chorionic membrane is somewhat hyaline and contains a few blood-vessles, around which there is an invasion of round cells. Otherwise it appears to be normal. The villi are hyaline and practically non-vascular, with degenerate stroma and epithelium. Between them there is a great quantity of necrotic trophoblast. A fibrous, degenerate yolk-sac and a stump of the cord with the degenerate vessels are the only embryonic remnants found.

(6) Early hydatiform degeneration. Decidua absent.

No. 611.

(1) V. N. Leonard, Baltimore, Maryland.

(2) A 45×24×20 mm.

(4) The specimen is smooth, has thick walls, and contains a well-defined cavity 25×8 mm. There is considerable reticular magma within this cavity, and a loose membrane, probably the amnion, is attached to one side of the chorion. Adherent to this membrane is an irregular fold, 5 mm. long, which attaches it to the chorion. On the opposite side a small nodule of irregular shape is closely attached to the walls of the specimen.

(5) Sections show that the thick-walled mole consists of a thin chorion encircled by blood and a very hemorrhagic decidua, the deeper portions of which show marked general infiltration. The amnion was not included in the sections, but can be seen as a crumpled membrane within the chorion among the blocks of tissue which were not cut. The chorionic membrane is hyaline, and through it are scattered numerous nuclei. It is surrounded by villi of the same structure, radiating through much necrotic trophoblast, with quite a good deal of fresh blood between them. The trophoblast shows a little activity where it comes in contact with the fresh blood. The fibrinoid shows a curious stratification in some areas not seen in other specimens. The very degenerate villi are encircled by a very thick layer of fibrinoid substance, following which is the very hemorrhagic and infiltrated decidua.

(6) Marked infiltration.

No. 645.

(1) C. A. Bentz, Buffalo, New York.

(2) Ovum 30×30×20 mm.

(4) One end of the ovum is covered with ragged villi. The chorion is lined with a delicate amnion, and at one

end is a small pointed body, 3 mm. long, thought to be the remnant of the umbilical cord. This is attached to a part of the chorion which is markedly thickened.

(5) Sections through the chorion include a hemorrhagic mass about 5 mm. in diameter, and show the amnion greatly hypertrophied, much folded upon itself, and more or less adherent to the chorion. What appeared to be the umbilical cord in the gross specimen is probably only a fold in the amnion. There are few blood-vessels in the chorion and one large epithelium-lined cavity. The villi have undergone mucoid degeneration and in some of them there are numerous Hofbauer cells. Where they come in contact with the blood-clot they are covered with active trophoblast, which not only forms islands, but also streams through the blood-clot.

(6) Typical hydatiform degeneration.

No. 651*d*.

(1) G. C. McCormick, Sparrows Point, Maryland.

(2) A 45×25×25 mm.

(4) The ovum is covered with long, tortuous villi. Within there is much reticular magma and the remnants of a disintegrated embryo.

(5) The chorionic wall has lost its sharp contour, and there are irregular strands of mesenchyme reaching from it to the cœlom. This tissue comes in contact with a thin membrane which seems to be the disintegrating amnion. The villi have mostly undergone mucoid degeneration, and there are a few clumps of trophoblast. There are also buds of syncytium scattered quite equally throughout the chorion. The villi and exocœlom contain many Hofbauer cells, which are very large, many of them containing several nuclei.

(6) Early hydatiform degeneration.

No. 651*e*.

(1) G. C. McCormick, Sparrows Point, Maryland.

(2) A 25×25×20 mm.

(4) The ovum is covered with regular villi which divide two or three times and measure from 2 to 3 mm. There is much reticular magma within the exocœlom, and within the amnion a layer of granular magma.

(5) The chorion is fibrous and the villi show mucoid degeneration. The trophoblast is scanty, but proliferating in places, with a stringy mass between the villi, invaded more or less by buds of syncytium. A remnant of the yolk-sac is present.

(6) Early hydatiform degeneration.

No. 658.

(1) Thomas C. Smith, Washington, District of Columbia.

(2) A 30×20×20 mm.

(3) Patient aged 41 years, married twice; three children by first marriage, none by second. In this case the patient says her menses came on time on March 12. On March 24 she had a sharp pain and the specimen dropped from her.

(4) The smooth vesicle is filled with a jelly-like whitish mass. On one side of the interior there is a transparent mound about 3 mm. in diameter. The chorionic wall is fibrous, covered with a few villi and an inflammatory, rather fibrous decidua. The villi are mostly fibrous, nonvascular, and the trophoblast scanty. Within there is a vesicle embedded in the fibrous amnion.

(6) Mild infiltration.

No. 668.

(1) O. S. Lowsley, Bellevue Hospital, New York.

(2) A 40×30×20 mm.

(3) Last period December 26; abortion in March following.

(4) Ragged specimen, to which is attached a transparent vesicle 10 mm. in diameter. The vesicle is attached to a hollow stem which can be traced into the mass, and there communicates freely with the amniotic cavity. Within this cavity is an opaque cylindrical body about 3 mm. long, possibly the remnant of an embryo. No doubt the ovum was injured some time before the abortion, causing the amnion to protrude and leaving it attached to the chorion. More careful examination of the specimen did not reveal the presence of an embryo.

(5) Sections were cut through the chorion, but did not include the amnion. The chorion is degenerate and the villi large and swollen, most of them having undergone mucoid degeneration, which is very complete in some cases. They are matted together by blood, inflammatory exudate, trophoblast, and many buds of syncytium, and contain large Hofbauer cells. Marked leucocytic accumulations are found at the periphery. Decidua is not included in the sections.

(6) Hydatiform degeneration. Decidua absent.

No. 682.

(1) G. H. Hocking, Govans, Maryland.

(2) Chorion with amnion.

(3) The woman had been married 18 years and had eight consecutive births at term, followed by this abortion. Syphilis suspected, but a Wassermann test gives a negative reaction.

(4) The specimen consists of large pieces of decidua and an ovum with a layer of ragged villi which are more or less bound together by blood-clots and fibrinoid. The mass measured in formalin 45×30×30 mm. Upon further dissection it proved to be a collapsed ovum lined with smooth membrane, which does not contain an embryo. The amnion is easily detached from the chorion, and the remnants of the umbilical cord can be seen. However, the specimen appears to be an ovum from which the embryo has escaped.

(5) The chorionic wall is somewhat fibrous, and over it there are degenerating matted villi. The encircling layer is composed mostly of fibrinoid substance and a small amount of decidua, which shows some general and considerable local infiltration. There is some active trophoblast where the villi come into contact with fresh blood.

(6) Mild infiltration.

No. 689.

(1) Robert B. Slocum, Wilmington, North Carolina.

(2) A 32×28×20 mm.

(3) Patient aged 22 years; married slightly less than a year. The last menstrual period was March 12 to 18, abortion following on May 22. Said to be caused by an automobile accident 2 days before.

(4) The ovum is spherical, measuring 32×28×20 mm. It is well covered with villi, some of which are larger than others, showing marked swellings at their tips. At one pole over 1 cm. square, the villi are scanty and poorly developed. Judging externally, the specimen appears to be abnormal. The clear area of the chorion was then removed, and it was found that the cœlom was filled with a very dense reticular magma. Within are opaque granules, one of which is about 1 mm. in diameter. Upon removing most of the magma a nodule, about 2 mm. long and evidently representing the embryo, was found near that portion of the wall of the chorion where the villi were best developed. On examination of the specimen in this way it was found that a portion of the magma was glassy in appearance and fell out easily, while the remaining part was fibrillar, the fibrils radiating toward the embryo.

(5) The entire chorion was cut into serial sections, those containing the nodule being mounted. There are no blood-vessels in the chorionic wall, and the villi appear edematous, with a scanty amount of trophoblast. There are numerous buds of syncytium. The amnion is sharply defined, well folded upon itself, and attached to the chorion at one point, but contains no embryo. There is, however, an umbilical vesicle—the nodule—which is nearly disintegrated. Its blood-islands are small,

but can still be outlined, and its interior is filled with round cells.

(6) Hydatiform degeneration. Decidua absent.

No. 701.

(1) George H. Hocking, Govans, Maryland.

(2) A 70×50×30 mm.

(3) Patient 22 years old. Married one year and the mother of one child. Last period March 8; abortion June 7, after a slight bloody discharge which had continued for 2 weeks.

(4) The chorionic mass, which measures 70×50×30 mm., contains a cavity 30×20 mm., lined by the amnion, in which is a cylindrical mass 2 mm. in diameter and 20 mm. long. No remnants of an embryo were found.

(5) The specimen consists of a chorion with many well-developed villi covered with a great quantity of necrotic trophoblast, blood, and fibrin. In this irregular mass are growing many buds of syncytium. The mesenchyme of the villi is somewhat fibrous, and scattered through it are many Hofbauer cells. Sections through the umbilical cord show the remains of large blood-vessels, indicating that the embryo was well developed shortly before the time of the abortion.

(6) Marked infiltration; early hydatiform degeneration.

No. 723*b*[1].

(1) Lawrence L. Iseman, Chicago, Illinois.

(2) A 60×40×40 mm.

(4) Ovum filled with magma. Umbilical cord is normal in appearance.

(5) The structure of the villi and of the chorionic membrane is quite normal. The mesenchyme of the villi contains great quantities of Hofbauer cells, and is largely non-vascular. Between the villi there is a great deal of fresh blood, and into this are growing numerous buds of syncytium. The surrounding tissue is markedly inflamed. Remnants of the amnion are attached to one end of the cord.

(6) Marked infiltration.

No. 723*b*[2].

(1) L. L. Iseman, Chicago, Illinois.

(2) A 50×35×30 mm.

(4) Ovum with smooth, fleshy wall, which is thickened and lined by the amnion, which has fused with the chorion.

(5) The villi, which are necrotic, have undergone partial mucoid degeneration and are surrounded by a degenerated, fibrous decidua. The spaces between the villi are filled entirely with fibroid which apparently has cut off the nutrition. There is very little trophoblast.

No. 757.

(1) A. C. Smink, Baltimore, Maryland.

(2) A 50×50×25 mm.

(3) Patient aged 30 years; married in 1909. Two pregnancies. Last menstrual period June 20 to 24, 1913, and abortion September 18 following. Condition of uterus normal; no venereal diseases. Patient belongs to a prolific family.

(4) The specimen is disk-shaped and measures 50×50×25 mm. It is covered by a delicate membrane, which suggests that the ovum has been turned inside out. Sections of this mass show the interior to be composed mostly of a stratified blood-clot, intermixed with numerous irregular villi.

(5) Microscopic examination shows that the outer layer above noted is composed of the inverted membranes which surround a blood-clot containing some villi. The stroma of the latter is decidedly fibrous, non-vascular, and degenerate, suggesting rapid destruction. The epithelium is quite well preserved, but the "appendici durate" are necrotic. Hofbauer cells are quite common, and the stroma in many places, and even whole villi, have undergone coagulation necrosis. In other villi it is fenestrated. The blood-cells are well preserved in many portions of the clot, but the stroma of both membranes has undergone hyaline degeneration.

(6) Decidua not included.

No. 771*a*.

(1) B. T. Terry, Brooklyn, New York.

(3) Patient had a miscarriage in 1900. From that time until June 28, 1913, she menstruated regularly, then the periods became irregular, until she was operated upon September 5, 1913. At operation it was found that the ovaries and left tube were normal, but that there was a chronic endometritis. Venereal diseases denied.

(4) The specimen is formed of blood-clot containing a cavity 13 mm. in diameter.

(5) The sections show very degenerate fibrous villi which are matted together in hyaline material and necrotic decidua. Between the villi and the decidua there is fibrinoid substance. The chorionic membrane is thickened, macerated, and degenerated, and neither it nor the villi contain any blood-vessels. The amnion, which is decidedly macerated and degenerate, is folded. No evidence of inflammation.

No. 803.

(1) W. J. Weese, Ontario, Oregon.

(2) A 43×26×23 mm.

(3) First pregnancy of a woman aged 21 years, married March 23, 1913. Last menstrual period October 15 to 19, 1913, and abortion November 26 following. No infection of uterus. No venereal diseases. Mother of patient had one abortion.

(4) The chorion has a very thin, hemorrhagic wall lined with a smooth membrane. On one end is a small tuft of villi. There is a considerable reticular magma, and on one side a nodular embryo 3 mm. long.

(5) The chorionic membrane, which is somewhat fibrous, is covered with matted villi which have undergone fibrous degeneration. There is a great deal of fibrinoid and large hemorrhages. On the outside is a layer of unorganized clot. The nodule consists of what appears to be a collapsed amnion. As the sections were not serial, it is impossible to determine the exact relation of this membrane to the chorion. The decidua is decidedly necrotic, fibrous, slightly infiltrated, and hemorrhagic.

(6) Slight infiltration.

No. 813.

(1) H. D. Taylor, Baltimore, Maryland.

(2) A 80×50×25 mm.

(3) First pregnancy of a woman aged 24 years, married August 10. Last menstrual period June 13 to 17, same year; abortion December 30 following. No venereal diseases. Family fertile.

(4) The specimen appears ulcerated and is composed of a flattened oval mass measuring 80×50×25 mm. After opening it, the chorionic wall was found to be sharply defined, with numerous hemorrhages between the villi. The cavity measures 70×35 mm. and is filled with a tough, clear jelly.

(5) Sections of the chorion show that the wall is very thick and fibrous, and that at many points it appears to be composed of two layers. The amnion is closely attached to the chorion. Some of the villi are completely degenerated, and others are fibrous and matted together by a large amount of fibrinoid substance. There is a necrotic decidua, the cells of which are arranged in whorls in some places, and which is markedly infiltrated in some areas.

(6) Marked infiltration.

No. 814.

(1) J. M. Melton, Crozet, Virginia.

(2) A 55×25×25 mm.

(3) The sixth pregnancy of a woman aged 43 years, married 18 years. Fourth pregnancy ended in abortion 7

years before. November and December periods missed before this abortion, December 26. No venereal diseases. Family very fertile.

(4) The mole is solid, stratified, and hemorrhagic, measuring 55×25×25 mm. Upon opening, it was found to be composed of a slit-like cavity running into the larger part of the specimen, which upon sectioning proves to be the amniotic cavity.

(5) Into this there extends the stub of an umbilical cord containing several very large blood vessels, and also a large cavity partially filled by a reticular mass. The chorionic wall and villi are very fibrous, and are matted together into a great mass by blood and quite active trophoblast. On the outside are remnants of decidua which are markedly inflamed.

(6) Severe infiltration.

No. 922.

(1) H. F. Cassidy, Roland Park, Maryland.

(2) A 60×45×26 mm.

(3) Negro, age 24 years, married in 1908. Two children, 5 and 2 years. This is the only abortion. Last menstrual period May 20 to 22 and abortion June 24 following (1914). Four or five days before abortion just a show, then about a normal flow. Lifted a heavy child and felt some pain then. No history of infection. Pregnancies not attended by fever.

(4) The specimen is a pear-shaped abortion mass measuring 60×45×26 mm., and consists chiefly of thiek, blood-infiltrated chorionic walls which inclose a smooth-lined cavity 20×9 mm. No trace of an embryo can be seen.

(5) The specimen is very hemorrhagic, with a very thin chorionic membrane and an amnion which is much folded upon itself. The decidua is ill-preserved, markedly infiltrated and hemorrhagic, and near it lie a very few fibrous villi. The trophoblast is mostly necrotic. The wide space (5 mm.) between the decidua and the chorion is filled with fresh blood.

(6) Marked infiltration; some hydatiform degeneration.

No. 960*a*.

(1) Marcus Ostro, Baltimore, Maryland.

(2) A 90×70×25 mm.

(3) Patient aged 32 years, married in April 1909. Three pregnancies, one abortion. Last menstrual period October 3 to 8, 1914; abortion October 16 following. Patient discharged from hospital March 29, 1914, after having had a post-partum hemorrhage. Menstruated regularly every month thereafter until abortion, each period lasting 4 to 6 days. Flow free, no pain. Two days after the last period ceased, bleeding began again and continued up until the time of entrance to the hospital, October 15. The hemorrhage was very profuse during the two days preceding the abortion, and the patient had become very weak and anemic. On October 16 the specimen was passed. Husband has triple-plus Wassermann on blood and spinal fluid.

(4) The specimen consists of a mass of clotted blood 90×70×25 mm., but the greater part is separated easily, leaving a placental mass with torn chorionic sac. No embryo was found. What was apparently the stump of the umbilical cord could be recognized.

(5) Sections of the chorion show a leucocytic infiltration within its cavity which involves the amnion. The villi are well-developed, largely non-vascular, and have undergone a peculiar degeneration which is neither mucoid nor fibrous; they are matted together with inflamed exudate, mucoid substance, and more or less active trophoblast. There are also numerous plaques of nuclear dust. A layer of fibrinoid substance covers the chorionic membrane as well as the tips of the villi. There are nests of trophoblast cells within the inflammatory mass, probably within the blood-vessels. It would appear as though the embryo escaped some time before the abortion, leaving a normal chorion which underwent degeneration.

(6) Intense infiltration.

No. 962*a*.

(1) J. M. Jackson, Pittsburgh, Pennsylvania.

(2) A 35×35×35 mm.

(4) The specimen is covered with decidua and has a smooth inner surface, to which is attached a delicate cord about 15 mm. long. This ends in a collapsed bag, measuring 30×5×8 mm., apparently in the amnion.

(5) Sections of the chorion show it to be thin and lined with a great deal of reticular magma. The villi on the outside are delicate, the mesenchyme having undergone mucoid degeneration, and there is some mucoid substance between them. The individual villi are well covered with trophoblast, all of which is vascular and very much more extensive than usual.

(6) Early hydatiform degeneration.

No. 976.

(1) J. C. Bloodgood, Baltimore, Maryland.

(3) Patient aged 38 years; married. One pregnancy 2 years before, ending in miscarriage at second month. Family and past history unimportant. Present trouble began with nausea about 4 months before curettage. At first this was slight and intermittent, but for the last 2 months it had been continuous and severe. Patient noticed no irregularities or abnormalities about her periods until September, when, although appearing on time, the flow was very scanty and lasted only 3 days instead of a full week as previously. After that she became worse, and there was bleeding for 2 weeks before operation. The hemorrhage was slight, and at no time did she pass any clots. During that time the patient was constipated and constantly nauseated, vomiting everything she took. At no time did she have any pain except a dull backache. This had been present for 4 months and was worse at her periods. No leucorrhea.

(4) Specimen consists of about 40 c.c. of uterine curettings, a considerable portion of which is chorionic membrane. Attached to one piece of this membrane is a cylindrical embryo 5 mm. long. Part of the chorion appears to have normal villi, while sections of another show its main wall to be very fibrous and the villi quite edematous, containing many Hofbauer cells. The entire ovum is encircled by a mass of leucocytes and shows an extensive inflammatory reaction in the uterus. The part of the chorion containing the embryo does not seem to have this inflammatory reaction.

(5) The piece of the chorion to which the assumed embryonic mass was attached was cut into serial sections, but upon examination it was found not to be such. The overlying trophoblast at this point and the decidua are very markedly inflamed.

(6) Severe infiltration.

No. 985.

(1) A. F. Ries, Baltimore, Maryland.

(2) A 70×50×35 mm.

(3) Patient aged 34 years; married about 14 years. Seven previous pregnancies. This abortion November 19, 1914. Endometritis, cystocele, rectocele, and lacerated perineum. Family fertile. Specimen was passed in two parts, with 12 hours interval between; first the ovum, then the decidua.

(4) Ovum 70×50×35 mm., with thick irregular walls. Apparently it is inverted and contains a fibroid nodule. 3 mm. in length, which, when sectioned, seemed to be the umbilical cord.

(5) Sections show the chorion with many villi, with degenerate nuclear mesenchyme containing some blood-vessels. There are several enormous Hofbauer cells scattered through the villi; in fact, they might be called giant cells. There is a great deal of blood between the villi, and the trophoblast is fairly active. The overlying decidua is very hemorrhagic and infiltrated. The embryonic nodule was cut into serial sections and proved to be the umbilical cord, which has undergone fibrous degenera-

tion. Within the cord there is an epithelial vesicle, possibly the remnant of the allantois. Besides the cord there is the amnion, which is thrown into many folds and which has also become very fibrous and degenerate.

(6) Marked infiltration.

No. 1001.

(1) Geo. Heller, Baltimore, Maryland.

(2) A 65×43×25 mm. (abortus); 42×30×20 mm. (chorion).

(4) The specimen is composed of a partially torn decidua containing a chorionic sac partly filled with clear fluid, and a small oval mass 1 mm. long which may be the remains of an embryo. The amnion, which is partially fused with the chorion, is approximately two-thirds its size. Where it is separated from the chorion reticular magma is present. When examined under the binocular microscope the presence of hydatiform degeneration easily is revealed. The decidua is only slightly hemorrhagic.

(5) The best examples of hydatiform villi which are already vesicular in form are found near the basalis, which, like all the rest of the decidua, has undergone autolysis and shows a few small areas in which there is an increase in round cells. Otherwise no evidence of infiltration was noticed. Some of the villi and membranes contain small numbers of atypical Hofbauer cells, and the stroma of all the villi is degenerate. The epithelium is not well differentiated and shows no evidence of unusual growth. The trophoblastic nodules also are degenerate and no remnants of an embryo were seen. A fair quantity of ill-preserved blood is found between the villi.

(6) Hydatiform degeneration with slight infiltration and autolysis of the decidua.

No. 1005.

(1) H. B. Titlow, Baltimore, Maryland.

(2) A 48×36×35. mm.

(4) On cutting the clot, "caseous magma" welled out, clotting immediately in the bichloride in which the clot had been placed. No embryo was found in the necrotic contents, which apparently represents the degenerate conceptus.

(5) Microscopic examination reveals nothing but the very degenerate vesicles with villi and decidua.

GROUP 4.

No. 11.

(1) F. E. Kittridge, Nashua, New Hampshire.

(2) A 10×7×7 mm.; embryo 0.8 mm.; umbilical vesicle 1.5×1 mm.

(3) Patient aged 25; menses regular every 4 weeks, periods lasting from 4 to 5 days. She gave birth to a child Spetember 19 and had the first recurrence of menstruation December 19. The second period followed on January 25, was very profuse, and lasted until February 1. She missed her next period, concluded she was pregnant, and called upon the physician a few days later. March 1 she fell and hurt herself, and during the night had a scanty flow. This recurred each day, and on March 7 she passed the ovum.

(4) The ovum is very large for its age, having a long diameter of 10 mm. and a short diameter of 7 mm. It is covered with villi only around its greatest circumference, having two spots without villi, as was the case with Reichert's ovum. The villi of the chorion are from 0.5 to 0.7 mm. long, branched and somewhat fibrous in structure. Upon opening the chorion it was found that the embryonic vesicle was situated just opposite the edge of the zone of villi. About it there was a considerable quantity of magma réticulé which was not removed. The portion of the chorion to which the vesicle was attached was cut and from the sections a reconstruction made in wax.

(5) The sections and reconstruction show that the embryonic vesicle is attached to the chorion by means of a stem. The greater part of the vesicle itself is composed of two layers, ectoderm and mesoderm. In the neighborhood of the embryonic stem there is a third outer layer which shows all of the characteristics of the ectoderm. Just beside the attachment of the vesicle to the stem there is a sharp, deep, and narrow invagination of all three embryonic membranes. Within the stem a sharply defined allantois communicates with the cavity of the vesicle just below the cavity of the ectoderm. The ectodermal plate of the evagination is very broad, but not of equal thickness throughout. It extends to the outside of the vesicle and ends quite abruptly in the neighborhood of the stem. The blood-vessels of the mesodermal layer extend to the stem, but do not enter it, nor are there any blood-vessels in the chorion. Since the first publication of this specimen our studies, both of normal and pathological material, have been greatly extended, and seem to prove even more clearly that this specimen must belong to the pathological class. The other pathological specimens in our collection, as well as the perfect, normal specimen described by Peters, all speak for this conclusion. Yet the presence of all three blastodermic membranes, with blood-islands in the mesoderm and an allantois in the embryonic stem, indicate that the specimen can not be far from the normal, but represents the earliest changes in the blastodermic membranes of an ovum of the Peters stage under pathological conditions. The villi coalesce and are matted somewhat. The chorion is macerated.

No. 14.

(1) J. Friedenwald, Baltimore, Maryland.

(2) A 30×30×30 mm.; within is a small double vesicle with a short pedicle 1.5 mm. in diameter.

(5) The mesodermal layer of the chorion is thin and decidedly fibrous, with but few cells scattered through it. There are groups of cells in the chorion at the base of the vesicular embryo. The walls of the vesicle are thick, without blood-islands, and covered with a single layer of epithelial cells which have fallen off at points. Scattered throughout the mesoderm are numerous cells. At the base of the vesicle there are a few blood-spaces containing blood-cells. At the base of the larger vesicle is a large closed space. A similar space lies immediately below the smaller vesicle. The small embryonic nodule shows but slight differentiation, and the whole specimen is considerably macerated.

No. 24.

(1) C. O. Miller, Baltimore, Maryland.

(2) Chorion 21×16×5 mm., with vesicular nodule.

(4) The ovum was completely covered with villi which branch a number of times. Upon opening the specimen, it was found that the coelom was filled with magma réticulé of moderate density; no trace of an embryo could be found. When placed in direct sunlight a small nodule became visible. The walls of the vesicle are composed of three layers, the outer being greatly thickened at points, but retaining sharp borders. The mesoderm is hypertrophic. The inner layer is irregular—thick and thin—with a tubular branching process which extends to the stem of the vesicle. There are blood-islands in the vesicle and stalk, and the vessels extend to the villi of the chorion. The trophoblast is very extensive, forming large buds upon the chorion as well as upon the villi. At points these buds coalesce to form islands, the centers of which are composed of a necrotic mass filled with fragmented nuclei. The amnion is absent, but a remnant of the allantoic stalk is found in the chorionic membrane. A small mass of tissue near the yolk-sac, and continuous with it, may be a remnant of the embryo. This shows but little differentiation. The villi show typical hydatiform degeneration.

(6) Hydatiform degeneration.

No. 25.

(1) J. W. Lord, Baltimore, Maryland.

(2) A 25×25×25 mm., with pedicle 6 mm.

(4) The ovum is covered entirely with long villi, and one side of it is hemorrhagic. The pedicle within shows all the characteristics of the umbilical cord of an embryo 5 weeks old. No trace of an embryo, however, could be found, but at the free end of the pedicle, which has very ragged edges, are a number of cells. The amnion lines the entire coelom and is reflected over the pedicle, just as it would be over a normal cord.

(5) Sections show that the club-shaped, cylindrical body is in fact the cord with its blood-vessels and amnion The free end of the cord is rich in round cells, appearing much like the granulation tissue of healing wounds. At this point the end of the cord is infiltrated with cells, in addition to the nucleated cells of the cord. It appears as if the embryo had gradually fallen off, piece by piece, leaving the ragged stump of a cord, the blood-vessels of which are but sparsely filled with blood. At the base of the cord there is a remnant of the umbilical duct. The chorion apparently is normal, but macerated.

No. 32.

(1) W. D. Booker, Baltimore, Maryland.

(2) Ovum 30×30×30 mm.; within is a pedicle 9×2 mm.

(3) Patient is a colored woman. Last menstruation began December 26 and lasted 4 days, the usual duration being from 4 to 5 days. Cohabitation with husband December 12 and January 9. Hemorrhage began March 14 and continued until the 18th, when the abortion took place. Time between beginning of last period and the abortion, 82 days.

(4) Within the ovum was a large pedicle 9×2 mm., which had every appearance of the normal umbilical cord of an embryo 25 mm. long. The age of the ovum, as estimated by the menstrual history, calls for a cord of this size, but the chorion is undersized.

(5) There was no embryo, but at the point where the cord should be attached to the body is a mass of cells, making it appear as though the embryo had sloughed away. At this point the blood-vessels are greatly distended with blood, which permeates also into the surrounding tissues. Within the cord is a large as well as a smaller space. The mesoderm of the chorion and villi is fibrous and the chorion thickened. The stroma of many of the villi is decidedly dense, suggesting "granular hyperplasia." The vessels are degenerate or altogether absent.

No. 37.

(1) G. M. Gould, Philadelphia, Pennsylvania.

(2) A 25×18×15 mm.

(4) The entire ovum is covered with villi which appear normal in form, both to the naked eye and under the microscope.

(5) The specimen was macerated considerably, but the thick sections made of it are extremely instructive. The embryonic mass within proved to be an atrophic cord, embryo and umbilical vesicle. The cord with its blood-vessels passes directly over into the head end of the embryo, which contains but a rudimentary nervous system. The mesodermal tissues are characteristic and the form of the pharynx and the lower jaw is recognizable. From this region two branchial arteries pass into the cord. A single vein, however, extends from the cord directly into the center of the body and ends just below the lower jaw. There is no heart, liver, myotomes, or lower end of the body, these being replaced by the cord. The arteries are empty and the vein is distended with blood.

No. 58.

(1) W. Howard, Cleveland, Ohio.

(2) A 20×15×12 mm.

(3) The specimen was from the first pregnancy of a woman who has been married one year. The duration of the menstrual period was usually 3 to 4 days, the last one having ended July 25. The August and September periods were passed, and September 30 she had a hemorrhage which she believed to be the usual menstruation; this ended October 1 with abortion of the ovum. The time between the beginning of the last period and the abortion is 71 days. Cohabitation July 25 to August 5, and again on August 15, or several days before the first period lapsed.

(4) The ovum was only partly covered with villi and filled with a jelly-like mass of magma. Floating within this mass was a large vesicle, 6 mm. in diameter, with transparent walls. This vesicle in turn was partly filled with granular magma.

(5) The trophoblast is excessive. The mesoderm of the chorion and inclosed vesicle is very fibrous. There are blood-islands and a cavity lined with epithelium in the stem of the vesicle. The main portion of the vesicle is composed of two layers, but near the stem three layers are present. The mesoderm of the villi is hyaline and edematous, and between them is a stringy mass of fibrin, rich in leucocytes. Some of the villi have coalesced and the stroma of others suggests "granular hyperplasia." The amnion is very much larger than the embryo. Both chorion and amnion show some maceration. The embryonic mass at the base of the amnion is well preserved and contains blood-cells and a small cavity.

No. 78.

(1) A. P. Stoner, Harlan, Iowa.

(2) A 36×33×13 mm.; B 1 mm.

(3) Last menstrual period December 1; abortion took place February 26 following. The sac was perfectly smooth when passed. After the abortion two or three pieces of decidua and placenta were passed, weighing together about 30 grams, the right quantity, it seemed, for a 10-weeks' ovum. The woman's husband had been absent for over 10 weeks, making the specimen at least that old. It appears as if there had been an arrest of development of the embryo and that the membranes continued to grow.

(4) When the specimen came to the laboratory the walls were perfectly smooth, without any villi whatever. The cavity was filled with a clear fluid, and within this was attached a small double vesicle, measuring 1×0.6 mm. This was embedded and cut in serial sections.

(5) The nodule within is covered with a single layer of epithelial cells which become thickened over the pedicle. At one point the thickening is greatly increased, and immediately below it there are two small vesicles lined with epithelial cells. The main cavity of the vesicle is lined with a layer of cubical cells, and is filled with a considerable quantity of round cells. This cavity is hour-glass in shape and extends to the walls of the chorion. The mesoderm of the vesicle is increased in quantity. At the base are several blood-spaces filled with blood. The chorionic membrane is absent, which accounts for the smooth nature of the specimen; but a few detached, degenerated villi are present.

No. 111.

(1) Dr. Gray, Washington, District of Columbia.

(2) B 3 mm. long.

(5) Specimen is a greatly dissociated embryo, in which there are two very large cavities and a remnant of the central nervous system, entirely filled with cells. The amnion is present in some of the sections, but in all of them the chorion is absent. No decidua accompanies the embryo.

No. 134.

(1) G. N. Sommer, Trenton, New Jersey.

(2) Ovum 17×11 mm., with compressed vesicle measuring in sections 9 x 3 mm.

(3) A number of sections of this unique specimen were received from Dr. Sommer with the statement that the ovum had been passed by a young multipara, after con-

siderable pain and hemorrhage due to the introduction of a bougie to produce abortion. The monthly period had been five days overdue when the abortion occurred. The bougie had been introduced several days earlier.

(5) In stirring up the ovum the woman punctured it, and it then became filled with maternal blood, which formed a clot around the embryo. The leucocytes invaded the walls of the ovum, the stem of the yolk-sac, and even the blood-vessels of the embryo, and show all stages of fragmentation within the embryonic tissue. The yolk-sac itself is most interesting, as it shows the effect of an infraction upon a very young normal embryo. The stem of the vesicle is quite extensive, and in it are embryonic blood-vessels filled with blood. Many of them extend into the chorion and some into the villi. The walls of the yolk-sac are composed of three distinct layers. The inner is composed throughout of a single layer of sharply defined cubical epithelium—the entoderm. Immediately next to this is an extensive mesoderm which continues into the mesodermal layer of the stem to the chorion. Near the attachment of the vesicle to the chorion there is a sharp evagination of the vesicle, which is lined with a thick layer of epithelial cells—the ectoderm. This layer lines only the evagination and does not extend over the rest of the vesicle. Beyond and on the distal side of the evagination the mesoderm is arranged in five groups of cells which in every way suggest myotomes. In this region there are embryonic blood-vessels filled with blood. The syncytium is very extensive.

The blood-clot from the mother's blood, within the cœlom, is recent, as is shown by the fact that many red blood-corpuscles are present. In the periphery of the clot, next to the chorion, the red corpuscles are partly broken down and appear as an imperfect granular detritus containing a network of fibrin. There are as yet no pigmentary changes in the tissues adjacent to the clot. The latter extends through a tear in the chorion into the cœlom, and as this portion is approached it is noticed that its characters change. The red blood-corpuscles diminish in number, and the main coagulum consists of leucocytes which extend through the surrounding tissues. This mass of leucocytes also extends along the border of the red clot into the cavity and walls of the vesicle. The blastoderm cells are intact on one side of the vesicle, whereas on the other they have suffered desquamation and have retracted from its walls. A part of the leucocytes composing this part of the clot are in a very imperfect state of preservation. They show great irregularities in the forms of their nuclei and are in a state of fragmentation. Fragmented leucocytes extend throughout the clot, a great portion of the chorion, and through the walls of the embryonic vesicle. The tissue elements of the embryo are for the most part well preserved. There is no evidence of extensive necrosis. Occasionally where the clot of red and white corpuscles and fibrin becomes clearly intermingled with the villi of the chorion the syncytial cells stain imperfectly. The blood-vessels of the chorion contain numerous leucocytes, constituting in some instances what appear to be leucocytic thrombi. One section was stained for bacteria, but none were found. The process as a whole is to be interpreted as an acute hemorrhagic inflammation of the embryonic structures. The large number of leucocytes undergoing fragmentation indicates that the inflammatory irritant was of a severe nature and had acted with a considerable degree of intensity, as is shown not only by the rich immigration of leucocytes, but by the severe retrogressive changes which they have undergone.

No. 161.

(1) H. F. Cassidy, Baltimore, Maryland.
(2) A 50×25×25 mm.; B 10 mm.
(3) "Last period at the end of August. Abortion November 17. After missing the next period patient took medicine and had a rubber tube introduced into the uterus. Purulent leucorrhea during the past six months.

(4) The entire ovum was covered with hard clots of blood, but on one side the villi appear to be normal. Upon opening the ovum a mass measuring 10×5×5 mm. was found attached to its walls.

(5) Upon sectioning, this proved to be a strangulated embryo of the fifth week, filled and covered with round cells. These cells have obliterated the structure of the head entirely, but as the tail end of the body is approached the outline of the organs still can be followed. The villi of the chorion are enveloped in a great mass of blood and pus, and the syncytium is excessive. Within the stroma of the villi at many points are numerous round cells which appear to be migrating cells from the embryo. The vessels of some of the villi and of the chorionic membrane appear to be normal.

(6) Decidua necrotic and infiltrated.

No. 162.

(1) A. Wanstall, Baltimore, Maryland.
(2) A 70×30×30 mm.; B 1 mm.
(3) "Last period from September 2 to 7, five days being the usual length of periods. The woman began bleeding November 9 and passed the specimen on November 22. She is the mother of five children and states that this is the only time she has aborted. There is not the slightest indication of uterine disease."

(4) Within the specimen is a cavity measuring 35×12×12 mm., lined with a smooth wall and filled with a jelly-like substance, within which is a very small embryo.

(5) The sections show a remarkable atrophy of the embryo and umbilical vesicle. The chorion is very thin and composed of mesoderm only. The villi and epithelial cells are lacking, but in their place is a thick layer of maternal blood. The entire chorion is lined with an amnion, and into its cavity the nodule-like embryo projects. Its tissues are not uniform, being thickened at some points, necrotic at others, and mucoid at others. Throughout the center of the nodule are some capillaries filled with blood. At the point of juncture between the amnion and chorion there are three projections from the embryo into the cœlom: (1) the umbilical vesicle; (2) the allantois; (3) the heart. That the second is the allantois is indicated by its cavity which is multiple at points. The heart is within a pocket of the cœlom and has an irregular lumen which is well filled with blood. At the base of the nodule there is a short tube which communicates with the allantois—the intestine.

No. 166.

(1) H. F. Cassidy, Baltimore, Maryland.
(2) A 40×40×40 mm.; B 2.5 mm.
(3) Last period October 18; on December 29 there was a discharge of blood which continued until the 31st, when the mole was expelled.

(4) The mole is composed of very thick, fleshy walls, within which there is a cavity with a smooth wall, measuring 30×20×20 mm. On one side there is a small atrophic embryo 2.5 mm. long.

(5) The sections of the chorion show that its villi are well formed and are embedded in a mass of blood. Possibly the syncytial layer of epithelium is increased. The cœlom side of the chorion is mooth and in contact with the amnion. Attached to the latter is the embryonic mass or remnant which does not reach to the chorion. No umbilical vesicle is to be found. The amnion and embryo are completely separated from the chorion, which is non-vascular. The embryo is nodular in form, being attached throughout half its length to the amnion, and passes through the latter. In the center of the embryo there is a solid column of cells quite sharply defined—the remnants of the central nervous system. At the tail end of the embryo there is a blind tube—the allantois. The cœlom of the embryo, which lies as a pocket on its ventral side, contains an irregular sac which may be either the heart or the umbilical vesicle, probably the former.

No. 189.

(1) T. E. Oertel, Augusta, Georgia.
(2) A 28×25×15 mm.; B 4 mm.
(4) The ovum, filled with granular and reticular magma, contains a deformed embryo lying within a distended amnion, 8 mm. in diameter.
(5) The umbilical vesicle and amnion appear to be normal for an embryo of this size, but the body is greatly deformed, the central nervous system is open throughout its extent and partly encircles the dwarfed embryo like a broad hoop around a ball. A number of the motor roots of the spinal nerves are developed, more in the region of the tail than elsewhere. There are no cranial nerves. The heart is a vesicle filled with blood, hanging into the cœlom and slightly attached to the body-wall. Its vascular connection with the body is entirely cut off. The blood-vessels of the body are irregular in shape and entirely changed from the normal type. They are filled with blood, which extends through their walls into the surrounding tissues. The branchial arches correspond to an embryo of this size. There are still traces of optic vesicles, chorda, and possibly allantois, the liver, stomach, and intestines having degenerated.

No. 198.

(1) R. E. Larsen, Chicago, Illinois.
(2) A 25×25×25 mm.
(4) The interior is filled with considerable reticular, and large clumps of granular magma. Embedded in this is a large cylindrical pedicle, 7 mm. long, bent upon itself. Sections of the specimen show the pedicle to be the umbilical cord rounded off at its former juncture with the embryo.
(5) The mesoderm of the cord, thickened chorion, and villi is fibrous, having also an excess of spindle-shaped cells. The blood-vessels are all very large, those of the villi as well as most of those of the main wall being gorged with blood. The large blood-vessels of the cord are empty. Within the cavity of the amnion, scattered throughout the magma, are numerous flakes of tissue of the embryo and a great many free cells.

No. 244.

(1) M. Brödel, Baltimore, Maryland. (From Dr. Kelly's sanitarium.)
(2) B 4 mm.
(4) The specimen is inclosed in the amnion, which measures 25×15×15 mm., and is surrounded by a mass of granular magma.
(5) The sections show the amnion attached along most of the ventral side of the embryo, somewhat as it is in the normal specimen at the end of the second week. The central nervous system is still quite sharply defined, being more characteristic in the head than in the trunk. The heart is composed of a solid mass of cells in the front of the embryo, and extends as a horn-like process to the head. Between the heart and the body there is a large group of epithelial cells, in which are scattered some small round cells, probably the remnant of the liver. Otherwise the tissue of the embryo is of even structure, with an occasional necrotic area. Most of the epidermis is missing. Neither umbilical cord nor umbilical vesicle is present, the free embryo being attached to the amnion only.

No. 247.

(1) W. S. Seymour, Trappe, Maryland.
(2) A 40×40×17 mm.; B 2.5 mm.
(4) The ovum was found filled with granular magma, and in the center, far away from the chorion, there is a free body.
(5) Sections of the chorion show that it is slightly macerated, and that the stroma of the villi has undergone hydatiform degeneration. The villi are without capillaries and the amnion is missing. At points between the villi the trophoblast cells form mounds below the epithelium, which have a tendency to penetrate the mesoderm of the chorion. The pear-shaped body is probably the embryo. It contains cavities lined with epithelium and surrounded by a considerable amount of mesoderm which contains numerous blood-vessels filled with blood. There are some accessory vesicles in this layer similar to those found in No. 78, described above.
(6) Hydatiform degeneration.

No. 253.

(1) M. Brödel, Baltimore, Maryland.
(2) A 35×30×15 mm.; B 4 mm.
(5) Chorion and villi are somewhat hyaline, with only indications of blood-vessels within them. The amnion, which measures 19×13×13 mm., is attached at one point, has hyaline walls, and does not contain the embryo. The latter is a swollen infiltrated specimen of the third week, with no brain and little of its spinal cord left. The rest of the structures (heart, cœlom, and Wolffian body) are quite sharply defined, but are well infiltrated with round cells. Most of the epidermis is intact. The arm-buds are well defined.

No. 264.

(1) Wm. S. Gardner, Baltimore, Maryland.
(2) A 25×20×15 mm.; B 2 mm.
(3) Last period occurred August 12, but menses had been irregular for three months before.
(5) The cœlom is filled with a hard hyaline magma, rich in round cells, in which is embedded the umbilical vesicle, measuring 2.5 mm. in diameter. The chorion is thickened, fibrous, and covered with some villi. These also are fibrous and most of them are non-vascular.
(6) Decidua infiltrated.

No. 275.

(1) W. Tobie, Portland, Maine.
(2) A 40×30×25 mm.; B 8 mm. (straightened).
(4) The chorion of this specimen, which was thought to be 2 months old, is thin and covered with some villi embedded in much blood. In structure it is fibrous, with a diminished amount of epithelium, and contains no blood-vessels. Within is an amniotic cavity, filled with a clear fluid, into which the deformed embryo projects. The exocœlom is from 2 to 3 mm. wide and is filled with typical magma réticulé.
(5) The structures of the embryo form almost a continuous mass of tissues, in which the irregular central nervous system can still be outlined. Most of the epidermis is still intact. The lenses of the eyes form small pearls inclosed in capsules lying beneath the skin. In front of them are two small bodies connected with the epidermis, which might pass for lenses, but which are probably olfactory pits. In a number of places the tissues are fibrous. The decidua shows some infiltration and the villi are decidedly fibrous, non-vascular, and glued.
(6) Mild infiltration.

No. 291.

(1) A. Wegefarth, Baltimore, Maryland. (Brödel collection.)
(2) B 5 mm.
(4) The membranes are devoid of villi and very thin. The umbilicial vesicle is necrotic and filled with an irregular mass.
(5) Sagittal sections of the embryo show that the specimen is pathological, its head being rounded and the epidermis having fallen off. The spinal cord is distended and the brain is solid. Veins and arteries are greatly distended with blood. The eye-vesicles are atrophic and the lenses dissociated, but encircled by a sharply defined capsule.

No. 292*a*.

(1) J. P. West, Bellaire, Ohio.
(2) A 50×30×30 mm.; B 3.5 mm.

(3) "Patient 31 years old, married 10 years, but has never been pregnant before. Last period November 10, and on December 24, after a hard day's work, she had a sudden gush of blood, and since then has been wasting at times until abortion, February 4."

(4) Chorion is partly covered with long villi, which are fibrous in some places and edematous in others. The amnion within, which occupies the entire cavity of the chorionic vesicle, is partly filled with granular magma through which can be seen the outlines of an atrophic embryo.

(5) Sections show that the brain and most of the spinal cord have been destroyed. In the middle of the embryo the aorta and cœlom are sharply defined, but elsewhere the tissues are entirely obscured by numerous round cells. The epidermis is intact. The decidua is decidedly infiltrated and also contains a few large local accumulations of leucocytes.

(6) Marked infiltration.

No. 304.

(1) G. L. Hunner, Baltimore, Maryland. (Brödel collection.)

(2) A 15×7×6 mm.; B 4 mm.

(4) The specimen is surrounded by much decidua, which is infiltrated with leucocytes.

(5) The stroma of the villi and chorion are decidedly macerated and degenerate, with remnants of blood-vessels within them, and are covered with an active trophoblast. The decidua is encircled with pus and fragments of uterine mucous membrane. The ovum is partly filled with magma réticulé, in which is embedded an umbilical vesicle 2 mm. in diameter, attached to the remnants of an embryo without myotomes. The neural canal is present and the body runs out into a stem containing a tube (allantois) which does not attach itself to the chorion. Remnants of an amnion are present. All in all, the embryo appears to be much like Graf Spee's specimen, which is 1.54 mm. long. No trace of a heart could be found, but there are numerous blood-islands in the umbilical vesicle and remnants of blood-vessels in the chorion.

(6) Severe infiltration.

No. 309.

(1) H. S. Steensland, Syracuse, New York.

(2) A 23×20×20 mm.; B 4 mm.

(4) This specimen, apparently normal, had been in alcohol for three or four years when received, but was well preserved. The amnion filled the entire chorion; otherwise the interior also appeared normal.

(5) Section showed, however, that the dilated amnion was accompanied by marked changes in the embryo. All of the tissues are infiltrated with round cells, obliterating, to a great extent, both the tissues and the organs. The central nervous system is markedly dilated and filled with round cells. In front the walls are broken and the round cells extend into the tissues of the front of the head. The eye and ear vesicles also are dilated and filled with round cells. No trace of a lens is seen, and the ear-vesicle has two sprouts on its ventral side. The whole epidermis is present.

The specimen is markedly dissociated; only the central nervous system, the head, and perhaps some hepatic remnants are present. The embryo apparently was sessile upon the amnion. All of the chorionic membrane that was mounted contained a network of vessels, and some of the villi also are splendidly vascularized. A continuous network of vessels containing some blood-cells is found just near the amniotic surface of the chorion, as shown in figure 82. The epithelium of the chorionic vesicle is full of syncytial buds and some maceration is present, but there also is very evident hydatiform degeneration.

(6) Decidua absent. Partial hydatiform degeneration.

No. 377a.

(1) J. L. Crawford, Cedar Rapids, Iowa.

(2) A 30×22×14 mm.; B 0.5 mm. long.

(4) The specimen is well covered with villi, which, to the unaided eye, appear quite normal. The interior of the ovum contains a considerable amount of reticular magma, within which is embedded a large sac (5 mm. in diameter) containing a nodule (0.5 mm. in diameter)—the embryo.

(5) Upon microscopic examination the villi are found to be very fibrous and tipped with trophoblast; at points the latter forms islands with necrotic centers. Sections show that the whole chorion is lined with the amnion except at the point of the inclosed sac, which proves to be the exocœlom. The embryo is composed of a mass of cells which extend into the mesoderm of the chorion. It may represent the last remnant of the umbilical vesicle No traces of blood-vessels are seen in any portion of the embryonic mass, nor in the mesoderm of the chorion.

No. 425.

(1) M. Brödel, Baltimore, Maryland.

(2) A 15×12×8 mm.; B 1 mm. long.

(4) The ovum, which is covered with a few villi and some decidua, contains a nodule about 1 mm. in diameter.

(5) Sections show that it is lined with amnion and contains at one point the atrophic nodular remnants of an embryo which is much degenerated. These remnants consist of an open neural groove, on either side of which are two large veins filled with blood. No remnants of any organs are present. Immediately below the neural body is a sharp ring of tissue which may represent the chorda. The amnion is fibrous and adherent throughout to the chorion, which is covered with thin, fibrous degenerate villi. The entire ovum is encapsulated in fragments of decidua, which shows very extensive inflammatory changes.

(6) Severe infiltration.

No. 433.

(1) D. S. Lamb, Washington, District of Columbia.

(2) A 23×21×11 mm.; B 4 mm.

(3) Patient is a multipara, 30 years old, whose menstrual period was one week overdue.

(4) The ovum is well covered with villi, and its anterior lined by a smooth chorionic membrane, to which is attached an irregular body about 1 mm. in diameter and 4 mm. long. There is practically no magma present.

(5) Sections of the chorion show that the villi are practically normal in form and arrangement, the tips being covered with a very liberal amount of trophoblast. However, between the villi there is some fibrinous substance through which are scattered numerous round cells and in which are embedded masses of syncytium. The embryonic mass is well preserved, and in it there are several gland-like bodies, probably the allantois. This embryonic tissue appears partly like an embryo and partly like a hypertrophic umbilical vesicle. The tip is ragged, indicating that most of the embryo has fallen off. At its point of attachment to the chorion there is a delicate membrane folded upon itself many times, which no doubt represents the collapsed amnion. There are but few blood-vessels within the villi of the chorion.

(6) Very early hydatiform degneration. Decidua absent.

No. 433a.

(1) D. S. Lamb, Washington, District of Columbia.

(2) A 27×25×15 mm.; B 3 mm.

(3) Patient has one child, 3 years old. Her regular menstrual period occurred February 1; there was a slight show March 1, lasting a few hours, and on March 15, after running to catch a car, the flow came on and continued until March 21, when the specimen was passed.

(4) The ovum is well covered with villi which are normal in form. Within there is a large quantity of reticular magma encircling several nodules, one of which appears to be the embryo. This is inclosed with its amnion and measures 3 mm. in length.

(5) The villi are non-vascular, have undergone mucoid degeneration, and are stuck together by a very pronounced mucoid mass, within which radiate numerous syncytial cells. At certain points these are covered with maternal blood; otherwise there is no indication of inflammatory changes. The form of the embryo and amnion appear to be quite normal, but the former is markedly dissociated. Its blood-vessels, including those of the chorion, are gorged with embryonic blood. The dissociation is so marked that practically all of the organs are involved and more or less obliterated, although their main form can still be made out. The lumen of the brain and cord are mostly filled with cells, which also invade the otic vesicle. The process of dissociation has involved the eye-vesicles to such an extent that they are entirely obliterated. At this point the cells of the brain seem to shade over to the mesenchyme of the head without any line of demarcation.

(6) Decidua absent. Probable hydatiform degeneration.

No. 436.

(1) J. Park West, Bellaire, Ohio.
(2) A 65×40×30 mm.; B 2.9 mm. long.
(3) "Patient a Russian Jewess, 31 years old, who has four children, the youngest 18 months old. In July 1907 she aborted at 2 months; in January 1908 at 3 months; this specimen May 17, 1908, at 2 months. She appears to be healthy and shows no evidence of syphilis."

(4) The large fleshy ovum is partly covered by decidua with atrophic villi. Its wall is thin, and when opened it was found to contain dense reticular and granular magma. On one side is a small nodule about 2.9 mm. in diameter, which encircles an atrophic embryo. The gross appearance of the embryonic mass looks much like a fish embryo. The yolk-sac is distended, has thickened walls, and is attached to the chorion by means of a pronounced stalk. The embryo lies spread upon this vesicle with head and tail ends protruding somewhat.

(5) Sections of the chorion show that both the chorionic membrane and some villi are fibrous and stuck together by a large quantity of mucoid tissue, within which are numerous buds of syncytium. The chorionic membrane is very vascular, but few vessels are found within the villi. Sections of the embryonic mass show that the vesicle is directly continuous with the body-wall; that is, the body is distended sufficiently to incorporate entirely the umbilical vesicle. The body-wall is very fibrous and there are several bundles of these fibers which push up the epithelium into papillæ. The central nervous system is more or less dissociated, but can be followed throughout most of the length of the embryo, and occasionally a lumen is present. Its course is interrupted at several points. In the head end there is an additional body, which may represent the pharynx, and which does not communicate with the yolk-sac, but appears to be continuous with the brain-tube; it may possibly belong to the latter. In the ventral midline there is a large single blood-vessel which represents all that is left of the heart. From this other blood-vessels are radiating into the body of the embryo. In the tail end of the embryo the neural tube has a very pronounced lumen, apparently filled with cells. In this region the amnion is continuous with the lateral sides of the vesicle, showing the line of demarcation between the body of the embryo and the yolk-sac. The chorda, eye and ear vesicles are absent. The decidua is somewhat infiltrated, fibrous and degenerate.

(6) Decidua slightly infiltrated.

No. 440.

(1) W. Preston Miller, Hagerstown, Maryland.
(2) A 25×20×15 mm.; B 2.5 mm.

(4) The chorion, which appears to be normal, is covered entirely with villi. When opened it is found to contain a great quantity of reticular magma, within which is buried an embryo 2.5 mm. long.

(5) The amnion is greatly distended, showing a marked hydramnios. Sections of the embryo show that it has undergone extensive dissociation, the central nervous system being the only structure that can be made out. Most of it is solid, cells from the wall having completely filled its lumen. In the anterior end of the embryo the eye and ear vesicles can still be outlined, although they are mostly filled with round cells. The chorionic wall and its villi have undergone fibrous degeneration, and few blood-vessels are present.

(6) Hydatiform degeneration. Decidua absent.

No. 441.

(1) J. T. Haller, Davenport, Iowa.
(2) A 17×13×10 mm.; B 2.3 mm.
(4) A transparent sac, about the size of the ovum, protrudes therefrom, and is no doubt the amnion. The ovum contains some granules, and near the attachment of the sac to the chorion there is an embryo, 2.3 mm. long, which is somewhat curled upon itself. Within the chorion there is considerable magma. The hydramnios is very conspicuous.

(5) Sections of the chorion show that its wall is somewhat fibrous, as is also the mesenchyme of the villi. Considerable trophoblast is attached to the tips of the villi, and between them there is a great deal of fibrinous substance intermingled with many leucocytes. Into this substance large buds of syncytium ramify. The tissues of the embryo are greatly dissociated, the central nervous system being composed of a uniform layer of round cells. The spinal cord does not reach to the tail end of the embryo, and the eye and ear vesicles are destroyed. Near the attachment of the embryo to the amnion there is a grouping of small round cells which no doubt represent the heart. In certain places these cells stream into the cœlom, which can barely be outlined. The umbilical vesicle is small and atrophic and attached to the lower part of the embryo.

(6) Hydatiform degeneration. Decidua absent.

No. 504.

(1) H. I. Davenport, Auburn, New York.
(2) A 15×15×15 mm.; B 0.2 mm. long.
(3) Patient 40 years of age; youngest child aged 6 months. Woman menstruated a little about February 3 and missed the next period, which should have come on about March 3. On March 17 passed some blood, accompanied by slight pain in back and over symphysis pubis. The abortion followed the next day.

(5) The entire specimen was cut into serial sections, and in several of these the remnant of a nodular embryo, about 0.2 mm. in diameter, was found. The embryo lies isolated within the extensive magma and contains two cavities. It is markedly macerated. In the region of the nodule there are numerous delicate mesodermal processes from the chorion, pointing towards it and indicating the point of its former attachement. There also seem to be a few blood-vessels in the chorionic wall and in some of the villi. The villi are capped with considerable trophoblast, most of which is atrophic and macerated. There are also numerous buds of syncytium arising directly from the chorionic membrane.

No. 525.

(1) David Jurist, New York.
(2) A 50×35×25 mm.; B 3 mm. long.
(4) The somewhat solid mole contains a clear vesicle 25 mm. in diameter. Its inner surface is smooth, but within the vesicle, which proves to be the amnion, there is considerable granular matter, and attached to one side is a nodular embryo 3 mm. long. On one side of the chorion is a small tuft of villi. Sections of the chorion

show that its wall is very hemorrhagic, the membrane somewhat fibrous, and the villi mostly necrotic, the rest having undergone what appears to be mucoid degeneration The decidua is necrotic and markedly inflamed.

(5) Sections through some tufts of villi show them to be quite normal in appearance, with a great deal of trophoblast between them. The embryo represents a transitional stage between the nodular and cylindrical forms. It is still possible to make out the head end upon microscopical examination. The central nervous system is partly dissociated, but throughout the embryo more or less of the tube-wall is still indicated. Some portions of this wall are broken through, and the contents are continuous with the surrounding mesenchyme. In the other portion of the embryo the spinal cord is double, but only one eye-vesicle is present, and that one very atrophic; the other has entirely degenerated. Lens and otic vesicle are lacking, as is also the heart. The cœlom is fairly well formed, and the ventral region of the embryo is filled by a small but much distended umbilical vesicle. It appears as though the embryo did not develop after it had reached a growth of 1.5 mm., but simply distended the cavities laid down at that time. The amnion is somewhat fibrous, and the umbilical vesicle does not protrude into the exocœlom, but seems to be contained within the body of the embryo. Along the dorsal side of what appears to be the pharynx are two very large blood-vessels filled with blood, which extend for a short distance in the middle of the embryo.

(6) Marked infiltration.

No. 528.

(1) G. Ackerman, Wheeling, West Virginia.

(2) A 30×20×20 mm.; B 4 mm.

(4) The chorion is covered partly with normally formed villi and partly with blood-clot. The cœlom contains considerable magma and an amniotic cavity about 13 mm. in diameter. Within the amnion are large flakes of sticky magma encircling a knob-like embryo 4 mm. long, which is attached to the amnion at its point of juncture with the chorion.

(5) The chorionic wall and its villi are somewhat edematous and fibrous. There is very little trophoblast, but a small group of quite irregular tufts of syncytium are seen at the tips of the villi and upon the outside of the chorionic membrane. The embryo was cut into sagittal sections and shows extensive dissociation. The only structure which can be made out with certainty is the central nervous system, which reaches through the whole length of the embryo and has a thin-walled tube filled entirely with round cells. The eye and ear vesicles are absent, but in their places there is the distended brain-tube broken through at points, where the cells within the lumen mix freely with those of the mesenchyme. There are several large blood-vessels within the embryo, and also an indication of the heart.

(6) Infiltration.

No. 529.

(1) M. B. Wesson, New York.

(2) A 25×15×15 mm.; B 3 mm. long.

(4) Chorion is partly covered with long, slender villi and the cœlom entirely filled with dense, irregular reticular magma. On one side of this were found two small bodies about 2 mm. apart, at first thought to be the umbilical vesicle and the embryo.

(5) Serial sections were cut of the entire specimen and those containing the embryo were preserved. The chorionic wall is fibrous, but the villi appear to be more nearly normal, the larger ones containing many sprouting blood-vessels. Attached to the villi is a considerable quantity of syncytium and a small piece of decidua which shows a marked inflammatory reaction. The two bodies seen within the ovum before the sections were cut prove to be two portions of the umbilical vesicle, one of which is free and the other attached to the chorion by means of a very pronounced pedicle. The pedicle contains a marked allantois and is rich in blood-vessels, which branch out into the adjacent chorion and villi. The other portion of the umbilical vesicle contains blood-vessels, the blood-islands within the pedicle apparently being separated from the blood-vessels. In addition to these two bodies a third was found within the specimen, which represents the lower part of the embryo, having a sharply defined spinal cord, the chorda, and myotomes. It appears to belong to an embryo about 3 mm. long.

(6) Marked infiltration; hydatiform degeneration.

No. 543.

(1) G. C. McCormick, Sparrows Point, Maryland.

(2) A 70×30×25 mm.

(3) Menstrual periods irregular; last one occurred on June 10, but continued for one day only. Abortion August 24.

(4) Pear-shaped specimen, the stem of which is solid and comprises about one-half of the entire mass. The other half contains the chorion, which is about 25 mm. in diameter and has a cavity 17 mm. in diameter. This is filled with delicate but pronounced reticular magma, in the center of which is a nodular embryo 3 mm. long.

(5) Sections show the chorionic membrane to be normal in structure, but the villi are fibrous and matted together. They are encircled by a zone of fibrinoid substance, followed by one of decidua which is extensively inflamed. The intervillous spaces are partly filled with maternal blood, in which there is a very great excess of leucocytes. In the fresh blood grow numerous buds of syncytium. What was taken for a nodular embryo seems to be a free umbilical vesicle, lying near a thin amnion which is thrown into numerous small folds. Outside of this are small remnants of a macerated embryo which is probably not over 2 mm. long. Where the umbilical vesicle and the amnion come together there is a thickening, and therein are several large blood-vessels. We have here a case of marked hydramnios with disintegration of the embryo, leaving the umbilical vesicle.

(6) Marked infiltration.

No. 568.

(1) Solomon Dodds, Baltimore, Maryland.

(2) A 48×36×21 mm.; B 0.5 mm. long.

(3) The patient was 36 years old and had been married 6 years. Pregnant four times; two living children. The other pregnancies ended in abortion, from one of which the present specimen came. Last period November 23 to 30. There was some bleeding in February and the abortion followed on February 6.

(4) The ovum is within the decidua, 64×42 mm., and measures 48×36×21 mm. It is completely covered with villi which branch two or three times, and lying free within it is a large, smooth vesicle equally distended, 27 mm. long and 17 mm. wide. Within the vesicle, to one side and at its point of attachment to the chorion, there is a small nodule about 0.5 mm. in diameter. This is the remnant of the embryo. The vesicle is undoubtedly the amnion.

(5) Sections through the chorion show the tissues to be atrophic and hyaline, with a small amount of trophoblast. The tips of the villi are embedded in a layer of fibrinoid substance which, in turn, is covered with a thin layer of decidua showing inflammatory changes. There is a great deal of reticular magma between the chorion and the amnion. The small, knob-like embryo has an irregular shape, and its main portion is taken up with a large, irregular vesicle filled with cells and lined with several layers of epithelium. No doubt this is a remnant of the central nervous system. There seems also to be present a rudimentary allantois, a body cavity, a few blood-vessels, and a very small, irregular umbilical cord.

(6) Marked infiltration; some hydatiform degeneration.

No. 569.

(1) W. P. Miller, Hagerstown, Maryland.
(2) A 30×26×20 mm.; B 2.5 mm. long.
(3) Patient had been married about a month.
(4) The ovum appears to be normal. It is completely covered with villi which branch two or three times, and the interior is filled with a dense mass of reticular magma. At one side is a small nodule 2.5 mm. long and 2 mm. in diameter, which appeared to be the remnant of the embryo. There are other opaque granules scattered through the magma. In order to determine which of these may be the remnant of the embryo, it was necessary to stain the entire specimen and cut it into serial sections.
(5) The chorionic wall and the villi are edematous, and some of the latter have undergone mucoid degeneration. There is not very much trophoblast attached to the villi. A great quantity of reticular magma is in the exocœlom. Sections of the embryo show that the brain is greatly distended and its ventral wall is disintegrating. This enlargement seems to be mostly in the hind-brain, the fore-brain being reduced in size. It ends in two extremely small eye-vesicles. The ear-vesicles are filled with cells. The spinal cord can be followed only a short distance into the body of the embryo. In the neck there are two very small bilateral blood-vessels. In the body the cœlom is pronounced, and suspended in it is a very small atrophic heart. The intestine is not present, but the lower part of the body is somewhat injured and the structures here can be followed with precision.
(6) Hydatiform degeneration. Decidua absent.

No. 573.

(1) G. Ackerman, Wheeling, West Virginia.
(2) A 46×17×17 mm.; B 8.5 mm.
(3) Period has been two weeks overdue.
(4) The specimen, fleshy and ruptured, contained a large cavity, with an atrophic embryo with a knob-like head, and arm and leg buds missing on the right side.
(5) The chorionic wall is hyaline and covered with completely degenerated villi which are matted together with blood-clot and very degenerate decidua, which show some leucocytic infiltration. The embryo is markedly dissociated, the brain being practically solid. The fore-brain is dragged out into a long process, and on each side there is a very small rudimentary eye with lenses attached to the skin. The dissociation of the eye-vesicles is so extreme that it is difficult to separate them from the surrounding tissue. The limb-buds are very atrophic. The shape of the organs and body is normal, but the tissues are much dissociated. There is a large central space in the umbilical cord filled with débris.
(6) Decidua very degenerate, but probably somewhat infiltrated.

No. 592.

(1) Abraham Poska, Hobson, Montana.
(2) A 47×33×26 mm.
(3) The specimen came from an induced abortion.
(4) One side of the ovum is partly covered with blood-clot, the other with short, apparently normal villi. Its cavity is filled with very dense reticular and granular magma containing remnants of an opaque and apparently disintegrated embryo. After fixation in formalin the magma is somewhat reticular, being intermingled with a very extensive and dense jelly-like substance. There are but few opaque particles to be seen within it.
(5) Sections show the magma to be quite clear, and scattered through it are large strands of cells representing the disintegrating embryo. In one of the sections a faint outline of the peritoneal cavity, encircling the intestine, can be made out. There are also independent blood-vessels. It would seem as though the embryo had been crushed when about 4 mm. long. The chorionic wall is thickened and badly infiltrated with leucocytes on the outside, but these do not enter the cœlom. The wall is covered with villi partly degenerated and partly normal in appearance. Between them there is an inflammatory mass. Where the villi are bathed with fresh maternal blood they are fibrous, with poorly preserved blood-vessels; but many of them contain blood-vessels which are filled with blood, which takes on an intense eosin stain. Scraps of tissue, which appear to be remnants of the amnion, reach from the chorion into the cavity of the ovum.
(6) Severe infiltration.

No. 610.

(1) V. Van Williams, Baltimore, Maryland.
(2) A 23×20×20 mm.; B 3 mm.
(3) Patient has a child about 15 years old. Aborted 4 years ago. Period 3 days overdue.
(4) The entire specimen is pear-shaped, the body being formed by the ovum, covered with a uniform layer of villi, which branch three or four times. The stem is 13 mm. long and is composed of fibrin, decidua, and blood. The interior of the specimen is partly filled with reticular magma, and on one side a small nodule, 3 mm. long and about 1 mm. in diameter, is embedded. This is not closely attached to the walls of the chorion, nor does it appear to be covered by the amnion. It probably is pathological.
(5) Sections of the chorion show that its walls are badly disintegrated. The main wall is somewhat fibrous, and between the villi there is a large quantity of fibrinous substance well filled with round cells and buds of syncytium. In other portions the trophoblast is necrotic. There are also a few clumps of it which show an active growth within the centers. The embryo is almost entirely dissociated. In the sections the head, brain and eye-vesicles can be made out, but otherwise the embryo is badly disintegrated.

No. 633.

(1) C. S. F. Lincoln, Shanghai, China.
(2) A 11×11×11 mm.
(3) The specimen is from a white patient who had gone 1 to 2 weeks overtime.
(4) The ovum is spherical in shape and covered with a uniform layer of villi which branch once and are 1.5 mm. long. It was opened carefully but no remnant of an embryo was found.
(5) Sections show that the chorion is macerated. Within was found a vesicle, 2 mm. in length, which appears quite like the umbilical vesicle. This runs out into a stem, one side of which is directly continuous with the chorion. At the point of juncture the tissues are full of blood-vessels; otherwise no structure can be made out. The specimen is very degenerate.

No. 651*g*.

(1) G. C. McCormick, Sparrows Point, Maryland.
(2) A 35×30×30 mm.; B 3 mm. long.
(4) The ovum is irregularly covered with ragged villi and entirely filled with a mass of granular and reticular magma containing a spherical amnion measuring 12 mm. in diameter. This latter is filled with clear fluid, and on one side is an hourglass-shaped body—the embryo—measuring 3 mm.
(5) Longitudinal sections through the body of the embryo show that it is set upon the flat amnion, which does not touch the chorion, being separated throughout by reticular magma. The main body of the embryo contains a pear-shaped central nervous system. There are several large cavities which can not be interpreted easily. One is the exocœlom; a second is the umbilical vesicle. The heart and a piece of intestine can be identified. The chorionic membrane and the villi have undergone a peculiar dissociation; some are a little fibrous, with small nuclei.
(6) Some hydatiform degeneration; decidua absent.

No. 660.

(1) Wm. J. Todd, Mount Washington, Maryland.
(2) Ovum 40×35×30 mm.; B 1 mm. long.
(3) Married woman 17 years old. Last menstruation January 17, and abortion March 25.
(4) A pear-shaped ovum, mostly covered with decidua. At one pole a third of the ovum protrudes and is covered with ragged villi. The interior is filled with a jelly-like, translucent reticular magma. No remnant of the embryo was seen at this time, but the search was incomplete.
(5) Sections through the chorion include the decidua, which shows considerable round-cell infiltration. The chorionic wall is thin and the villi, which are fibrous and non-vascular, are attached to the decidua by a thick layer of fibrinoid substance, the trophoblast having almost completely undergone this sort of transformation. There are, however, numerous buds of syncytium. The amnion is markedly fibrous and thickened, and within are numerous spaces containing some Hofbauer cells. The nodular embryo is quite completely dissociated, but not macerated. It is impossible to recognize any organs.
(6) Mild infiltration.

No. 674.

(1) Guy L. Hunner, Baltimore, Maryland.
(2) B 3.5 mm.
(3) "Patient is 42 years of age; has had 11 children and one miscarriage. Youngest child 2 years old. Normal labors. For several months the periods have been profuse, but she thinks the last period was three weeks ago, when she bled unusually. For the past six weeks there has been some bleeding off and on most of the time. She is now suffering with a great deal of pain in the lower quadrant and about the umbilicus, and is tender over the appendix region. I think that whatever pathological condition you find was due to the threatened miscarriage as expressed by the recent bleeding. There was no evidence of inflammation anywhere except in the appendix, and this was not of an acute character, and probably had not influenced the pelvic organs. The extreme retroversion of the uterus may have had something to do with the threatened abortion."
(4) When received the fresh uterus had been opened in front and a pathological ovum protruded. Ovum was opened and an atrophic embryo 3.5 mm. long and 2 mm. wide, was found within. Sections were taken through the middle of uterus and chorion, then at right angles to it through the fundus. The ovum is almost entirely detached from the uterus, but we succeeded in getting good transverse as well as longitudinal sections through it without disturbing the relation. The transverse section is near the os. In this region the chorion is fully separated from the mucous membrane and the latter has practically degenerated. The longitudinal section shows this degeneration on one side of the chorion, while on the other side the villi are still in contact with the uterus.
(5) Over the villi are long strands of decidua reaching far into the mucous membrane. The villi, which are closely attached to the uterus, are surrounded in many places by a large mass of fibrinoid substance. They, too, have undergone fibrous degeneration, are non-vascular, and frequently are intermingled with large plaques of nuclear dust. At other points the trophoblast pierces the glands and blood-vessels, while between the mucous membrane and the greater portion of the amnion there is a large organized clot composed of stratified fibrin, some leucocytes and small masses of red blood-corpuscles which do not serve to nourish the ovum. The chorionic wall is fibrous and the villi few in number. The specimen represents well the last stages of an abortion in which the ovum has gradually become detached and the mucous membrane is regenerating. However, sufficient nutrition may have been carried to the embryo to allow it to continue to grow in an irregular fashion. The embryo is very irregular in form. Near the sharp tip are two pigmented spots—the eyes. The embryo is completely dissociated and macerated, and entirely covered with a poorly preserved epidermis. The pigmented spots are separated from the brain, and a pronounced central nervous system does not make its appearance until the region of the heart is reached, and even then does not extend very far into the body. It is composed of round cells and is sharply separated from the body of the embryo by a fibrous layer of mesenchyme. Most of the tissue has undergone a pronounced fibrous degeneration. Along the ventral side of the body there are numerous sharply defined cavities, devoid of cells, which ramify in all directions and convert the body at the point of its attachment to the umbilical cord into a curious cavernous mass. It is impossible to determine whether the system of spaces is vascular or coelomic; probably the latter. In the neighborhood of the degenerated heart there are several large blood-vessels, but these do not communicate with the system of spaces. There are also numerous wart-like processes extending into this cavity. The decidua is locally infiltrated, especially in the region of the implantation site, where the peri-glandular infiltration is very evident.
(6) Marked focal infiltration.

No. 677.

(1) Thomas Brayshaw, Glenburnie, Maryland.
(2) A 18×21×12 mm.; B 1.5 mm. long.
(3) Patient had been married 3 years, this being her first pregnancy. The last period was February 15 to 19; abortion April 17.
(4) The fresh specimen, measuring 18×21×12 mm., was brought to the laboratory immediately after the abortion. It was well covered with villi, having bulbous tips to which adhered scraps of decidua as well as blood-clot. The ovum was opened in warm saline solution and sketches of its contents made under the binocular. It is filled with a delicate web-like transparent system of reticular fibers containing the flattened, transparent yolk-sac and blood-vessels, which lead to a white embryonic rudiment. This shows four processes, possibly the extremities. While the specimen was fixed in sublimate and glacial acetic, the reticular magma immediately became dense, completely obscuring the nodular embryo.
(5) The latter is completely dissociated, and over its body are numerous irregular warts which are difficult to interpret. The whole rests upon a large umbilical vesicle. There are slight traces of the central nervous system, and within the body is a curious mass which may represent the degenerated heart. The brain and spinal cord can barely be outlined. Towards its lower part the specimen contains a lumen. The umbilical cord, or what amounts to the same, passes along one side of the umbilical vesicle before it reaches the wall of the chorion. The chorionic wall is somewhat fibrous and contains numerous very large, almost empty blood-vessels. The mesenchyme of the villi is mostly degenerated and disintegrated, and practically all of the trophoblast is necrotic. The villi are glued together by strands of fibrin, blood, syncytium, and fine fragments of extremely degenerate decidua.
(6) Hydatiform degeneration.

No. 692.

(1) James L. Huntington, Boston, Massachusetts.
(2) A 20×20×20 mm.; B–3 mm.
(3) Patient aged 40 years; married 6 months. This may be the second pregnancy, as patient gives a history suggestive of an early abortion February 10, when she was 19 days overdue and flowed profusely. She had no medical attendant. Last menstrual period March 10 to 16; abortion May 19 following. No evidence of syphilis, gonorrhœa, or endometritis due to other infections. Uterus involuted normally and well.
(4) Specimen measured in formalin. The ovum is 20 mm. in diameter, and one half of it is covered with ragged villi, the other half being quite smooth. The interior is filled with a delicate reticular magma. Within the amnion

on one side is a small spherical body, without the characteristic form of a degenerate embryo. Further gross examination was impossible without injuring the specimen.

(5) The villi and chorion are very fibrous, and some of the mesenchyme is edematous with large cavities. The trophoblast is quite irregular in shape. There are some buds of syncytium and strands of a mucus-like substance. There are many Hofbauer cells in the tissues. The amnion is fibrous and attached to the chorion by means of a short cord. The embryo, which is closely surrounded by the amnion, is turned away from this cord, and on the side opposite the amnion there is an opening through which the tail of the embryo protrudes to reach out to and enter the very small atrophic umbilical vesicle. The back of the embryo is toward the umbilical cord and adjacent chorion. The tissues of the embryo are almost completely dissociated. The heart can still be outlined, as also a few of the body nerves. The central nervous system forms a large tube mostly filled with cells, reaching through the body up into the head, where it is practically lost. In the forepart of the head is a sharply defined, epithelial pocket, which may represent the beginning of a lens.

(6) Early hydatiform degeneration. Decidua absent.

No. 708.

(1) N. I. Ardan, Bristol, Tennessee-Virginia.

(2) A 70×60×40 mm.; B 2 mm.

(3) The specimen came from the first tubal pregnancy of a woman 24 years of age. Dizziness began two weeks before the abortion and continued with hemorrhage.

(4) The specimen measures 70×60×40 mm. and is covered with villi which are very markedly developed, in fact, hypertrophic. It contains a cavity lined with smooth membrane. This cavity measures 45×20 mm., and from it protrudes a small umbilical cord, 10 mm. long and 2 mm in diameter. At the end of the cord there is a small opaque knob, a little less than 2 mm. in diameter, undoubtedly a remnant of the embryo.

(5) The specimen consists of a fibrous chorionic membrane, to which are attached numerous long, irregular villi, and beyond these large areas of inflamed decidua, the inflammatory processes often being so extensive as to produce small abscesses. The villi are matted together with fibrinoid substance, a great deal of blood, and fibrin. The trophoblast is scanty. The mesenchyme of the villi contains no blood-vessels. The amnion is closely adherent to the chorion. The embryo is represented by a small nodule of largely undifferentiated tissue.

(6) Marked infiltration; hydatiform degeneration.

No. 712.

(1) G. W. Cox, Hartford, Connecticut.

(2) A 30×30×30 mm.; B 2 mm. long.

(3) Patient aged 37 years, married, and the mother of a child 2 years old. No other pregnancies. Health good, except recently a neoplasm of the breast. Periods about regular and normal. No history of venereal infection. Last period March 21; 36 hours after operation vaginal hemorrhage started. This increased in severity and patient was packed 24 hours later. Twelve hours after being packed she entered the hospital (June 4), and since hemorrhage had stopped she was curetted. The specimen was procured at this time.

(4) The chorion is covered entirely with long, ragged villi, except at one end. Without the stem, which forms this end, the specimen measures 30×30×30 mm. The amnion is greatly folded. This cavity contains a transparent body 8 mm. long and nearly 2 mm. in diameter—the umbilical cord.

(5) The chorionic wall, amnion, and villi are fibrous. The trophoblast is quite active, producing numerous buds of syncytium and clumps of trophoblast which have partially undergone fibrinoid degeneration. The body within the chorion consists mostly of an umbilical cord, which is capped by a clump of uniform round cells, which no doubt represent the embryo. A highly differentiated group of these cells encircles a cavity in the center, and possibly represents the heart. No other structures can be made out.

No. 714.

(1) G. J. Lochboeler, Washington, District of Columbia.

(2) A 30×20×20 mm.; B 2 mm. long.

(3) Patient aged 38 years, married at 26 years. Eight pregnancies; five normal, one following 18 months after ovarectomy for cystic disease; since then one miscarriage at 4½ months (macerated fetus), one at 2½ months, and another (the last) at 2 months. All occurred without assignable cause. Last period April 20 to 25; abortion June 25. Was infected at the time of abortion from inflammation of stump of right tube, which had been removed five years previously with a cystic ovary. Family fertile.

(4) The chorion measures 30×20×20 mm., and is covered with long, delicate villi. It contains a cavity 15 mm. in diameter and lined by an amniotic membrane. In the bottom are several small nodules, one of which is pointed and protrudes into the cavity about a millimeter, while the other two are slightly larger and lie between the amnion and the chorion.

(5) The chorion, amnion and villi are present, the latter being stuck together by an irregular mass of fibrin, blood, and trophoblast, which is scanty. The embryonic mass is irregular and dissociated, and the cœlom is not symmetrical. The spinal cord and brain are dissociated and are not sharply defined, and the heart is probably atrophic. The yolk-sac is degenerate.

No. 723*a*.

(1) L. L. Iseman, Chicago, Illinois.

(2) A 22×19×17 mm.

(4) The small chorion measures 22×19×17 mm., and is covered with long, irregular villi. The specimen, which had been opened, contained a transparent body composed of several membranous sacs, which together measure 4 mm. in diameter. Within these sacs were a few granules, one more opaque than the rest.

(5) The chorion is covered with but few villi, although there is a great tuft of them opposite the attachment of the embryonic mass. Most of the villi have undergone mucoid degeneration. The trophoblast is plentiful, and between the villi there is considerable mucoid matter and blood. The embryonic mass consists of a collapsed amnion and a degenerated cord, to which is attached a nodular embryo containing spaces, the cœlom, an epithelial tube and possibly the alimentary canal.

(6) Hydatiform degeneration. Decidua absent.

Nos. 788 *a*, *b*.

(1) Anfin Egdahl, Menominie, Wisconsin.

(2) Twins { (*a*) Ovum 60×45×40 mm.; stunted embryo 17 mm. CR. (See Group 6.)
(*b*) Ovum 65×55×40 mm.; nodular embryo 2 mm. long.

(3) Norwegian woman aged 32 years, married 10 years. Three previous pregnancies. This abortion, which is the first, occurred July 2, 1913. Condition of uterus normal. No history of venereal disease. First twins known in family.

(4) *b*. This specimen measures 65×55×40 mm., and is composed of chorion covered with degenerate villi. The wall is thin and lined throughout with the amnion. The cavity is filled with transparent fluid, within which was found floating a small vesicle 3 mm. in diameter. On one side of this vesicle is a small nodule. Otherwise no trace of an embryo was found.

(5) The chorion is thickened, and the mesenchyme of most of its villi is fibrous. The trophoblast is scattered in large nodules between the villi. The centers of these nodules have undergone fibrinoid degeneration and contain large plaques of nuclear dust. The decidua is some-

what inflamed, showing a general infiltration. Its inner border is formed by a fibrinoid layer. The embryo contains a large cavity, the walls of which are very thick and fibrous, and the lumen of which is filled almost entirely with cells. The thickened wall of the cavity passes into the nodular embryo, which has undergone fibrous degeneration and contains degeneration areas. Towards the tip of the embryo the central nervous system is indicated, but its lumen is entirely filled with cells which grade into the surrounding mesenchyme. Sections of the central nervous system are not characteristic. The epithelial lining is crescent-shaped. The entire epidermis is still intact, but otherwise no structure can be recognized.

(6) Mild infiltration.

No. 795.

(1) C. S. Minot, Boston, Massachusetts.

(2) A 40×35×15 mm.; B 3 mm.

(4) The ovum is pear-shaped and smooth on the outside and measures 40×35×15 mm. The wall is relatively thin, and the ovum completely surrounded by a layer of blood which is covered by a thin layer of decidua. The interior is lined with a smooth membrane and filled with blood and magma. On one side, closely attached to the chorion, is a very opaque nodular embryo, with a sharply pigmented eye. It measures 3 mm. in length and is markedly deformed.

(5) The chorionic wall is thickened and lined with the amnion. The villi are atrophic and buried within a large mass of maternal blood. The nodular embryo is entirely dissociated and its cells stain intensely. The free end contains a vesicle which may represent an eye or the brain. At the attachment of the embryo to the chorion there is a semicircular space, and within this is a body lined with cylindrical epithelium. This may be interpreted as representing the alimentary canal surrounded by cœlom. Below this the body of the embryo is closely attached to the chorion, and in this region a great many blood-vessels pass from the embryo into it.

No. 799.

(1) V. Van Williams, Baltimore, Maryland.

(2) A 40×25×25 mm.; embryo 1.5 mm. long.

(3) Patient aged 43 years, mother of 14 live-born children; 5 miscarriages. Only 3 or 4 children living, and these are all boys. Last period three weeks previous to abortion. Both husband and wife use alcohol to excess.

(4) The chorion, which measures 40×25×25 mm., is covered with long, irregular villi which make the specimen appear pathological. The wall is thin and closely lined with the amnion. The latter, which measures 25×18×18 mm., contains a small white nodule 1.5 mm. in diameter.

(5) The chorion and villi, which are thick, have undergone mucoid degeneration and most of the trophoblast is necrotic. The nodular mass is also completely dissociated and is attached to the amnion, where it is greatly thickened. At the point of attachment there is a large vesicle which may represent the alimentary canal. Below this is a second small vesicle and also numerous spaces which reach far out into the detached amnion, and appear to be remnants of distended and degenerated blood-vessels.

(6) Early hydatiform degeneration. Decidua absent.

No. 807.

(1) Raymond Sanderson, Canandaigua, New York.

(2) A 18×12×12 mm.; B 3 mm.

(4) The ovum is partly covered with decidua, which comes off as a shell and shows the ovum covered with a broad zone of irregular villi which divide twice. The two poles are bare and opaque. Through one of these the ovum was opened. The cœlom is filled with reticular magma. Near the point of opening is a spherical cavity 5 mm. in diameter containing an opaque, irregular embryonic mass 3 mm. long.

(5) The chorion is markedly fibrous and sparsely covered with non-vascular villi which are also fibrous, and attached to some of them is a small quantity of trophoblast. The umbilical vesicle apparently is normal and somewhat macerated. The wall of the amnion is also fibrous, and at its point of attachment to the embryo it appears somewhat like the umbilical vesicle. The exocœlom is wide open up to the body of the embryo, and from the latter a small yolk-duct appears to arise. However, this can be followed through the free space to the yolk-sac with which it communicates. The embryo is markedly stunted and dissociated, but most of the organs can be made out. The central nervous system has we lumen filled with round cells, and the heart is fairly still defined, but dissociated. The eye-vesicles are still present, although very small.

No. 820.

(1) C. W. Crum, Brunswick, Maryland.

(2) A 45×25×20 mm.; B 1 mm. long.

(3) Patient aged 38 years; married in 1899; 11 pregnancies—10 births at term and this abortion. Began bleeding 6 days before, which was attributed to lifting. Uterus not infected; no fever; no venereal disease. Family fertile.

(4) The specimen is an irregular mole 45×25×20 mm., containing a sharply defined cavity, 25×7 mm., which is lined by a smooth membrane and filled with reticular magma. On one side is a small nodule, a millimeter in diameter, which may represent the embryo. The wall of this specimen is composed of numerous villi which have undergone mucoid degeneration, and are matted together by fresh blood, considerable fibrinoid and trophoblast. On the outside is an inflamed decidua.

(5) The chorionic membrane is very fibrous and the cœlom filled with granular magma. Arising from one side are small strands of tissue which may possibly represent the amnion. Lying in the granular magma are remnants of tissue which probably come from the chorion. The epithelium of the latter is largely destroyed, and the infectious process seemed to be attacking the chorionic membrane from the outside.

(6) Marked infiltration.

No. 830.

(1) Austin Miller, Portersville, California.

(2) A 80×38×35 mm.; B 4 mm.

(3) Woman aged 41 years, married in 1889. Pregnant 10 or 11 times; 8 living children, last child 6 years old. Last period at end of June, abortion September 26 following. Uterus presumably normal. No venereal diseases. Family fertile.

(4) The specimen is a pear-shaped abortion mass, measuring 80×38×35 mm. At the larger pole a clear bluish membrane was exposed through an opening 30×15 mm. The mass was opened through this membrane and found to contain a cavity 60×30×30 mm., lined by a smooth membrane which crosses it in a large, clear fold. To this was attached a small opaque white embryonic rudiment, 4 mm. in length, as well as what seemed to be a yolk-sac about 1.5 mm. in diameter. The wall of the oval mass is thin throughout except at the smaller or upper pole, where it measures about 9 mm. in thickness, and is very hemorrhagic.

(5) The chorionic wall is composed of non-vascularized villi matted together by an inflammatory material, a great deal of fibrinoid substance and inflamed decidua. The trophoblast is fairly active, and there are numerous plaques of nuclear dust.

(6) Marked infiltration.

No. 888.

(1) Oliver T. Logan, Changteh, Hunan, China.

(2) A 70×50×50 mm.; B 1 mm. in length.

(3) Chinese woman, age 32 years, married 16 years. First child born 4 years after marriage; second child stillborn at 7 months. Two children died in infancy of fever. Three living, healthy children, the youngest 2 years old.

No history of lues in either parent. Last menstrual period October 10. On the following February 21 the patient flooded badly and was anemic. Came to the hospital on the 22d, when uterus was emptied.

(4) The specimen consists of an abortion mass 70×50 ×50 mm., one half of which exposes villi probably about 9 mm. long, while the other half is covered by decidual tissue. The ovum was opened freely and a distended spherical vesicle (amnion) protrudes. It is attached to one end of the chorion. The structure of the amnion is very fibrous, and when opened a nodular but irregular mass, about 1 mm. in diameter, was found attached to one side of it. The chorionic membrane is very fibrous and the villi have undergone partly fibrous and partly mucoid degeneration. There is an overlying trophoblast present. The decidua is degenerate, but some villi are still well implanted in it.

(5) The embryonic mass is in the form of a cone with the entire base attached to the thickened amnion. Below this base there is a large mass, the débris of which stains intensely with hematoxylin. This may be a remnant of the yolk-sac. On either side of this is a large, sharply cut space which may represent the cœlom. The embryo itself is composed of two parts, one part forming a large cavity lined partly with a thickened layer of epithelium; the other has undergone fibrous degeneration and includes several round epithelial tubes which may be remnants of the intestines. The large cavity seems to be the central nervous system. It lies entirely within the amniotic cavity; otherwise it might readily be construed as the yolk-sac, its walls having much the appearance of some yolk-sacs.

(6) Marked infiltration; hydatiform degeneration.

No. 915*b*.

(1) C. S. Minot, Boston, Massachusetts.

(2) A 7×7×7 mm.; B 2 mm. GL.

(4) The specimen consists of a clear piece of chorionic wall about 7 mm. in length, with scanty, thread-like villi with irregular enlargements. A small, pear-shaped and opaque, featureless nodule, about 2 mm. in length, is adherent to the inner surface.

(5) The chorion and villi are very fibrous, and the latter are covered with a small amount of trophoblast. The embryo forms a curious crescent-shaped body with a well-defined neural tube. This on its ventral side spreads out through the rest of the embryo, so that cells seem to be directly confluent with the main tube. Between the embryo and its attachment to the chorion there is quite a plexus of spaces. Numerous villus-like bodies protrude into the exocœlom. Within the embryo there are myotome-like bodies on one side of the cord; otherwise the dissociation is almost complete. In addition to this embryo there is a well-defined, fibrous vesicle lined by epithelium. In this are a few groups of cells which may represent blood-cells.

No. 930.

(1) F. H. Bacon, Peoria, Illinois.

(2) A 34×34×25 mm.; B 1 mm.

(3) Patient aged 38 years, married 19 years. Six children, all living; eldest 17 years and the youngest 14 months. No previous miscarriages. Missed menstruation in April, flowed slightly May 23; missed June period. On July 4, after working harder than usual, began to have abdominal cramps and started to flow some in the evening. Cramps and blood increased on the 5th and 6th. On the 7th patient had severe hemorrhages. Examination showed uterus to be about the size of a two-months' gestation.

(4) The specimen is a pear-shaped abortion mass measuring 55×37×37 mm., the upper portion of which consists of "fresh" deciduous tissue; the lower, of a spherical ovum, measuring about 34×34×25 mm. Villi, 7 mm. in length and few in number, are exposed. On opening, the ovum showed a smooth-walled cavity in which was found a nodular embryo 1 mm. long.

(5) The chorionic membrane is very fibrous, and attached to it are short fibrous villi matted together by considerable trophoblast, mucoid substance, and blood. A decidual mass 2 mm. in diameter has in its center a large accumulation of leucocytes. The nodular embryo has undergone degeneration, and only the cœlom and several large vesicles which are buried in the chorion can be made out with precision. Part of the embryonic tissue looks a little like cartilage, and another portion is composed of small round cells. There is also a small papilliform body at the tip of the embryonic mass.

(6) Severe infiltration.

No. 943.

(1) Elizabeth Comstock, New York City.

(2) A 50×50×50 mm.; B 2 mm.

(3) Patient aged 28 years; married in December 1906. Seven pregnancies: (1) abortion at 6 months; (2) abortion at 4 months; (3) term, child now living; (4) term, child died at 3 months; (5) term, child died at 4 months; (6) term, child died at 8 months; (7) this abortion, at 3 months. Last menstrual period May 21 to 23; abortion August 25 following. There was a slight redness of the cervix and a blood-tinged, albuminous, glistening discharge the day before the abortion. Syphilis acquired from husband. Ovaries and tubes in good condition. Family fertile.

(4) The mass consists of a hard body 80×40×40 mm., from which protrudes a chorionic vesicle 50 mm. in diameter, partly covered with relatively small villi. This contained a clear fluid, a few large flakes which float easily, and a small body 2 mm. long, which appeared to be the remnant of the embryo.

(5) The chorion is fibrous and the few villi have mostly undergone mucoid degeneration. These are matted together with degenerate trophoblast, and there is also considerable blood between them. The amnion lines the entire chorion. The nodular embryo is greatly degenerated and very fibrous, and contains a cavity which ramifies and seems to be composed of the nervous system. In the head end there seem to be two rudimentary eye-vesicles, while at the other end, where the embryo is attached to the chorion, the tissues have undergone fibroid degeneration.

The decidua is well preserved, but shows considerable local infiltration. Beginning fibrous and obliterative endarteritis are evident in certain areas.

(6) Mild infiltration.

No. 1019.

(1) Joseph S. Lewis, Buffalo, New York.

(2) A 70×35×30 mm.

(3) The patient had had three previous abortions—one at 7 months, two at 3 and 4 months. The last two were self-induced. The last period occurred about September 15. Hemorrhage began September 27. No infection is present.

(4) The abortus consists of a chorionic sac almost covered with clotted blood which adheres firmly to the villi. The chorionic vesicle is filled with a reddish fluid containing an embryo 2×4 mm., which is adherent to one side of the chorionic wall. Subchorial hematomata are present, but the chorionic wall is so thin that it is difficult to identify the villi with the unaided eye.

(5) The clot contains a very degenerate chorionic membrane, villi, and decidua. The stroma of many of the villi is quite fibrous, and no remnant of the vessels is seen.

No. 1022*h*.

(1) Ernest C. Lehnert, Baltimore, Maryland.

(2) 35×25×20 mm.

(4) A little more than half of the chorionic sac is bare. A small white nodule can be seen on the interior. It is about 1 mm. in diameter, and apparently represents the embryo. The remainder of the chorion is covered by a

thick coat of villi. Examination under the binocular shows the presence of undoubted hydatiform degeneration, and a small nodule within, which suggests an embryonic remnant.

(5) Higher magnification shows this to be a specimen of hydatiform degeneration, with non-vascular, glassy, fenestrated, and degenerate stroma, with only moderate epithelial proliferation. A few small vessels still are found in the chorionic membrane. Some villi contain considerable numbers of Hofbauer cells. The decidua was not included and no embryonic or amniotic remnants were seen in the sections examined. The trophoblastic nodules are degenerate.

(6) Hydatiform degeneration.

GROUP 5.

No. 110.

(1) J. P. West, Bellaire, Ohio.

(2) A 46×30×30 mm.; B 8 mm. CR.

(3) "The last menstrual period began September 22 and lasted 5 days. On December 8 there was a slight flow which continued until the 13th, when the abortion took place."

(4) The shape of the ovum is oblong and its walls are fleshy, the villi having all disappeared. Within there is a clear fluid, with a granular deposit covering the embryo. The embryo is greatly macerated and is but slightly attached to the chorion. At the point of attachment there is an elevated mound of necrotic tissue, to which the embryo is stuck. There is no distinct cord and the amnion is absent. Evidently both chorion and embryo have been dead for a long time.

(5) The chorion is atrophic and the decidua is infiltrated with leucocytes. The amnion, umbilical vesicle, and the attachment of the umbilical cord to the chorion are completely destroyed. The embryo is atrophic, the face not being developed at all. The central nervous system is swollen; the outlines of the viscera and body-cavity are obliterated and filled with migrating cells. The liver is small; the heart and blood-vessels greatly distended.

(6) Mild infiltration and probably hydatiform degeneration.

No. 115.

(1) A. S. Atkinson, Baltimore, Maryland.

(2) A 30×27×22 mm.; B 3 mm.

(3) The abortion took place two months after the beginning of the last period. During the second month of pregnancy there was continuous bleeding.

(4) The ovum was brought to the laboratory fresh, immediately after the abortion. It was opened at once in formalin and found filled with a gelatinous, transparent mass, which became fibrous after the formalin had acted upon it. Later on alcohol made it opaque. The chorion is practically free of villi and looks necrotic. The embryo is well in the middle of the ovum and apparently is separated from the chorion. The head, as well as the tail, is atrophic.

(5) Sections show that the villi of the chorion are also atrophic, with but a small quantity of syncytium attached to them. Both chorionic membrane and villi are wholly non-vascular, and the stroma of many of the latter is clear. Except for slight maceration, the amnion looks normal. It is detached from the chorion and the embryo is practically sessile upon it. The entire chorion is surrounded by a mass of decidua filled with leucocytes. The magma of the cœlom is very dense and has within it but few migrating cells. Within the greatly distended amnion lies the embryo, looking much like a chick of the third day. The peritoneal cavity communicates freely with the exocœlom, in which hangs an atrophic umbilical vesicle. The lumen of this is filled completely with entodermal cells, its blood-spaces greatly distended but nearly empty, and its solid stem ends abruptly after it enters the body of the embryo. There is no trace of either alimentary canal or liver. Rudimentary Wolffian bodies and ducts are present. The central nervous system is solid. The heart and large veins are simple in form and greatly distended with blood.

(6) Marked infiltration of the decidua; hydatiform degeneration of the chorion.

No. 141.

(1) J. P. West, Bellaire, Ohio.

(2) A 40×30×30 mm.; B 8 mm.

(3) Specimen obtained from same patient as No. 110, described above. Woman has had 9 children and has always been healthy until about 10 years ago. From that time her health gradually became worse; now she is extremely neurasthenic. Stomach is dilated, digestion poor, bladder irritable, and urine scanty. Uterus large, thick, and retroverted; leucorrhea. The uterus is about three times its normal size and has a number of cysts in the cervix. There were several earlier abortions; the one before this took place December 13, 1897 (No. 110). The last period began October 27, 1898, and the abortion followed on January 13.

(4) The chorion is fleshy, like No. 110, with but few villi, and within the cœlom there is a great quantity of magma réticulé and a dissociated embryo about 4 weeks old.

(5) The sections show that the chorion and villi are matted together and contain but few blood-vessels. The trophoblast is very extensive, and where it is in large masses the most central cells are necrotic. The mesoderm of the chorion is fibrous and hypertrophic. There is a considerable quantity of mucus or fibrin, rich in leucocytes, between the villi. This condition may have been more extensive elsewhere, as only the chorion in the neighborhood of the embryo was examined. The great quantity of magma réticulé within the cœlom has numerous migrating cells scattered through it. The amnion is partly in contact with the chorion, and at the points of contact is normal in appearance, but in other places it is cystic. Where it is separated from the chorion by the excessive quantity of magma, the walls of the amnion are greatly hypertrophied. The umbilical vesicle is collapsed and its walls have undergone complete hyaline degeneration. The central nervous system of the embryo is greatly dilated and dissociated. The body-cavity can barely be outlined. The large blood-vessels are faintly marked by the blood within them. The rest of the tissues form one homogeneous mass of tissue cells infiltrated with round cells, within which can still be recognized cartilages and nerve bundles. The boundaries of the heart and liver are wholly obliterated, due to their dissociation.

(6) Probably some hydatiform degeneration. Decidua absent.

No. 142.

(1) G. N J. Sommer, Trenton, New Jersey.

(2) A 50×40×30 mm.; B 15 mm.

(3) "Last period September 28. On January 3 there were marked uterine pains; free hemorrhage February 1; abortion February 4."

(4) Chorion fleshy with some villi. Subchorial hematomata are present. Within is a macerated embryo about 5 weeks old, embedded in a mass of fibrin-like magma. Between the magma and walls of the chorion is a large space filled with clear fluid.

(5) Serial sections of the embryo and chorion show most remarkable changes. The chorion and amnion are greatly thickened and very fibrous, and appear in every respect like the membranes in fleshy moles. The very degenerate, fibrous villi are matted together by necrotic as well as living cells. The fibrinous mass within the amnion is in all probability blood which has entered from the exterior. It has all the appearance of blood-clots found elsewhere in the body, but in addition it has been invaded by wandering cells from the embryo. The cœlom was partly filled with a granular magma, into which project numerous slender villi arising from the walls of the thickened am-

nion. The dimensions of the ovum and the length and degree of development of the embryo indicate that the pathological changes began not later than the sixth week of pregnancy, while the menstrual history of the mother indicates that at least 14 weeks elapsed between the conception and the abortion. In other words, the pathological process has been under way for at least 8 weeks. The embryo itself has undergone most marked changes, which also speak for this. The nervous system is markedly dissociated and macerated. Arms and legs, external features, as well as most of the internal organs, have vanished. The liver is still outlined but necrotic. Wandering cells have invaded all of the tissues and are also beginning to attack the cartilaginous bodies of the vertebræ. Large nests of them are also embedded in the clots of blood which surround the embryo. The main blood-vessels of the embryo can still be traced through the surrounding tissues. The cord is filled with embryonic blood, but likewise is necrotic. From all appearances, had the ovum remained in the uterus much longer it would soon have become filled with maternal blood, which in turn would soon have solidified to make of the specimen a typical fleshy mole.

(6) Decidua necrotic and infiltrated; chorionic changes suggestive of lues.

No. 150.

(1) Theo. E. Oertel, Augusta, Georgia.

(2) A 35×30×10 mm ; B 5 mm.

(4) There are but few villi on the chorion. The embryo is distorted and the arm on one side is unusually large.

(5) The chorion and amnion are greatly degenerated. Villi are not included. The sections of the embryo show an extreme degree of change. The nervous system is swollen and solid, and the contour of the viscera is wholly obliterated. The large blood-vessels are greatly distended with blood. Round cells are distributed equally throughout the body of the embryo.

(6) Decidua absent.

No. 205.

(1) D. S. Lamb, Washington, District of Columbia.

(2) A 40×30×30 mm.; B 6 mm.

(3) "The specimen which is about 4 weeks old is from a woman who had been married 3 months. Syphilis is suspected in the case."

(5) The chorion is partly encircled by the decidua, which is more or less necrotic and infiltrated with leucocytes, showing that an inflammatory process was present in the uterus. The chorion is fibrous at points, and at others edematous, with but few villi present. These are irregular and many of them fibrous. Their outlines are irregular, and they are covered with a dense and very irregular mass of syncytial cells. The few blood-vessels present in the villi are all empty. The amnion is completely adherent to the non-vascular chorion throughout its extent, making these two membranes appear as one. On the amnion side there are numerous fibrous tuberosities which look much like small villi inverted. At other points the epithelial covering of the amnion builds by itself a double layer of cells, which often give rise to papilliform processes much like the syncytium on the outside. In some places this layer of epithelium is raised, forming a blister with a fibrin-like substance, possibly magma, throughout which are scattered transparent round cells with very small nuclei. The umbilical cord is quite fibrous, with large, irregular cavities scattered through it. These are filled with a mucoid substance in which a few nuclei are scattered. The blood-vessels are all obliterated, except at the point of attachment of the cord to the embryo, where irregular vessels are filled with blood. The external form of the embryo is well preserved and covered entirely with much thickened epidermis. The brain and spinal cord are swollen, the former being practically solid in the region of the forebrain. The heart and large vessels are gorged with blood, which extends from them into the surrounding tissues, obliterating them almost entirely. Within this mass of migrating cells can be seen the outlines of some of the organs of an embryo about 4 weeks old. The liver, stomach, and lungs are riddled by them, and only the faintest mark of an endocœlom can be seen. It appears as if all the blood of the specimen accumulated within the embryo, the cord and the chorion being free, the extensive epidermis preventing the migration of the blood-cells into the amniotic cavity.

(6) Probably some decidual infiltration; chorion and amnion suggestive of lues.

No. 228.

(1) J. P. West, Bellaire, Ohio.

(2) A 60×25×25 mm.; B 4 mm.

(3) "The specimen is from the first pregnancy of a fairly healthy woman. Last period July 1 to 3; abortion, October 10."

(4) The solid, blood-red specimen contains a regular cavity, 30×18×18 mm., which is filled with a granular magma, on one side of which is attached an embryo shaped like an hour-glass.

(5) Sections of the mole show that it is composed of thick walls in which there is much blood, some villi, a great deal of decidua, and some pus, especially on the outside. The mesoderm of the villi and chorion is very fibrous and devoid of blood-vessels. The cavity of the chorion is lined with a very thick amnion, and the remnant of an embryo indicates that its development was arrested towards the end of the third week. The vascular system still is represented by a mass of cells on the ventral side of the embryo, behind which there is a large vessel full of blood, extending towards the remnant of the umbilical vesicle. No vessels extend to the chorion. The central nervous system fills the main part of the embryo, being much dilated in the head and pretty well filled with round cells throughout. In front of the brain are two vesicles which communicate with it through two long tubes. These no doubt represent the eyes. In the neck there is a small gland, possibly the thyroid.

(6) Marked infiltration.

No. 246.

(1) A. Wegefarth, Baltimore, Maryland.

(2) A 30×21×14 mm.; B 3 mm.

(3) "The woman from whom this specimen was obtained is the mother of two children, the youngest about 7 years of age. Since then she has had five miscarriages, all of about the same age as this specimen. No history of syphilis, but have started to give her iodide of potash, with the hope that she may give birth to a child. It would be interesting if the great fire we had recently could have played any part in this trouble, as she felt well up to that time, and the fright, due to the fear that the fire would burn out her neighborhood, kept her in a state of great excitement for about 24 hours."

(4) The external surface of the ovum is normal in appearance, but when opened it was found to contain a deformed embryo lying beside a very large amnion. Sections of the chorion show that its structure is somewhat hyaline and the villi are devoid of blood-vessels. The embryo and membranes were cut together, and the sections show that the amnion is greatly hypertrophied, folded, and torn, and that the embryo is deformed and injured, but lying outside the amnion. The heart and great blood-vessels are empty, the brain is distended and partly filled with round cells; together they give the appearance of an embryo of the beginning of the third week. No liver can be found, but there are loops of intestine present, as during the fourth week. The otic vesicles are well defined, but the optic vesicles are absent. No umbilical vesicle can be found, but this may have been lost when the amnion was torn. The amnion, however, runs down in a thickened ridge which contains two large blood-vessels and an epithelial tube, the allantois, between them.

At no place is the amnion attached to the chorion, nor are there indications that they have been torn apart.

(6) Early hydatiform degeneration and maceration. Decidua absent.

No. 252.

(1) D. S. Lamb, Washington, District of Columbia.

(2) B 3 mm.

(3) "First pregnancy in an unmarried woman 23 years old. Patient missed one month, then had free hemorrhage which continued for a month, when the embryo was expelled." This would make its age three months, counting from the last period.

(4) This remarkable specimen shows to what extent an embryo may grow after its regular development has been arrested. It came to the laboratory attached to a solid body and appears to be about 3 weeks old. The free end of the embryo is bent upon itself, and tapers to a point where two intensely black spots may be seen.

(5) The membrane or body behind the embryo is undoubtedly the thickened, curled-up amnion; for on the side towards the embryo it is covered with epithelium, which continues over the body. On the other side the mesoderm, which is thickened and hyaline, is free, there being no border cells or villi. The skin is markedly thickened, the epidermis in some places forming small papillæ and in others depressions where pearl-like bodies similar to those of epithelial cancer are found. Within the body there is a large cavity filled with round cells. Near its attachment to the amnion several such "abscess-like" masses lie within the embryo. The pigment dots, on account of their position, undoubtedly represent the eyes. Each forms a small sac immediately below the skin, filled with large, free pigment cells. Deeper within the head a band of pigment cells, which may be the optic nerves, connects the eyes.

No. 288*a*.

(1) H. Brülle, Baltimore, Maryland.

(2) A 85×35×35 mm.; B 11 mm. CR.

(4) On one end of the chorion there is a space (30×30 × 5 mm.) filled with reticular magma. Within this, and pushed to one side, may be seen a collapsed ovum. The intervening space is filled with blood, through which ramify a few long, slender villi. These are fibrous and devoid of blood vessels. At points they are invaded by syncytium and leucocytes. The amnion, which is also fibrous, is partly filled with magma réticulé and is very rich in degenerated migrating cells from the embryo. The disintegrating embryo is pushed to one side of the chorion and is pretty well dissociated, but the tissues are sharply enough defined to show that it is not over 6 weeks old. They are well infiltrated with round cells which extend into the surrounding magma. The epidermis is absent.

(6) Infiltration.

No. 289.

(1) H. Brülle, Baltimore, Maryland.

(2) B 8 mm.

(4) The specimen is distorted, very dissociated, and macerated. Limb-buds are merely indicated, and the outlines of the organs are almost entirely obscured.

(6) Decidua and chorion absent.

No. 297.

(1) D. S. Lamb, Washington, District of Columbia.

(2) B 6 mm.

(3) This specimen was removed from the uterus with a curette and is said to be nearly 3 months old.

(4) The distorted embryo is of the 3-weeks stage and shows extreme changes in its organs and tissues.

(5) The chorion is thin and atrophic. There is no trace of an umbilical cord, but instead the embryo sits upon the amnion. The spinal cord is dilated and the brain is fully dissociated, filling up the stumpy head entirely. The blood-vessels are much dilated with blood, and all of the tissues are infiltrated with round cells which deform the organs and obscure their outlines. The mandible is necrotic, and the distended medulla reaches almost to the mouth.

No. 302.

(1) M. Brödel, Baltimore, Maryland.

(2) A 25×20×15 mm.; B 4 mm.

(4) The ovum is normal, apparently, but is covered with irregular villi. Sections show, however, that these are fibrous and contain remnants of blood-vessels. The trophoblast is very active and the villi are partly surrounded by a recticular mass of mucus, rich in leucocytes.

(5) The amniotic vesicle, which is 10 mm. in diameter, is embedded in much magma réticulé and filled with granular magma, in which is an embryo about 3½ weeks old. The umbilical vesicle is degenerated and lies in the reticular magma. The blood-vessels and tissues of the embryo are gorged with blood and the outlines of the organs are obliterated. The brain is partly solid and the spinal cord distended and dissociated. The eye vesicle and lens are nearly destroyed. The umbilical cord is very short and wide, without marked blood-vessels, but infiltrated with round cells.

No. 312.

(1) E. M. Stanton, Albany, New York.

(2) A 25×15×10 mm.; B 8 mm. (straightened).

(3) Abortion followed a blow upon the abdomen.

(4) One side of the ovum is very hemorrhagic, the other side thin.

(5) The villi are few in number, without a syncytial covering and possibly invaded by leucocytes. The main wall of the chorion appears to be necrotic. The embryo is straight and shows three gill arches and some myotomes. Its tissues do not stain well, but the spinal cord can still be outlined. The tissues appear to be infiltrated with round cells.

No. 321.

(1) A. C. Wentz, Hanover, Pennsylvania.

(2) A 40×40×20 mm.; B 2 mm.

(4) The ovum is covered entirely with villi and contains some reticular and much granular magma.

(5) The whole chorion is lined by the amnion and the embryo is attached to it at its middle. Traces of the central nervous system can still be seen, and in front of it there is a structure which may represent the heart encircled by a large space—the cœlom—which extends to the umbilical cord. The tail end of the embryo is nearly solid. A large share of the dissociation may be due to the dilute alcohol (50 per cent) in which the embryo had been placed 10 days before it was received at the laboratory. This, however, could not alter the general shape of the embryo and its attachment to the chorion.

(6) A very macerated hydatiform degeneration. Decidua is absent.

No. 328.

(1) A. G. Pohlman, Bloomington, Indiana.

(2) B 4.5 mm.

(5) The chorion is covered with irregular, fibrous villi, surrounded by a necrotic decidua more or less infiltrated with leucocytes. The main wall of the chorion is about normal in structure and contains numerous blood-vessels. Within, the amnion nearly reaches the chorion. The degenerated umbilical cord is attached to the amnion, but not to the chorion. The umbilical vesicle is well embedded in magma, is very rich in blood-vessels, and on its outside has many papilliform processes, some of which seem to blend with the chorion. In fact, it appears as if the blood-vessels of the umbilical vesicle passed directly over into those of the chorion. The embryo is somewhat deformed, and it is difficult to follow the outlines of some of its viscera. The central nervous system is dilated and converted into a mass of round cells lying in the mesoderm, without any epithelial lining; the otic and optic vesicles

are likewise filled with round cells. The larger vessels are filled with blood, and the tissues are fairly well infiltrated with round cells. The epidermis is intact. Dissociation of the tissues has taken place to such a degree that it is difficult to outline the organs with certainty.

(6) Infiltration.

No. 340.

(1) C. S. Minot, Boston, Massachusetts.

(2) B 6 mm.

(5) The embryo is infiltrated with round cells, and the dissociation of the tissues is quite complete. Large blood-vessels can still be outlined, but the central nervous system is practically solid.

No. 347.

(1) C. S. Minot, Boston, Massachusetts.

(2) A 40×35×30 mm.; B 11 mm.

(5) The decidua is hemorrhagic and necrotic at points and well infiltrated with leucocytes. The scattered villi and main walls of the chorion are fibrous, and at some points infiltrated with leucocytes. Very little syncytium is present, and but few traces of blood-vessels are found in the chorion. The villi are non-vascular and partly matted. The embryo is dissociated and macerated, with dilatation of the central nervous system and extension of the medulla. The blood-vessels are distended and the blood-cells are continued through their walls into the surrounding tissues.

(6) Slight infiltration of the decidua.

No. 366.

(1) A. G. Pohlman, Bloomington, Indiana.

(2) B 9 mm.

(5) Sections of the chorion, which is fleshy in appearance, show that its main wall is very thin and lined with amnion. The villi, few in number, are fibrous or hyaline and covered with some syncytium, while the spaces between them are filled with blood. Some of the villi adhere by means of the trophoblast to the decidua, which is fibrous and necrotic. There is no leucocytic infiltration of the chorion nor of the decidua. The embryo is pretty well infiltrated with round cells and the tissues are dissociated. The latter are, however, well preserved and appear to have been very much alive. There is a considerable quantity of blood within the cavity of the heart and in the blood-vessels. The central nervous system is dissociated. The lower jaw is large and adherent to the head above, and to the trunk below. The arms and legs are atrophic.

(6) Hydatiform degeneration; specimen very degenerate.

No. 398.

(1) C. R. Bardeen, Madison, Wisconsin.

(2) B 5 mm.

(5) The embryo is of the 3-weeks stage, but markedly changed. Most of its organs can still be recognized and the embryonic cœlom is fairly definite. The front of the head is adherent to the thorax below, and the face is pretty well atrophied. The central nervous system is dissociated and distended, as are also the heart, the blood-vessels, and the liver.

No. 399.

(1) A. S. Thompson, Mount Horeb, Wisconsin. (Bardeen collection.)

(2) B 4 mm.

(3) Patient 20 years old, married 10 months. She is a marked bleeder; otherwise strong and healthy. The pelvic organs are normal. The last period occurred during the first week in September and the abortion followed October 9.

(4) The external form looks much like that of a chick embryo.

(5) Sections show that the tissues are generally dissociated and also macerated.

(6) No decidua or chorion.

No. 400.

(1) G. J. Kaumheimer, Milwaukee, Wisconsin. (Bardeen collection.)

(2) B 3.5 mm.

(3) Last menstruation October 21; abortion December 19.

(4) The external form is that of a normal embryo, but the sections show that marked changes have taken place.

(5) The central nervous system is distended and partly filled with round cells. The walls of the brain are dissociated and apparently are giving rise to the numerous round and fragmented cells which are present. The heart and large blood-vessels are distended and well filled with blood. The tissues of the mesoderm are generally filled with round cells, as well as with numerous fragmented nuclei, the infiltration including the myotomes and peritoneal cavity. The amnion and epidermis are intact.

(6) Decidua and chorion absent.

No. 413.

(1) A. R. Stevens, Baltimore, Maryland.

(2) B 5 mm.

(4) The ovum measures 35×25 mm. and is covered with numerous long atrophic villi. It contains a large amnion, measuring 17 mm. in diameter, which encircles a stunted and twisted embryo 5 mm. in length. The embryo is curled upon itself at the lower end, being sessile upon the amnion, but the head and neck are straight and in many respects appear to be normal.

(5) The arm-buds appear very much like those of a normal embryo of this size, but the brain is completely dissociated, forming an even layer of cells throughout the neural canal. In fact, the only structure in the embryo that is pronounced is a very sharp pericardial cavity containing an atrophic heart. It is impossible to outline any other organs within the body save the spinal cord. There is a fairly sharp outline of its cells in the tail of the embryo, where it spreads out into a wide open plate forming spina bifida. This is a case of stunted embryo with spina bifida and almost complete dissociation of tissues.

(6) Decidua absent. Hydatiform degeneration.

No. 414.

(1) J. R. Laughlin, Hagerstown, Maryland.

(2) A 30×20×20 mm.; B 6 mm.

(3) Patient is 32 years old and the mother of four living children. She had one miscarriage at 4 months three years ago. There is no specific history. The last menstruation occurred August 28 and the abortion November 8.

(4) The ovum is transparent and entirely covered with scattered, ragged villi. It contains a deformed embryo 6 mm. in length. The head is normal in shape, but the body is atrophic. The arm-buds are large, but the leg-buds are too small for an embryo of this size. The cœlom is filled with reticular magma.

(5) Sections of the embryo show extensive dissociation of the tissue. The nervous system is practically solid, the brain being greatly reduced in size. The eye-vesicles also are atrophic, reaching from the brain to the skin as delicate, trumpet-shaped bodies. The optic cups contain vascular lenses. Within the tissue of the embryo many of the blood-vessels can still be outlined by the presence of blood corpuscles within them. The heart is solid and more or less atrophic, and the cœlom fairly well outlined. The body is directly continuous with the amnion, there being no umbilical cord. The cœlom of the embryo communicates very freely with the exocœlom, and at the point of communication the intestines extend into the latter. Adjacent to the intestines there is a very small atrophic umbilical vesicle. There is no lumen, the Wolffian bodies can barely be made out, and the liver is completely dissociated. The amnion is greatly thickened at points, but the chorionic wall appears normal in structure and thickness. The villi are somewhat fibrous, the trophoblast scanty, and there is a small amount of mucoid substance

between them. It appears that in this case there was an arrest of development of the embryo at about the 20-myotome stage, but the specimen continued to develop in an irregular fashion, the tissues becoming dissociated and ultimately undergoing maceration.

(6) Decidua absent.

No. 419.

(1) J. Park West, Bellaire, Ohio.

(2) A 15×5×5 mm.; B 5 mm.

(3) This is the second specimen from the same woman, the first being from an abortion in March or thereabouts. The woman is about 27 years old and very nervous. Last period began on October 5 and was as usual. Before November 5 she decided she was pregnant. November 23 there was a slight show, which increased and continued until the abortion, November 28. There was no pelvic trouble, but the uterus was very small, almost of an infantile type.

(4) The ovum has a hemorrhagic wall 4 to 8 mm. thick, the entire mass measuring 25×20×20 mm. It contains a cavity lined by an amnion measuring 15×5×5 mm., and a stunted embryo which is somewhat straight and measures 5 mm. in length.

(5) The chorionic wall is of normal thickness, but very degenerate. The hemorrhagic mass is also surrounded with fibrous decidua, more or less infiltrated with leucocytes. The few villi which are embedded in blood are mostly necrotic, the trophoblast being scanty, but where it remains in any considerable quantity it has undergone extensive fragmentation, leaving large plaques of nuclear dust. Sections of the embryo show extensive dissociation and maceration. The brain is solid, but the medulla and spinal cord contain a lumen. The eye-vesicles can barely be outlined. The branchial organs appear quite normal, but the two poles of the body are atrophic. The heart, which appears to be normal in form, lies free within the pericardial cavity. The tissues of the lower part of the body are so much macerated that it is impossible to determine whether or not the organs are normal in form.

(6) Marked infiltration of the decidua; probably hydatiform degeneration.

No. 446.

(1) Elizabeth Morse, Boston, Massachusetts.

(2) B 8.5 mm.

(3) Patient is 33 years of age and the mother of several healthy children. She is overworked and lives under poor hygienic conditions. Last period was October 17 and the abortion December 15.

(5) There is a piece of chorion which, upon section ing, proved to be very hemorrhagic; otherwise the structure is poorly defined. However, there are a few necrotic villi close to the chorion and the embryo. The latter is markedly dissociated, but some of the organs can still be made out. The brain fills entirely the head region, and the spinal cord reaches to the tip of the tail. The heart, pharynx, and lungs can still be outlined in their proper positions. The myotomes are well outlined, and between them are seen various peripheral nerves, indicating that the embryo had developed normally to about the 5 or 6 mm. stage before the strangulation and dissociation began. At the tail end of the embryo there is a large accumulation of round cells which stain intensely.

No. 451.

(1) H. D. Senior, Syracuse, New York.

(2) A 80×45×40 mm.; B 3.5 mm.

(3) Patient aged 23 years; married 6 years. Five years ago a child born at 8 months died at 3 months. Four years ago gave birth to a 7-months child, stillborn. Three years ago had 2 months' abortion, another the year following, at 2 months. One year ago had a child born dead; said to have been "distinctly syphilitic"; an "unusual amount of liquor amnii." This miscarriage was preceded by one month's flow. Last period began September 1; abortion December 4 (?).

(4) The surface of the ovum is smooth and covered with decidua. The very large cavity is lined with a very smooth membrane which proved to be the amnion.

The decidua is composed of an inflammatory mass. At points there are abscesses. Between the decidua and the chorionic membrane the villi are packed together in an inflammatory exudate. Most of the trophoblast is necrotic, but the mesenchyme of the villi is still sharply defined. The dissociation of the embryo is quite complete, although the form of the brain and heart can still be made out. The umbilical cord is short and distended, and in the chorion, opposite to its attachment, there is a sharply defined epithelial tube lined with cylindrical epithelium. This, no doubt, represents the distended allantois. The embryo is irregular in shape and filled quite uniformly with round cells. These are very pronounced within the cavities of the heart, but do not invade its wall. They appear to reach the heart by invading it through natural channels. There is a small remnant of the Wolffian body, and the eye-vesicles are still outlined by their pigments. They are detached from the brain and filled with round cells. The borders of the hind-brain are fairly well pronounced, but those of the fore-brain are entirely obliterated. The anterior tip of the head is pronounced and extends beyond the brain, which makes it appear as though the mesenchyme of this region had continued to grow independently. No ear-vesicles can be found.

(6) Infiltration; probably early lues.

No. 466.

(1) Henry Rohfling, St. Louis, Missouri.

(2) A 29×23×16 mm.; B 4 mm.

(3) The patient, who was 35 years of age, never missed her menstrual flow; always regular, 28 days from the beginning of last menstruation, the periods lasting 4 days. On the day of the abortion she began to menstruate early in the morning, and at about 6 o'clock in the evening the physician was called on account of pains, which patient asserted resembled labor pains. On examination he found a slightly dilated os and a protruding mass which felt like a cyst. After strong bearing down he received the mass, which proved to be an ovum, *in toto*. Patient had borne three children, all in a healthy state.

(4) Somewhat over half of the ovum is covered with villi, 2 to 3 mm. long, very irregularly shaped, and many of which show bulbous enlargements. Over the remaining portion of the ovum are sparsely scattered villi about 1.5 mm. in length, which branch several times, but do not show enlargements.

(5) The stroma of the villi is non-vascular, fibrous, and so degenerate in many instances that few nuclei remain. Degenerate erythroblasts (Hofbauer cells of Minot) lie between the amnion and chorion, and the chorionic membrane is rather fibrous. The trophoblast lies in necrotic knots among the villi. A window being cut in the ovum, it was examined in strong sunlight under the binocular at every possible angle. There is a small amount of granular magma. An opaque spot is seen near one end. This has the general appearance of a small embryo with a groove along its dorsum. Magma covers it so closely as to prevent a sharper picture. The embryo is curled sidewise upon itself, and the camera drawing made of it before it was cut shows that we have an extensive spina bifida reaching well up into the head region. In section the embryo shows the homogenous appearance so characteristic of those specimens in which dissociation has taken place. The outline of the brain is recognizable and the two optic stalks are present. Only the anterior end of the brain is inclosed. In the head region the epithelial covering has fallen off, and round cells have accumulated around the periphery of the sections. Caudal to this the central nervous system opens over the back of the specimen in a broad, shallow trough. At intervals ventral to this trough in the body of the embryo are dense accumulations of cells, which probably represent remnants of both mesodermal and entodermal structures, most of which are unrecognizable.

However, the solid heart figures in this way in familiar outline on the ventral surface. The embryo is attached along its ventral surface to the amnion, from the anterior limit of the heart backward. Near its caudal end it is bent abruptly to one side. In this region the central nervous system is closed, and its round outline may be seen twice in the same section, with about 10 somites indicated in the region between. There is a fragment lying on the amnion near the embryo, which may represent the umbilical vesicle. It is very small, with practically no vessels.

(6) Some early hydatiform degeneration.

No. 489.

(1) John A. Luetscher, Baltimore, Maryland.

(2) A 45×30×25 mm.; B 2 mm.

(4) The ovum is smooth and partly covered with atrophic villi, over which there is an extensive decidua. The large cavity within measures 30×23 mm. and is lined by a smooth membrane which proves to be the amnion. The amniotic cavity is filled with clear fluid, and on one side, closely attached to the chorion, is a cylindrical embryo 2 mm. long, shown in section in figure 28, plate 4.

(5) Sections through the chorion show it to be covered, as was surmised, with a capsule of decidua and mucous membrane, half of which are infiltrated. Where the mucous membrane comes into contact with the villi there is an extensive fibrinoid degeneration. The chorionic membrane is closely attached to the amnion, but where they are separated the gap is filled out with a delicate reticular magma. The villi are mostly non-vascular and fibrous, but some seem to have undergone mucoid degeneration. The latter are filled with Hofbauer cells. The intervillous spaces contain blood and large necrotic nodules of trophoblast. Growing into this substance are numerous processes of active syncytium. In other words, there is a very perfect implantation in this specimen. The chorionic wall contains a number of blood-vessels filled with blood. The chorion in the neighborhood of the attachment of the embryo shows a beautiful implantation. The trophoblast cells invading the uterine mucous membrane are capped with fibrinoid substance, and the mesenchyme of the villi has undergone extensive fibrous degeneration. The non-vascular umbilical cord is in direct continuity with the amnion, but not with the chorion. The embryo itself has undergone extensive dissociation, but the brain, heart, and liver can be outlined. The round cells of the embryo extend out into the cord, and where they stop there are many Hofbauer cells, making it appear as though the latter arose in the chorion and are invading the embryo. The dissociation of the brain is quite complete, and within the embryo it is somewhat difficult to see a line of demarcation between the brain and the adjacent mesenchyme. Unfortunately, we have no clinical history of this interesting specimen, but its morphological study suggests that the prime difficulty may have lain in the umbilical cord.

(6) Infiltration, probably luetic.

No. 545.

(1) Richard F. Rand, New Haven, Connecticut.

(2) A 12×9×9 mm.; B 5 mm.

(3) Patient has one healthy child 14 months old. Last menses September 2 to 7, normal. Coitus, September 15. Menstruation due September 30, but failed to appear, the patient feeling merely "out of sorts." Coitus October 6. October 22, 23, and 24 had a very slight show; October 25, cramps and free flow. Embryo in sac found in clots in the cervix.

(4) The specimen is well preserved and partly covered with villi. It contained a cylindrical embryo suspended upon what at first appeared to be a large umbilical cord.

(5) Sections show the chorionic wall to be very thin and somewhat fibrous, as are also some of the villi which have undergone mucoid degeneration. On one side they are matted together with mucus and fibrin containing only a few leucocytes. The trophoblast is scanty. The embryonic mass is closely encircled by an amnion. The umbilical vesicle reaches from the lower surface of the embryo almost to the chorion. In this region of the latter there are but few villi. The umbilical cord is small and runs around one side of the amnion to reach the chorion at a point somewhat distant from the tuft of villi. The vessels then encircle the chorion and finally reach those villi which seem to have been still active. The embryo has undergone extensive dissociation. The brain is almost completely dissociated and entirely fills the atrophic head. The eye-vesicles can still be made out, and the otic vesicles are sharp and filled with round cells. The lower part of the body has undergone less change than the head end. The eye, spinal cord, and Wolffian bodies are well formed. The heart has undergone the least change. The pleural and pericardial cavities are well formed. The arm and leg buds are just beginning, and in the lower part of the body the myotomes are sharply outlined.

No. 551.

(2) A 11×6×6 mm.; B 3 mm.

(3) Last period June 27. Left husband June 7. Abortion August 30, after two weeks of ill health. Pelvic inflammatory disease. The whole ovum was expelled, but opened before fixing.

(4) Amnion with distorted embryo 3 mm. long. Near the latter is a vesicle 2 mm. long, and on the opposite side of the amnion a granule 1 mm. in diameter.

(5) The entire mass was cut in serial sections and those containing an embryo were mounted. The cylindrical embryo shows extensive dissociation with an early stage of destruction of the brain. The brain-tube with its eye-vesicles is distended and the wall partly broken down, the adjacent mesenchymal cells entering it. The spinal canal likewise is distended. The heart has collapsed and the inner walls are partly dissociated. There are several large blood-vessels well distended with blood. The chorda is present. The cœlom is sharply defined and passes off into the umbilical cord, which is attached to the amnion. In this region the amnion is thickened and fibrous. The yolk-sac passes through the patent cœlom well into the body of the embryo. In addition to the attachment of the embryo to the amnion, there is a special band of tissue making a second umbilical cord which passes as an isolated band over the region immediately below the heart and across the amniotic cavity, to become attached to the amnion at a point somewhat distant from the embryo. It contains a blood-vessel filled with a great quantity of blood-cells, which passes around the amnion behind the embryo and becomes markedly dilated. In this section of the amnion there is a capillary plexus encircled by numerous strands of mesenchymal tissue, making it appear as though the amnion had been attached to the chorion in this region. Since the chorion was not received it is impossible to establish this point. Within this region there are several larger isolated cavities having the appearance of diverticula of the amniotic cavity, and it may be that they arose from it.

No. 587.

1) F. A. Conradi. Baltimore, Maryland.

2) A 58×38×29 mm.; B 7 mm.

(4) The chorion is pear-shaped, quite smooth, and without villi. The walls are thick and fleshy, and surround a smooth cavity, 32×23×23 mm., filled with clear fluid. This cavity appeared also to contain a layer of reticular magma (?). On one side of it, closely attached to the amnion, was an oblong embryo shaped like a grain of wheat, with a small additional knob at one end, probably a remnant of the head. The length of the embryo is 7 mm. and its greatest diameter is 4.5 mm.

(5) Sections of the chorion show it to be composed of a thin chorionic wall somewhat separated from the amnion, and between the two there is a delicate reticular magma. The entire mass is encircled by a decidua somewhat infiltrated with leucocytes, which is separated from the chorion by a layer of fibrinoid substance. Between the

latter and the chorionic wall are small irregular villi, most of which are degenerated, and which contain a scanty amount of trophoblast. The stroma of the villi, which is somewhat hyaline and partly mucoid, is rich in nuclei. The chorionic wall appears to have undergone a gradual atrophy. The embryo is greatly dissociated. The central nervous system is practically solid, and attached to the brain in front are small atrophic, but completely dissociated, eye-vesicles. One of these shows a small amount of pigment formation. The spinal cord contains a lumen throughout the greater length of the body. The heart and blood-vessels are easily outlined by the blood within them, but their walls are indistinct. A slight indication of cœlom where it passes into the umbilical cord, and a remnant of the intestines can be made out. The cord has undergone maceration and the extremities are atrophic.

(6) Decidua slightly infiltrated.

No. 621.

(1) George H. Hocking, Govans, Maryland.
(2) A 70×45×40 mm.; B 3 mm.
(4) The specimen is pear-shaped, dark, and well covered with decidua. The walls are thick, measuring at points over 10 mm. Within is a cavity 20×20×20 mm., filled with clear fluid, in which floats a transparent vesicle. The amnion is suspended in the cœlom, which is lined with most delicate and transparent reticular magma. On one side is an atrophic embryo 3 mm. long.

(5) The chorionic wall is transparent, but may be a little more fibrous than in normal specimens. The villi also are somewhat fibrous and non-vascular, with considerable trophoblast attached to them. This in turn has a fairly normal connection with the decidua. The latter is somewhat fibrous and hemorrhagic, with very little leucocytic infiltration. The intervillous spaces contain some blood and considerable stringy matter, the latter being filled with buds of syncytium. At certain points there are very large spheres of trophoblast; in some places the tips of the villi end in them, and others pass through them. The embryo is markedly dissociated and is partly filled with round cells. In the head the central nervous system is distended, although the outline is still preserved. The eye-vesicles are very atrophic, and the brain reaches only to the upper part of the body. In this region the heart, which lies within a well-formed pericardial cavity, begins. From it arise two vessels which run down to the point of attachment of the embryo to the thickened amnion, which divides near this point, forming a very large vesicle noticed in the specimen before it was cut. One side of this is closely attached to and directly continuous with the chorion. In the lower part of the embryo there is a row of cells running along the dorsal side, probably the dissociated cord. The cœlom is well formed.

No. 639.

(1) Edwin B. Fenby, Baltimore, Maryland.
(2) A 18×12×12 mm.; B 6 mm.
(3) Patient took 8 grains of quinine to break up a cold and two or three days later had an incomplete miscarriage. She did not think she could have been pregnant more than two weeks, and said she did not know she was in that state. The specimen was obtained through curettage for an incomplete miscarriage.

(4) The ovum is covered with irregular patches of ragged villi and filled with a dense mass of granular magma. Within there is a disintegrated embryo whose greatest length is 6 mm. There are also two round bodies, about 1 mm. each in diameter, which probably are the arms.

(5) The chorionic wall and villi are somewhat fibrous, with practically no trophoblast. Sprouts of syncytium arise from some of the villi. The embryo is badly macerated, and the brain is completely dissociated, there being no lumen present. The boundaries of the spinal cord are indistinct. Only a portion of the embryo was cut into serial sections.

No. 655.

(1) A. G. Singewald, Baltimore, Maryland.
(2) A 30×30×10 mm.; B 4 mm.
(3) White patient, aged 36 years; married 18 years. Has had nine pregnancies—four abortions and five births at term. Four children living. Three abortions occurred within the last three years. The first two took place in an interval between full-term births. All were induced. The patient last menstruated January 22 to 27, and the abortion occurred March 21, having been induced February 28. Bleeding from the uterus began March 1 and continued intermittently until March 21. Uterus rather enlarged. Part of placenta retained. No infection; no venereal diseases.

(4) The ovum was carefully examined, and a fine reticular magma was found lying so closely about the embryo, yolk-sac, and belly-stalk that great care was necessary to obtain a clear view of it without the reticular fibers pulling on the amnion or yolk-sac. The embryo appeared to be normal, with normal amnion; the yolk-stalk lay to the left, the belly-stalk to the right; the cœlom is wide open posteriorly. The heart and lungs are most prominent. In general it might be said that the body below the heart is unusually short, but it may be flexed. Direct measurement of the embryo through the amnion while in alcohol gave 4 mm. as the greatest length. The edges of the ovum opposite the embryo are denuded for a few millimeters, but the remainder is covered closely with villi, which reach 5 mm. in length and branch two or three times.

(5) The sections of the chorion show that the villi are normal in form, but macerated. All of them contain blood-vessels and blood. There is considerable trophoblast and a peculiar mucoid substance between the villi. The embryo appears to be normal in form, but badly macerated, but whether it is dissociated is impossible to determine. Judging from the history, it was probably killed some time before the abortion.

(6) Decidua absent.

No. 669.

(1) O. S. Lowsley, New York.
(2) B 7 mm.
(3) Patient's last period two months before abortion.
(4) The club-shaped embryo was attached to a small piece of fibrous chorion, on which there were no villi.

(5) The dissociated brain almost completely fills the head of the embryo, and the tissues of the body have undergone extreme dissociation. It is difficult to outline any other organs, although there are indications of the vertebræ and spinal nerves. In place of the heart there is a large group of round cells, but these grade over into the adjacent tissues.

No. 690.

(1) D. V. Adnaine, Williamstown, Massachusetts.
(2) A 40×35×25 mm.; B 7 mm.
(3) The specimen came from a woman 36 years of age, who has been married 7 years. She is the mother of a child 6 years old, and had an abortion August 15, 1910. Last menstrual period October 20, 1911; abortion January 12 following.

(4) The ovum measures 40×35×25 mm. One half of it is covered with well-developed villi; the other half is fibrous, with but few ragged villi. The interior is filled with a clear fluid. Within the amniotic cavity is an atrophic embryo 7 mm. long, without any well-defined umbilical cord. From the front the organs are protruding, and in front of the head is a small, club-shaped nodule, which it was thought may represent the heart.

(5) A portion of the ovum was cut into serial sections to get the relation of the membrane, and the embryo was cut sagittally. The sections give its greatest length as 7 mm. Sections of the chorion and villi show that the mesenchyme is edematous and contains but very few blood-vessels. The trophoblast is scanty, but at points is

vacuolated. Otherwise the ovum is undergoing fibrous degeneration. There are also numerous buds of syncytium. The exocœlom is filled with a very dense mass of magma, but a large part of the amnion is so closely blended with the chorion that it can not be separated from it. Along this line, as well as in the exocœlom, there are numerous Hofbauer cells. Although the embryo is cylindrical in shape, macerated, injured, and dissociated, the organs can still be outlined. The liver is well infiltrated with round cells; the heart has apparently broken away, but the larger blood-vessels are filled with blood. The front of the head is very small and entirely filled with the dissociated brain, which protrudes anteriorly.

(6) Very early hydatiform degeneration. Decidua absent.

No. 704.

(1) Winfred Wilson, Memphis, Texas.

(2) A 20×12×12 mm.; B 6 mm.

(3) Patient aged 26 years; married 1904. Four pregnancies: Birth at term 1906, another in 1910; abortion 1912, and the present one, June 8, 1913. Last menstrual period April 25 to 30. No infection, but bad retroversion of uterus. Does not belong to a large family.

(4) The specimen, which measures 20×12×12 mm., consists of a clean chorion, covered mostly with villi which divide about twice. On one side there are no villi, but instead a smooth membrane. The specimen is filled with reticular magma, in the center of which is a cavity about 3 mm. in diameter. On clearing away the magma it was found that this cavity contained an embryo which, when straightened out, measured about 6 mm. in length and 1 mm. in diameter. It has a knob-like head 1 mm. in diameter, which in form resembles very much a chick of the same age. No amnion was found.

(5) The chorion is somewhat fibrous, with a scanty trophoblast, and contains numerous blood-vessels filled with blood. The embryo is embedded in a granular substance and an extensive infiltration of round cells which are largely disintegrated. There is no amnion. The central nervous system can still be outlined, and a few peripheral nerves recognized. No other organs can be seen.

(6) Early hydatiform degeneration. Decidua absent.

No. 710.

(1) Howard Fletcher, Fairfax, Virginia.

(2) A 95×55×55 mm.; B 13 mm.

(3) Patient aged 31 years; married 6 years. Mother of three children, this being her first abortion. Last period October 27 to 30; abortion following June 15.

(4) The chorion measures 95×55×55 mm., has a rough surface, with irregular and atrophic villi and some decidua. Within is a cavity of uniform caliber of about 2 mm., which extends throughout the specimen. To one side of the cavity was a large mass 40×30 mm., which was found to be a subchorial hematoma. Opposite this mass, towards the point of the specimen, was an atrophic, bean-shaped embryo 13 mm. long and 5 mm. in diameter, with an edematous umbilical cord.

(5) The chorionic wall and amnion are very fibrous and thickened, and are encircled by a mass of fibrin, blood, and coagulum, in which are embedded necrotic fibrous villi and small masses of dust. The epithelium of the chorionic membrane is somewhat abundant, but vacuolated and necrotic. The embryo is almost completely dissociated, but the organs can still be made out. The ribs are very evident. There are remnants of the extremities and a large cavity within the short umbilical cord. A few peripheral nerves are present, but the central nervous system was disintegrated completely, forming, in fact, an irregular amorphous mass in which there is seen the pigment of the eyes.

No. 785.

(1) C. S. Minot, Boston, Massachusetts.

(2) A 15×12×10 mm.; B 2 mm.

(3) Patient aged 27 years; married in 1911. One previous pregnancy, a birth at term. Last menstrual period August 5 to 10, 1913, and abortion October 8 following. Had been menstruating since September 20; occasional show. Badly lacerated cervix. No venereal diseases. Family fertile.

(4) When received the chorion had been opened. It is entirely covered with irregular villi, well matted together, and many of them are club-shaped. Within there is a great deal of reticular magma, in the center of which is an embryo 2 mm. long, with a knob-like head.

(5) The villi are fairly fibrous, and between them are considerable trophoblast, blood, and a slimy substance rich in leucocytes. Some of the villi contain remnants of blood-vessels and a few have undergone mucoid degeneration. Within the chorionic wall is the amnion, which is thrown into many folds. The embryo is well disorganized. The brain-tube has two marked protuberances from the head end, probably the remnants of the eye-vesicles. At the junction of the head with the body the solid nervous system communicates freely with the exterior of the body. Otherwise, no structures can be recognized in the head or in the upper part of the body; but as the lower part is approached a free communication between the amnion and the yolk-sac takes place through the dorsal midline. That is, there is a spina bifida, or probably an open blastopore. The lower part of the body is closely attached to the yolk-sac, there being no true umbilical cord. The tissues throughout the body are dissociated, and only at its lower end is there any indication of blood-vessels.

(6) Probably very early hydatiform degeneration. Decidua absent.

No. 839.

(1) W. S. Miller, Madison, Wisconsin.

(2) A 50×30×30 mm.; B 5 mm. long.

(4) The specimen consists of a beautiful white egg-shaped ovum, 50×30×30 mm., about one-half of which is covered with slender, thread-like villi, as much as 9 mm. in length. The other half of the surface is bare and transparent. Through the clear chorionic membrane and in the middle of the bare area a small white embryonic rudiment could be seen. On one side of this bare area the ovum was opened and found to be free of magma. The embryonic rudiment, measuring 5 mm., lay within a large amniotic cavity. Stretching from the embryo to the chorion, opposite the well-developed villi, was a white cord about 17 mm. long (magma?).

(5) Sections through the embryo include also the chorionic wall, which is found to be somewhat fibrous and covered with atrophic villi which have undergone mucoid degeneration. Most of the trophoblast is degenerate. The entire cavity of the chorion is lined by the amnion, which contains a very thick-walled cavity. Within, and closely attached to it, lies a nodular embryo. The tissues are markedly dissociated. The central nervous system, although nearly obliterated, can be followed throughout the body. At one point there is a remnant of the cœlom, and the region of the heart can still be outlined.

(6) Some hydatiform degeneration. Decidua absent.

No. 842.

(1) G. C. Ney, Baltimore, Maryland.

(2) A 76×34×27 mm.; B 5 mm.

(4) The knotty, fleshy abortion mass measures 76×34×27 mm. Cross-section near one end discloses what is apparently a collapsed chorionic cavity, measuring about 10 mm. across. The next slab shows a dimension of almost 20 mm. for the cavity. A remnant of the mass was then opened cautiously by a longitudinal incision, and disclosed a large flattened oval space, 50×20 mm., lined by a smooth membrane and containing at one pole a compact, deep-red clot, 25×15×15 mm. At one point there is a small cylindrical protuberance about 5 mm. in length and 2 mm. in diameter—the embryonic rudiment.

(5) Sections were cut longitudinally through the embryo attached to the chorion. The amnion and chorion are fibrous, and the non-vascular villi are matted together by an inflammatory exudate; the whole being covered by a very thin, inflamed decidua. Between the amnion and the thick, macerated, degenerate chorion there is a very dense reticular magma containing a small collapsed and dissociated umbilical vesicle. The embryo is pear-shaped, with the stem attached to the amnion, there being no umbilical cord. It is composed of a mottled mass of round cells, so that only the central nervous system can be made out with precision. The latter is a small mass of cells located in the dorsal midline and in the head. Both eye-vesicles are present, but not connected with the brain.

(6) Mild infiltration.

No. 856.

(1) C. O. Henry, Fairmount, West Virginia.

(2) A 57×31×26 mm.; B 5 mm.

(3) Polish woman aged 17 years; married August 30; first pregnancy. Last menstrual period December 24–28 (same year); abortion February 11 following. Condition of uterus good; no infection. No venereal diseases. Family fertile.

(4) The specimen consists of a pear-shaped, thin-walled transparent vesicle measuring 57×31×26 mm. The sac, which seems to be the denuded chorion, is sharply pointed at one end. An opaque, white, and comparatively straight embryonic remnant was found protruding from one side of the wall of the sac, near the base. The embryo measures about 5 mm. and somewhat resembles an embryo with 15 somites.

(5) The non-vascular chorion and amnion are thin and fibrous, and covered by a single layer of degenerated cells. There are no villi. The embryo is completely dissociated; the central nervous system, which appears as a solid mass, reaches through its whole length. There is an indication of the cœlom, and in the lower part of the embryo the myotomes can just be made out. In this region the tissues are dissociated. The cord is short and attached directly to the chorion, which here contains a few islands of blood-cells.

No. 874*b*.

(1) Homer Scott, Little Rock, Arkansas.

(2) A 35×30×30 mm.; B 3 mm.

(3) Patient aged 32 years; married September 9, 1906. Four pregnancies. Last menstrual period January 23 to 28, 1914; abortion April 13 following. No infection of uterus. First abortion in her family.

(4) The chorion, which is transparent and spherical, measures 35×30×30 mm., and is partly covered with atrophic villi. It contained clear fluid, within which the amnion, 10 mm. in diameter, was floating. The cœlom was filled with delicate reticular magma. The embryo, which is cylindrical in form, was attached to the amnion.

(5) The chorion is closely covered with villi, which have a reasonable amount of trophoblast and some mucoid substance between them. The mesoderm is somewhat fibrous. The embryo is closely attached to the amnion, and at the point of attachment the cœlom communicates freely with the cavity of the chorion. It appears as though there was an arrest of development at this point. The cœlom is distended, but the greatest distention is in the central nervous system, in which it is so pronounced that it might be called "hydrocephalus." The eyes are very small and atrophic.

(6) Hydatiform degeneration. Decidua absent.

No. 885.

(1) Robert Dodds, Chicago, Illinois.

(2) B 10.3 mm.

(3) Patient aged 33 years; married April 1906. Three pregnancies—two births and one abortion. Last menstrual period September 5, 1910; abortion January 11 following. Condition of uterus normal. No venereal diseases. Family fertile.

(4) The specimen consists of a small cylindrical embryo 10.3 mm. The head is rounded and the extremities are barely marked. The cord is long, running out to a slender point at its attachment to the chorion, and has undergone mucoid degeneration.

(5) The tissues are markedly dissociated, but the skin and epidermis are intact. The brain is converted into a kind of unformed mass, and the front of the head has grown over into the thorax, concealing entirely the lower jaw. The heart is represented by a mass of round cells. The liver and intestines can be outlined.

No. 915*a*.

(1) C. S. Minot, Boston, Massachusetts.

(2) A 26×24×15 mm.; B 4.6 mm.

(4) The specimen consists of a flattened spherical ovum, measuring 26×24×15 mm., covered over most of its extent by villi which reach 9 mm. in length. It was opened freely so as to completely expose the chorionic cavity, in which are a moderate amount of reticular magma and a collapsed spherical amniotic sac about 10 mm. in diameter. Through the walls of the latter an opaque white embryo, apparently free in the amniotic cavity, can be seen. It measures 4.6 mm. in length and is distinguished by a marked dorsal concavity. The head is represented by a practically featureless nodule in which one may make out the mouth. An extension of anterior limb-buds may be seen.

(5) The amnion and chorionic wall are somewhat fibrous, as is also the mesenchyme of the villi. The trophoblast is scanty. The embryo has been almost completely dissociated and only the central nervous system can be made out with precision. It forms a solid strand which is enlarged within the head region, and ends in front in a very small solid mass to which are attached two rudimentary eyes. There are no lenses.

(6) Hydatiform degeneration. Decidua absent.

No. 933.

(1) Gilbert M. Elliott, Brunswick, Maine.

(2) A 37×32×40 mm.; B 4.5 mm.

(3) Patient aged 32 years; married in 1904 or 1905. Four pregnancies. First ended at term, 1906; second in abortion at three months, 1910; third at term, 1912; fourth, this abortion, August 5, 1914. Last menstrual period supposed to be about the middle of June. Condition of uterus normal. Patient has slightly contracted pelvis. Family fertile.

(4) The specimen consists of a spherical ovum measuring 37×32×40 mm., about one-half of which is covered with villi, normal in form, and reaching 9 mm. in length. The remainder of the ovum is devoid of villi. In the denuded area the chorion was carefully opened, disclosing a beautifully transparent spherical amniotic sac, about 20 mm. in diameter. Although separated by a considerable distance, the amnion is bound to the chorion by many invisible magma strands. The spherical yolk-sac is 8.5 mm. in diameter. Within the amnion an opaque white embryo, measuring about 4.5 mm. long, could be seen. It is clearly malformed.

(5) Sections of the chorion show that the tissues appear to be quite normal, but the trophoblast is scanty. There also are strings of mucus in the intervillous spaces. The embryo was cut with the chorion and amnion around it. The tissues are markedly dissociated, but the organs can still be made out. The eye-vesicles are very small and atrophic, and the lenses still attached to the skin. The central nervous system is practically solid. The blood from the blood-vessels extends over into the tissues.

(6) Early hydatiform degeneration. Decidua absent.

No. 937.

(1) Gilbert M. Elliott, Brunswick, Maine.

(2) A 30×11×7 mm.; B 4 mm.

(3) Patient aged 27 years; married in 1907. Three pregnancies First and second at term, June 1908 and

December 1912, respectively, and this abortion, August 15, 1914. Last menstrual period June 24 to 27. Condition of uterus normal. No venereal diseases.

(4) The specimen consists of a small oblong abortion mass, measuring 30×11×7 mm. On opening, it is found to consist chiefly of fibrous chorionic tissue so infiltrated with blood as to be very fragile. Within is a pear-shaped chorionic cavity 11 mm. in length by 5 mm. greatest width, which contains a clear coagulated substance. This substance broke easily and could be lifted out, and proved to be a very interesting pathological embryo, 4 mm. long, with a transparent yolk-sac 3.3 mm. in diameter.

(5) The chorion is fibrous and covered with small degenerate villi, matted together and surrounded by a degenerate and inflamed decidua. Most of the trophoblast is necrotic, and there is considerable nuclear dust, as well as an invasion of leucocytes. The embryo is mostly dissociated and is attached to the chorion at the lower end. In its middle there is an accumulation of cells which appear to be the remnants of the heart, and towards the upper end the nervous system can be outlined. No eyes, ear-vesicles, or extremities are present. The amnion is almost completely destroyed, while the embryo is embedded in a mass of granular magma which is being invaded by cells from the embryo at a point where the two come in contact.

(6) Mild infiltration, probably luetic.

No. 1004.

(1) E. Plass, Baltimore, Maryland.

(2) A 256×52×68 mm.

(3) The patient was the mother of 9 children and had one abortion four years ago. Last menstrual period occurred on October 1 to 5, and the abortion, which was spontaneous, on December 4.

(4) The decidual cast, which was open at one end, contains a chorionic cavity 20 mm. in diameter. The latter contains nothing but a portion of an umbilical cord 18 mm. long and 2 mm. in diameter. Since the amniotic fluid had been drained off, remnants of the embryo may, however, have escaped through the opening.

(5) The membranes are fused and have undergone hyaline degeneration. The villi are fibrous and degenerate. The decidua also is degenerate and infiltrated slightly, with local intensification. Portions of it have undergone fibrosis. Except in a few places, only moderate syncytial proliferation is present. No remnants of the embryo were seen.

(6) Decidua slightly infiltrated.

No. 1022*a*.

(1) Ernest C. Lehnert, Baltimore, Maryland.

(2) A 62×33×24 mm.

(3) The last menstruation occurred on January 2. Hemorrhage began March 6 and abortion occurred March 25. Abortion was said to probably have been mechanical.

(4) The chorionic vesicle contained a blighted embryo 3 mm. in diameter. Examination of the former under the binocular microscope shows the presence of splendid partial hydatiform degeneration.

(5) Histologic examination confirms the presence of hydatiform degeneration, although the histologic specimen was not taken from the portion which showed the hydatiform degeneration present in most pronounced form. The stroma of the villi is degenerate and fenestrated and contains numerous atypical Hofbauer cells. The epithelium is not increased and syncytial buds are practically absent. The chorion and embryo also are degenerate. Many of the oval and elongated degenerate decidual casts show a finely granular cytoplasm, but the decidua as a whole is too degenerate to enable one to judge of the question of infiltration. However, since the villi are embedded in large, dense masses of leucocytes, infection undoubtedly was present.

The tissues of the embryo are dissociated and its development was apparently normal for only the brain and cord. Possibly the optic cups and the cœlom are present. Although an area of condensation is found in the more caudal portion, it is impossible to identify this with the development of any particular organ.

(6) Partial hydatiform degeneration.

GROUP 6.

No. 54.

(1) J. M. McMorris, Belle Plaine, Iowa.

(2) B 11 mm.

(4) Only the embryo was received at the laboratory. The head is atrophic, but otherwise the specimen has the appearance of a normal embryo of 4½ weeks.

(5) In the sections it is seen that the central nervous system is solid, with the exception of the midbrain, whose ventricle still communicates with the exterior of the body through an open neuropore. Some of the vertebræ are fairly well developed; the liver is large, but the heart, other organs, and cœlom are difficult to outline because of the presence of marked disintegration.

(6) Decidua and chorionic vesicle absent. Maceration and disintegration of fetus.

No. 69.

(1) G. Henry Chabot, Baltimore, Maryland.

(2) A 70×50×20 mm.; B 13 mm. CR (from mounted section).

(4) The chorion is smooth, not being covered with villi. The head of the embryo is atrophic and club-shaped, the body fairly plump. The arms are well developed, of the 5-weeks stage, and appear normal.

(5) The central nervous system is distended and the brain is macerated. The outline of the organs and of the peritoneal cavity are not distinct, and the entire body is filled with migrating cells. The main bundles of nerves are filled with spindle-shaped cells, making them look like the nerves of amphibian embryos. The epidermis is hypertrophied, and at many points forms papillæ. Some of these have a short pedicle and could justly be called appendices. The embryonic end of the umbilical cord is atrophic, invaded by migrating cells, and its blood-vessels are greatly distended. The whole chorion and part of the cord have undergone fibrous degeneration. Twenty-five vertebræ are present and quite well preserved.

(6) Decidua and chorion absent.

No. 81.

(1) J. H. Branham, Baltimore, Maryland.

(2) A 65×55×35 mm.; B 20 mm.

(3) "Abortion took place just three months after the beginning of the last menstrual period."

(4) The apparently macerated embryo was broken in its middle. The crest of necrotic tissue on the head, the stumpy leg, the distended cord, and atrophic chorion, all indicate that it is pathological. The two parts were cut in serial sections and different portions of the chorion also were examined.

(5) Macroscopic as well as microscopic examination of the chorion shows that it has undergone extensive degeneration. Subchorial hematomata are present, and the chorionic membrane is non-vascular, fibrous, greatly thickened, and fused with the amnion. The villi are fibrous, wholly non-vascular, decidedly clubbed in some areas, and coalescing. The umbilical cord is extremely edematous near the abdomen, and contains only a trace of the vessels. The embryo is somewhat atrophic. Its central nervous system is macerated, and there is a marked cyst-like dilatation at the tip of the spinal cord, which incloses double cavities filled with mucoid reticulum. This tissue is similar in appearance to the normal notochord of the amphibian embryos. All the tissues, including the cartilages, show more or less dissociation. A necrotic crust covers the top of the head; the ectoderm is destroyed and the mesoderm covering the brain is greatly thickened

and pigmented with round cell infiltration of the surrounding tissue.

(6) Decidua locally infiltrated. This and the chorionic changes suggest lues.

No. 104.

(1) J. P. West, Bellaire, Ohio.

(2) A 35×35×15 mm. Embryo elongated, 12 mm.; if curled upon itself, CR about 7 mm.

(3) Last menstrual period began May 7, and abortion took place June 11.

(4) The villi of the chorion appear to be atrophic, and are absent on one side of the ovum. After carefully cutting in half, the ovum was found to be filled with magma, partly reticular and partly granular. On one side is an embryo with straightened head and atrophic extremities. This, with a piece of chorion to which it was attached, was cut into serial sections.

(5) The main walls of the chorion are fibrous; the amnion is intact. The brain and spinal cord of the embryo are dilated and dissociated, probably macerated also. The outlines of the organs and body-cavity are obliterated. The boundaries of the liver can no longer be determined. The tissues of the body are generally dissociated, and they, with the umbilical cord and magma, are infiltrated with migrating cells. The heart, large veins, and aorta are greatly distended with blood. The head is atrophic.

(6) Hydatiform degeneration. Decidua absent.

No. 122.

(1) J. W. Williams, Baltimore, Maryland.

(2) A 20×16×6 mm.; B 5 mm.

(3) "Last period began April 19, and the abortion took place June 23. Continuous bleeding for eight days before the abortion."

(4) The thin transparent and fibrous chorion is covered with a few scattered villi of irregular length. The embryo is atrophic, with club head, large heart, stump tail, and no limb-buds.

(5) The nervous system is greatly distended and dissociated. The front of the head and the branchial arches are atrophic. The liver is small, the Wolffian body well marked, and the body-cavity sharply defined. The large veins of the body and of the liver are greatly distended with blood, the aorta being much enlarged and empty. The tissues of the entire embryo are partly filled with loose round cells. The amnion is macerated.

(6) Decidua and chorion absent. Hydatiform degeneration of chorion.

No. 132.

(1) R. Munson, Washington, District of Columbia. (Sent by Dr. Lamb.)

(2) A 42×30 mm.; B 15 mm.

(3) The woman menstruated last between August 15 and 20, and aborted November 12.

(4) The chorion is atrophic, with but few villi. The embryo has a stub head and the extremities on the right side are atrophic, while those on the left appear to be normal.

(5) The organs of the embryo are about normal in form and structure. The cord and brain are slightly dissociated. There is a small number of migrating cells in the tissues of the body, as well as within the peritoneal cavity.

(6) Chorion and decidua absent.

No. 135.

(1) Wm. E. Moseley, Baltimore, Maryland.

(2) A 105×65×65 mm.; B 9 mm.

(4) The ovum is fairly smooth, its walls very thin and lacking in villi. It was completely filled with a gelatin-like mass, neither fibrous nor granular. Within this mass there is an atrophic embryo attached to a thin umbilical cord. The entire chorion is lined with amnion. The head of the embryo is atrophic and the body shaped like a grain of wheat. The extremities are more rudimentary on the right than on the left side.

(5) Sections of the embryo show the cord distended, the brain almost completely destroyed, and the mesoderm of the top of the head converted into a mass of mucoid tissue. The head end of the chorda is greatly hypertrophied, being converted into a mucoid tumor. On either side of this tumor are two large cartilages of normal structure. Farther cranialward, buried deep in the mesoderm, are two additional pearl-like bodies, which, on account of their appearance, as well as by the fact that they are encircled by an oval zone of pigmented cells, are identified as the lenses of the eyes. These bodies have within them lens fibers, making them appear much like the lenses of amphibians. The front end of the head is necrotic. The heart is convoluted, its outline obscure and distended with a mass of blood-cells. The outline of all of the abdominal organs and of the peritoneal cavity can be determined, although the tissues are considerably obscured by the great quantity of round cells within them. The entire wall of the chorion is very thin and lined throughout with a delicate fused amnion. The villi have almost disappeared, and in their place are islands of necrotic syncytium covered with a hyaline layer of fibrin. The whole chorion and decidua are infiltrated with leucocytes, which form small abscesses at points.

(6) Marked decidual infiltration and fibrosis; marked hydramnios.

No. 137.

(1) William T. Watson, Baltimore, Maryland.

(2) A 65×50×30 mm.; B 16 mm.

(3) "Last period commenced September 26. Abortion December 21."

(4) The ovum is nearly covered with long and well-developed villi, having a bare area on one side. The cœlom contains no magma. The embryo is broken from the cord and is macerated on its ventral end. The head is atrophic, but the arms and legs are normal. At the middle of the umbilical cord there is a marked swelling seen in other specimens of this kind.

(5) Sections of the chorion show the villi to be normal in form, but somewhat hyaline in structure and without blood-vessels. There is a considerable quantity of trophoblast. The thickened umbilical cord has within it a cavity partly filled with a reticular substance, homogenous in appearance and more intensely stained than the surrounding tissues. Within the cord there are large blood-vessels, greatly distended with blood-cells, which extend through the walls into the surrounding tissues. 10 mm. from the attachment of the cord to the chorion is the umbilical vesicle. It measures 3×2 mm.; its walls are degenerated and its cells, which are necrotic, fill its cavity. The stem of the umbilical vesicle reaches but halfway to the umbilical cord. The central nervous system of the embryo is irregularly distended and dissociated, the spinal cord being roughly segmented to correspond with the vertebræ. The liver is necrotic and filled with blood. The heart is collapsed and dissociated. The large blood-vessels are collapsed and empty, while the small ones are filled with blood. The outlines of the abdominal organs are pretty sharp, the tissues fairly free from migrating cells. Most of the epidermis has fallen off the embryo, but where it remains intact it shows areas of irregular thickening.

(6) Early hydatiform degeneration. Decidua absent.

No. 174.

(1) E. C. Gibbs, Baltimore, Maryland.

(2) A 35×25×25 mm.; B 13 mm.

(3) Last period January 11, and bleeding five weeks later, which continued until the eighth week, when the abortion followed.

(4) The ovum is smooth, having but few villi, and is filled with granular magma.

(5) Sections of the chorion show a marked degeneration of its stroma and walls, nearly all of its villi having been destroyed. The few fragments of villi that remain are embedded in blood and riddled with cells of the syncytial layer. The mesodermal layer of the chorion no longer is sharply defined, and is more or less filled with cells with fragmented nuclei, the origin of which can not be determined. The embryo is of the five or six weeks' stage, with pretty sharply defined organs and tissues which are more or less dissociated and infiltrated with round cells. Most of the epidermis has fallen off. In the region of the olfactory pit, which is almost obliterated, the epidermis forms two marked horn-like elevations. The central nervous system is swollen and dissociated more than the remaining tissues of the body, the change being greater in the brain than in the cord. The vascular system is gorged with blood, which is beginning to invade the surrounding tissues. This is most marked in the umbilical cord, which appears edematous.

(6) Decidua absent; not enough chorion present.

No. 177.

(1) R. G. Harrison, Baltimore, Maryland.

(2) B 12 mm.

(5) The sections show, well outlined, all the organs of an embryo at the end of the fifth week, but they are dissociated and swollen. The head is beginning to become stumpy, and the frontal process is necrotic and commencing to fall off. So extensive is the dissociation of the head that the brain has become practically solid, the vesicles being nearly obliterated. The process is not so extensive in the spinal cord. Most of the epidermis has fallen off. The vascular system is greatly distended with blood, which is infiltrating the tissues, especially those surrounding the larger arteries and veins. In general the tissues show the changes always seen in embryos which have been gradually strangulated before the abortion. In this specimen there is one marked variation in the changes usually found. The precartilage outlines all of the vertebræ and ribs, but no true cartilage is yet formed in them. Back of the eyes in the occipital region on either side of the head, there are two cartilages which are too well developed for an embryo in this stage. A more advanced stage of cartilage was found in embryo No. 135, described above.

(6) Decidua and chorion absent.

No. 188.

(1) G. N. Sommer, Trenton, New Jersey.

(2) A 45×40×40 mm.; B 17 mm.

(3) "Last menstruation began January 6; bleeding began March 19, and ended in a few hours with the abortion. The unopened ovum was immediately placed in 95 per cent alcohol."

(5) The cœlom is filled with granular magma, the chorionic membrane is absent, and the villi very fibrous and mostly lacking. The organs of the embryo are all normal in form and approximately of the degree of development for an embryo of this size. The tissues are dissociated somewhat, the most marked being that of the brain. The veins of the body are all gorged with blood, with but little migration of blood-cells into the surrounding tissues. The decidua is somewhat fibrous and degenerate.

(6) Slight infiltration of degenerate decidua.

No. 200.

(1) Max Brödel, Baltimore, Maryland.

(2) A 35×25×20 mm.; B 14 mm.

(5) The central nervous system is dissociated and macerated very much, the form of the brain and spinal cord being lost entirely. The organs are all disintegrated, the liver being necrotic. There is ulceration of the front of the head, but the epidermis is intact over the rest of it, in spite of the extensive internal change. The walls of the umbilical vesicle are broken down entirely and its lumen is filled with a mass of necrotic cells. The amnion, chorion, and villi are more fibrous than normal. The villi are non-vascular and show "granular hyperplasia." The nodules of trophoblast are quite necrotic and some of the villi are glued.

No. 201.

(1) Max Brödel, Baltimore, Maryland.

(2) A 80×60×50 mm.; B 20 mm.

(4) The ovum was received without villi, and when opened was found to be filled with a fluid which had hardened into a jelly in formalin. The embryo is atrophic with a necrotic mass on top of the head.

(5) The fleshy chorion proved to be a mixture of true chorion, villi, blood, fibrin, decidua, pus and syncytium. The layers show all stages of disintegration. The mesoderm of the villi is fibrous and at many points is invaded by leucocytes and syncytium. At other points the syncytium invades the blood-clot and frequently maternal blood sinuses are filled with leucocytes and syncytium. Within the embryo most extensive changes have taken place. The brain is greatly deformed and severed, through a growth of tissue from the spinal cord in the region of the medulla, back of the deformed ear. In fact, the brain is included within the cap-like body on top of the head. The spinal cord begins quite abruptly in the upper cervical region and ends in the same way in the upper lumbar region. At its end there is a curious fibrous tumor measuring half the diameter of the cord. The cord, so far as it is developed, appears to be normal, but somehow dissociated. Below the upper lumbar region the spinal cord is wholly lacking, the spinal canal being filled with mesodermal tissue rich in blood-vessels. Where it is missing, most of the spinal nerves appear to remain, and many dorsal ganglia can be made out. This all indicates that the changes in the central nervous system took place after the spinal nerves were developed. The eyes are united into a single one with a double retina, two lenses, a single choroid, and a single optic nerve; back of this they are double. It certainly appears as if the two eyes had wandered together and united in the middle line. The epidermis is quite complete, but is broken through at the back of the head. The extensive ulcer which is found here is very rich in blood-vessels, involves the walls of the brain, but does not reach into its ventricle. At the highest point of the head the epidermis has developed into a papilliform body; below this there is a large necrotic area in which is found a great quantity of yellow pigment granules. The mouth is closed, although the alimentary canal from there to the stomach is open and appears normal. The intestine is matted together, the cloaca and anus being obliterated. The epithelium of the upper portion of the intestine shows marked growths into this matted mass. The thoracic region, liver, and vascular system have undergone practically no change. The extensive growth of mesodermal tissue throughout the embryo has caused an extensive destruction and arrest of further development of the muscular system. This is shown by secondary changes in the connective tissue, especially that of the skin, which is markedly fibrous. Here the change is so great that it obliterated the external auditory canal entirely.

(6) Marked infiltration of the decidua.

No. 207 *a*, *b*.

(1) Max Brödel, Baltimore, Maryland.

(2) A 70×45×45 mm.; B 16 mm.

(4) The specimen is smooth, with small villi at one of the poles. Within are two embryos, both macerated with atrophic heads. The larger measures 16 mm.; the other is a little smaller, but as it is broken an exact measurement could not be made. The cords of both embryos are atrophic. There is some granular magma within the amniotic cavity, with several large clumps in the cœlom where the two amnions meet.

(5) Sections of the membranes show that the chorion is denuded of most of its villi, except over the point of

attachment between the cord and the broken embryo. The villi are non-vascular and fibrous, with a clear stroma in some. The entire chorion is covered with its decidua, which is rich in blood-sinuses and infiltrated with leucocytes. But few remnants of the syncytial layer of the chorion remain. The whole embryo is still covered by epidermis, except on top of the head, at the tail end of the body, and at the attachment of the umbilical cord. At these points there is a marked destruction of the tissues, which are beginning to disintegrate. The top of the head is ulcerated, and in front it is necrotic and pigmented, as is frequently noted. The nervous system shows the usual changes seen in strangulated embryos. The vascular system is gorged with blood, but none is within the vessels of either the cord or the chorion. Within the body there is quite an extensive migration of blood-cells in the tissues, obliterating them in part. The majority of the organs can still be outlined. We have here a rapid infiltration with migrating cells of an embryo of 40 days, with cytolysis rather than dissociation of the tissues. The changes in the broken embryo are practically the same as in the unbroken one, although they are more advanced. Only the head extremities and cord remain entire, and in these the changes are more marked than in the corresponding parts of the unbroken embryo. In the former it is practically a mass of individual cells, while in the latter the brain is swollen and quite solid.

(6) Marked decidual infiltration; chorionic changes somewhat suggestive of lues.

No. 216.

(1) A. Wegefarth, Baltimore, Maryland.
(2) A 35×35×25 mm.; B 17 mm.
(3) This specimen was entered as pathological, but later was transferred to the normal group. The original note is dated January 28, 1903.
(4) On further consideration, it appears that this is really a pathological embryo, as the head is somewhat rounded and the extremities are not well developed. The cord has two enlargements, and there is considerable granular matter within the amniotic cavity.
(5) Sections show the embryo to be both macerated and dissociated, the dissociation being especially marked around the cartilage and in the extremities. The blood-vessels are gorged with blood, and in the lower part of the body their walls are well defined. They seem to be normal within the head. The small segment of the chorionic vesicle which was cut is thin and only slightly vascular. The slender villi also are non-vascular and fibrous, and the thin amnion is fused with the chorion.
(6) Decidua absent; not enough chorion.

No. 232.

(1) M. Brödel, Baltimore, Maryland.
(2) A 45×25×25 mm.; B 14 mm. CR.
(4) Most of the chorion is devoid of villi, except immediately over the attachment of the cord, which appears to be normal. The villi are somewhat fibrous, with less numerous blood-vessels than usual, and are covered with a rich layer of syncytium. The amnion reaches the chorion.
(5) The embryo is atrophic and embedded in a mass of granular magma containing numerous round cells. Most of the epidermis has fallen off. The head is cylindrical in form, containing a solidified brain and dissociated eyes. The lenses are composed of broken cells surrounded by a very thick hyaline capsule. The organs of the body are not sharply defined, being filled with many round cells. Even the nerves and cartilages have lost their sharp borders. The extremities are stubby, being composed of densely packed round cells which show no differentiation. The blood-vessels are mostly empty.
(6) Endometritis.

No. 251.

(1) A. H. Ritter, Brooklyn, New York.
(2) A 30×25×25 mm.; B 9 mm.
(3) Last period January 16; abortion April 3.
(4) Half of the chorion is covered with villi; the other half is bare, thickened, and hemorrhagic. The amnion lines the entire chorion and the cord is very thin.
(5) Sections show that the mesoderm of the villi is rich in cells, fibrous, and devoid of blood-vessels. The main wall of the chorion apparently is normal, with a large number of vessels containing blood scattered through it. The head of the embryo is atrophic and is nearly filled with a distended, dissociated, and macerated brain, which protrudes from the back of the head. The eyes are solid and the lenses have become dissociated, but are encircled with sharply defined and thickened hyaline capsules. The heart and blood-vessles are distended and filled with blood. The organs and tissues of the body are not well defined and are filled with round cells. The epidermis is lacking. The extremities are stubby, without structure, and filled with round cells. The cartilages are sharply defined and the liver appears to be about normal. The decidua is very hemorrhagic and contains a large number of abscesses. Apparently there was an extensive endometritis.
(6) Decidua necrotic and infiltrated; probably early lues.

No. 262.

(1) H. F. Giering, Baltimore, Maryland.
(2) A 80×15×15 mm.; B 14 mm.
(4) The interior of the specimen is filled with a large amount of granular magma, in which was embedded a necrotic embryo 14 mm. long.
(5) The decidua is filled with small abscesses, the leucocytes invading the villi as well as the main walls of the chorion. The changes in the embryo are extreme, the nervous system being solid and filling the stumpy head. The outlines of the organs are hazy, they being filled more or less with round cells. The embryo is falling to pieces, but some of the epidermis is still intact.
(6) Marked infiltration of the decidua. No chorion.

No. 263*d*.

(1) Albert B. Lyman, Baltimore, Maryland.
(2) A 27×27×27 mm.; B 17 mm.
(4) The villi apparently are normal in form.
(5) In structure they possibly are a little fibrous and some are macerated. The blood-vessels appear to be normal. The cord is dilated, showing the double enlargements, which are mucoid in structure. The brain and spinal cord are dissociated, the brain protruding into the mouth, but the other organs are fairly well outlined. The heart and large blood-vessles are filled with blood, and there is some infiltration of the surrounding tissues with round cells. The epidermis has fallen off. The changes within the embryo may be due to maceration, but on account of the sharply defined tissues of the chorion and slight amount of fibrous changes in the villi and the mucoid dilatations in the cord, with some wandering cells in the tissues, it is probable that this specimen represents the earliest stage of a strangulated embryo of the sixth week.
(6) Decidua absent. Maceration of chorion and probably early hydatiform degeneration.

No. 270.

(1) L. R. Wilson, Baltimore, Maryland.
(2) A 40×30×20 mm.; B 14 mm.
(5) The chorion is only partly covered with villi, which are atrophic and fibrous in structure but contain some blood-vessels. The main wall of the chorion is also fibrous and of irregular thickness, but contains some blood-vessels. The amnion has reached the chorion and is filled with granular magma, which completely envelops the embryo. The central nervous system is distended, dissociated, and macerated. The large blood-vessels and

heart are distended with blood, and the tissues of the body are somewhat infiltrated with round cells. The outlines of the organs are slightly obscured, and the tissues macerated. The villi are fibrous and largely non-vascular.

(6) Decidua absent.

No. 276.

(1) Dr. Stanley, Portland, Maine.

(2) A 70×35×35 mm.; B 13.5 mm.

(3) Time between the last menstrual period and abortion 80 days.

(4) The walls of the chorion are partly infiltrated with blood, and on one side are closely adherent to a fleshy mass—the decidua.

(5) Sections through these regions show that the decidua contains large blood-sinuses and numerous small abscesses. The villi of the chorion are embedded in a mass of blood and covered with a normal amount of syncytium, but in structure they are fibrous and partly devoid of blood-vessels. In addition, they are invaded at numerous points by the syncytium, which forms in them small vesicles lined with two layers of cells, and which are often filled with dense masses of small round cells. These vesicles sometimes communicate with the surface of the villi by means of bands of epithelial cells. The chorion is in apposition to the amnion, but neither is invaded by syncytium.

The changes within the embryo are equally remarkable. The spinal cord is dilated and dissociated; the medulla is solid, fills the entire head, and protrudes from an opening formed by the destruction of the forepart of the head. In front of this opening the atrophic upper jaw, containing nerves, may be seen, and behind the epidermis it has grown into a small ridge encircling the opening. The outlines of the organs are not sharp, but those of the precartilages are very definite. The blood-vessels are greatly dilated and filled with blood-cells. They are especially well marked along the line from the umbilical cord to the heart. In their immediate neighborhood there is more or less infiltration with round cells. The smaller veins and arteries are still filled with blood.

(6) Marked infiltration of the decidua; early hydatiform degeneration of chorion.

No. 285.

(1) T. W. Keown, Baltimore, Maryland.

(2) A 45×35×35 mm.; B 8 mm.

(3) "Last menstruation October 9 to 12; abortion December 20. The specimen came away unbroken, was washed in water, and placed in alcohol. There is reason to believe that conception did not take place until the time for the period which lapsed. The mother insists that this is the case, and inasmuch as all three of her children had diphtheria at that time, this date probably is correct."

(4) The chorion is mostly bare, with some hemorrhage in its walls.

(5) The villi that are left are fibrous and contain few blood-vessels. The syncytium over them is very active and at numerous points it is heaped up in small mounds which form depressions, making it appear as if they were about to invade the mesoderm of the villi as well as that of the main wall of the chorion. The amnion fills the entire chorion, which is non-vascular. Between the villi there is a reticular arrangement of blood and mucus in which are found numerous leucocytes. The trophoblast enters this reticular mass at numerous points and makes a very remarkable picture. The embryo has an atrophic head and cord, showing, however, enough structures to fix its age at 4 weeks. The spinal cord is dilated and dissociated, and the brain is solidified, filling the entire head. The eyes are destroyed. The blood-vessels are enormously distended with blood, which also fills the tissues of the body, obscuring them to a great extent. The epidermis is intact.

(6) Decidua absent. Early hydatiform degeneration.

No. 311.

(1) Wm. T. Watson, Baltimore, Maryland.

(2) A 36×30×30 mm.; B 12.5 mm.

(4) The wall of the chorion is thin and covered with a few scattered and irregular villi.

(5) Sections show the villi to be in all stages of degeneration, the large ones with blood-vessels and a rich syncytium, the small ones, which are fibrous, devoid of syncytium and infiltrated with leucocytes. The spaces between them contain considerable blood, and where this comes in contact with an active syncytium the nuclei of the leucocytes are fragmented; elsewhere they are not. Portions of the main wall of the chorion are very thin, fibrous, and devoid of epithelial covering. The amnion is in contact with the chorion and at many points blended with it. Within the amniotic cavity there is a mass of granular magma which could be seen through the thin walls of the chorion before it was opened. The umbilical cord is enlarged in its middle and very thin at its attachment to the chorion, which also is atrophic at that point. Sections show that the center of the cord is fibrous, and that the enlargement is due to the extreme mucoid degeneration. Near its attachment to the body the cord is infiltrated with round cells, and the intestine within the coelom of the cord is irregular and gorged with them; the lumen of the intestine is destroyed entirely. The embryo is embedded in the granular magma and approximately normal in form. Within, however, most radical changes have taken place. The blood-vessels and heart are distended enormously with blood and the tissues are gorged with round cells. Liver, heart, intestine, and mesenchyme are undergoing destruction. The precartilage is more sharply defined than in the normal embryo. The spinal cord is dilated, the brain and eye are nearly solid, and the earvesicle is destroyed. The ganglia and nerves are disintegrating. The epidermis is partially lacking, and in the head region the skin is studded with numerous papillomata. The face is adherent to the thorax.

(6) Decidua absent. Early hydatiform degeneration.

No. 320.

(1) E. C. Gibbs, Baltimore, Maryland.

(2) A 70×50×40 mm.; B 18 mm.

(4) The chorion is fleshy and thick, with irregular spots of villi covering its surface. Some of the villi are fibrous, others are swollen, and all are deficient in syncytium. The decidua is fibrous and well filled with leucocytes. The entire chorion is lined by the amnion, which contains no magma. The umbilical cord is thin at its attachment to the chorion, but swollen in its middle. This swelling, upon microscopic examination, proves to be a vesicle filled with a hyaline, stringy mass tinged with carmine. Otherwise the cord is fibrous, with remnants of blood-vessels in its center. These are practically obliterated. The tissues of the embryo are pretty well dissociated, the cord and brain are nearly solid, with occasional irregular spaces representing the central canal. The outlines of the alimentary canal are obscure, and its epithelial lining is nearly lost. The blood-vessels are distended with blood in an irregular fashion. The liver is necrotic and free from blood. The tissues of the body are all dissociated, which condition obscures the muscles and nerves and sharpens the outlines of the cartilages. The epidermis is intact.

(6) Slight infiltration of the decidua; probably early hydatiform degeneration.

No. 325.

(1) E. K. Ballard, Baltimore, Maryland.

(2) Ovum 55×55×35 mm.; B 13 mm. CR.

(3) "Last menstrual period September 15; abortion November 27. Periods regular."

(4) The specimen was clean, well covered with villi, and hardened in formalin. The amnion and coelom are filled with magma réticulé, in which is embedded the

trunk of an embryo attached to the chorion by a thin cord. On the opposite side of the ovum the head is located, also embedded in magma. Over the body of the embryo there is a greenish-colored nodule 4 mm. in diameter, which proves to be the degenerated umbilical vesicle. The legs are poorly formed and stubby.

(5) Sections of the chorion show that the mesoderm of the villi is hyaline, and therein remnants of blood-vessels may be seen; a normal number of round nuclei are scattered through it. The trophoblast also appears to be normal. Between the villi may be seen some mucus containing leucocytes. No decidua is attached to the villi. The cord is thin at its attachment to the chorion, and is slightly enlarged midway between the chorion and the embryo. Here it contains large mesodermal spaces, which at points are infiltrated with round cells. The umbilical vesicle is present only in outline and its lumen is partly filled with débris. However, some beautiful multipolar mesoderm cells may be seen. The epidermis covers the embryo only in part; a shell of granular magma covers the rest of the body. The tissues are greatly dissociated and macerated, which has caused almost complete obliteration of the outlines of the epithelial lining of the alimentary canal. The central nervous system is nearly solid, and the large blood-vessels are gorged with blood. The liver is necrotic. The mesodermal tissues are obscured, with the exception of the cartilages, whose outlines are sharpened.

(6) Hydatiform degeneration. Decidua absent.

Nos. 330 *a*, *b*.

(1) J. Park West, Bellaire, Ohio.

(2) Twins { (*a*) A 60×55×50 mm.; B 12 mm.
(*b*) A 55×50×45 mm.; B 12 mm.

(3) "The woman from whom these twin specimens were obtained is about 25 years of age. Fifteen months ago she gave birth to an 8 months child which lived for 2 days. Her last regular menstrual period took place during the middle of September. The October and November periods were missed. About the middle of December, at her regular time, bleeding began, which continued until January 21, when these two ova were aborted. I am quite positive, but not certain, that the woman has syphilis."

(4) Both ova have smooth surfaces, being composed of thin walls, upon which there are occasional villi.

(5) In both specimens the villi are irregular, fibrous, non-vascular, and embedded in a mass of pus, in which may be found much necrotic syncytium, fibrin, and blood. Many leucocytes are found in the mesoderm of the villi. The chorion and amnion of both specimens are of irregular thickness and well blended with each other. The changes in the two embryos are very similar. In both the epidermis is intact and the dermis thickened. In front of the head, in the region of the deformed mouth, there are peculiar thickenings of the epidermis. Both spinal cords are markedly dissociated. The dissociation of the brains is so extensive that the cerebral vesicles and midbrains are nearly destroyed, and the hind-brains occupy spaces in the centers of the deformed heads. The large vessels and heart are gorged with blood. In 330*b* the wall of the ventricle is well infiltrated, and in 330*a* nearly destroyed by the migrating cells. The outlines of the organs and tissues are very obscure, the whole being more or less filled with round cells. Some of the liver tissue is necrotic.

(6) Decidua necrotic and infiltrated; chorionic changes suggestive of lues.

No. 334.

(1) B. J. Merrill, Stillwater, Minnesota.

(2) A 50×40×30 mm.; B 5 mm.

(3) "Last period 4 weeks before. About 10 days before abortion there was some bleeding, which repeated itself at intervals, and was finally followed by the abortion."

(4) Examination of the mass proves that it is made up mostly of uterine mucous membrane, decidua, and blood, and that it contains a cavity 15 mm. in diameter.

(5) The chorion can still be made out as a very macerated, fibrous band. The amnion is almost completely degenerated, the villi are macerated, the non-vascular stroma clear and wavy, but the epithelium and trophoblast fairly well preserved.

(6) Decidua and mucosa infiltrated; hydatiform degeneration.

No. 336.

(1) J. Park West, Bellaire, Ohio.

(2) A 35×25×15 mm.; B 8 mm.

(4) The ovum is smooth, one end being covered with well-developed villi.

(5) Their mesoderm is hyaline, with scattered nuclei containing some remains of blood-vessels. The main wall of the chorion is fibrous and infiltrated with blood-cells from the embryo. Within, there is a cavity (15×10 mm.) filled with granular magma and containing the umbilical vesicle and the embryo, which is closely encircled by the amnion. The embryo is somewhat distorted, with large blood-vessels filled with blood and tissues infiltrated with round cells. What is especially noteworthy is that the circulation within the chorion has been cut off, the cord being atrophic and infiltrated. The large omphalomesenteric vessels are filled with blood and spread over the yolk-sac, the walls of which are necrotic.

(6) Decidua absent. Hydatiform degeneration.

No. 339.

(1) C. S. Minot, Boston, Massachusetts.

(2) A 50×30×30 mm.; B 16 mm.

(4) The chorion is thin, covered by only a few villi and hemorrhagic at one end.

(5) In structure it is somewhat hyaline at points and at others somewhat fibrous. The villi are largely non-vascular, fibrous, and hyaline. The cord is thickened and fibrous. The walls of its blood-vessels are dissociated, and the blood from them is infiltrating the surrounding tissues. The embryo is somewhat distorted, but normal in form. Within, the tissues are dissociated and macerated. The large blood-vessels are distended with blood, and within the liver and heart the blood-cells from them have extended into the surrounding tissues.

(6) Decidua absent.

Nos. 341 *a*, *b*.

(1) C. S. Minot, Boston, Massachusetts.

(2) A 70×60×50 mm.; B 14 mm.

(4) The ovum is pear-shaped and smooth, being covered with some decidua and at points with hemorrhagic masses. Its tissue does not stain well, but some of the villi appear to be fibrous and others edematous. There is not much syncytium present. Possibly there are masses of leucocytes in the decidua. Within the ovum are two stumpy embryos, both of which have dilated cords which come to a point where they are attached to the chorion.

(5) These dilatations show the usual mucoid changes with cavity formation. The embryos are dissociated and macerated. The large blood-vessels are filled with blood, and it appears as if the migrating cells had infiltrated much of the tissues.

(6) Decidua too necrotic; probably some hydatiform degeneration.

No. 343.

(1) C. S. Minot, Boston, Massachusetts.

(2) A 55×45×35 mm.; B 11 mm.

(4) The chorion is mostly smooth and of unequal thickness. The decidua is necrotic and infiltrated with numerous leucocytes. Below it there are distorted villi with fibrous, non-vascular mesoderm. The amnion is in contact with the chorion. Between the villi there is a tringy mucoid masa rich in leucocytes. The stumpy

embryo is attached by means of a fibrous umbilical cord. Its tissues are dissociated and infiltrated with round cells. The blood-vessels and heart are greatly distended with blood. The liver is necrotic. In front of the head the tissue is broken away, leaving a pocket which contained the forebrain, and above this the brain protrudes. The cord and fourth ventricle are distended and dissociated. The epidermis is intact.

(6) Marked infiltration of the decidua; insufficient chorion.

No. 344.

(1) C. S. Minot, Boston, Massachusetts.

(2) A 45×45×45 mm.; B 16 mm.

(5) The wall of the chorion is very thin and non-vascular, with a few fibrous villi scattered over it. The long, thin umbilical cord is fibrous and shows remnants of blood-vessels. The embryo has a rounded head and stumpy legs. Its tissues are dissociated, the brain being distended and macerated as well. The medulla has expanded towards the mouth. Heart and blood-vessels are distended. In many places the walls are destroyed and the blood-cells extend into the surrounding tissue. This condition is very marked in the liver. The legs are filled with an even mass of round cells, *i. e.*, the tissues are dissociated. Some of the epidermis has fallen off.

(6) Decidua absent. Chorion suggestive of lues.

No. 346.

(1) C. S. Minot, Boston, Massachusetts.

(2) B 13 mm.

(4) A piece of hemorrhagic chorion, which may have been 50 mm. in diameter, is attached to the embryo.

(5) Its tissues are macerated, but preserved well enough to show that there is mucus and pus between some of the villi. The latter are matted, very degenerate, non-vascular, and fibrous. The chorion has undergone hyaline degeneration and contains remnants of blood-vessels only. The decidua is markedly infiltrated. The umbilical vesicle is filled with a necrotic mass. The embryo is dissociated and macerated. The central nervous system is dilated and the heart is distended with blood, some of which infiltrates the surrounding tissues.

(6) Marked infiltration of the decidua.

No. 348.

(1) R. M. Pearce, Albany, New York.

(2) A 50×30×25 mm.; B 12 mm.

(4) The specimen is smooth, being covered with numerous small hemorrhagic spots and irregular masses of small villi.

(5) Sections show that the decidua is infiltrated with leucocytes, with a consequent fibrous degeneration of the villi of the chorion. Some of the villi, as well as the very degenerate portions of the wall of the chorion, have undergone invasion by leucocytes and syncytial cells. The stroma of the villi is largely non-vascular and shows "granular hyperplasia." The epithelium and trophoblast are fairly well preserved. The dissociation of the tissues of the embryo is extreme, the blood from the blood-vessels having passed through their walls to infiltrate the surrounding tissues. This is especially well marked in the heart and liver. The nervous system is pretty well broken up and the epidermis has fallen off.

(6) Marked infiltration of the decidua and changes suggestive of lues.

No. 357.

(1) E. J. Russell, Baltimore, Maryland.

(2) A 90×40×40 mm.; B 17 mm.

(3) "The specimen came from an unmarried woman 22 years old. Her menstruation was irregular, sometimes every two weeks, sometimes every six weeks. The last period occurred about the middle of January. On March 29 she began to bleed and aborted April 19. Apparently her uterus is normal."

(4) The unruptured specimen was inclosed in a layer of decidua and covered with villi of unequal size, some being very large. Within it was a stumpy embryo without a neck and with atrophic leg-buds. The cord was transparent and partly filled with granules, indicating that the embryo had been dead for some time before the abortion.

(5) The main wall of the chorion is very thin, being composed in many places of epithelial cells only. The mesoderm of the villi is unusually fibrous and contains no blood-vessels. The very large villi are degenerated, often hollow, and do not stain. The syncytium is very deficient in quantity, but at points invades the mesoderm. Over the villi there is a mass of fibrin and disintegrated blood. Leucocytes are not numerous, even in the decidua, which appears to be normal. The tissues of the embryo, which are dissociated and macerated, do not stain well. The sharp boundaries are lacking, showing that adjacent tissues have begun to coalesce. In fact, the whole head, down to the thorax, seems to have been converted into a bag in which fragments of cartilage and nerve tissue may be seen. The front of the head is adherent to the thorax immediately over the heart. The contour of the cartilages, liver, heart, and adrenals can be made out, but that of the blood-vessels is obscure. According to the menstrual history, this embryo was in the seventh week when bleeding began, which was followed by the abortion three weeks later. However, the degree of development of the cartilages and other structures places the embryo in the sixth week. The continued bleeding may have been the primary difficulty, being followed by death and degeneration of the embryo.

(6) Decidua is very degenerate and possibly infiltrated; hydatiform degeneration of the chorion.

No. 364.

(1) B. J. Merrill, Stillwater, Minnesota.

(2) A 90×50×40 mm.; B 16 mm.

(3) "Last menstruation April 7, abortion July 5. The first flow and pain appeared on the night of July 4. The woman has been married four years, but this was her first conception. Both she and her husband are very anxious to have a child, so the miscarriage could not have been aided. There was no incident, accident or otherwise, to give cause for the abortion. The woman is unusually healthy and the miscarriage took place without chill or rise of temperature. She had been operated upon several years ago for appendicitis. She has not been altogether regular with her menstrual periods, and there is some pain connected with them. She had been treated, some time before I saw her, for vaginal discharge; there may have been edometritis. Prior to her conception I gave her some treatment for leucorrhoeal discharge, and also made some slight dilatation of the cervix. She had a long cervical os with a narrow canal. There was some vaginitis and, as I remember, some endocervicitis rather than endometritis, none of them very marked. Probably there was enough uterine trouble to cause the delayed development of the embryo and the abortion. The husband is ordinarily healthy, but about a year ago, his wife states, he had some trouble with his genital apparatus. He has night emissions and I judge took medicine for them. As far as I can ascertain from her outline, he has not had venereal disease. If so, he did not contaminate her. If he has, as she states, night emissions, perhaps the virility of his semen is below par."

(4) The ovum is covered with a few ragged villi, over which there is some decidua more or less detached.

(5) Sections of the chorion show that the villi are far more numerous than was suspected from the simple unaided eye inspection. The main wall of the chorion is thin, atrophic and lined with the amnion, which is fully detached where it connects with the umbilical cord. However, it must have been attached at one time, as remnants of blood-vessels from the embryo are seen in the villi of the chorion. The mesoderm of the villi is very

fibrous and the villi are matted together by a slimy mass rich in blood and leucocytes with fragmented nuclei. The syncytium is well developed and extends into the blood and slime. The decidua over the chorion has large sinuses within its walls, is quite hemorrhagic, and at points has large islands of lueocytes, usually situated along the course of the blood-vessels. The embryo has hare-lip and displaced ears. The viscera protrude in the front and there is spina bifida. The large blood-vessels and heart are still filled with blood, and there is quite a general infiltration of the tissues with round cells. The vessels of the embryo end in the cord and do not reach to the chorion. In general, there is mainly a destruction of the tissues possibly due to the irregular growth of the embryo. The central nervous system has been converted in great part into a mass of connective tissue, with remnants of the cord below and a rudimentary brain above, which forms a shield upon the protruding mass. A portion of this shield has grown into the connective tissue below, forming a gland-like structure. The clavicle, mandible, and maxilla have begun to ossify, and some of the muscles are fairly developed.

(6) Slight infiltration of the decidua.

No. 365.

(1) A. G. Pohlman, Bloomington, Indiana.

(2) B 14 mm.

(4) This embryo, with spina bifida, iniencephaly, and anencephaly, but the extremities of which are normal in form, has a straight body and is attached to the end of a very large umbilical cord.

(5) Sections show that the spinal cord is absent, but there is a solid brain which is more or less infiltrated with round cells at its periphery. The same is the case with the eyes. The mouth is closed by the tongue, which has become adherent to the lips. The nodules in front of the body are composed of necrotic epithelial cells. Some of the other tissues of the body also are necrotic, but most of them are infiltrated with round cells. Those of the head are quite fibrous in character. The walls of the alimentary canal and the lungs are also pretty well filled with irregular patches of round cells. Especially well marked is this change in the region of tendons and perichondrium, showing that there is an irregular growth of the mesodermal tissues. The clavicle, maxilla, and mandible are well ossified, which should not be the case in so small an embryo.

No. 375.

(1) Simon H. Gage, New York.

(2) B 13 mm.

(4) A piece of chorion, accompanied by the mutilated embryo. Both appeared quite normal.

(5) Sections of the chorion, however, show that the mesoderm of the villi is non-vascular, somewhat degenerate, and very fibrous. That of its main wall also is non-vascular, edematous, and macerated. The syncytium seems to be deficient in quantity and the epithelium degenerate. The mesenchyme of the cord is very degenerate and the vessels have disappeared completely. Sections of the embryo indicate that it is nearly normal, with some dissociation of tissues. The larger blood-vessels are gorged with blood, and some of the tissues, especially those in front of the head, are infiltrated with round cells. The central nervous system is swollen and dissociated, as is so frequently the case in many of the other embryos.

(6) Decidua absent. Chorionic changes suggestive of lues.

No. 401.

(1) Dr. Hay (Bardeen collection).

(2) B 5.5 mm.

(5) Much of the chorion and many of the villi and the syncytium are necrotic and infiltrated with many leucocytes. The umbilical vesicle is necrotic and filled with a mass of broken-down cells. The tissues of the embryo are dissociated, macerated, and infiltrated with round cells.

(6) No decidua, but evidences of infection are present.

No. 402.

(1) Edmund J. O'Shaugnessy, New Canaan, Connecticut.

(2) A 40×25×20 mm.; B 4 mm.

(3) "The woman, aged 30, is strong and healthy. She was married 3½ years before she became pregnant, and menstruated regularly. After the birth of the first child she had a slight discharge, which was diagnosed by her attending physician as an ulcerated cervix, and which he treated by local applications. Since the birth of the second child patient has had some discharge, but again became pregnant, this time aborting at 6 or 8 weeks. She has never done anything to prevent pregnancy, and both she and her husband are anxious for a large family." At the time the specimen was sent the patient was menstruating and still had a chronic discharge.

(4) The villi of the ovum are well developed and regularly distributed over its surface. Within, the cœlom is well filled with reticular magma. The embryo is club-shaped, its head being much too large for the body. Umbilical vesicle normal in size and shape, and the heart is well outlined. Extremities beginning to develop. The embryo is lying free within the cœlom and is attached but slightly to the amnion, some distance from the latter's attachment to the chorion.

(5) Sections of the chorion show that the villi are matted together with a fibrinous mass extending more or less between them. Within this mass there is quite an active trophoblast, which at numerous points forms large nodules, many of which have necrotic centers. The chorionic membrane appears to be normal in texture, and from it arise great masses of reticular magma which are brought out well by the Van Gieson method of staining. The mesenchyme of the villi is partly fibrous and partly mucoid, and many villi contain numerous Hofbauer cells. The nervous system of the embryo is completely dissociated, the cells forming a uniform layer throughout the canal. It is impossible to outline the different portions of the brain. The spinal cord has a lumen at its lower end. The vascular system is also destroyed almost completely, only a portion of the heart being recognizable. The cœlom is more or less filled with round cells. No myotomes can be outlined. Small remnants of the pharynx and the cœlom are present at different points.

(6) Marked infiltration of the decidua and hydatiform degeneration.

No. 450.

(1) John Girdwood, Baltimore, Maryland.

(2) A 60×45×45 mm.; B 18 mm.

(3) Patient had missed two periods. She is the mother of several healthy children, and has also had several previous miscarriages.

(4) The unopened specimen came with its decidua partly stripped off. The portion of the chorion which is exposed is covered with very long and extremely delicate villi, with an unusually thin chorionic membrane. The embryo's head is nearly detached, and is atrophic, with rounded atrophic forehead. The body of the embryo is normal in shape. The cord is sharply dilated in its middle and very small and pointed at its attachment to the chorion.

(5) The decidua appears to be normal in form and thickness, but shows a very extensive inflammatory reaction. At points there is such an accumulation of leucocytes as to form small abscesses. The villi are small and fibrous, with practically no trophoblast attached to them. The main wall of the chorion also is thin and fibrous. Serial sections through the umbilical vesicle indicate that it is necrotic and undergoing disintegration on one side, while on the other its wall is fibrous and seems to be growing quite actively, tufts appearing upon

its surface like small warts. The tissues of the embryo show marked dissociation, the shape, border of the cartilages, and practically all of the organs being obliterated. These changes extend to the extremities. The specimen may be viewed as typical of general dissociation of the tissues in an embryo of this size. It appears as though the tissues grew independently for some time after the strangulation of the embryo.

(6) Slight infiltration of the decidua.

No. 465.

(1) H. W. McComas, Oakland, Maryland.

(2) A 70×70×50 mm.; B 13 mm.

(4) The ovum is pear-shaped, with a pedicle 40 mm. long, representing, no doubt, the portion that was protruding from the uterus. Parts of the decidua are hanging to the chorion. Other portions of the specimen are covered by very large villi, while the greater part of it appears to be ulcerated. The amniotic cavity is very large, filling almost the entire specimen. It contains a clear fluid and a pathological embryo the head of which is broken off from the body. The extremities are stunted and the cord is 20 mm. long. The united portions of the embryo measure together 13 mm.

(5) Sections show that the villi are matted together and covered with decidua. The mass between the villi and the decidua consist of fibrin, mucus, blood, irregular masses of trophoblast, and pus. The chorionic wall appears to be normal in structure. Many of the villi are fibrous and the trophoblast is scanty. The embryo is dissociated and macerated. The lower part of the embryo and the tips of the extremities are infiltrated with round cells, making it appear like sections of the lymphatic glands. The structures of the head are very much macerated and appear to have succumbed before the lower end of the embryo. The cord is degenerated, jelly-like in consistency, and contains a cavity.

(6) Slight infiltration of the decidua and hydatiform degeneration.

No. 499.

(1) H. H. Arthur, Baltimore, Maryland.

(2) A 45×45×40 mm.; B 17 mm.

(3) "The specimen is from a frail girl, weight about 110 pounds. Gave birth several years ago to a premature child at 7 months. Child now living and in robust health. The last pregnancy, about 6 months ago, terminated in abortion at about 8 weeks. Could get no information as to its being induced, so presume it was spontaneous. The specimen was delivered to me, and, besides considerable clots, was partially surrounded by a sac containing intact embryo. In the absence of any evidence to the contrary, from an obstetric standpoint I consider it to be a case of habitual tendency to abortion, as there was no history of traumatism or interference in either instance."

(4) The ovum is composed of a thin white membrane which is covered quite evenly with delicate long villi, measuring on an average about 17 mm. long. Attached within is a much deformed embryo, with kinked arms and legs, protruding abdominal wall, very thin umbilical cord, and complete spina bifida. There is also an exencephaly.

(5) Sections of the chorion show that its walls are somewhat fibrous, thick, and rarefied. The non-vascular stroma of the villi is very degenerate and fenestrated. There is very little trophoblast present. It appears as though the chorion had macerated before we received it. Sections through the umbilical cord show a marked dissociation of tissue, and the intestines, which normally protrude into it, seem to have dissociated completely. The same is true of the walls of the large blood-vessels. These are filled with blood, which, not being circumscribed, penetrates into the surrounding tissues. Sections through the embryo, which were much too thin, show that, with the exception of the liver, the tissues are dissociated, the processes being most marked in the intestines, along the aorta, and in front of the head. The dissociation is well marked around the cartilages of the vertebra column. The tissue of the brain is almost entirely destroyed, and in it there is a mixture of nerve-fibers, connective tissue, and blood-vessels. It has undergone almost complete vascularization. The large blood-vessels are gorged. Some of the nerves run almost to the surface of this tissue, which would indicate that the brain had been well formed before it degenerated into this vascular mass. Within the tip of the tail the cord is still covered by the skin of the embryo.

(6) Decidua absent.

No. 510.

(1) H. G. Steele, Keystone, West Virginia.

(2) A 60×45 mm.; B 10 mm.

(4) Scattered over the ovum are long, slender villi which do not branch much, and over the top of these is a large piece of decidua.

(5) Sections were cut from two portions of the chorion. In one the decidua is found to be very vascular, with a great deal of fibrinoid substance on the side adjacent to the villi. Large arms of decidua extend between the villi. It appears as though the decidua had tried to make up for the defective villi by growing towards the chorion. In this region the chorion has undergone extensive mucoid degeneration, with cavity formation. Some of the villi contain many Hofbauer cells and very little trophoblast. Sections from the other side of the chorion show the chorionic membrane to be very thin, with an extensive mucoid degeneration of the villi, some of which are mere shadows, and are outlined by fibrinoid substance which also reaches between them. There are a few masses of necrotic trophoblast, otherwise the spaces between the villi are practically empty. The tissues of the embryo have undergone very extensive dissociation, but the liver, heart, and stomach can still be made out. Most of the myotomes and vertebræ are distinct. The umbilical cord contains numerous large cavities, with plenty of Hofbauer cells scattered through its tisses, as it is undergoing mucoid degeneration. The dissociation of the lower part of the embryo is almost complete, it having been converted into a fairly uniform layer of round cells. The brain and spinal cord seem to be more macerated than dissociated. The brain protrudes through the skin in front, and at the lower part the spinal canal is open. In this region there is quite a tumor covering the spina bifida, which is composed of a necrotic mass of tissue invaded by round cells. Between the tumor and the cord, partly blocking the opening between its lumen and the outside of the body, are several small nodules of transparent tissue which have the appearance of being made up of nerve fibers. In this region, immediately below the epidermis, is a lens-like body. The otic and optic vesicles are obliterated. There is no branchial region, as the face has grown firmly to the body, and at the juncture there are several pronounced papillomata.

(6) Slight infiltration of the decidua and hydatiform degeneration.

No. 512.

(1) W. G. McCallum, New York.

(2) A 30×27×18 mm.; B 10 mm.

(4) The chorion is thin and covered with irregularly grouped villi. On one side a tuft of villi appears to be normal in size and branching, but elsewhere they are scattered and atrophic. The chorion is lined entirely by the amnion, the two being very closely attached. The stunted embryo is attached to the chorion by means of a short, thin umbilical cord. The head is atrophic and transparent, being partly broken from the body. It appears as though the embryo had been broken for a considerable time before the abortion.

(5) Sections through the chorion at the point of attachment show that the cord is attached directly to the amnion, which is only in apposition with the chorionic wall. The villi are thin, with a clear, non-vascular stroma, not rich

in nuclei and practically devoid of trophoblast. The tissues of the embryo have undergone extensive dissociation and maceration. The brain is nearly solid, as are the eye-vesicles, the lens forming small, solid bodies immediately below the skin. The heart, as well as the structure of the lower part of the body and the lumen of the spinal cord, appears to be normal in form. The dissociation is most pronounced in the stunted extremities.

(6) Decidua absent. Early hydatiform degeneration.

No. 516.

(1) J. M. Hundley, Baltimore, Maryland.

(2) A 65×50×40 mm.; B 15 mm.

(3) "The patient missed her menstrual period February 15, 1911, had a slight show of blood March 15, and aborted April 15.

(4) The chorion is thin and transparent and covered with long, ragged atrophic villi which accumulate in tufts on one side. Attached to the villi are numerous opaque bodies about a millimeter in diameter, which no doubt represent clumps of necrotic trophoblast. The amniotic cavity lines the entire chorion and contains a transparent fluid with a small granular deposit.

(5) Sections of the chorion do not include the amnion. The chorionic wall is thin, fibrous, and degenerate. The villi are non-vascular, fibrous, and hyaline, with a fenestrated stroma in some. Small clumps of trophoblast and small mounds of fibrin bind a few of the tips together. In this region there are buds of syncytium, some of which have undergone nuclear fragmentation. Sections of the amnion which include the attachment of the cord show that it is thick and fibrous. The tissues of the embryo are dissociated and macerated, the dissociation at the tips of the extremities being typical and pronounced. The brain and cord are badly macerated and folded, the former protruding from the front of the head through what appears to be an artificial rupture. The face is atrophic and round, and there is no well-formed neck. The veins are gorged with blood, the cells of which radiate more or less into the surrounding tissues. The umbilical cord contains numerous large spaces quite characteristic of specimens of this kind.

(6) Decidua absent. Possibly early hydatiform degeneration.

No. 521*e*.

(1) Francis Carpenter, Baltimore, Maryland.

(2) A 40×30 mm.; B 15 mm.

(4) The specimen is badly macerated and the embryo broken. It has a round head, atrophic legs, and a very atrophic umbilical cord.

(5) The tissues of the embryo are dissociated and extremely macerated. The chorionic wall is thin and fibrous, and the non-vascular villi are more or less hyaline and fenestrated. Very little trophoblast is present.

No. 521*f*.

(1) Francis Carpenter, Baltimore, Maryland.

(2) A 50×70 mm.; B 22 mm.

(4) The embryo shows a thick ridge along the dorsal midline of the trunk. The head is smaller than usual.

(5) Sections through the chorion show that the tissues are macerated and necrotic in places, nor do they stain well. However, this much can be made out: the chorionic wall at the attachment of the cord is fibrous and the villi have undergone fibrous, mucoid, and hyaline degeneration. They are matted together with a mass of fibrin, mucus, and necrotic trophoblast, and are capped by a layer of degenerated decidua. A thick layer of fibrin and degenerate blood covers the maternal surface of the decidua. Sections of the embryo show extensive maceration, as well as dissociation of the tissues. The spinal cord is disintegrated, the fragments being mixed up throughout the main cavity of the spinal canal. The distended macerated cord accounts for the ridge seen in the dorsal midline before the embryo was cut.

No. 566.

(1) A. F. Fuchs, Loyal, Wisconsin.

(2) A 24×19×19 mm.; B 6.5 mm.

(2) Patient gave birth to a healthy child 5 months before. This specimen came away spontaneously in what appeared to be the first menstruation after pregnancy.

(4) A beautiful white specimen, completely covered with villi, somewhat more dense on one side than the other. The villi are about 2 mm. long and divide once or twice. The cœlom is filled completely with granular and reticular magma. The amnion is filled partly with a clear fluid and contains a nice white embryo, 6.5 mm. in length (CR), slightly bent towards the right immediately below the arms, and apparently normal. The internal surface of the amnion is smooth, the cœlom large, and filled with dense reticular magma. The umbilical vesicle is spherical, 2.5 mm. in diameter.

(5) The chorionic villi seem to be capped with a layer of blood which filters down between them. They are macerated, almost wholly non-vascular, and the stroma has undergone mucoid degeneration. The trophoblast is abundant and well preserved. The chorionic membrane also is degenerate and macerated. The embryo and umbilical vesicle show extensive dissociation of the tissues, but the myotomes and peripheral nerves, as well as other organs of the body, can still be made out. The blood-vessels are gorged with blood and the brain and spinal cord are macerated. The tissues of the wall of the heart appear quite normal.

(6) Decidua absent, but the coagulum is infiltrated; early hydatiform degeneration.

No. 595.

(1) Caleb Athey, Baltimore, Maryland.

(2) A 33×27×25 mm.; B 9 mm.

(4) The entire specimen is club-shaped, with an ovum at the larger end. The latter is vesicular and covered entirely with villi which branch several times. Upon opening, it was found to be lined with a smooth membrane. The embryo is nearly normal in form, but injured.

(5) The thin chorion appears to be normal in structure and surrounded by a layer of matted villi intermingled with blood and covered with decidua, showing a considerable degree of inflammatory change. The villi are non-vascular and have undergone fibrous degeneration. The trophoblast is scanty and disintegrating, but certain of the villi and part of the chorionic wall contain blood-vessels. The embryo is greatly dissociated and somewhat macerated, and the blood-vessels and heart gorged with blood. The central nervous system is folded, indicating maceration, and a macerated and dissociated brain fills the entire cavity of the head. The front end of the latter is atrophied, and what remains is growing down, to later become attached to the thorax. Such organs as can be outlined show a marked dissociation of tissues.

(6) Marked infiltration of the decidua.

No. 601*c*.

(1) Charles K. Winne, Jr., Albany, New York.

(2) A 44×41×20 mm.; B 10 mm.

(3) Patient is 39 years old; married 7 years; two children, 3½ years and 21 months respectively. First two pregnancies miscarried, at 6 and 3 months, respectively; cause unknown. Last menstruation April 20. Two days before the physician saw her she had been working very hard, packing and closing her house in Washington. Heat intense. She came to New York June 27, and from there to Albany on the night boat, arriving there next morning. While on the boat she was nauseated and vomited, and had slight vaginal bleeding, which continued. Despite appropriate treatment, the threatened miscarriage proceeded to full completion a few hours later, early in the morning of June 28. This history can be relied upon, as both the patient and her husband were anxious for the child and distressed at the outcome of the pregnancy.

(4) The vesicular ovum, which is covered with long, ragged villi, is filled with clear fluid. The walls are transparent and contain a broken embryo, probably pathological, measuring approximately 10 mm. The entire embryo, with its attachment to the chorion, was cut into serial sections.

(5) The chorionic membrane is thin and fibrous, and the villi consist of long, delicate fibrous strands with practically no vessels or trophoblast, except occasional small nodules which appear to have undergone degeneration. There are a few remnants of blood-vessels in the villi, showing that at one time they must have had a circulation. The umbilical cord also is thin and fibrous, with degenerating vessels and cavity formation. The amnion is partly separated from the non-vascular chorion. The tissues of the embryo are somewhat dissociated and slightly macerated. The blood-vessels are well distended with blood, and there is a large extravasation in the peritoneal cavity. Sections which pass through the leg-bud indicate that it is slightly stunted in its growth.

(6) Decidua absent.

No. 604.

(1) J. M. Jackson, Pittsburgh, Pennsylvania.

(2) A 70×50×50 mm.; B 17 mm.

(4) This vesicular specimen is constricted in the middle and its surface is not uniform, being covered partly with fibrin clots and partly with decidua and some ragged villi. The walls are 3 or 4 mm. in thickness, and the interior is filled with a jelly-like magma of uniform consistency. On one side, lying free within the magma, is an embryo with an atrophic head, arms, and legs. The head is not bent as it should be at this stage, but is erect.

(5) Sections show a fibrous chorionic membrane surrounded by a few very degenerate villi, much blood, and fibrinous substance. This layer is capped by an inflamed decidua. The trophoblast is thickened, and it, as well as the mesenchyme of the villi, are infiltrated with round cells. The embryo shows considerable maceration, and the dissociation of the tissues is so great that only the cartilages can be made out with certainty. The liver is necrotic, and the walls and cavities of the heart are practically obliterated, the whole organ being converted into a mass of round cells. The same is true of the neck, and the entire skull and spinal canal are filled with the dissociated and macerated brain and spinal cord. In the latter the cells of the floor-plate still hang together, showing the characteristic structure of this region as seen in normal embryos.

(6) Marked infiltration of the decidua.

No. 635c.

(1) A. C. Pole, Baltimore, Maryland.

(2) B 18 mm.

(5) Sections of the embryo show that all the tissues are macerated. The outline of some of the blood-vessels is not sharp, some of the cells have migrated into the adjacent tissues, and the periphery of the cartilages shows dissociation. Hence it is probable that this embryo died some time before the abortion.

(6) Decidua and chorion absent.

No. 651a.

(1) G. L. McCormick, Sparrows Point, Maryland.

(2) A 70×45×45 mm.; B 27 mm.

(4) The embryo, which is normal in form, with the possible exception of the lower part of the body, came within the amniotic sac, which measures 70×45×45 mm. No chorion is present. The lower part of the spinal canal is opened, the opening being 1 mm. in width and 4 mm. in length. Both legs appear deformed, the left less so than the right, the latter having a marked bend at the knee.

(5) Sections through the amnion show it to be fibrous and macerated. Where the vessels pass through it there is some dissociation. The embryo was cut into serial sections which show that the tissues are greatly macerated. The brain and what is left of the spinal cord are practically solid, the latter filling the spinal canal incompletely in the thoracic region. The skin forms a groove in the lower lumbar region in which the cord is really absent. The skin is fairly intact, but the tissues are markedly dissociated; that is, the boundaries of the organs and cartilages are obliterated by an irregular wandering of the cells. This is especially marked at the beginning of the umbilical cord.

(6) Decidua and chorion absent.

No. 651c.

(1) G. C. McCormick, Sparrows Point, Maryland.

(2) B 17 mm.

(4) A deformed embryo with an atrophic head and injured cord, rounded in form. The arms and legs appear atrophic.

(5) The tissues are dissociated, macerated and largely necrotic. The central nervous system is solid.

(6) Decidua and chorion absent.

No. 653.

(1) Ira L. Fetterhoff, Baltimore, Maryland.

(2) A 80×50×35 mm. B 11 mm.

(3) Patient is a young woman who has been married about 2 years. First pregnancy. Apparently healthy, and in this case had gone the normal course of a woman 4 months pregnant. Physician was called to attend her for bleeding, without pain; an hour later he was recalled to attend her in severe pain, when she passed this specimen.

(4) The fresh specimen was brought to the laboratory and fixed in 10 per cent formalin. Care was taken not to injure the embryo, and on opening the chorion a rudimentary body, uninjured, and markedly deformed, was found. The ovum is covered with a few irregular, ragged villi and scraps of decidua. It contains a large cavity and an embryo 11 mm. long.

(5) Sections through the chorion show it to be composed of an irregular mass of blood, decidua, fibrinoid substance, degenerated villi, and a curious combination of chorion and amnion, forming in several places processes which extend into the amniotic cavity. There is only a slight amount of inflammatory reaction on the outside of the specimen. A considerable amount of nuclear dust is present. The embryo is markedly dissociated, but the organs can be outlined within it. The cartilages are fairly sharp, but dissociated. The liver is the only organ retaining any of its normal structure. The extremities are rounded off and dissociated, but there is no central nervous system, and it is impossible to find any canal for it. The vertebræ and ribs can be outlined, and in this region the tissues are not broken. The heart is almost completely dissociated and protrudes through an opening in the thorax.

No. 675.

(1) John Woodman, New York City.

(2) A 50×30×25 mm.; B 10 mm.

(3) Patient has had several previous miscarriages. Hemorrhage began on February 10 and was profuse. There was another hemorrhage a month later, which became very severe at the time of the abortion, April 14.

(4) The ovum measures 50×30×25 mm. and is covered with a few atrophic villi. On opening, it was found to contain a very large amniotic cavity 30 mm. in length. The embryo (10 mm. GL) is opaque and its extremities are atrophic. The chorionic membrane is fibrous and separated from the decidua by considerable fibrin. The decidua shows considerable inflammatory reaction. The space between these two structures is filled with degenerate, fibrous villi, a few buds of syncytium, plaques of nuclear dust, and a great deal of fibrin.

(5) The tissues of the embryo are well dissociated. The heart is represented by a large mass of cells, its walls being practically destroyed. The liver and intestines still are sharply defined. The brain is almost completely dissociated and forms an irregular mass which fills the entire pointed front of the head. The form of the brain is abnormal, and the midbrain protrudes as a solid mass behind. Between it and the medulla there is a curious cartilaginous body which encroaches upon the hindbrain. The lower part of the spinal cord is greatly enlarged, and the cells have encroached upon and destroyed the vertebræ.

(6) Slight infiltration of the decidua; probably luetic.

No. 681.

(1) George H. Hocking, Govans, Maryland.

(2) A 45×45×45 mm.; B 20 mm.

(3) Patient is a Bavarian, 42 years old, who has had 10 children and 2 abortions. Last period January 20 to 25; abortion April 25. No evidence of uterine disease. Interference suspected in this as well as in the previous abortion (No. 621, group 5).

(4) The specimen was found to consist of two parts, one a portion of the decidua and blood clots, the other a pathological ovum with a hemorrhagic wall. The ovum measures about 45 mm. in diameter and contains a cavity 30 mm. in diameter, in which there is an atrophic embryo 20 mm. GL. The cord is short and transparent, and attached to the embryo.

(5) The chorionic wall is fibrous, and the umbilical cord, within which is a large cavity, is undergoing mucoid degeneration. The villi are fibrous and mucoid, without any active trophoblast, and are well embedded in blood-clot. The decidua also looks degenerate and even necrotic in places. The tissues of the embryo are dissociated and macerated, most of the blood-vessels being well filled with blood. The dissociation is best shown in the hands and feet. The brain and spinal cord are characteristic of this type of macerated embryo.

(6) Decidua not infiltrated.

No. 699.

(1) Emil King, Fulda, Minnesota.

(2) B 13 mm.

(3) "Patient aged 24 years. Previous history negative; always very good health. Married 8 months. Menses regular until 10 weeks ago, then ceased; 4 weeks ago felt unwell, though not in bed. Traveled some distance 2 weeks before abortion, June 2. As the patient was in agonizing pain a hypodermic of morphine and atropine was given and the vagina packed with gauze. When the pain ceased the packing was removed and the fetus and membranes were found free in the gauze. The sac had been ruptured, there being a small tear in it. The chorion seemed poorly developed, being very dark in color and thin." It was the physician's opinion that the fetus had been dead 4 weeks.

(4) The specimen consists of a piece of chorionic wall about 30 mm., one side of which is covered with degenerate villi in a layer of uniform thickness. Within is a pathological embryo, CR 13 mm., attached to the chorion by means of a short cord. The front of the head is atrophic. The right arm and lower part of the body seem to be normal, while the left arm and legs are stubby.

(5) The chorionic wall is thick and non-vascular. The villi are necrotic and encircled with an inflamed decidua. There is considerable blood between them, and most of the nuclei of the trophoblast have been converted into nuclear dust. The embryo is dissociated and the head end is filled entirely with the brain. The heart, which protrudes on the chest, is represented by a small mass of blood. The liver is swollen. The two poles of the body are rounded off, and in the legs the dissociation is quite complete.

(6) Slight infiltration of the decidua; probably luetic.

No. 705.

(1) C. E. Caswell, Wichita, Kansas.

(2) B 18 mm.

(3) Patient aged 39 years; married at 19. Two pregnancies—normal delivery about 20 years ago, and this abortion, June 8. Last normal period March 12 to 16. Scanty flow April 12 and 13; also a show on May 10. Examination on May 12 showed the uterus very slightly enlarged (woman is stout) and cervix blue. Uterus about size and depth of a 10-weeks' pregnancy. At that time pus in urine; no casts.

(4) Head and probably legs of embryo are atrophic.

(5) Most of the structures appear to be normal, but the central nervous system has undergone quite extensive dissociation. The medulla and forebrain encroach upon the pharynx. The large blood-vessels and heart are filled with blood. The tissues, especially those of the tips of the extremities, are dissociated.

(6) Decidua and chorion absent.

No. 711.

(1) G. W. Cox, Hartford, Connecticut.

(2) A 35×25× 25 mm.; B 12 mm.

(3) "Patient aged 31 years; married 8 years. Mother of three children, two living. Last child born 3 years ago. Periods were regular and about 28 days apart; last one March 31. In April period was missed. On April 25 patient had slight vaginal hemorrhage lasting only a moment. On May 9 severe hemorrhage; patient was packed a few days. May 9 she came to the hospital, bleeding slightly and with some pain. May 21 she passed the specimen, after which she was curetted."

(4) Part of the chorion was cut away. What remains measures 35×25 mm. The amnion, which measures about 20 mm. in diameter, is much thickened, fibrous, and contains an atrophic embryo with a round head and a very short cord.

(5) The wall of the specimen consists of a thick and infiltrated chorionic membrane encircled by fibrous villi which are covered with curious spherules of trophoblast undergoing fibrinoid degeneration. Some of these have the appearance of sections of cartilage. There are also small nests of nuclear dust and considerable infiltration with leucocytes. The embryo is markedly dissociated, the tips of the extremities being mostly disintegrated. Round cells invade the cartilages. The outline of the viscera appears to be normal, but the brain is greatly dissociated and occupies almost the entire head. The tissue in front of the brain is infiltrated with round cells and not sharply separated from the dissociated brain.

(6) Intense infiltration of the decidua with abscess formation, probably luetic.

No. 715.

(1) M. Warren, Roosevelt Hospital, New York.

(2) A 55×25×25 mm.; B 10 mm.

(3) Patient aged 40 years; married 2½ years. First pregnancy. Last menstrual period March 28 to April 1, abortion June 22 following. No infection of uterus, but multiple fibroid tumors, varying in size from a lime to a small orange. No history of previous pelvic trouble. Patient belongs to a healthy, fertile family.

(4) Specimen consists of a smooth vesicular mole 55×25×25 mm. The cavity, which extends throughout, is lined by the amnion and contains a macerated and distorted embryo about 10 mm. long. The cord is very short and thick, and the arms and legs, as well as the head, are atrophic.

(5) The wall of the chorion is relatively thin and is composed of a macerated, fibrous amnion and chorionic membrane. It is covered with scattered necrotic villi stuck together with blood and decidua. The embryo is markedly dissociated.

(6) Decidua very necrotic.

No. 723*b*[1].

(1) Lawrence L. Iseman, Chicago, Illinois.
(2) A 40×25×25 mm.; B 12 mm.
(4) The ovum has very thin walls, and attached to one pole are a few atrophic villi. It contains an embryo 12 mm. long. The form of the chorion appears normal.
(5) The mesenchyme of the villi is almost wholly non-vascular, has undergone marked mucoid degeneration and contains some Hofbauer cells. The trophoblast is not well defined, and between the villi there are strands of mucoid substance inclosing many buds of syncytium, some of which are vacuolated. The embryo is macerated and markedly dissociated. The front of the head is atrophic; the large blood-vessels are distended with blood, but their walls are indefinite. The same is true of the heart.
(6) Decidua absent. Hydatiform degeneration.

No. 727.

(1) B. J. Merrill, Stillwater, Minnesota.
(2) A 55×35×33 mm.; B 9 mm. CR.
(3) Patient 36 years old; married 9 years. Three children, born May 9, 1906, March 15, 1908, and August 4, 1910. This is her first abortion. Last menstrual period April 18 to 21, 1913; abortion June 12 following. Patient thinks conception could not have taken place until the last of April or the first of May. Condition of uterus normal. No venereal diseases. Family fertile.
(4) The specimen is a smooth vesicular mole with ragged villi, and measures 55×35×33 mm. The amnion, which measures 30×20 mm., fills nearly the entire chorionic cavity. Hanging within it is a stunted embryo with knob-like arms, legs, and tail. The front of the head is round, and the embryo is well bent upon itself.
(5) Attached to the chorionic membrane are a few fibrous villi with Hofbauer cells and considerable blood and mucoid substance between them. The fibrinoid substance over the villi is thickened with overlying decidua, thin and markedly inflamed. The embryo shows extensive dissociation. The front of the head and extremities are atrophic, and the latter markedly dissociated. There are numerous epithelial warts protruding from the skin. The organs can be fully outlined, and the peripheral nerves are well formed. The heart and blood-vessels are filled with blood.
(6) Marked endometritis and early hydatiform degeneration.

No. 732.

(1) T. W. Harvey, Orange, New Jersey.
(2) A 80×45×45 mm.; B 19 mm.
(3) Patient aged 29 years; married December 1911. Two pregnancies—normal birth September 1912, and this abortion. Last menstrual period April 26 to 28, 1913, and abortion July 23 following. Condition of uterus normal.
(4) The specimen is a pear-shaped mass, measuring 80×45×45 mm., the "pointed" end consisting of placental tissue and blood-clot covering the ovum wall, while the bulbous end consists of the unruptured chorionic sac, which is covered with delicate villi about 10 mm. long, except in the somewhat denuded areas, over which they are scattered irregularly. The wall of the mass is about 2 mm. in thickness and lined throughout with amnion. Upon opening the chorion at the denuded area, the distended amnion was seen as a separate sac, containing a macerated embryo with rounded head and possibly atrophic arm and leg.
(5) The chorionic wall, which appears quite normal in structure, is surrounded by a mass of coagulated blood containing a few fibrous villi. The fibrinoid substance is greatly increased in thickness and is separated by blood from the surrounding decidua, which shows slight general and more decided local infiltration. The embryo is both macerated and dissociated, and the front of the head and abdominal wall are missing. The viscera are embedded in a mass of magma, showing that the abdominal wall was destroyed before the abortion. In the lumbar region the vertebral column is bent forward towards the protruding viscera. The tissues of the extremities and heart are markedly dissociated.
(6) Slight general infiltration of the decidua.

No. 739.

(1) F. B. Bowman, Hamilton, Ontario.
(2) A 70×70×70 mm.; B 17 mm.
(3) The patient was a Polish woman, who was in the hospital only 4 or 5 hours.
(4) The chorion, which measures 70 mm. in diameter, is spherical and covered with patches of irregular villi over one-half of its surface. The interior is taken up by a large amniotic cavity, leaving a wall only 3 mm. thick. Floating free within this cavity was a macerated embryo from which the viscera had fallen out. The embryo, straightened, measures 17 mm. long, and has a round, knob-like head and knob-like extremities.
(5) Sections of the chorion, which include the amnion, show that it is surrounded by fairly well formed villi, from which numerous buds of syncytium extend. The stroma of the villi is degenerate and mainly non-vascular. There also are large clumps of trophoblast which have undergone almost complete fibrinoid degeneration. Surrounding the villi is a layer of fibrinoid substance which in turn is followed by an inflamed decidua. Otherwise the intervillous spaces are filled with a clear fluid. The embryo, which is distorted and macerated, shows marked dissociation in the extremities and vertebral column. The epidermis contains some warts of epithelial cells.
(6) Marked infiltration of the decidua; some hydatiform degeneration.

No. 752.

(1) Thomas J. Simms, Baltimore, Maryland.
(2) A 65×40 mm.; B 21 mm.
(3) Patient aged 31 years; married October 15, 1902. Eight pregnancies; last confinement February 17, 1912. Previous abortion in January 1910. Menstruation regular, lasting 5 to 6 days. Did not know she was pregnant. Abortion August 29, 1913. No infection of uterus; no venereal diseases. Patient belongs to a small family.
(4) Ovum turned inside out, and measures 65×40 mm. Its wall is very thin, with smooth, hemorrhagic protuberances on the inside. An embryo 21 mm. long (CR), with an atrophic head and face, is attached to the chorion by means of a thickened umbilical cord.
(5) The chorionic wall is thickened, somewhat fibrous, and only a few necrotic villi ramify through the blood-clot. Most of the trophoblast also is necrotic. On the outside is a small layer of necrotic decidua which shows a marked inflammatory reaction. The tips of the villi are encircled with old fibrin clots, while fresh hemorrhages are in the intervillous spaces, causing protuberances of the chorionic membrane into the chorionic cavity. The amnion and chorion are closely adherent, and where far apart are bound together by an excessive mass of magma fibrils. The embryo shows considerable dissociation, especially within the extremities. The macerated brain almost entirely fills the head, which is reduced in size.
(6) Intense infiltration of the decidua.

No. 771*b*.

(1) B. T. Terry, Brooklyn, New York.
(2) B 8 mm. long.
(3) Patient aged 29 years; married in June 1910. Three pregnancies—two births, September 1911 and December 1912, and this abortion, September 11, 1913. Last menstrual period July 7 to 12. Conception must have taken place July 15. Condition of uterus apparently normal. No venereal diseases. Family fertile.
(4) The embryo is a curious nodular mass, 8 mm. long, with a round head running to a knob in front, atrophic arms and legs, and a distended umbilical cord.

(5) The embryo is markedly dissociated. The head is small, being filled entirely by the brain-tube, and on the dorsal side there is a curious vesicle under the skin, probably the otic vesicle. The heart can be outlined, but the abdominal organs are almost completely dissociated. The peripheral nerves are seen in the trunk.

No. 776.

(1) William Kirk, Troy, New York.
(2) A 45×30×25 mm.; B 13 mm.
(4) The chorion, which had been opened, measures 45×30×25 mm. The embryo, which is 13 mm. (CR) long, has atrophic arms and head, displaced eyes, and was eviscerated.
(5) The chorion is thickened and hemorrhagic, and is composed of a fibrous membrane and a few long, fibrous, degenerate villi radiating through the blood-clot. The periphery of the clot shows marked inflammatory reaction. At points where the villi protrude into the spaces there is a fairly active trophoblast. The macerated and dissociated brain fills the entire head; the vertebral column is markedly kinked and the extremities are dissociated. The right eye is encircled by a thickened layer of round cells which also invade its lens. The left eye is placed in front and on top of the head over the midbrain, lying directly under the skin. It communicates with the brain through a short optic stalk. The lens contains a cavity into which its posterior layer projects.
(6) Marked infiltration of the decidua.

No. 788 *a*, *b*.

(1) Anfin Egdahl, Menomonee, Wisconsin.
(2) Twins { (*a*) Ovum 60×45×40 mm.; stunted embryo CR 17 mm. (*b*) Ovum 65×55×40 mm.; nodular embryo 2 mm. long, group 4.
(3) Norwegian woman, aged 32 years, married 10 years. Three previous pregnancies. This abortion, which is the first, occurred July 2, 1913. Condition of uterus normal. No history of venereal disease. First twins known in family.
(4) *a*. This specimen measures 60×45×40 mm. Half of its surface is formed by a transparent membrane, which was found upon opening to be the greatly distended chorion and amnion, containing an atrophic embryo 17 mm. CR.
(5) The chorion and amnion are thickened and fibrous, the villi irregularly formed, non-vascular, and undergoing mucoid degeneration. They are encircled by considerable fibrinoid substance and a hemorrhagic and inflamed decidua. The intervillous spaces have within them considerable trophoblast, some of which is necrotic. There is a fair amount of activity in the syncytium, some of which has been converted into nuclear dust. The embryo is dissociated, but all the organs can be outlined. The front of the face is attached to the thorax.
(6) Mild endometritis.

No. 802.

(1) W. G. Sexton, Baltimore, Maryland.
(2) A 19×26×16 mm.; B 6 mm.
(3) Patient aged 29 years; has had four normal pregnancies and two miscarriages. One week before operation patient began to have abdominal pain and slight bleeding. The bleeding continued until the time of admission to the hospital. At times she passed large clots. At the operation the entire placenta was removed and the uterus curetted.
(4) The ovum is well covered with villi, excepting at one pole, which is bare. It was carefully opened through this area, and a well-formed embryo CR 6 mm. was found encircled by a somewhat opaque amnion.
(5) The villi are well defined, and the chorionic wall is normal in structure. The villi are matted together and do not have the usual clear mesenchyme. The stroma, which is somewhat macerated, contains degenerating vessels. The trophoblast is very irregular, most of it necrotic, and numerous small buds of syncytium are attached to the villi. The body of the embryo is normal in form, and sections indicate that its organs are well defined and apparently normal, with the exception of some dissociation, which is especially well marked in the cells of the large blood-vessels; that is, the blood appears to be diffusing through them. The head is atrophic, the brain badly dissociated and very small, and the eyes are round and reduced in size.
(6) Decidua absent.

No. 872.

(1) Charles E. Brack, Baltimore, Maryland.
(2) A 38×28×30 mm.; B 13 mm.
(3) Woman aged 40 years; married in 1896. Eight term pregnancies and three miscarriages. Abortions between second and third child, between sixth and seventh, and after the eighth. Last menstrual period January 18 to 25; abortion April 17 following. Patient was ill after the middle of February with nausea, languor, and chilly sensations. Size of specimen did not correspond with period of amenorrhea. Condition of uterus normal. No venereal diseases. Family fertile.
(4) The specimen consists of an abortion mass, measuring 55×35×35 mm., and seems to be mainly decidual tissue from which the spherical and distended ovum has freed itself. The ovum measures 38×28×30 mm., and is covered on one side by luxuriant villi which attain a length of 12 mm. On the other side it is bare and transparent. Opened in the denuded area, an opaque, stunted embryo and yolk-sac are seen. The embryo is still attached to the chorion by a short, clear umbilical stalk. It measures 13 mm. GL. The neck has been torn ventrally, so that the head is somewhat more extended upon the body than previously, and therefore the length recorded is too great. The head, arms, and legs are atrophic. Lying about 8 mm. distant from the embryo is a thin-walled but opaque yolk-sac, measuring 4×6 mm. The amnion lines the entire chorion. The villi are irregular in size, ragged, and suggest the presence of hydatiform degeneration.
(5) Upon microscopic examination the hemorrhagic decidua shows the presence of considerable autolysis. Some portions are composed wholly of the usual large polygonal cells, but in other areas cells of the fibroblast type prevail. These not infrequently show a tendency to streaming or arrangement in whorls. No indication of infection is present.

The chorion, amnion, and villi, though macerated, are relatively well preserved and the latter distinctly hydatiform in structure. Considerable epithelial proliferation is present and the nodules are degenerate. Epithelial migrations are present in some villi, but only relatively small syncytial buds are present on the chorionic membrane. In many regions the epithelium is still distinctly two-layered. Hofbauer cells, especially transitional in type, are quite common.
(6) Hydatiform degeneration.

No. 880.

(1) B. F. Terry, Brooklyn, New York.
(2) B 10.5 mm.
(3) Patient 34 years old. Has two children, both living. No former abortions. Menstruated last November 5; suddenly developed "cramps" February 3 following. Expelled membranes containing fetus the same day. She did not suspect her condition because of menstrual irregularity. At times she does not menstruate for several months. This is probably due to anemia. Age of embryo estimated at 8 weeks.
(4) The specimen consists of a pathological embryo, measuring 10.5 mm. CR, 11.2 GL, and 11.2 NL. The left side of the body has suffered grave mechanical injury, the legs having been removed, the muscles, ribs, and nerves

being exposed. The embryo is stunted, as disclosed by the featureless head and face and poorly developed brain.

(5) The specimen is somewhat macerated and markedly dissociated. The ear seems to be displaced and the face is partly adherent to the body, but most of the structures are normal in form. There are curious warts on the surface of the skin, one on the side of the head being especially prominent. The walls of the blood-vessels are not sharply defined.

(6) No decidua or chorion.

No. 936.

(1) John A. Leutscher, Baltimore, Maryland.

(2) A 80×40×15 mm.; B 9 mm.

(4) The specimen consists of a pear-shaped abortion mass measuring 80×40×15 mm., covered almost completely with a decidual cast, except at the lower pole, where the chorion is exposed. Here the villi measure 6 mm. in length. The cavity, which is circular, measures about 35 mm. in diameter, and shows only delicate shreds of amniotic tissue; otherwise, no amnion is to be seen. Projecting into the cavity is an irregular embryonic rudiment 9 mm. long, with a thick, white umbilical cord about the same length; 7 mm. distant from its point of attachment to the chorion is a flattened opaque sac, 3 mm. in diameter. The embryo was evidently badly macerated, as well as seriously hurt mechanically. On the left side the stump could be distinguished; on the right only the leg could be made out.

(5) The chorion and amnion are fibrous, and the yolk-sac is a solid mass of necrotic material. The villi are fibrous and covered with large clumps of trophoblast. There is considerable trophoblast substance and a stringy substance in the intervillous spaces. The head of the embryo is missing, and sections show that the upper part of the body ends in a ragged stump. The tissues are markedly dissociated, but most of the organs can still be made out. The dissociation is especially pronounced in the tips of the extremities, as well as in the vertebral column. In place of the spinal cord there is a slit extending throughout the length of the embryo, on either side of which are two strands of round cells in the position of the dorsal ganglia. These appear like blood-vessels filled with blood rather than nerve cells. In the lower part of the body one of these strands has undergone a peculiar fibrous degeneration. It appears much like a small neuroma.

(6) Intense infiltration; probably some hydatiform degeneration.

No. 958.

(1) Frederick J. Beitler, Baltimore, Maryland.

(2) A 31×22×20 mm.; B 13 mm.

(3) Patient married about 4 years. Three pregnancies, first and second ending at term, and this abortion. Condition of uterus normal, no infection, no venereal diseases. Five children on maternal side of family and 3 on paternal.

(4) The chorionic mass measures 31×22×20 mm. and is covered with villi and enmeshed blood-clot, except for a denuded area 10 mm. in diameter. On opening the chorionic sac there appears a mass of semi-solidified magma, removal of which revealed a well-preserved embryo showing signs of arrested development.

(5) The degenerate chorion is entirely lined by the amnion. Its main wall is thin and covered with clumps of degenerate, fibrous villi which are matted together with trophoblast and mucoid substance. Within there is a great deal of granular magma. The embryo is stunted and greatly dissociated. The head is closely adherent to the body, the face atrophic, and the spinal cord open below, with the cord protruding. The organs, however, can be fairly well outlined. Most of the blood-vessels are filled with blood, but all the tissues are dissociated.

(6) Decidua absent.

No. 962.

(1) Joseph M. Jackson, Pittsburgh, Pennsylvania.

(2) A 34×28×24 mm.; B 10 mm. (est.).

(3) A patient aged 32 years; married 12 years. Six pregnancies.

(4) The specimen consists of a chorionic sac covered almost entirely by villi, and measuring 34×28×24 mm. On opening it, a cloud of fine, opaque particles exuded; otherwise the chorionic cavity was filled by a reticulated semitransparent network which bridges it from wall to wall.

(5) A piece of chorionic sac, thicker than the rest, was cut into serial sections, and in this was found a macerated embryo of about the 10 mm. stage. The wall of the chorion and its well-developed villi are fibrous and macerated. Some of them are closely matted together with necrotic trophoblast, and most of them contain degenerating vessels. The stroma of the villi also seems to be invaded by a great deal of nuclear dust and also many sprouts of trophoblast. The embryo is closely encircled by the amnion and greatly macerated, the organs and cavities being practically obliterated. Marked autolysis of the decidua.

(6) Some (?) local infiltration.

No. 983*a*.

(1) J. F. Hempel, Baltimore, Maryland.

(2) A 70×50×30 mm.; B 18 mm.

(4) The specimen consists of a thickened and discolored chorionic sac 70×50×30 mm. On opening it, a yellowish, watery fluid, with brownish, fragile clumps, escaped. After this was drained off an embryo 18 mm. long and apparently badly macerated, was found attached by an umbilical cord 11 mm. long.

(5) The villi are mostly atrophic, and at certain points the intervillous spaces are distended with blood. The tissues do not stain well, and the organs, which can barely be outlined, are badly macerated. The head is somewhat atrophic.

(6) Decidua very necrotic.

No. 993.

(1) L. W. Haynes, Detroit, Michigan.

(2) A 48×41×15 mm.; B 7 mm. (est.).

(3) Patient aged 42 years; has 3 children living, 8, 6, and 3 years, respectively. About 10 years before the abortion she had a bad fall and miscarried at 3 months. That was the only miscarriage except the present one. On May 3 she fell down a short flight of steps, sustaining a large bruise on the right hip. Several hours later she began to flow. At that time the patient was two weeks overtime for her period, but had none of her usual symptoms of pregnancy. The flow continued until May 5, when the specimen passed.

(4) The specimen consists of a partially collapsed amniotic sac measuring 48×41×15 mm. The villi are thin and transparent, and divide several times. On opening the sac there was an escape of turbid fluid containing a very fine precipitate. On rinsing this out the fragments of an embryo were found, consisting of an atrophic head and the tail portion of an embryo about 7 mm. long.

(6) No decidua. Sections include the chorion, amnion and villi, but do not stain well. Histolysis is almost complete.

No. 1022*e*.

(1) Ernest C. Lehnert, Baltimore, Maryland.

(2) 33×22×15 mm.

(4) Specimen is a portion of an inverted chorionic sac with peculiar, long, branching villi, some of which measure 16 mm. The embryo is stunted and the arms are atrophic. Under examination with the binocular scattered hydatiform villi are seen, although the vesicle is degenerate.

(5) Examination under higher magnification confirms the presence of undoubted hydatiform degeneration, although there is no unusual increase in epithelium. The decidua is extremely degenerate.

(6) Partial hydatiform degeneration.

GROUP 7.

No. 60.

(1) G. W. Dobbin, Baltimore, Maryland.
(2) B 8 mm.
(4) The mutilated body and extremities of the embryo appear normal in form.
(5) The tissues are considerably macerated and the specimen may be normal. The spinal cord is solid. There are large islands of blood-cells in the very degenerate liver. The umbilical vesicles are completely destroyed a little distance from the abdomen, and near the latter the cord is distended and the stroma almost completely destroyed.
(6) Probably a normal mutilated and macerated embryo. Decidua absent.

No. 79.

(1) David K. Briggs, Blackville, South Carolina.
(2) A 50×50×50 mm.; B 32 mm.
(3) Abortion took place 91 days after the beginning of the last menstrual period.
(4) The specimen was received with all of the membranes intact. When opened, it was found that the amnion was filled, and the embryo entirely covered with a layer of firmly coagulated granular magma.
(5) The chorion is very necrotic, thick on one side and thin on the other. Many of the villi also are necrotic and others have undergone mucoid degeneration. All are non-vascular. There is much degenerate trophoblast. The decidua is very degenerate. Serial sections of the embryo show that it must have been strangulated long before the abortion took place. The central nervous system is greatly macerated, the liver has disintegrated, and the aorta is very much distended. The rest of the embryo appears normal. The intestine is almost entirely within the peritoneal cavity, but a single loop of it still remains in the opening communicating with the cœlom of the cord. The vessels of the latter are still present. The embryo is completely covered with a layer of magma which contains but few cells. Below this the epidermis is lacking at many points, while at others it appears fairly normal.
(6) Decidua absent. Early hydatiform degeneration.

No. 94.

(1) Edwin G. Knill, Detroit, Michigan.
(2) A 50×40×30 mm.; B 20 mm.
(4) The ovum is smooth, with villi on one side only. The amnion measures 30×20 mm., and does not fill the chorion completely. Within it there is much coagulated matter which entirely envelops the embryo, but which can be picked off easily in large flakes. The embryo thus exposed is bent upon itself more than usual and appears macerated, as if it had been dead for a number of days. The features are not clear, nor are the tips of the hands and feet well defined. The lower part of the body is necrotic and the spinal cord is protruding.
(5) The sections show that the villi of the chorion are degenerate and non-vascular. The decidua is infiltrated. The mesoderm of the chorion and amnion clearly show marked degeneration. The embryo itself is normal in shape, but the brain is greatly dissociated; the liver is cloudy and projects into the cord. All of the epidermis is exfoliated, and great masses of degenerate nuclei lie between the embryo and the envelope of magma.
(6) Decidua infiltrated; early hydatiform degeneration.

No. 97.

(1) Gustav Goldman, Baltimore, Maryland.
(2) A 33×30×15 mm.; B 7 mm.
(3) Beginning of last menstrual period March 8; abortion May 8.
(4) The ovum appeared normal, with the villi distributed equally over it. Upon opening, it was found filled with dense magma réticulé, in which could be discerned the faint outline of a 4-weeks' embryo. The embryo, amnion, and umbilical vesicle are all normal in form.
(5) The amnion is filled with cells; the umbilical vesicle is filled with migrating cells, but its blood-islands and entoderm appear fairly normal. The chorion is fibrous, rarefied, and macerated. The outer covering of the vesicle is composed of a short layer of columnar epithelial cells. The magma of the cœlom is filled with wandering cells. On one side of the embryo the epidermis is missing. The nervous system is greatly dilated and dissociated, and the liver tissue obscured and filled with migrating cells. The contour of the abdominal viscera is obliterated, and they, likewise, are filled with migrating cells. Pharynx, heart, large veins, and aorta are greatly dilated.
(6) Decidua absent. Some hydatiform degeneration.

No. 124.

(1) H. F. Cassidy, Baltimore, Maryland.
(2) A 90×75×50 mm.; B–35 mm.
(4) The ovum was received fresh and unopened. It appears as a transparent cyst with a crescent-shaped placenta on one end, measuring 60×50 mm. Within it was a second sac, 50×37×35 mm., with tough, fibrous walls, which proved to be the amnion. Within this was an embryo, with club hands and feet, pointed ears, and a very thin, twisted umbilical cord.
(5) Sections of the placenta show that the villi are matted together and covered with a thick layer of decidual cells. The wall of the chorion is considerably thickened immediately below the placenta and fibrous in structure. Between the villi at their bases there is a quantity of fresh blood, and between their distal ends there is a great quantity of trophoblast which does not stain well and appears to be necrotic. Masses of granules, which stain intensely with hematoxylin, can be seen. Sections of this interesting specimen do not reveal very much, for the tissues do not stain well. The form of the organs and skeleton, with the exception of that of the extremities, appears to be normal. However, the skin appears more fibrous than usual, being somewhat infiltrated with round cells. In the deformed extremities this infiltration is very pronounced and involves all of the structures of the hands and feet, with the exception of the cartilages. Syndactyly is present.
(6) Marked decidual infiltration; changes in chorion suggest lues.

No. 133.

(1) J. M. Hundley, Baltimore, Maryland.
(2) A 32×32×32 mm.; B 12 mm.
(3) Patient's last period began September 15 and continued 8 days; bloody discharge began November 11, and abortion occurred on the 19th. Both parents perfectly healthy.
(4) When received, the specimen was thought to be normal, but after a piece of the chorion had been cut the cœlom was found to be completely filled with a dense mass of magma réticulé. In taking off the piece of chorion the attachment of the umbilical cord was cut and thus the embryo located. The mass of magma and a portion of the chorion encircling the embryo were removed and cut into serial sections.
(5) The villi of the chorion are fibrous and macerated, but normal in shape, with little trophoblast at their tips and with poorly preserved vessels. The epithelium of the chorion is greatly macerated. The cœlom is filled with magma and migrating cells. The amnion is present but necrotic. The umbilical vesicle is filled with desquamated entoderm cells. The embryo is distorted and cramped; epidermis exfoliated at the points where the amnion contains masses of migrating cells. The nervous system is distended and dissociated, and the organs and peritoneal cavity fairly well outlined. The liver is filled with blood, which forms large islands at points. The front end of the head is distorted greatly, the eye macerated, and the whole head gorged with round cells.
(6) Decidua absent. Long retention.

No. 152.

(1) H. J. Boldt, New York.

(2) A 70×42×38 mm.; B 31 mm.

(3) "The specimen is from a woman suffering with endometritis, this being her third successive abortion, which took place in each instance during the third month of pregnancy. The beginning of the last period preceding this abortion took place on April 16; conception April 20 (?), and abortion June 25."

(4) The chorion was smooth and apparently devoid of villi. The cavity of the amnion was filled with a mass of granular magma covering entirely an embryo over 2 months old. The umbilical cord was much twisted and thin, measuring 0.5 mm. in diameter.

(5) Microscopic examination shows that the chorion and amnion are fibrous, thickened, and degenerate. The villi of the chorion are matted together with fibrin and a mass of cells which have undergone hyaline degeneration. The epithelium is absent or necrotic; stroma of villi very fibrous, being invaded at many points by syncytial cells and leucocytes. At numerous points there are large nests of leucocytes forming abscesses. It is a plain case of endometritis infecting the chorion. The embryo is embedded in a large quantity of magma and presents just such a picture as No. 79, described above. The organs are dissociated and macerated and the tissues stain poorly, indicating that the embryo had died a considerable time before the abortion took place. Again, the central nervous system is swollen and dissociated. Migrating cells are found in clumps or scattered in all of the tissues. In general, the connective tissues are more fibrous than normal, the dermis showing considerable hypertrophy. The epidermis is lacking.

(6) Infiltration of the decidua; long retention.

No. 182.

(1) D. S. Lamb, Washington, District of Columbia.

(4) Head and upper end of the body of an embryo about 5 weeks old.

(5) Sections show an extreme degree of disintegration. The brain is converted into a mass of cells filling the central canal entirely and extending into the surrounding tissues, the line of demarcation being obliterated. The large veins of the body are gorged with blood, which also extends into the surrounding mesoderm. On the frontal side of the head there is a straw-colored, necrotic mass containing some migrating cells. On the dorsal side the mesoderm is thin and blistered. The cartilages alone are still well defined.

(6) Decidua and chorion absent.

No. 212.

(1) J. Park West, Bellaire, Ohio.

(2) B 15 mm.

(3) The macerated embryo is from a large ovum which was aborted October 9. Last menstrual period began on April 3, 189 days before the abortion.

(5) The tissues show that its development was arrested during the sixth week. The central nervous system is completely dissociated, being but a mass of cells. The face and top of the head have been converted into a thickened mass of degenerated tissue, in which may be seen large veins filled with blood. The eyes are immediately below the skin, thoroughly dissociated, but the vesicular lenses can still be outlined.

(6) Decidua and chorion absent.

No. 215.

(1) D. F. Unger, Mercersburg, Pennsylvania (Brödel collection).

(2) A 45×40×40 mm.; B 17 mm.

(4) The specimen is smooth and fleshy and filled with granular magma, in which were found the remnants of a macerated embryo.

(5) Sections of the chorion show that it corresponds with its history, which states that the specimen is about 12 weeks old. The amnion lines the whole ovum. The chorion is thickened locally and degenerate. The villi are matted together, and the stroma is non-vascular and fibrous, with necrotic epithelium. The two sections of the decidua present show no infiltration, but the appearance of the sections and of the gross specimen suggests very strongly that infection must have been present.

No. 226.

(1) J. Park West, Bellaire, Ohio.

(2) A 60×60×30 mm.; B 24 mm.

(3) "The woman, mother of three children, menstruated last on March 3 and aborted on May 29."

(4) The ovum is covered with a few large villi, 2 mm. in diameter at their base, and irregular clots of blood; elsewhere it is smooth. The amnion is filled with a granular mass which was easily removed.

(5) Between the amnion and chorion there is an irregular mass of maternal blood. The tissues of the villi and the chorion are somewhat fibrous with only a few degenerated blood-vessels in some of them, indicating that the circulation had ceased some time before the abortion. This is confirmed by a study of the embryo. The external form of the embryo indicates that it was nearly 50 days old when it died; for, with the exception of the head, its form is practically normal. The menstrual history makes it 87 days, and if 28 are subtracted, 10 days are still left, which is time enough in which to bring on the internal changes found. In general, the organs are sharply defined, but do not stain well. The cartilages also are well formed, and the maxilla, mandible, clavicle, humerus, ulna, radius, femur, and tibia have begun to ossify. All this indicates that this embryo died quite suddenly, and that the changes within it are to be viewed as post-mortem changes. The vascular system is well developed, the heart-muscle being normal in shape, but very fibrillar, and does not stain well. Most of the large vessels are empty, the blood-cells being scattered throughout the tissues of the embryo and the cord. The muscle-fibers are unusually well marked, and the connective tissue seems to be thickened. The most marked changes are seen in the head. Much of the epidermis is still in place, but some of it has fallen off. At the back of the head the destructive process has included the back of the brain and the upper part of the spinal cord. The forebrain, midbrain, and spinal cord of the trunk are still intact and dissociated. The eyes are normal in shape and position, but much macerated. The nerves of the head can still be outlined, which shows quite conclusively that the disintegration of the medulla is of recent date.

(6) Decidua absent.

No. 230.

(1) J. Park West, Bellaire, Ohio.

(2) A 75×60×59 mm.; B 57 mm.

(3) "The patient has had 3 children and 3 miscarriages. She always menstruates regularly during pregnancy, and hence has been undecided during the past 7 months whether or not she was pregnant."

(4) Upon opening the ovum it was found that the fetus was greatly cramped and embedded in much granular magma. The cord is thin and knotted. The right leg has a club-foot and the left a dislocated knee-joint. Evidently the embryo had been dead for a long time.

(5) The chorion and amnion are very degenerate, fused, fibrous, and thickened. The vessels of the chorion are largely obliterated. The stroma of the villi is fibrous and non-vascular, and the epithelium necrotic. The villi are matted into a solid mass by fibrin and coagulum, together with the degenerate decidua and trophoblast. The dislocated knee and club-foot of the embryo show that the cartilages are markedly deformed. The liver, brain, spinal cord, and eye are macerated, converted into a pulpy mass, and do not stain. All of the epidermis has fallen off.

Apparently the embryo died suddenly, for there are practically no tissue reactions to suggest the contrary, and the changes must have taken place after death.

(6) Decidua very necrotic; changes in chorion suggestive of lues.

No. 261.

(1) W. H. Lewis, Baltimore, Maryland.

(2) A 120×70×70 mm.; B 90 mm.

(4) The distorted fetus, which no doubt had been dead for a long time, is embedded in a mass of granular magma.

(5) Sections of the placenta show that the villi and chorion are very fibrous and almost devoid of epithelium. The stroma of the villi is clear and non-vascular. Numerous degenerate syncytial buds are present. The vessels in the decidual septa, and some of those in the chorion, are obliterated or are being obliterated. The umbilical cord is somewhat fibrous, but contains blood-vessels filled with blood. The decidua contains large sinuses and is infiltrated and fibrous. The tissues of the hand and the skin are somewhat infiltrated with round cells, but other changes within them are not marked. It appears as if the embryo died quite suddenly.

(6) Decidua is infiltrated.

No. 286.

(1) John Girdwood, Baltimore, Maryland.

(2) A 100×50×40 mm.; B 60 mm.

(3) This specimen must have been dead in the uterus for about 5 months, the last period having taken place during the latter part of May and the abortion on January 4 following.

(4) The chorion thickens as it passes into the large, fleshy placenta on one side and is very thin on the other. The thin, twisted cord enters the chorion at the border of the placenta. The embryo is well-embedded in granular magma.

(5) Sections from the placenta at the point where the cord enters it show a most remarkable reaction. The amnion is thickened, fibrous, folded upon itself, and has undergone hyaline degeneration. The chorion also is hyaline, thickened, and infiltrated with leucocytes and syncytium. The villi are fibrous, with numerous spots of hyaline matter scattered through them. The lining cells of the large blood-vessels of the villi show remarkable growth, forming small pearls of endothelial cells. They are also invaded by syncytial cells at some points, and at others by masses of leucocytes. Between the villi there is a great mass of necrotic syncytium mixed more or less with fresh blood. Throughout this general mass numerous small islands of active trophoblast may be seen; there are also a great number of scattered leucocytes. The decidua is decidedly fibrous and degenerate in some places, and infiltrated in others. Sections of the cord, of the abdominal viscera, and of the hand show that the embryo must have died quite suddenly. However, the tissues do not stain well and the epidermis has fallen off, although the large blood-vessels are filled with blood containing the usual number of leucocytes.

(6) Decidua infiltrated, fibrous, and degenerate.

No. 316.

(1) Thomas J. Simms, Baltimore, Maryland.

(2) B 44 mm.

(4) There are peculiar patches upon the skin, the cord is atrophic, feet and hands club-shaped, and one hand is adherent to the side of the head.

(5) Sections of the cord show that it is fibrous and infiltrated with round cells along the course of the blood-vessels. The skin is thickened locally and much of the epidermis has fallen off. At points the epithelial cells form mounds without any horny changes. The muscles, blood-vessels, and nerves of the extremities are converted into a mass composed of spindle-shaped cells, giving much the appearance of myomatous tissue, infiltrated at points with round cells. The cartilages are still hyaline, but richer in nuclei than is normal. Bone formation is present, and at the border-line between it and the cartilage the latter shows peculiar changes. There is a mass of this changed cartilage in the os calcis, without any surrounding bone formation. In general the cartilages are deformed, a condition in part producing distorted joints. Where the hand is adherent to the side of the head the epidermis of the two is blended. The skin and subcutaneous tissue are thickened, being composed of a mass of round cells. At some points of the body there are thickened areas in the skin. The form and structure of the brain are pretty well preserved, while the tissues of the liver and intestine are necrotic and macerated. It appears as if the growth of the embryo had been retarded by a continued growth and change in the connective tissue, and that, after its death, it was retained in the uterus for some time.

(6) Decidua and chorion absent.

No. 345.

(1) C. S. Minot, Boston, Massachusetts.

(2) A 60×50×50 mm.; B 19 mm.

(4) The fleshy ovum is composed largely of decidua in which are buried plugs of mucus and necrotic villi of the chorion. The embryo is normal in shape.

(5) Its tissues are greatly macerated, but on account of the distended medulla, which encroaches upon the mouth, it is probable that the tissues were dissociated before they became macerated.

(6) Slight general infiltration of the decidua; chorionic membrane absent.

No. 379.

(1) A. W. Meyer, Baltimore, Maryland.

(2) A 35×25×15 mm.

(3) Last menstrual period early in August; abortion October 20.

(4) The specimen is well covered with villi and filled with a considerable amount of reticular magma. The amnion measures 10 mm. in diameter and contains a granular mass, which, when floated from alcohol into water, revealed an embryo of the fourth week. No internal structures could be seen, and in handling the embryo it fell to pieces. No doubt it had been dead for some time. The wall of the amnion is composed of two layers of cells and appears to be normal.

(5) Sections show that the mesoderm of the umbilical cord, the wall of the chorion, and the villi are fibrous, with a curious growth of blood-vessels in some places. The stroma of most of the villi is clear, non-vascular, and has undergone mucoid degeneration in some. Maceration changes also are present. Within the vessels of the villi are numerous fragmented cells which may have come from the blood of the embryo. The syncytium is very extensive and necrotic at points. In many places it dips deep into the mesoderm of the villi and forms islands of epithelial nests. The wall of the amnion is composed of two layers of cells and appears to be normal.

(6) Decidua absent. Very early hydatiform degeneration.

No. 445a.

(1) J. L. Fewsmith, Newark, New Jersey.

(2) B 60 mm.

(3) "Patient first menstruated at about 14, and as far as she can recall was pretty regular at first. At 19 the periods became rather irregular. She could count upon skipping two months in summer, usually July and August. This irregularity has continued up to the present time, though not so marked during the last two years since she has been under treatment. Each period, as a rule, is accompanied by severe pain lasting for the first 12 to 14 hours. This has been so severe at times as to need small doses of morphine or cocaine. The flow, when established, has usually lasted for about 5 days. During the last 2 years it has been less in amount and has ceased on the

third or fourth day. When about 15 or 16 years of age she had a great deal of pain over the ovaries, and her physician made her stop playing tennis, etc. When about 18 there was a mild attack of chlorosis, with cessation of menstruation for several months. She became pregnant about a year after her marriage, 6 years ago. The fetus was carried for 6 months, when she miscarried. Development apparently had not gone much beyond 3 to 3½ months. The pregnancy was accompanied by a great deal of pain in the sacral region. As she did not become pregnant again, she was, about 3 years ago, put under the doctor's care. He finally decided to dilate the cervix, curette, and put in a glass plug. At the operation he found the cervix to be very brittle; he could feel it give under the dilators, so that he had to give up dilating and merely do a slight curettage. She became pregnant again about 4 months after the operation. This time the fetus was carried 4 months. The pregnancy was accompanied by some pain in the back, often with bearing-down pains and pains along the thighs. She became pregnant again last September and miscarried at the end of January. This is the specimen in which the sac was unruptured. The same pains were present, but even more severe, making her extremely uncomfortable and miserable. This last miscarriage was hard, the severe pains lasting about 8 hours, as the cervix would not dilate. Each miscarriage has been preceded by a bloody discharge lasting from 5 days to a week. Dr. ——— (the physician under whose care she had been) can tell you better the condition of the uterus and appendages. He considers the uterus, I believe, to be rather fibrous and the ovaries to be somewhat smaller than they should be, but says he can not explain the pains, nor why, having become pregnant, she should miscarry. There has never been any leucorrhea."

At that time it was recommended that the uterus of this patient be thoroughly scraped a number of times, if necessary; but, as the following will show, it seemed to be of no value in preventing this particular disease of the fetus and subsequent abortion. Five years later we wrote to Dr. Fewsmith again, asking for more details regarding the case. He replied that during the interim the patient had been pregnant twice, each time aborting at about the same period of gestation—that is, about the fifth month. In his opinion the fetuses aborted were about the 3-months' stage.

(5) The chorion is small, hemorrhagic, and atrophic, and contains an embryo which, although somewhat distorted, is normal in form. The villi are very fibrous and some of them are edematous. The trophoblast is scanty and at many points has invaded the stroma of the villi. There are also numerous Hofbauer cells. The intervillous spaces are packed with an inflammatory mass consisting of mucus, fibrin, disintegrating blood, and numerous leucocytes. Intermingled with this mass are many small buds of syncytium. The chorionic wall does not seem to be any thicker than usual, and between it and the amnion there is a dense layer of reticular magma, through which are scattered numerous Hofbauer cells. The decidua appears to be atrophic, but there is the usual fibrinoid layer between it and the villi.

(6) The decidua is markedly infiltrated and contains small abscesses; hydatiform degeneration of the chorion.

No. 445*b*.

(1) See No. 445*a*.
(2) B 85 mm.
(3) (See No. 445*a*, just described.)
(4) The chorion is somewhat hemorrhagic and covered with well-formed villi. The fetus is normal in shape, well bent upon itself, and the cord is very much twisted, being extremely thin at some points. The amnion is filled with a large quantity of granular magma which forms large cakes, many of which are closely adherent to the embryo.

(5) The chorion shows all the reactions of 445*a* but in a more marked degree. A hand from each embryo was cut into serial sections and appears to show slight changes, more pronounced, however, in 445*b* than in 445*a*. The decidua is infiltrated intensely in some places.

(6) Marked infiltration of the decidua.

No. 502.

(1) A. Shelley, Baltimore, Maryland.
(2) A 90×60×50 mm.; B 85 mm.
(3) Said to be a fetus of the third month.
(4) The pear-shaped mass is quite solid, being hemorrhagic, with only a few villi protruding. It contained a compressed, dried fetus, which seemed to be normally developed but much shriveled, with a greatly twisted and flattened umbilical cord.

(5) Sections through the chorion at the point of attachment of the umbilical cord show that the mesoderm of the villi is very fibrous, and that the chorion is covered with an inflammatory, hemorrhagic mass composed of blood, fibrin, numerous leucocytes, fibrinoid substance, and villi which have undergone extensive degeneration. There is very little trophoblast present, but a number of syncytial buds radiating into this mass, many of which are being converted into nuclear dust. Surrounding each villus is a space filled with fresh blood, indicating that in some way the trophoblast has the power to prevent coagulation. Serial sections were cut of the right hand of the embryo and show dissociation of its tissues. At points the epidermis is lifted from the underlying structures, and the cleft thus formed is filled with small round cells.

(6) Decidua absent. Very long retention; chorionic membrane infiltrated.

No. 549.

(1) J. M. Jackson, Pittsburgh, Pennsylvania.
(2) A 40×35×20 mm.; B 12 mm.
(4) The specimen is covered mostly with a layer of decidua and the cœlom is filled with a mass of reticular magma, within which is a ruptured amnion containing the remains of an embryo of about the 12 mm. stage.

(5) The tissues of this remnant are macerated and partly dissociated. The chorionic wall is normal in structure, but is encircled by villi which have undergone fibrous and mucoid degeneration. There is very little trophoblast, and some of that has undergone nuclear fragmentation. There is also considerable fibrinous exudate between the villi. The layer of villi is encircled by considerable fibrinoid, decidua, and fresh hemorrhages. The decidua shows leucocytic infiltration. The magma of the exocœlom is very rich in cells, especially in small round cells. The embryo is dissociated and macerated.

(6) Some infiltration of the decidua.

No. 586.

(1) F. A. Conradi, Baltimore, Maryland.
(2) A 90×55×40 mm.; B 30 mm.
(3) Patient is said not to have menstruated for a year.
(4) A cavity extends throughout one side of the mass. This is lined with a smooth amnion in which was found a compressed, extremely macerated, and somewhat mutilated embryo, measuring about 30 mm. CR. According to the shape of the arms and legs, the specimen is normal in form. However, on account of the color and consistency of the tissue, it appeared to have been dead a long time before the abortion.

(5) Sections of the chorion show that its wall is extremely macerated and greatly thickened on one side, measuring 25 mm., on account of a large hemorrhage. This thickened area is composed of degenerated villi intermingled with fibrin, pus, and fresh blood. The trophoblast is mostly necrotic, and at points there are large masses of nuclear dust. The villi are degenerate, and many of them are invaded by leucocytes. The nuclei of the chorionic wall do not stain well, and apparently are disintegrating. The specimen appears to be like some of those obtained from tubal pregnancy; that is, after the

chorion is detached it keeps on growing in an irregular fashion, for the villi are in fresh hemorrhages. Sections of the embryo show that cartilages have been well formed. In some places the ossification centers stain with hematoxylin; otherwise the tissues are markedly macerated. Since none of them gives a differential stain, the embryo no doubt had been dead for a long time before the abortion.

(6) Some infiltration of the decidua; long retention.

No. 622.

(1) H. T. Collenberg, Baltimore, Maryland.

(2) A 80×40×15 mm.; B 70 mm.

(3) Patient aged 30 years, with three children living and apparently healthy. This is the third miscarriage. The others were early and likely not induced. Fetus was expelled after 24 hours of pain. No menstruation for 9 months.

(4) The specimen consists of an unopened membrane with placenta. The contents of the amniotic cavity consist of a dark-brown fluid and the macerated fetus. The latter measures CR 70 mm., is very much distorted and slender, with a head greatly reduced in size. The extremities are very much deformed, with club hands and feet, and the left forearm is adherent to the shoulder. The cord is nodular and atrophic.

(5) The placenta, which was cut at the attachment of the cord, was found to be fibrous. The villi are packed together with an almost continuous mass of necrotic trophoblast and show considerable invasion by leucocytes. Occasionally some activity is shown in the trophoblast. Most of the villi are fibrous and others do not stain well. They are all degenerate, even necrotic, and are glued by degenerate blood, epithelium, and trophoblast. Throughout the entire specimen large plaques of nuclear dust indicate that the tissues had been dead some time before the abortion.

(6) Marked infiltration of the decidua; long retention.

No. 627.

(1) H. F. Cassidy, Roland Park, Maryland.

(2) A 80×50×35 mm.; B 45 mm.

(4) The specimen consists of a solid mass, 40×30×25 mm., to which is attached a large vesicle, measuring 80×50×35 mm., and undoubtedly representing the distended amnion. Within the latter, which is filled with clear fluid, there is a distorted embryo with an extremely small and very much twisted umbilical cord. Over the legs, on one cheek, and on the back of the head there are large vesicles which seem to involve only the skin. The one over the back of the head is 15 mm. long and 8 mm. wide. Caudal to this and running down the middle of the back there is a marked fibrous ridge. The hands, especially the fingers, appear as if deformed.

(5) Sections made in the neighborhood of the attachment of the umbilical cord show the vessels of the latter with indistinct walls but filled with blood. The villi have largely undergone fibrous degeneration, and most of the trophoblast has been converted into nuclear dust, although some have fibrinoid substance only within their centers. There also are left rounded islands of trophoblast.

(6) Marked infiltration of the decidua; changes suggestive of lues.

No. 646.

(1) G. C. McCormick, Sparrows Point, Maryland.

(2) A 90×60×50 mm.; B 85 mm.

(4) The chorion, which measures 90×60×50 mm., was empty, the amniotic sac having slipped out. Within the latter was a macerated, edematous fetus, with a distorted head from which the brain is protruding. There are marked contractions in the forearms, and the fingers of the right hand are nearly amputated. From their knob-like stumps extend numerous delicate fibrils. As they strip off so easily, it is probable that they are composed exclusively of macerated epidermis. The umbilical cord is very thin and greatly twisted. The chorion is covered with large, shaggy villi, showing that implantation had been well established before the abortion.

(5) Sections through the cord show that it has undergone degeneration; sections through the hand show the dissociation of the periphery of the cartilages and muscles. In other words, there is an infiltration of cells between the muscle-fibers.

(6) Decidua and villi absent.

No. 649.

(1) G. C. McCormick, Sparrows Point, Maryland.

(4) The body and extremities of this specimen are much out of proportion. There is a large tumor on the back of the head, the spinal column is bent upon itself, and the viscera hang out in an enlarged bag in front. From one side of this bag the umbilical cord arises.

(5) The most marked abnormalities of this specimen are total spina bifida and defective posterior portion of the cranial vault. The spinal column consists of 31 vertebral bodies. This includes the coccyx, but not the atlas, which could not be traced. Along the sides of the vertebræ there are present rudimentary, cartilaginous neural processes. The spine is in sharp dorsi-flexion in the upper cervical and lower thoracic regions, with a more rounded and probably compensatory kyphosis below these areas. All that remains of the spinal cord is a strip of thin membrane into which the spinal nerves run fairly regularly ventrally. The anterior vault of the cranial cavity is flattened so that it is reduced to a narrow slit, and the defective contents of the cranium project backwards into a sac which lies over the spinal column. This sac consists of several layers of membranes. The remains of the nervous system which it contains are quite elongated nerves and shreds of much-folded membranous tissue. (Wheeler.) The ribs are very crowded and show a tendency towards fusing. In the forearms both ulnæ are present; 4 metacarpals and 4 phalanges; the radii and thumbs are lacking. In the legs the bones are all present, but the positions are anomalous. There is extreme external rotation, with the soles of the feet directed backward and inward (equino-varus). There is ectopia viscerum, the liver, intestines, stomach, spleen, and pancreas projecting outward into a rounded sac. Several subcutaneous blebs are scattered over the surface of the sac, and the stumps of the cord attached to it show marked mucoid degeneration. There is a Meckels diverticulum; the diaphragm is bilaterally defective; the lungs are abnormally formed and lie next the kidneys. The adrenals could not be traced.

No. 717.

(1) Max Emmert, Atlantic, Iowa.

(2) A 50×45×35 mm.; B 14 mm.

(3) Patient is 34 years old: married June 1907. First abortion February 1908, at 3 months. Last menstrual period April 7 to 10, 1913; abortion June 5 following. No infection of uterus; no venereal diseases. Patient is one of two children.

(4) The specimen measures 50×45×35 mm., and consists of a vesicular chorion covered partly by a few ragged villi and partly by infected decidua. The chorionic wall is very thin, and the cavity contains a clear fluid and a granular deposit. There also is a small mass of granular magma on one side, a macerated cord 10 mm. long, and a floating remnant of an embryo 14 mm. long. The latter can barely be outlined. One arm and the atrophic legs are still intact. A slight amount of shaking would cause the entire specimen to fall to pieces.

(5) The chorionic membrane and amnion are thin and fibrous. The villi are atrophic and some are fibrous. Between them there is a considerable amount of mucoid substance and blood, containing numerous buds of syncytium. The entire mass is surrounded by a thin layer

of decidua marked off on the inside by a pronounced zone of fibrinoid substance.

(6) Decidua not infiltrated.

No. 735.

(1) J. R. Blackman, Hastings, Nebraska.

(2) A 50×40×30 mm.; B 4 mm.

(3) First pregnancy of a woman, aged 30 years, who was married January 10, 1912. Last menstrual period May 29 to 31, and abortion July 20 following. Cervix dilated July 19 and a strip of gauze inserted in the uterus. Abortion induced for pernicious vomiting. Last periods were less profuse. Right ovary adherent and tender over McBurney's point. Frequent pain in appendix region. Uterus not infected.

(4) Pear-shaped mole 50×40×30 mm., with very thick walls and well filled with granular magma, which peels out in the form of large clumps. The cavity containing the magma measures 25×20 mm. On one side was seen a small whitish, amorphous body, about 4 mm. in length, the remnant of the embryo.

(5) The chorionic wall is thin and lined with a dense mass of granular magma containing embryonic fragments. It is surrounded by necrotic villi which are embedded in a mass of fibrin, mucoid substance, and some blood. The surrounding fibrinoid substance and decidua are very thin. There are numerous syncytial buds at points; otherwise most of the trophoblast is necrotic. The embryonic mass proved to be a macerated fragment of an embryo. It includes a section of precartilage and spinal cord, and is closely embedded in granular magma. No amnion was found. The decidua is necrotic, but not infiltrated.

(6) Decidua very degenerate, but apparently not infiltrated.

No. 740.

(1) Ira L. Fetterhoff, Baltimore, Maryland.

(2) B 56 mm.

(3) Patient 44 years old; married in 1890. Six pregnancies: First ended at term; second and third in abortions; fourth, twins; fifth at term; sixth, this abortion. Menstruation in April 1913, continued 6 weeks; again July 16 to 23; abortion August 8 following. After careful examination uterus found to be apparently normal.

(4) The embryo has a clubfoot, but otherwise is normal. It is encircled by a mass of magma which has cemented the extremities together, making it look like a mummy. The cord is very thin and twisted. No membranes were received with the specimen.

(6) Decidua and chorion absent.

No. 743.

(1) John H. Groshans, Baltimore, Maryland.

(2) B 105 mm.

(3) Patient 34 years old; married June 1, 1907. One birth at term, July 1908; abortion at 4 months, June 1910. Last menstrual period March 8 to 16, 1913, and abortion August 17 following. Patient supposed to use abortives, but denies it. No venereal diseases. Patient is a second wife. Husband's first wife had 7 children and 3 abortions.

(4) The specimen is shriveled, as if it had been in alcohol for some time, but the body and extremities are normally formed. The frontal bone is greatly retracted and the parietal bones overlap. The ears are flattened out and the eyes are sunken, all of which make it appear as an early stage of fetus compressus.

(6) Decidua and chorion absent.

No. 797.

(1) George T. Tyler, Greenville, South Carolina.

(2) A 65×35×35 mm.; B 35 mm.

(3) Woman aged 29 years; married one year. Always has had painful menses, which have been profuse. This was especially so in the last period, 4 weeks before the present one, November 9. History of exertion just before this period began. The patient did not know she was pregnant, as she had missed no periods. Physician called on November 9 because of pain and bleeding, and he found specimen presenting at vaginal orifice. No previous history of importance.

(4) The specimen is covered with a few atrophic villi, and its wall is thin on one side and thick on the other. The interior is filled with a jelly-like magma and contains an atrophic embryo 35 mm., which is markedly deformed, having atrophic hands and feet and a very thin umbilical cord. The head is also reduced in size.

(5) Sections of the chorion show that it is hemorrhagic and inflamed. The chorionic wall is fibrous and degenerate, and the villi mostly necrotic, only a few of them being fairly preserved. They are bound together by fibrin and a great deal of fibrinoid substance. There is also considerable nuclear dust.

(6) Marked infiltration of the decidua; probably luetic.

No. 805.

(1) Morris A. Birley, Thurmont, Maryland.

(2) A 100×60×45 mm.; B 50 mm.

(3) Woman aged 31 years; married 16 years. Seven births at term, this being her first abortion. Last period September 2 to 5; abortion December 5 following. Badly lacerated os. Patient belongs to a very fertile family.

(4) The chorion, which measures 100×60×45 mm., has a smooth wall, the greater part of which is thickened and hemorrhagic. One end, however, is thin and transparent. When the specimen was halved it was found to contain a cavity 70×50×25 mm., lined by a smooth amnion containing a fetus CR 50 mm., normal in shape but macerated, with numerous edematous blebs of skin. The umbilical cord is very thin and extremely twisted.

(5) Sections show that the amnion and chorionic wall are fibrous, and surrounding the latter are numerous villi packed together and intermingled with a great quantity of fibrinoid substance, organized blood, decidua, and inflammatory patches. There also is a great deal of nuclear dust. The spheres of trophoblast so frequently seen in these specimens have undergone fibrinoid changes.

(6) Marked infiltration of the degenerate decidua.

No. 809.

(1) O. S. Lowsley, New York.

(2) A 50×30×30 mm.; B 22 mm.

(4) The abortion mass, which is composed mostly of chorion, measures 50×30×30 mm. The amnion protrudes and contains a badly macerated embryo 22 mm. GL. This is distorted and bent upon itself, but when straightened appears to be normal in form.

No. 811.

(1) George H. Hocking, Govans, Maryland.

(2) A 100×80×60 mm.; B 120 mm.

(3) Patient aged 40 years; married 1896. Six pregnancies, five at full term and one abortion. Last menstrual period May 12 to 17; abortion December 26 following. Beginning about October, there were slight losses of blood at intervals for several weeks, and it is fair to assume that gestation ceased even earlier than this. Patient one of 6 children. The specimen is bent markedly upon itself; the epidermis is mostly lacking and the cord is greatly twisted. The fetus measures 120 mm.

(5) The amnion and chorion are very fibrous and closely connected by a thick layer of reticular magma. The chorionic wall is closely covered with decidua, there being no villi in the portion cut. One of the hands of the embryo was cut into sections. The tissues do not stain well.

No. 828.

(1) Austin Miller, Porterville, California.

(2) A 50×30×16 mm.; B 8 mm.

(3) Patient aged 28 years; married 3 years. One previous pregnancy, which ended at term. Last men-

strual period about November, and abortion January following. No venereal diseases. Family fertile.

(4) This specimen consists of a compressed oval mass, measuring 52×30×16 mm. On being opened, the firm hemorrhagic wall disclosed a smooth-lined cavity from which some blood-stained fluid emerged. It was filled with reticular magma, in which was embedded a macerated embryo GL 8 mm. The chorionic cavity measures 30×12×10 mm. The embryo is in fragments, two of the limbs being free; these, however, preserved their form well. The umbilical vesicle measures about 5 mm. in diameter and appears normal.

(5) Sections of the chorion show that the chorionic membrane is macerated, well infiltrated with leucocytes, and covered with matted villi, together with an inflammatory exudate. There is much fibrinoid substance and many buds of syncytium. The embryonic mass is composed mostly of a well-developed cord and portions of a macerated and disintegrated embryo, more or less encircled by the amnion. In the cord there are indications of dissociation, as the walls of the distended blood-vessels are not sharply defined.

(6) Severe intervillous infection.

No. 831.

(1) Austin Miller, Portersville, California.

(2) A 85×85×85 mm.; B 115 mm.

(3) Patient aged 29 years. Two pregnancies ending at full term. Last menstrual period July 21 and abortion January 20 following. Uterus normal as far as known. No venereal diseases. Family fertile.

(4) The specimen consists of a fetus compressus well curled upon itself and inclosed in its membranes, with placenta attached. The whole mass, which is spherical, measures about 85 mm. in diameter. On opening the membranes, the amnion could be separated from the chorion; on opening the amniotic cavity, a white, cloudy fluid poured out. The inclosed fetus is somewhat macerated, the epidermis being off in places and the head compressed. The umbilical cord is about 30 mm. long and very much twisted upon itself. Otherwise the specimen is normal in form.

(5) Sections were made through the chorion at the attachment of the umbilical cord. The chorion and villi are fibrous and matted together by a great quantity of fibrinous substance, more or less invaded by trophoblast cells, making the substance look like cartilage. There are numerous buds of trophoblast undergoing conversion into nuclear dust. The decidua is atrophic and inflamed.

(6) Slight infiltration of the decidua; probably luetic.

No. 868.

(1) E. H. Egbert, Washington, District of Columbia.

(2) A 75×48×22 mm.; B 39 mm.

(3) Patient aged 26 years, with no specific family or personal history on the part of patient or her husband. Both are in good health. Miscarriage March 1911, at 2½ months; May 1912, stillbirth at term; miscarriage at 2½ months, with curettage, May 25, 1913. Last menstrual period September 26, 1914; all symptoms of pregnancy. Flowed November 1 to 15 (a few clots); abortion April 7, 1914.

(4) The specimen consists of a pear-shaped abortion mass, measuring 75×48×22 mm., and the fetus which was inclosed therein measures CR 39 mm. It appears unquestionably pathological, both regarding the shape of the head and the extremities, which are club-like. The lining of the chorion (amnion) presents a remarkable sight, being profusely covered with small thickenings in the form of minute tubercles in rings.

(5) The chorionic membrane is very fibrous, and the overlying villi are firmly matted together by fibrinoid substance and some trophoblast. There are also numerous plaques of nuclear dust. Upon examining the amnion, it is seen that the minute tubercles are due to local thickenings in the fibrous layer.

(6) Decidua absent. Probably luetic.

No. 869.

(1) G. C. McCormick, Sparrows Point, Maryland.

(2) B 150 mm.

(3) Negro, age 30 years, married April 24, 1907. Six pregnancies: first, 7 months; second, 6 months; third, 6 months; fourth, 8 months; fifth, 4 months; sixth, 6 months. Last menstrual period October 1–4, 1913; abortion March 28 following. Condition of uterus good. Syphilis. Family fertile.

(4) The specimen is normal in form, but badly macerated. Most of the epidermis has fallen off, and the extremities, as well as the head, are compressed in an irregular fashion.

No. 896.

(1) Edwin B. Fenby, Baltimore, Maryland.

(2) B 88 mm.

(3) Patient aged 25 years; married nearly 7 years. Four pregnancies, but this is the first abortion, all the others at term and living. Uterus apparently normal. No history of venereal diseases. Family fertile.

(4) The abortion mass, consisting of placenta and fetus intact in its amnion, was sent to the laboratory 2½ hours after being passed. It was opened under salt solution, and much brown fluid with "débris" poured out. In this were epidermal casts of hands and feet, and a badly macerated fetus, length CR 88 mm., weight 26 grams, with a long, twisted umbilical cord, 150 mm. The head is shrunken, making it appear as an early stage of fetus compressus, perhaps from strangulation due to the extreme twisting of the cord.

(5) Sections of the placenta at the attachment of the cord show that the villi, though well formed, are practically non-vascular, and the stroma degenerate and cellular. The intervillous spaces are filled with some blood, trophoblast, and a great deal of fibrinoid substance. There are also numerous plaques of nuclear dust.

(6) Slight infiltration of the decidua.

No. 903*a*.

(1) J. H. Bacon, Peoria, Illinois.

(2) B 66 mm.

(4) The embryo is greatly macerated, distorted, and decerebrated. It weighs 11.5 grams in formalin, which indicates that it is somewhat under weight. The umbilical cord is very thin and twisted.

No. 921.

(1) J. L. Genella, New Orleans, Louisiana.

(2) B 16.5 mm.

(3) Patient aged 35 years. Mother died in childbirth and father of dementia. About five years after a diagnosis of malignancy was made the patient gave birth to a normal child. Several recent abortions. Coitus March 9. Beginning of last menstrual period February 28; abortion March 30. Pathologists had made a diagnosis of chorioepithelioma and hysterectomy was advised. It appears that the patient has syphilis.

(4) The specimen consists of a rather poorly preserved young fetus, measuring 16.5 mm. CR. The ventral abdominal wall had been seriously injured. It is difficult to be sure whether or not the specimen is normal, the left hand plate being somewhat abnormal in outline. The head is smaller than usual, being round in front. Maceration is so complete that a depression is present over the lower part of the spinal cord.

No. 929*b*.

(1) N. H. D. Cox, Baltimore, Maryland.

(2) A 80×70×50 mm.; B 75 mm.

(3) Patient aged 22 years; married 6 years. Four pregnancies; one abortion and three births at term.

Had no menstrual period after the birth of last child, November 10, except one day in January, and once, April 14, after a fall downstairs. After this a slight flow every two weeks. Nausea February 28 and March 22; abortion June 3. Accidental abortion from fall and therefore no infection. No venereal diseases.

(4) The chorion, which measures 80×70×50 mm., is entirely covered with well-formed villi, and appears to be normal. The contained fetus, measuring 75 mm., is badly macerated. It has a much-twisted and very slender umbilical cord, and there are large blebs on the right leg which appear to be abraded over the knee.

No. 960.

(1) G. C. McCormick, Sparrows Point, Maryland.
(2) B 190 mm.
(3) Negro woman, aged 31 years; married April 6, 1914. Has been pregnant six times; no abortions. Last period February 18 to 22, 1914; abortion October 17 following.
(4) An encephalic fetus apparently at term. Crown of head devoid of scalp, exposing an area 40×60 mm. of blighted brain and its membranes. Over the sacral region there is an area devoid of integument.

No. 964.

(1) Henry F. Cassidy, Roland Park, Maryland.
(2) B 115 mm.
(3) Negro patient, aged 24 years; married March 20, 1911. Two pregnancies, both ending in abortion; the first in 1913 at 3 months. Last menstrual period March 22 to 25; abortion October 19, 1914. Bled September 3, and intermittently after October 6, apparently a natural flow in time and amount. No history of venereal disease. Family fertile.
(4) The specimen consists of a macerated, flattened, and distorted embryo with umbilical cord 280 mm. long, and detached placenta 80×65×35 mm. On section the uterine surface of the placenta presents a firm white marginal layer of decidua, 2 mm. thick, thrown in ruge.
(5) The villi of the placenta are normal in shape, but closely packed together with trophoblast, and nearly all of them have undergone fibrinoid changes. The mesenchyme is fibrous and there are many plaques of nuclear dust. There is some blood in the intervillous spaces. This stains black with the Heidenhain method. The trophoblast in contact with it shows no activity whatever.
(6) Slight infiltration of the decidua; probably luetic.

No. 971.

(1) G. C. McCormick, Sparrows Point, Maryland.
(2) B 92 mm.
(3) Patient aged 26 years; married December 31, 1903. Three pregnancies—two births at full term and this abortion. Last menstrual period May 24 to 27, 1914, abortion October 29 following. Condition of uterus good. No venereal diseases. Family fertile.
(4) The specimen consists of a placenta, amnion, and a compressed, greatly macerated, attached fetus. The placenta is very firm. The cord is about 130 mm. long and not greatly twisted. The extremities are flattened and contorted, the legs being badly bent upon themselves. Most of the epidermis has fallen off, and the fetus in general is shrunken.
(5) Sections through the placenta at the attachment of the cord show the villi to be very fibrous, degenerate, and matted together by a uniform mass of fibrinoid substance, in which there are numerous plaques of nuclear dust.

No. 979.

(1) James A. Melvin, Baltimore, Maryland.
(2) B 210 mm.
(4) The specimen consists of a badly macerated fetus attached to a placenta which measures 130×100 mm. The fetus is discolored and distorted and the cord greatly twisted.
(5) The chorion is very fibrous and most of the trophoblast necrotic. The villi are matted together with extensive masses of fibrinoid substance, within which are large plaques of nuclear dust. The decidua is thin and somewhat inflamed, and the placenta itself is practically dead, there being no buds of syncytium at the point where the trophoblast comes in contact with the fresh blood.
(6) Slight general infiltration of the decidua; some suggestion of lues.

No. 983*c*.

(1) J. F. Hempel, Baltimore, Maryland.
(2) B 103 mm.
(4) The specimen consists of a naked fetus with flattened and distorted extremities. The eyes are receding and the face has the appearance of a mummy. The cord is irregularly shaped, thin and fibrous at some points and thick and mucoid at others. Most of the epidermis has fallen off.

No. 983*d*.

(1) J. F. Hempel, Baltimore, Maryland.
(2) B 97 mm.
(4) Specimen consists of placenta with unopened membranes, 100×74×55 mm. On opening the latter there was found a shrunken and distorted fetus.
(5) The villi are well formed and appear to be fibrous; between them there is some blood and occasional clumps of nuclear dust. The decidual layer is thin and is attached to the tips of the villi by means of a fibrinoid substance. No active trophoblast is present in any portion of the sections.
(6) Decidua not infiltrated.

No. 996.

(1) H. B. Titlow, Baltimore, Maryland.
(2) A 72×60×30 mm.; B 100 mm.
(4) The specimen consists of placenta, membranes, and fetus. The uterine surface of the placenta is pearly white, hard, and corrugated. On cutting this surface it was found to be covered by an external layer about 1 mm. thick, of a firm cartilaginous substance. The cord was twisted excessively, and the extremities flattened and distorted.
(5) Sections through the chorion at the attachment of the cord show that the villi are fibrous, and that large nodules of trophoblast have undergone fibroid degeneration and contain plaques of nuclear dust. Some of the villi are attached to the decidua, which contains several well-defined small abscesses.
(6) Decidua infiltrated.

No. 1014.

(1) M. Ostrow, Baltimore, Maryland.
(4) The specimen is an unopened conceptus about 8 inches in diameter. The uterine surface of the placenta was gristle-like in consistency and the membranes opaque. The amniotic fluid was brownish and the fetus contorted and macerated. The cord is decidedly tortuous.
(5) The villi are non-vascular and very fibrous, with an especially degenerate epithelium which shows beginning calcification. Some of the larger vessels in the chorion are represented as solid fibrous areas, their lumina being entirely obliterated. Some fairly preserved blood is found between the villi, the stroma of which is represented by a translucent coagulum only. The decidua is too degenerate for further comment.

No. 1020.

(1) W. F. Twigg, Cumberland, Maryland.
(2) CR. 260 mm.
(3) The last menstruation occurred April 26 to 30 and abortion December 11. The patient declares she felt life September 30. No infection. Abortus is estimated to have been dead 10 days at least.
(4) Specimen is a macerated fetus with marked abdominal distention, suggesting ascites. It must have been

dead for some weeks, and this is indicated also by the relation of the menstrual age of 32 weeks and 5 days to the anatomical age of 29½ weeks.

No. 1027.

(1) H. B. Titlow, Baltimore, Maryland.
(2) 130×80×50 mm.
(4) The placental area of the chorion is firm and partly converted into a gristle-like substance. The remnant of the chorion is opaque and thickened, except for an area 40×50 mm., which is translucent. The chorion contains a brownish fluid and a brownish, macerated fetus with several turns of the umbilical cord around the neck. The extremities are very distorted.
(5) Microscopic examination of the placenta presents the picture typical of long retention. The vessels are largely degenerate. The epithelium is necrotic or wholly absent and the stroma fibrous and degenerate. In places growths of villi are matted and fused into a solid mass, forming the so-called "infarcts." The decidua also is very degenerate, but some fairly well-preserved blood still is contained in the intervillous spaces and also in some of the dilated villous vessels.

No. 1028.

(1) G. J. France, Baltimore, Maryland.
(3) Last menstruation occurred September 25 to 27, and abortion December 18.
(4) The specimen is a very badly macerated and distorted fetus with compressed and twisted extremities, and portions of the body barely recognizable.
(5) One of the umbilical vessels (apparently an artery) is almost completely obliterated, while the other two vessels show little change. Perivascular infiltration is absent. In spite of the marked maceration and disintegration, the subcutaneous vessels still show in some of the digits, and the striations and voluntary musculature are splendidly preserved.

DESCRIPTIONS OF PLATES.

Plate 1.

Fig. 6. Old retained hydatiform degeneration. No. 323. ×1.25.
Fig. 7. Abnormal conceptus. No. 1843. ×6.
Fig. 8. Decidual cast containing remnants of conceptus. No. 698. ×1.
Fig. 9. Festoons of chorionic epithelium. No. 1324. ×300.
Fig. 10. Detached conceptus, still *in utero*. No. 1224. ×6.
Fig. 11. Almost total lysis or gossamer form. No. 606. ×69.

Plate 2.

Fig. 12. Villi showing hydatiform degeneration. Same specimen as fig. 10.
Fig. 13. Hydatiform tubal twins *in situ*. No. 825. ×3.
Fig. 14. A fine hydatiform villous tree in section. No. 367. ×10.
Fig. 15. Full-term nodule accompanying a twin donated by Dr. Slemons. No. 1682. ×1.1.
Fig. 16. An unusual nodular form. No. 2288. ×6.
Fig. 17. Reniform nodular cyema. No. 1369. ×4.
Fig. 18. Cross-section of a nodular cyema, showing simple structure. No. 651*g*. ×10.
Fig. 19. External appearance of chorion containing small nodular twin. No. 788*b*. ×1.15.

Plate 3.

Fig. 20. Cross-section of No. 788*b*, shown in fig. 19. ×45.
Fig. 21. Macerated normal cyema, No. 788*a*, companion to 788*b*. ×1.
Fig. 22. Divergence in external form of cylindrical cyemata. No. 885. ×4.
Fig. 23. Illustrating marked changes in form and structure of cylindrical cyemata. No. 446. ×6.
Figs. 24–26. Illustrating variation in form of cylindrical cyemata. Nos. 2236 (×9), 2222 (×6), and 1776 (×6).
Fig. 27. Longitudinal section showing structure of cylindrical cyema. No. 150. ×15.

Plate 4.

Fig. 28. Longitudinal section of cylindrical embryo. No. 489. ×37.5.
Fig. 29. A cyema in the pre-gossamer stage of lysis. No. 2197. ×6.75.
Fig. 30. Twin conceptus with larger chorion opened and location of smaller indicated. No. 587. ×0.75.
Fig. 31. Part of the same conceptus in section, showing the cavities of both chorionic vesicles. ×1.5.
Fig. 32. Side view of cyema, showing so-called stunting. No. 2173. ×3.
Fig. 33. Front view of same specimen, showing maceration and stunting. ×3.
Fig. 34. Illustrating stunting. No. 2233. ×4.5.
Fig. 35. External view of No. 2473, showing stunting in an older specimen. ×3.
Fig. 36. Section of a similar fetus, to show structure. No. 675. ×4.5.
Fig. 37. Sagittal section illustrating fusion of mandibular margin with chest. No. 788*a*. ×4.5.
Fig. 38. Sagittal section showing internal maceration changes and gaping of the mouth. No. 983*a*. ×4.5.
Fig. 39. Macerated, firmly rolled-up, young fetus. No. 921. ×2.25.
Fig. 40. Macerated, rolled-up, older fetus. No. 1041. ×0.75.
Fig. 41. Cyema classed as fetuses compressus. No. 1245. ×3.

Plate 5.

Figs. 42–50. Various forms of cyemata classed as fetus compressus: Nos. 1463 (×2), 1806 (×1.5), 1301 (×8.5), 1513 (×0.58), 1495c (×0.58), 896 (×.55), 1925 (×.65), 1239 (×0.55), 1515 (×0.58).

Fig. 51. Distortion due to maceration and retention *in utero*. No. 1931. ×1.

Figs. 52–63. Illustrating the absence of fundamental differences between the group of fetus compressus and grade 3 of the normal specimens.

No. 1295b (fig. 52) pathological. ×1.5.
No. 532 (fig. 53) normal. ×1.8.
No. 1475 (fig. 54) pathological. ×1.5.
No. 852 (fig. 55) normal. ×2.
No. 1750 (fig. 56) normal. ×1.5. (To be compared with No. 1806, fig. 43.)
No. 1779 (fig. 57) normal. ×1.
No. 651a (fig. 58) pathological. ×1.
No. 1513 (fig. 59) pathological. ×0.58.
No. 1350 (fig. 60) normal. ×0.58.
No. 1474a (fig. 61) normal. ×0.58. (To be compared with No. 896, fig. 47)
No. 1758 (fig. 62) pathological. ×0.5.
No. 1532 (fig. 63) normal. ×0.5.

Fig. 64. Fusion of epidermis on lower extremities during maceration. No. 1859. ×0.5.

Fig. 65. Epidermal thickenings. No. 316. ×7.5.

Fig. 66. Early drooping and distortion of extremities. No. 1710. ×1.

Fig. 67. Showing diversity in position and distortion of extremities. No. 1751. ×0 5

Fig. 68. A similar but younger specimen. No. 1931. ×1.

Fig. 69. Distortion of digits. No. 1751. ×1.

Fig. 70. Unilateral maceration bleb on cord. No. 1523. ×0.5.

Fig. 71. Bleb formation on neck, same specimen. ×1.

Fig. 72. Bleb formation in whole nuchal region. No. 2261. ×1.5.

Plate 6.

Fig. 73. Nodular fibrosis of the amnion. No. 868. ×1.35.

Fig. 74. Nodular fibrosis of the amnion. No. 1048. ×0.66.

Fig. 75. Large, clear, normal decidual cells. No. 1599. ×200.

Fig. 76. Maceration, hemorrhage, and lysis, with early transformation of the decidua. No. 872. ×200.

Fig. 77. Further transformation of the polygonal decidual cells into the spindle and fibroblast type of cells. Same specimen as figure 76. ×200.

Fig. 78. Longitudinal section of right ovary, showing carcinomatous nodule to the right. No. 865. ×2.

Fig. 79. Same specimen. Portion of carcinomatous nodule. ×27.

Fig. 80. Left ovary from same case in longitudinal section, showing disk-shaped teratoma in section. ×2.

Fig. 81. Teratoma in section, same case. ×11.5.

Fig. 82. Remarkable vascular proliferation in the chorionic membrane. No. 309. ×120.

6

7

8

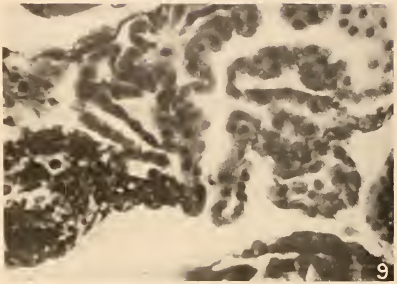
9

10

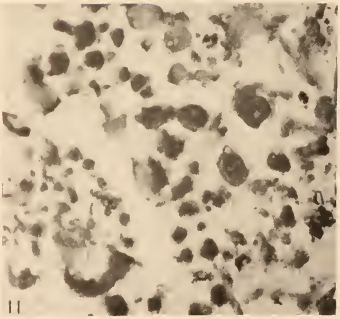
11

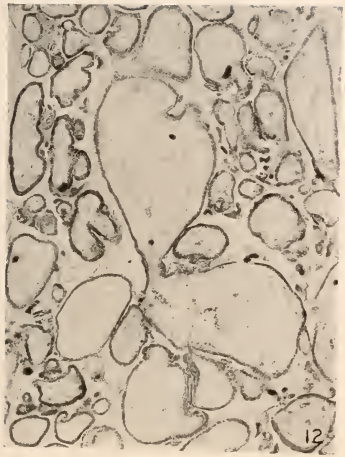

12

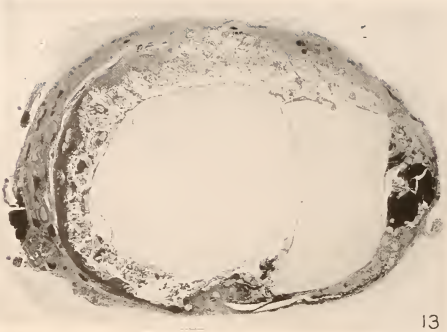

13



14

15

16

17



18

19

20

21

22

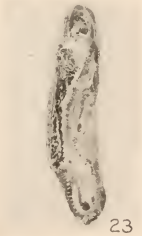

23

24

25

26

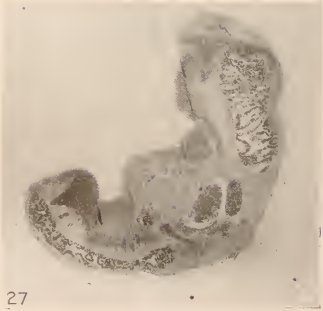

27

28

29

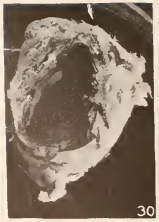

30

31

32

33

34

35

36

39

37

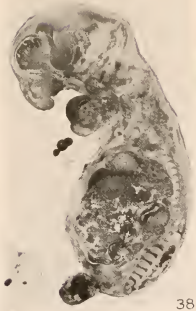

38

41

40

42

43

44

45

46

47

48

49

50

51

52

53

54

55

56

57

58

59

60

61

62

63

64

65

66

67

68

69

70

71

72

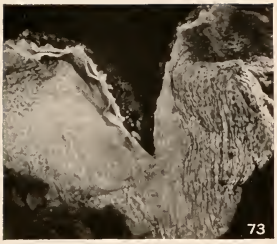
73

74

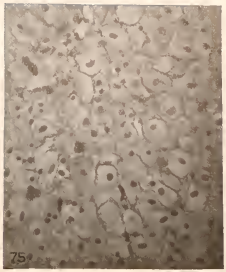
75

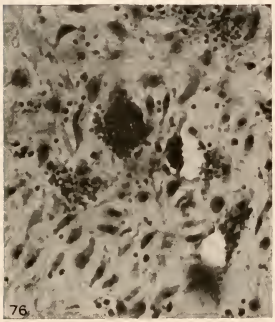
76

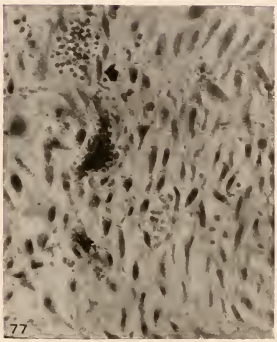
77

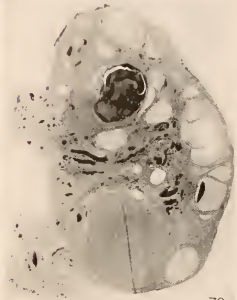
78

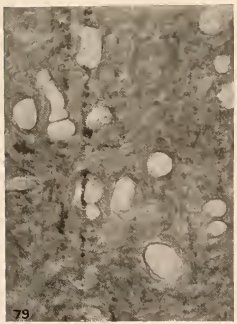
79

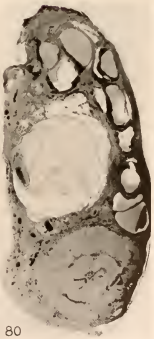
80

81

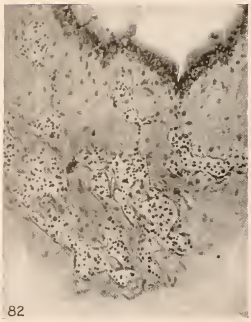
82

CHAPTER V.

THE RELATION OF CYEMIC TO CHORIONIC SIZE.

The occurrence of hydramnios indicates that in some specimens the relation of cyemic to chorionic size must vary considerably for this reason alone. This could fail to be the case only if hydramnios could be recognized in its beginning, so that such specimens could be excluded. Moreover, since we are as yet unable to recognize the earliest regressive changes in the cyema, this fact too would increase the range of variation in specimens which might be regarded as normal, at present. If we consider specimens classed as pathologic in the Carnegie Collection, the disproportion between cyemic and chorionic size would of course be very much greater. This variation, in fact, is over 800 per cent. Since the cyema may be extremely abortive and evidently also disappear entirely, disproportion between cyemic and chorionic dimensions might be extremely great in these specimens also. But even aside from these considerations, the relation between chorionic and cyemic size can not be constant throughout gestation unless the shape of the conceptus were invariable. But we know that such is not the case, for the greater growth in length of the fetus, placental development, the formation of the chorion læve, and other matters, all tend to change the form of the conceptus. It is true that regression of the villi in the region of the chorion læve would be compensated for to some extent by placental formation on the other side of the vesicle, but in such large specimens the extrauterine change in form will be considerable and thus increase the fluctuation in the measurements. However, it is very probable that the closest correlation exists between cyemic and chorionic size, during the early stages of development, when the conceptus probably is still more nearly spherical. During this time the conceptus also undergoes but little change in form during measurement under proper extrauterine conditions; but even at this time the villi always will be a decidedly variable factor in all external measurements of the chorionic vesicle. Hence it would seem that satisfactory results for a comparison of chorionic and cyemic dimensions probably can not be obtained without taking those of the chorionic vesicle regardless of the villi. Such measurements, however, can not be made accurately without bisecting the vesicle.

I do not know whether the increase in amniotic fluid is very constant or not, but if its volume changes disproportionately, even if not independently of the length of the cyema, this fact would introduce another variable and so further obscure the real correlation in size between the cyema and its chorionic vesicle. In addition to all these things, there are, of course, the normal variations in growth and the changes in form effected during parturition and fixation, for very few abortuses are obtained and measured when fresh. Besides, the vesicle and the cyema no doubt vary independently of each other in growth, so that a very broad basis becomes necessary before a reliable comparison between the two can be made. For all these reasons, then, it would seem that the volume, or, better still,

the weight, of the empty chorionic vesicle and that of the cyema would be more reliable data for a determination of a correlation between the two.

Very few data on this matter are available to us in the literature and we must bear in mind that it is not yet possible to distinguish between the early normal and the abnormal. Whether or not the relationship between the dimensions of the cyema and the chorionic vesicle can be used, as suggested by Giacomini (1894), for distinguishing between the normal and abnormal, it is impossible to say at present. But even if such a criterion can not be obtained, a comparison between the size of the cyema and the chorionic vesicle nevertheless may reveal fluctuations in the one or the other, or in both, which might otherwise be overlooked.

Without reference to the excellent older observations of Velpeau (1855), His (1882) concluded that chorionic was related to amniotic size in early specimens, as shown in the accompanying table.

Embryo.	Chorion.
mm.	*cm.*
2 to 4	less than 1.5
4 to 10	1.5 to 3
10 to 15	2.5 to 4
15 to 20	3.5 to 5
20 to 25	4.0 to 6

Giacomini stated that embryos with a length of 2 to 4 mm. are contained in vesicles 1.5 cm. long; embryos 4 to 10 mm., in vesicles 1.5 to 3 cm.; embryos 10 to 18 mm., in vesicles 2.5 to 4 cm.; embryos 15 to 20 mm., in vesicles 3.5 to 5 cm.; and embryos 18 to 20 mm., in vesicles 4 to 6 cm. long. Giacomini also stated, as did His (1882), that the amnions of embryos less than 10 mm. long invest the latter closely and His further stated that the amnion is 1 to 3 mm. distant from embryos 11 to 15 mm. long and that it had fused with the chorion when the embryo had gained a length of 2.5 cm. Schaeffer (1898) stated that embryos 1.15 mm. long are contained in vesicles of 2.5 to 2.7 cm.; embryos 3 mm. long in vesicles of 2.5 cm.; and embryos 8 mm. long in vesicles 7.5 to 8.5 cm. J. Kollmann (1898) gave the relation of chorionic to embryonic size the same as His. Since His and Kollmann give only one chorionic measurement, it is impossible to surmise what their conception of the form of the chorionic vesicle was, but His's table suggests that the relation between embryonic and chorionic length varies from 1–5 to 1–2 by the time the embryo has reached a length of 2 cm.

Eternod (1909[a]) emphasized the fact that the conceptuses described by Reichert, Ahlfeld, and by himself, all were lenticular in form and also flattened somewhat upon one of their faces. The same thing is true of those reported by Bryce and Teacher, Peters, von Spee, and also of some other specimens. Eternod stated that while early conceptuses are lenticular, they later become ovoid, and still later more spherical. According to Eternod, the portion toward the basalis is flattened the most, while that toward the capsularis is more curved.

Since some of the conceptuses called lenticular by Eternod are so very small, their shape scarcely can be attributed to the influence of the surrounding musculature. Hence it would seem that the human conceptus soon loses the inherent sphericity undoubtedly possessed by the ovum. If, as Eternod thought, the villi of early conceptuses are zonal or annular, with two free surfaces which he designated as dorsal and ventral, a further source of variation in the measurements of young specimens would be introduced.

Evans, in an undated circular issued by this laboratory, gave the length of the embryo and the size of the chorionic vesicle as indicated in table 5. Such tabulations as these are very helpful and suggestive and are bound to gain much in value with enlargement of the data upon which they are based. This table from Evans indicates that the conceptus of the third week practically is spherical, that it then rapidly becomes oblong so that its greatest diameter is almost twice that of the second dimension by the fourth week, and that it returns to a more spherical condition in the sixth, seventh, and eighth weeks, during which time its greatest dimension is indicated as only one-sixth longer than the second dimension. Upon comparing the length of the cyema with that of the conceptus as given in table 5, we find that the greatest dimension of the latter is 10 times that of the former in the third week. The greatest dimension of the chorionic vesicle is approximately 6 times that of the embryo in the fourth week; 4.5 times in the fifth week; 3 times in the sixth week; 2.2 times in the seventh; and 1.4 times in the eighth. From this it is seen that there is a rapid and early approximation between the greatest dimension of the chorionic vesicle and the length of the cyema. This might be expected from the fact that growth in length of the cyema is so much greater than growth in the other two dimensions. The irregularities evident in this table probably are attributable to the small series available for the tabulation, to the fact that all measurements of necessity had to be made postpartum, and that they were not made by the same individual.

The exact form of the human conceptus in its early stages still remains unknown, but as indicated by specimens from the literature, it is probably spherical. This sphericity, however, must be lost as soon as the conceptus extends across the uterine cavity or when the cyema reaches a length which brings its cephalic and caudal extremities closer to the chorionic membrane than are the rest of its surfaces. From this time on we might expect the form of the conceptus to become more and more elongated and ovoid. It may be recalled that one of Leopold's specimens of early conceptuses was represented as ovoid or as almost cylindrical even, but one must bear the possibility of molding during abortion and of postpartum distortion in mind. However, it often is difficult to detect elongation attributable to molding during labor, even in conceptuses of considerable size. Conceptuses up to 4 and 5 cm. in greatest dimension usually assume a flattened, ovoid form when placed in fluid of approximately the same specific gravity. One might, I presume, suppose that after the first weeks all conceptuses have a more or less cylindrical form, in consequence of the shape of the uterine or tubal cavities, but the form of early guinea-pig conceptuses throws doubt upon this supposition. They are quite spherical, and the same thing is true of young rabbit conceptuses, even when they have considerably distended the thin-walled cylindrical uterine cornua by reaching a size of one centimeter.

What is needed, however, is a careful series of measurements on selected material, although even such material will not be ideal as long as we remain unable to differentiate early normal from abnormal forms and as long as not all measurements are made either on fresh or on fixed material. Hence it is evident that the

field and graph shown in Chart 1, although made upon the basis of selected normal material from the Carnegie Collection, supplemented by data from the literature, probably can not give us anything more than a very rough approximation of a portion of a curve illustrating the relation between cyemic and chorionic size during the first month.

Among the cases used for this graph there are a few in which the cyemic length is somewhat greater than the greatest chorionic measurement. This may be due to the fact that the chorionic vesicle was measured after it was opened and fixed. It is always diffcult to restore the form of opened chorionic sacs in fluid, even with the greatest care, unless they are coated with blood and decidua so that their walls are stiffened.

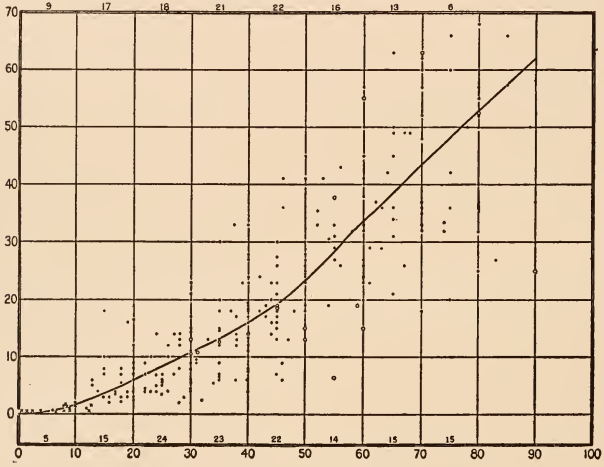

Greatest dimensions of chorion in millimeters.

CHART 1.—Field and graph showing correlation between cyemic and chorionic size, based on the 255 selected normal specimens. Uterine specimens indicated by dots, tubal by circles.

In some instances conceptuses with different menstrual ages have the same size, a fact which not necessarily finds its explanation in the existence of normal growth differences, but rather in the earlier death of one cyema or conceptus. Other discrepancies between the length of the cyema and the dimensions of the chorionic vesicle may be due to distention of the latter after death of the former, or possibly to actual growth of the chorionic vesicle after the death of the embryo. It is fortunate that we possess a double check on our data, for we can consider the relation of the size of the ovum and the cyema independently, and also can compare each with the menstrual age.

Since the number of conceptuses with embryos of the first month which have been measured is exceedingly small, any curve based on these data necessarily must remain largely conjectural. However, if we regard it as purely tentative, even such a curve nevertheless may be of value. Moreover, its obvious incompleteness will prompt to improvement. As will appear from Chart 1, only 16 cases were available for the construction of the curve for the first month; 8 of these were from our own collection, 8 from the literature. One of the two embryos, 2.5 mm. long, belongs to a vesicle which is entirely too large and hence falls high on the chart. On consulting the history of the case it was learned that the conceptus was decidedly collapsed and hence very probably distorted. But this is not the only specimen which shows considerable disproportion between the size of the cyema and the conceptus. I do not imply, however, that these disproportions represent wholly normal variations, although until a large series is available for study it will remain impossible to determine the deviation from the average of normal specimens in a given state of development.

The field represented in Chart 1 was plotted from measurements of chorionic vesicles and cyemata below the fourth month, which are listed as normal in the Carnegie Collection. It includes both uterine and tubal specimens; the former are represented by dots and the latter by circles. In addition to these specimens the measurements of 12 young conceptuses from the literature have also been added; these are represented by crosses. Since scrutiny of the fields made by the use of other than only the greatest dimension of the chorionic vesicle made it evident that the other dimensions were quite useless as criteria, only the greatest measurement was used for the construction of the field as here represented. The greatest dimension of both cyema and chorionic vesicle is represented in millimeters--the former on the ordinate and the latter on the abscissa.

Reference to the location on the field of the cases from the literature, and also an inspection of the beginning of the curve, show that the chorionic vesicle forges ahead of the cyema in its growth. This is what one would expect, for embryonic differentiation naturally must be delayed at the start. However, the specimens of conceptuses with a measurement of less than 10 mm. are too few to enable one to regard this part of the curve as more than an approximation of the actual. Between a length of 10 and 20 mm. a considerably larger number of cases are found, and here the curve is more reliable, although considerable scattering of the cases nevertheless is present. To what extent this scattering is due to variations to growth, and to what degree to the fact that the material was perhaps not strictly fresh or normal, it is impossible to say; probably both factors are involved. Moreover, since the chorionic measurements were external, the condition and length of the villi introduce a further factor of fluctuation; for although the average dimensions of normal villi may fluctuate very little in length when large series of conceptuses are concerned, they do vary considerably, not only in different but also in the same specimen. This is especially true when the period of placental differentiation is reached. Hence measurements of the cavity of the chorionic vesicle or those taken from the wall of the bisected vesicle would give

far more reliable data, because the variations in thickness of the membranes are slight and one has then to contend only with the question of distention from hydramnios or other causes.

Since the curve is fairly regular throughout, and the disproportion of the cases but slightly greater as the older conceptuses are reached, I think it can be assumed that it is approximately correct in its general relations. With advancing age it is seen that the length of the fetus more and more approximates the greatest dimension of the chorionic vesicle. This is in agreement with common observation and shows that the greatest chorionic dimension no longer can be of any special value for determining the fetal age. Moreover, in older conceptuses the vesicle no longer retains its form.

Since the majority of the tubal specimens fall considerably below the curve, it is evident that development of the fetus was considerably retarded in these specimens. Only a few fall above the curve, but one of these is so very far above that one is compelled to conclude that the greatest dimension of the chorion was not obtained in this case, or the chorionic vesicle must have been torn and the amniotic fluid drained off. As will be noticed, the length of the fetus in this case exceeds that of the membranes in which it was contained.

From the curve it is seen that the relations apparently existing between the chorionic and cyemic dimensions are approximately those shown in table 6.

TABLE 5. (From Evans.)

Probable age in full weeks.	Standing height.	Greatest external dimensions of the ovum.
	mm.	*mm.*
3	0.5	5 by 4
4	2.5	14 by 9
5	5.5	24 by 17
6	11.0	34 by 29
7	19.0	42 by 36
8	30.0	52 by 44

TABLE 6.

Chorion.	Embryo.	Approximate ratios.	Chorion.	Embryo.	Approximate ratios.
mm.	*mm.*		*mm.*	*mm.*	
5	0.5	10.0	45	19.5	2.3
10	1.5	6.6	50	23.5	2.1
15	3.0	5.0	55	28.5	1.9
20	6.0	3.3	60	33.5	1.8
25	8.5	3.0	65	38.5	1.7
30	11.0	2.8	70	43.5	1.6
35	13.0	2.7	75	48.0	1.56
40	16.0	2.5	80	53.0	1.50

A comparison of the estimates on the accompanying graph (Chart 1) with the estimates of other investigators previously referred to shows that those of Evans agree most closely with these. However, the present curve can be regarded as provisional only, for it is based upon but 255 cases and upon external measurements alone.

CHAPTER VI.

SEX-INCIDENCE IN ABORTIONS.

By Adolph H. Schultz.

The numerical proportion of the sexes has always been a subject of great interest. The question whether man produces males and females in equal or unequal numbers bears a close relation to the problem of sex determination and must be studied in connection with the death-rate in different periods of life and the comparative sex-mortality. While sex-ratio is conditioned originally upon sex-determination, mortality may change it in the course of time. It will be shown herein that sex-ratio is not constant, but varies in the different periods of life and under manifold influences. Most of the information at hand concerning it is derived from statistics of the new-born and adult, but as regards intrauterine life, as far back as conception, our knowledge is limited to a few incomplete statistics and conflicting estimates. The main purpose of this study is to elucidate as far as possible this problem of the proportion of the sexes *in utero*, both living and aborted. The short review of the sex-ratio after birth, given herein, is intended to show the fluctuations in the numerical proportion of the sexes throughout life and may serve for a comparison of the relative mortality before and after birth. The last part of the study is a compilation from the literature of factors which may possibly have an influence on the original sex-ratio and of conditions which may change it during the course of prenatal life.

In view of the generally accepted supposition that sex is determined either before or at the time of fertilization, one may speak of a sex-ratio at conception or a sex-ratio of fertilized ova. This may also be called an original, physiological, or *primary* sex-ratio; the sex-ratio of the new-born may be termed *secondary* and, finally, that of adults is the *tertiary* sex-ratio. The latter term, in contrast to the preceding ones, does not apply to a definite time, such as conception or birth, but may be used collectively to designate the changing numerical proportion of the sexes after they reach maturity.

TERTIARY SEX-RATIO.

The consideration of sex-ratio in adults will be limited to generalities. According to Bücher (1892), for Europe the sex-ratio,[1] including all ages, is 97.6; for Asia 104.5; for Africa 103.3; for America 102.8; for Australia 117.4. However imperfect these computations may be, they nevertheless show that Europe, with its excess of females, occupies a unique position. There are only a few European countries with a greater proportion of men than women. Among the American negroes there is an excess of females, and among the American Indians an excess of males (Cummings, 1918). According to Brooks (1887), the Australasian colonies

[1] The most common method in use for representing the sex-ratio is to determine a number which indicates the proportion of males to every 100 females. Unless otherwise stated, this is the method used herein. The sex-ratio is also frequently termed *masculinity*.

had in 1881 a sex-ratio of 143.7 for the aborigines, and one of 118.6 for the population of foreign descent.

TABLE A.—*Number of females per 1,000 males.* (From Rauber.)

Age in years.	Austria, 1869.	England and Wales, 1871.	France, 1872.	Germany, 1875.
25 to 30	1,087	1,111	1,017	1,059
30 to 40	1,074	1,092	991	1,046
40 to 50	1,089	1,081	996	1,052
50 to 60	1,033	1,074	1,008	1,081
60 to 70	1,022	1,128	1,033	1,114
80 to 90	1,052	1,376	1,359	1,240

TABLE B.—*Changes in sex-ratio with advancing age.* (From Prinzing.)

Age in years.	Females per 1,000 males.	Age in years.	Females per 1,000 males.
0 to 5	993	40 to 45	1,045
5 to 10	998	45 to 50	1,067
10 to 15	995	50 to 55	1,121
15 to 20	995	55 to 60	1,140
20 to 25	1,008	60 to 70	1,189
25 to 30	1,008	70 to 80	1,259
30 to 35	1,014	80 to 90	1,338
35 to 40	1,020	90 to —	1,751

Table A, taken from Rauber (1900), represents the number of females to every 1,000 males in some of the European countries. As will be noted, the excess of females increases with age. This is still more clearly shown in table B, from Prinzing (1905), taken from the census of 1900 in Germany. Inasmuch as in Europe sex-ratio at birth favors males, its subsequent decrease must be the result of a greater mortality among the latter, and also, in some countries, of a greater emigration of males. The unequal mortality is shown in table C, from Ploss (1887).

The sex-ratio of mortality may differ with age and under various conditions of life. For example, between the ages of 25 and 40 years (according to Knöpfel, 1907) in rural districts it is below, while among urban population it is above 100. A difference in the comparative death-rate of the sexes in city and rural populations is shown by table D (Baker, 1910, compiled from the United States census of 1900) to exist throughout life, but to vary at different ages.

TABLE C.—*Sex-ratio of mortality in European countries.* (From Ploss.)

Country.	Ratio.	Country.	Ratio.
Sweden	104	Spain	107
Russia (Europe)	105	Austria	108
Holland	105	Switzerland	108
Italy	106	Germany	109
England	107	Greece	111
France	107	Rumania	116

TABLE D.—*Excess of male death-rate (per 1,000 population) over female death-rate.* (From Baker.)

Years.	Urban.	Rural.
Under 1	31.6	27.4
Under 5	10.6	6.4
5 to 14	0.1	0.
15 to 24	0.7	−0.1
25 to 34	1.3	−1.0
35 to 44	2.1	−0.4
45 to 64	4.0	0.7
65 to —	7.6	6.3

Bell (1918), in his studies on the Hyde genealogy, found that during the years covering the child-bearing period the death-rate was greater among females than among males. His conclusions were based, however, upon comparatively small statistics. In opposition to this we have the more reliable conclusion of Willcox (1904) that, according to the life tables of several entire countries, the death-rate of women between 20 and 30 years of age (a period during which probably four-fifths of the child-births occur) was less than that of males of the same age.

SECONDARY SEX-RATIO.

The sex-ratio of the living-born for all European countries is, roughly averaged, 105 to 106, but this may vary markedly even in comprehensive statistics. Manifold explanations for these variations have been offered and these will be considered briefly farther on. In the individual countries small differences in the secondary sex-ratio may exist, as shown by table E, taken from a table by Ploss.

We have very little data concerning the sex-ratio of new-born among races other than white. Newcomb (1904) states that in Japan the excess of males in over 1,000,000 births was practically the same as in European countries. According to the same author, it seems probable that among the negroes of the United States there is a slight excess of female births. In a table by Nichols (1907) one finds the following sex-ratios among the living-born of primitive races: Japan (1877–1902), 104.7; India (1891–1900), 107.5; negroes of United States (1900), 99.8; and an average since 1880 of 100.9.

TABLE E.—*Secondary sex-ratio.* (From Ploss.)

Country.	Ratio.	Country.	Ratio.
Russian Poland	101	Sweden	105
England and Ireland	104	Denmark	105
France	105	European Russia	105
Germany	105	Italy	106
Switzerland	105	Austria	106
Belgium	105	Massachusetts	106
Holland	105	Spain	107
		Connecticut	110

TABLE F.—*Sex-ratio of mortality during first year of life.* (From Prinzing.)

Country.	Ratio.	Country.	Ratio.
Italy	111	England	121
Rumania	115	Sweden	121
France	119	Denmark	121
Austria	119	Norway	123
Switzerland	120		

As a result of the unequal mortality of the sexes, this secondary sex-ratio becomes reversed early in life. Kroon (1917) states that in Holland the sex-ratio of mortality during the first year of life is 119; that is, the mortality among male infants is greater by one-fifth than among females; also, that during the first two months of life this ratio reaches even 139. Analogous numbers for the first year of life are given in table F (Prinzing, 1906).

Kroon's statistics show that this high ratio of mortality of the first year of life soon undergoes a decrease, reaching its minimum (approximately 80) between the fourteenth and fifteenth year. According to Prinzing (1905), and also Willcox (1904), the mortality from the ages of 5 to 20 years is greater in females, and indeed in the latter part of this period it is the result chiefly of tuberculosis, for which disease the common occurrence of anæmic and chlorotic conditions at the time of puberty furnishes an excellent soil. After this age the sex-ratio of mortality increases rapidly and results in the reversion from an excess of males to an excess of females, and the higher the death-rate the earlier will this reversion take place, the death-rate being influenced by various factors. It can be said, for instance, that as a general rule the death-rate of infants is especially high in countries with a high birth-rate, such as Russia and China. This, in connection with the high sex-ratio of infantile mortality, will tend to decrease very rapidly the sex-ratio of the surviving infants.

PRIMARY SEX-RATIO.

The sex-ratio of fertilized ova can not be determined directly; however, there is an indirect method of solving the problem of the original sex-ratio by means of computing the mortality of cyemata.[1] In case the sex-ratio of fetuses dying *in utero* is equal to the secondary sex-ratio, then only will the latter and the primary sex-ratio be equal. If the number of males and females that were aborted or still-born were absolutely the same, then the primary would be lower than the secondary sex-ratio. If, however, the sex-ratio of mortality during pregnancy exceeds the sex-ratio of the living-born, then the primary sex-ratio must of necessity be greater than the secondary, and indeed increasingly so as the total intra-uterine mortality becomes relatively greater. It is necessary, therefore, to consider two factors in order to deduce the primary sex-ratio from the secondary: (1) The sex-incidence in abortions, and (2) the relative frequency of abortions. Both of these factors—*i. e.*, the sex-ratio and the relative rate of mortality—differ in the various periods of pregnancy, thus complicating the calculation of the primary sex-ratio. I have endeavored to gather from the literature estimates and statistics concerning the intrauterine mortality, beginning with the relative frequency of still-births and abortions.

The relative number of still-births differs to some extent according to the various authors. This is in part explained by the fact that the statistics are taken from different countries and at various times. Von Winckel (1903) reported that in Berlin, during a period of 70 to 80 years, the number of still-born males varied from 3.2 to 7 per cent of all births, that of females from 2.5 to 5.5 per cent. Rauber states that in Germany the still-births amount on an average to 4 per cent of 1,800,000 annual births. According to Carlberg (1886), the proportion of still-births to the total number of births in Livland lies between 2.58 and 2.90 per cent, while the percentage for western Europe lies between 4 and 4.5. According to Prinzing (1907), from 1891 to 1900 the following proportions of still-births occurred in every 100 births: Austria 2.9, Switzerland 3.6, Italy 3.9, Holland 4.3, Belgium 4.5, France 4.6. These figures are somewhat increased when expressed in percentage of the living-born. Computing from Auerbach's (1912) statistics of over 100,000 births in Budapest, the still-births amounted to 3.3 per cent of the living-born. Bucura (1905) found that among 40,169 births in the Clinic Chrobak in Vienna, 5.8 per cent were still-born; Le Maire (1906) found 5.7 per cent among 40,339 births in Copenhagen. Both of these figures are too high, inasmuch as these authors did not use the term *still-born* in the usual sense, a small number of abortions being included. Nichols (1907) quotes the following figures from registries of vital statistics: 3.6 per cent of total births of whites in the United States are still-births, and among the negro births of the District of Columbia 13.8 per cent are still-born. The percentage of still-births in Japan is 8, according to the same source. These figures from Nichols also include abortions, but inasmuch as these are not nearly so regularly reported as miscarriages in the last few months of pregnancy, they do not considerably increase the percentages.

[1] I use the term *cyemata* as a collective name for fertilized ova, embryos and fetuses. (See Meyer, 1919.)

The relative number of abortions is extremely difficult to determine, inasmuch as everywhere large numbers of them, especially of the earlier months, remain unknown, and even the most careful statistics will always be far from complete. The most reliable source of information is probably the estimate of the experienced obstetrician. Williams (1917) expresses himself on the question of frequency of abortions as follows:

"A conservative estimate would indicate that about every fifth or sixth pregnancy in private practice ends in abortion, and the percentage would be increased considerably were the very early cases taken into account, in which there is profuse loss of blood following the retardation of the menstrual period for a few weeks."

Other authors give different estimates. Franz (1898) found 15.4 per cent of pregnancies ending in abortion; Malins (1903) found 19.23 per cent; Taussig (1910) estimates that one abortion occurs to every 2.3 labors; Pearson (1897) one to every 2.5 labors; Mall (1910) calculates that there is one abortion to every 4 births at term; Ahlfeld (1898) estimates the same proportion; Whitehead (1848) assumes that every seventh pregnancy is interrupted by abortion, and states later on that only 13 per cent of married women who reach the end of the child-bearing period escape having an unsuccessful pregnancy. Auerbach (1912) reports that, according to estimates for Berlin, abortions amount to one-sixth to one-tenth of the number of living-born. According to the same author, in Budapest, from 1901 to 1905, there were 111,139 living born, and from 1903 to 1905, 7,702 abortions. Assuming an approximately equal number of living-born for each year, they would amount to 66,678 for the years 1903 to 1905, the proportion of abortions to this number of living-births being 11.55 per cent. This percentage is doubtless too small. Auerbach himself assumes that many abortions of the earlier months are concealed. Under certain circumstances the proportion of miscarriages and abortions may increase tremendously. Bluhm (1918) reports that among working women in Berlin in 1915 and 1916 there were 190 abortions to every 100 full-term births, and attributes this partly to the harmful occupations in factories.

From these quotations it would seem most probable, on a rough average, that out of every 100 fertilized ova only 78, or even less, develop to term, the remainder being aborted. This intrauterine mortality may appear to many to be very high, but if we consider that during infancy this waste of life continues unabated the above estimate will not seem so improbable. Infant mortality during the first year of life varies in different countries; according to Phelps (1910), from slightly below 10 to 27 (in Russia) per 100 living-born; *i. e.*, the number of infants dying within the first year of life may be more than one-fourth the number of living-born.[1]

It appears that the frequency of abortion is greatest in the first three months of pregnancy. Auerbach, in considerable material, found that half of the abortions fell within that period, yet it is for this period that our statistics are most incomplete. In reality, therefore, more than half the number of abortions must occur in the first three months. According to Franz, 42.6 per cent, and according

[1] In the registration area of the United States in 1900 there were the following death-rates for infants under 5 years of age (Billings, 1904): White: males 5.33, females 4.43; negroes: males 11.85, females 10.58 per 100. In the negro race infant mortality is more than twice as high as in whites.

to Dührssen, even 59 per cent of abortions occur in the third month alone. Nichols tabulated the relative frequency of abortions and still-births at different periods of pregnancy from extensive statistics of Paris, Brussels, and the District of Columbia. Table G is based on this table by Nichols, the figures representing the percentages of the total number of abortions and still-births. These statistics are quoted for the sake of completeness and not because the writer believes that they represent the actual conditions; all that they show is that the farther back we go into fetal development the less regularly are abortions reported. There can be no question, for instance, that the abortions occurring in the third to the fifth month inclusive amount to very much more than 11.6 per cent of all the intrauterine deaths, and yet this percentage is given for the whites of the District of Columbia.

TABLE G.—*Percentage distribution of abortions in different months of pregnancy.* (Adapted from Nichols.)

Month.	Paris.	Brussels.	District of Columbia.	
			White.	Negro.
	p. ct.	*p. ct.*	*p. ct.*	*p. ct.*
Third.....	27.5	10.8	5.2	7.2
Fourth.....		16.2		
Fifth.....	7.2	15.3	6.4	7.4
Sixth.....	12.0	2.3	10.7	12.4
Seventh....	14.9	55.4	14.2	15.2
Eighth.....	11.4		14.6	15.6
Ninthorover	27.0		48.9	42.2

TABLE H.—*Sex-ratio of still-born.* (From Morgan.)

Country.	Ratio.	Country.	Ratio.
Norway.....	124.6	Denmark.....	132.0
Holland.....	127.1	Belgium.....	132.0
Germany.....	128.3	Austria.....	132.1
Hungary.....	130.0	Switzerland.....	135.0
Italy.....	131.1	Sweden.....	135.0

Scattered through the literature are reports on the sex-ratio of abortions. Those concerning the numerical proportion of still-births are more numerous and more reliable than those relating to younger fetuses and embryos that have been aborted. The sex-ratio of the still-born is much higher than that of the living-born. Table H, taken from Morgan (1913), gives the sex-ratios of still-born for some of the European countries. According to Nichols, the sex-ratio in over 11,000,000 still-births in Europe was 134.2, being highest in Spain (152.3). In Japan ample statistics of still-births yielded the unusually low sex-ratio of 107, a proportion which is only a little higher than that for living-born. It should be mentioned that in the statistics used by Nichols still-births comprise "in the main fetuses of more than six months' gestation." Such high sex-ratios of still-born as that of Walter (260) or that of Tschuprow (400) are probably based upon relatively limited material and do not represent true ratios.

Auerbach gives detailed information concerning the sex-ratio of abortions. His material is distributed among the different months of pregnancy as shown in table I. The sex-ratio of abortions during the first three months he assumes to be at least equal to that of abortions in the fourth month, *i. e.*, 229. It seemed to him more probable, however, that it increases in constant proportion, and he therefore estimates 322 for the third month and 452 for the second month. Nichols tabulated, by sex and period of gestation, large statistics of "still-births" comprising almost 60,000 cases from Paris (1891–1902), and 4,400 whites and 7,500 negroes from the District of Columbia (1874–1902). In these statistics neither

sex nor age determination is any too reliable, and the ratios in the different periods have therefore to be taken for what they are worth. Nichols's figures, in abstracted form, are given in table J. His conclusion is that the "ratio of male fetuses born dead is much the highest from the third to the fifth month; much lower from the sixth to the eighth month; and at term the ratio again rises." According to Carvallo (1912), the sex-ratio of abortions up to the fourth month is 250; this figure he calculated from the statistics of Paris in 1908. Körösy (1898)

TABLE I.—*Sex-ratio of abortions in different months.* (From Auerbach.)

Month.	Males.	Females.	Sex ratio.
Fourth	928	405	229
Fifth	645	396	163
Sixth	506	437	116
Seventh	402	348	116
Total	2,481	1,586	156.4

found the sex-ratio in 3,781 abortions to be 152.4 Pinard and Magnan (1913) report on 1,229 abortions, the ages of which are not stated. This material showed a sex-ratio of only 101.1. Rust (1902) also found the sex-ratio in 454 abortions from the first six months to be very low, *i. e.*, 101.8. It is apparent how greatly these figures vary. A new contribution towards the knowledge of the sex-incidence in abortions is therefore not valueless, especially as great care has been taken to determine age and sex.

TABLE J.—*Sex-ratio of abortions and still-births in different months.* (Adapted from Nichols.)

Month.	Paris.	District of Columbia.	
		Whites.	Negroes.
Third and fourth	176	145	122
Fifth	121	148	152
Sixth	117	111	124
Seventh	119	114	122
Eighth	123	106	112
Ninth and over	134	129	127
Average	134.8	123	124.9

TABLE K.—*Sex-ratio of 1,410 fetuses from different months.*

Month.	Total material.	Whites only.
Third	121.0	110.7
Fourth	117.5	122.0
Fifth	109.6	107.0
Sixth	87.5	88.4
Seventh	108.5	112.1
Eighth	133.3	123.5
Ninth and tenth	167.6	156.5

The last paper of the writer on this subject (1918) was based upon a relatively small amount of material; since then it has been more than doubled, increasing correspondingly the dependability of the conclusions drawn from it. The material in all consists of 1,410 fetuses, 1,249 of which are from the embryological collection of the Carnegie Institution of Washington. For data on 32 fetuses, I am indebted to Dr. Ingalls, and in addition I have made use of 57 fetuses published by Rauber and of 72 Filipino fetuses tabulated by Ruth (1918). Of this material only a small percentage is derived from induced abortions; the great majority were spon-

taneous ones and therefore represent the inevitable mortality. Age classification was based upon the sitting height (Keibel and Mall, 1910). Both normal and pathological fetuses were used in this study. These were for the most part white. In a limited number of cases no parental history was available; however, it is certain that a great majority of these also were white. Among the specimens other than white there is a preponderance of negroes, with a total of 201. The sex-ratios of these fetuses in the various months of pregnancy are given in table K. The pathological fetuses alone show a sex-ratio of 103.7, a proportion which indicates that the two sexes become pathological with about the same relative frequency. The sex-ratio of all the negro fetuses is 105.1, and of all the Filipinos 182.1. The material on which these latter ratios are based is, however, too small to draw any safe conclusion from them.

The greatest deviations in the ratios obtained by Auerbach and by Carvallo, on the one hand, and by the author on the other, occur in the third and fourth months, in which Auerbach found the ratios to be 322 and 229, and Carvallo 250. The author's corresponding figures are very much lower, namely, 121 and 117, respectively. The great excess of male abortions in the early months of pregnancy, as found by Auerbach and Carvallo, may find its explanation in the fact that in the statistics used by them the sex was determined by different individuals who had not the specialized knowledge necessary for such determination on young fetuses. The same source of error exists in case of statistics of abortions throughout whole countries as used, for instance, by Nichols.[1] Early in the differentiation of the external genitalia only the expert can state the sex with certainty. At this time, and even later, the inexperienced, misled by the size of the clitoris as well as by other factors, may erroneously determine the female fetus as male. Fewer errors would be made on specimens from the latter part of the third and the fourth months if only those definitely male were reported as such, and all the doubtful ones were designated as female. Even granted that larger statistics might raise the sex-ratio of abortions, the latter would never reach the high figures stated by Auerbach, by Carvallo, and assumed by others. Just as the sex-ratio of mortality following birth varies according to age, so it is found to be true during the prenatal period. The author's material showed a high sex-ratio in the third and fourth months. In the fifth to the seventh month it became very much lower, to rise again in the eighth to the tenth month, attaining a higher figure than in any previous period. An analogous changing of the sex-ratio of intrauterine mortality was found by Auerbach and by Nichols with only slight differences in the duration of the periods of high and low ratios, but with considerable differences in the ratios themselves. Nothing is known in regard to the sex-ratio of abortions during the first two months of pregnancy; however, that of the third month might be used hypothetically for this period. The author's material from the fifth to the seventh month shows an average of 101.9, but owing to the variability in the individual months it is quite probable that the number of male and that of female fetuses

[1] The writer had an opportunity to compare the death certificates of a large number of abortions and still-births with his own findings on the specimens themselves, and found a surprisingly high percentage of errors in sex determination in the certificates, sometimes even on full-term fetuses.

perishing during the period from the fifth to the seventh month is *relatively*, not *absolutely*, equal. At any rate, it is apparent that during the middle third of intrauterine development the excess of male abortions is much lower than at the beginning and at the end of pregnancy.

In order to make use of the above citations and figures in computing the primary sex-ratio, rough and approximately average values must first be established. The following appear to be most probable: For each 100 living-born, with a sex-ratio of 105.5, there occur in the eighth to the tenth month 4 still-births with a sex ratio of 130; in the fifth to the seventh month 7 abortions with a sex-ratio of 106; in the fourth month 2 abortions with a sex-ratio of 120; and from conception to the end of the third month 15 abortions with a sex-ratio of 125. This makes altogether 28 abortions and still-births to every 100 living-born; *i.e.*, 100 living-born to every 128 fertilized ova.[1] The primary sex-ratio found from these averages by simple mathematical operations is 108.74. The writer's last calculation of the primary sex-ratio (1918) resulted in 108.47. The very small increase in the corresponding value of the present study serves as a confirmation of the previous finding. The sex-ratio at conception was estimated by Bernoulli as 108.2. Slightly higher (108.7) is the ratio computed by Jendrassik (1911) from statistics collected by Bodio. Both of these figures are strikingly similar to that of the author. Lenhosséck (1903) estimates the primary sex-ratio as 111, Auerbach as 116.4, but the latter believes that it would reach at least 125 if corrections were made.

Even if these approximate averages, which will become more exact only when based upon more extensive, careful statistics, must be accepted *cum grano salis*, it may nevertheless be stated with certainty that more males (not exceeding 10 per cent) are conceived; that at certain periods of pregnancy the relative mortality of males exceeds that of females by as much as one fourth or more; and that this, in connection with the very high intrauterine mortality, especially at the beginning of pregnancy, serves to lower the primary sex-ratio considerably throughout prenatal life.

DETERMINATION AND CHANGES OF THE PRIMARY SEX-RATIO.

The question now arises as to what determines the sexes and their unequal distribution at conception. Its discussion dates back into antiquity; since Aristotle, philosophers and physiologists searched in vain for the key to this problem. The most fantastic theories were advanced, one of the oldest being that sex is correlated respectively with the right or left ovary or testicle (Hippocrates, Galen). In recent times much work has been done in trying to solve this problem. Among the most interesting theories stands the idea of the possibility of two distinct varieties of spermatozoa. Wilson (1905) distinguishes between male-producing and female-producing spermatozoa. This might lead to an unequal distribution of sexes at conception. Morgan (1913) suggested that it may be due to a difference

[1] The relative number of fertilized ova, estimated by Rauber to be 100 to 76 living-born or, calculated as above, 131.6 to 100 living-born, is somewhat larger than that obtained by the author.

in the rate of travel of the two types of sperm, or that a disease process, or a factor such as alcoholism, might affect one type to a greater degree than the other.

Hertwig (1912) attributes sex determination to the ovum or the degree of its maturation, an advanced stage of maturation producing males. In this way he attempts to explain the difference in sex-ratio according to social class. Thury (1863) proposed the idea that ova which are fertilized late may produce more males. Thus he explained the high sex-ratio among Jews who, on religious grounds, refrain from intercourse for 7 days following menstruation. Here may also be mentioned the recent investigations by Siegel on the relation of menstruation to sex, according to which coitus from the first to the eighth day after menstruation yields 86 per cent males; from the ninth to the fifteenth day it results in 65 per cent females; from the sixteenth to the twenty-second day, 85 per cent of conceptions are females, and in the remaining premenstrual period woman is practically sterile. Pryl and Jaeger, working independently, have confirmed Siegel's observations.[1] These findings contradict, in a way, those of Hertwig and Thury.

Lorenz (1898), Lenhossék (1903), and Orschansky (1903) are of the opinion that sex is sujbect to hereditary influences, inasmuch as they found families in which males predominated and those in which females appeared in excessive numbers. Newcomb (1904), Woods (1906), and Heron (1906) deny this and show that inheritance plays no part in the sex-ratio. Numerous authors attribute its variation to the absolute and relative ages of the parents. According to Rosenfeld (1900), there is a decided preponderance of male children born to young and old fathers, as compared with those of middle age. Francke, from the statistics of Norway, found this to be true in respect to young fathers, but reached an opposite conclusion as regards old ones. Dumont (1894) found for Paris a sex-ratio of 101.9 when the fathers were from 18 to 25 years, 104.2 when the fathers were between 25 and 50 years, and 97.5 when they were over 51 years. According to E. Bidder (1878), the sex-ratio of births by mothers under 18 and over 40 years is especially high, and Specht (1916) reports that the large majority of births by mothers under 16 years are male. Sadler (1830) stated that the relative ages of the parents determine the sex-ratio. The latter is 86.5 when the father is younger than the mother, 94.8 when both are of equal age, and reaches 163.2 when the father's age exceeds that of the mother by 16 or more years. Kollman (1890) obtained an opposite result, drawing the conclusion, which was based on extensive material, that the sex-ratio is high when the father is younger and low when he is older than the mother. At the same time he opposes the view that the absolute age of the mother has any influence whatever upon sex-ratio. Stieda, on the basis of his investigations, came to the conclusion that any influence on the part of the absolute ages of the parents is out of the question, as he noted the highest sex-ratio when the parents were of equal age. Numerous other authors have occupied themselves with the question of parental age as an influence upon sex-ratio, but only two additional ones will be mentioned, Boudin (1862) and Stadler (1878). The conflicting views which have been presented suffice to show that nothing

[1]These papers could not be obtained by the author, but are discussed by Nilsson.

definite is known concerning a correlation between the age of the parents and sex determination; in fact, such a correlation is hardly to be expected.

Pearl (1908), in a very careful study, demonstrated that there are more males produced when the parents are of different racial stock. The same effect of hybridization on the sex-ratio has been found by King (1911) for rats and by Guyer (1903) for birds. The well-known assertion that the sex-ratio rises after wars has evoked various attempts at explanation. The following few examples show best how little the different authors agree on this improbable relation. Ploss (1858, 1861) ascribes it to malnutrition of the mothers. Berner (1883) believes it to be due to the decreased competition which follows wars and which brings about an increased prosperity. Düsing sees the cause in the increased sexual demands upon the male, which is also said to increase the sex-ratio in polygamy. According to Newcomb, following the American Civil War of 1861–65 no increase in sex-ratio was observed. Nichols found no effect of war upon the sex-ratio in France from 1806 to 1872. On the other hand, Henneberg (1897) claims to have found such an influence; he reported that in Holstein, between 1835 and 1845, the sex-ratio was 105.76, and after the period of the war, from 1846 to 1853, it was 106.67. In the few cases where such a difference was confirmed, it was so slight as not to exceed the normal variations of the secondary sex-ratio (it is in the latter that any difference would be found) and therefore is to be considered as such. These natural variations were shown by Lehr (1889), Carlberg, Nichols, and others; they may be very considerable, as reported by von Winckel (1903), according to whom the sex-ratio of new-born in Berlin showed extremes in a period of 100 years of 104.79 and 100.64. Variations of sex-ratio have been determined not only for individual years and groups of years, but also for the seasons. According to Goehlert (1889), in autumn and winter relatively few conceptions take place, but of these a higher percentage is male. The same conclusion was reached by Sormani (1883). Inasmuch as the studies of these authors were based upon statistics of births, without consideration of the relative frequency of abortions, their conclusions in regard to the sex-ratio at conception must be treated with caution.

CHANGES IN THE SECONDARY SEX-RATIO.

The primary sex-ratio, as shown above, becomes transformed by an unequal intrauterine mortality of the two sexes into a different secondary ratio, and it is obvious, from a mathematical consideration, that the greater the proportion of abortions and still-births the lower will be the sex-ratio of living-born. Attempts have been made by a number of authors to explain the great mortality of males during certain periods of prenatal life. Carvallo simply says "les garçons sont plus fragiles"; Auerbach, also, considers the male fetus less resistant. Grassl (1912) gives as an explanation the supposition of a difference in the viability of the germ plasma. Jendrassik speaks of hereditary reduction of vitality among the excess of males. Ewart (1918) suggested that "it is possible—here, of course, we have no data—that the female conception may graft itself on the lining membrane of

the uterus more easily than the male." Rauber explains the greater mortality of males by the greater demands of the larger fetuses upon the mother, the latter not always being able to meet them; the production of a female does not require as much from the mother. Lillie (1917) offers the suggestion that the greater mortality among male fetuses is a result of disturbance of the equilibrium that protects the male from the sex hormones of the mother. These are all more or less plausible hypotheses lacking in proofs. As to any real understanding of the unquestionably higher mortality of male fetuses we are still at a loss; attention may be called, however, to the fact that this sexual difference in vitality and power of resistance against disease is not restricted to the period of intrauterine life, but is found also in the first few years of postnatal life, at which time occupation, child-bearing, and other factors can not be held responsible for the difference between the male and female death-rate.

The excess of male still-births is ascribed by most authors to the more difficult labor attendant upon the greater size of the male,[1] especially the circumference of the head. Dutton (1910) is of the opinion that at the time of birth the bones of the male skull are, as a rule, more firmly ossified than those of the female. He states also that with the advance of civilization the pelvic development in women is not proportionate to the cephalic development in infants. This perhaps explains the conclusion reached by Bluhm (1912), that the relative number of therapeutically induced premature births is increasing. That labor in case of male children more often demands artificial aid from the obstetrician than in case of females is shown by Prinzing, according to whom 6.18 per cent of male births in Württemberg called for operative measures, as compared with 4.67 per cent of the female births. This, however, is not due alone to the greater size of the male infant. Von Winckel found that in 566 new-born infants of over 4,000 grams weight operative aid was necessary in only 3 per cent more cases than in births of lighter babies. Furthermore, the more difficult labor of the larger male child can not in itself be held responsible for the high sex-ratio of still-born infants, inasmuch as, according to Treichler (1895), 29.6 per cent, and, according to Prinzing (1907), 32.6 per cent, of all still-births are premature, and in the sex ratio of these size plays but little part. According to Ladame (1904), in Switzerland the number dying during labor constituted only 36.4 per cent of the total still-births. Finally, Von Winckel found that the death-rate among 1,000 new-born of over 4,000 grams weight was only 4.17 per cent.

Sex-ratio has frequently been studied in relation to the pelvic diameters of the mother. The results are somewhat conflicting. Hoffmann (1887), Dohrn (1888), and Orschansky (1894) may be mentioned, according to whom the sex-ratio in children of mothers with narrow pelves is low. In contrast to this, Linden (1884) states it to be 133 in 360 births in which the mothers had narrow pelves. In case the size of the pelvis really has an influence, this can be exerted only upon the secondary sex-ratio in the way of elimination. In the same manner it seems evident that many of the factors which apparently affect the sex-ratio do not

[1] Von Winckel found among 1,000 new-born, of over 4,000 grams weight and 52 cm. length, a sex-ratio of 226.

influence it at the time of conception; that is to say, they do not have any sex-determining effect, but by their influence upon intrauterine mortality they change only the sex-ratio of the living-born. The well-known fact that the secondary sex-ratio among Jews is relatively high is explained by Düsing on the ground of incest, blood marriages being of frequent occurrence in that race. Schultze (1903), on the other hand, concluded that inbreeding has no effect upon sex determination and the same conclusion was reached by King (1918). Düsing, in his conclusions, failed to make a distinction between the sex-ratio at birth and that at conception; the latter is probably not different in Jews from what it is in other white races, but changes less by reason of the relatively fewer abortions and still-births among Jews, resulting in a higher secondary sex-ratio. The relative infrequency of abortions among Jews has been shown, for instance, by Auerbach. One finds frequently the assumption that the negro produces fewer sons than other races—another conclusion drawn from statistics of the new-born alone. Nichols pointed out that in the District of Columbia still-births and abortions among the colored population amount to 13.8 per cent of the living-born, whereas in the white it is only 6.5 per cent. This difference is responsible for the different secondary sex-ratios of the two races (103.1 in negroes and 106.2 in whites). Punnett (1903) and others have shown that the births among classes of lower social status present a lower sex-ratio than those of the rich. The explanation lies again in the fact that the greater frequency of abortions among women of the working classes, who can spare themselves less during pregnancy and in whom pregnancies occur in more rapid succession,[1] results in a corresponding reduction in the sex-ratio, which probably was originally equal in the two classes. In addition, this greater reduction of the primary sex-ratio in the poorer classes is due to their higher percentage of still-births. According to Conrad in Halle, among laborers it was 5 per cent, while among the upper classes it was only 2.1 per cent; and according to Verrijn Stuart (1901), in Holland, among the poor, it was 3.16 per cent and among the rich 2.5 per cent of all births.

A further example illustrating how the primary sex-ratio was erroneously thought to be influenced is shown in its difference in legitimate and illegitimate children. Heape (1909) states that the sex-ratio of legitimate births among the white population of Cuba is 109.0, still-births included; that of the illegitimate only 105.95. There is even a greater difference among negroes, the sex-ratio being 97.91 for illegitimate children and 107.73 for legitimate ones. Heape immediately draws the conclusion that illegitimate unions result more often in the conception of females than do legitimate ones. According to Düsing, the sex-ratio of legitimate births in Prussia, between the years 1875 and 1887, was 106.37; that of illegitimate only 105.54. The still-births in legitimate unions amounted to 3.91 per cent, in illegitimate ones to 5.32 per cent. A corresponding difference was demonstrated by Bertillon (1896) in the frequency of legitimate and illegitimate abortions. The greater mortality of illegitimate fetuses reduced the sex-ratio to a greater degree. The rule that the sex-ratio is greater in legitimate than in illegitimate births is

[1] According to Düsing (1884), the longer the intervals between births the higher is the sex-ratio.

not, however, without exceptions. Srdinko (1907) found that the sex-ratio of legitimate births in Austria was lower than that of the illegitimate, and explains this by the fact that the illegitimate are for the most part Jewish, in which race abortions are less frequent. Further exceptions are reported by Nichols in the case of England and Scotland. According to the last-mentioned author, there is an especially high sex-ratio in legitimate births as compared with illegitimate ones in Rhode Island (104.7 to 98.8), Portugal (107.1 to 100.5), and Greece (114.0 to 96.9). He, too, found a greater frequency of still-births and abortions in illegitimate pregnancies. Obviously, in such cases there is more concealment and consequently still less complete statistics are available than in the case of legitimate pregnancies ending in abortion.

According to a number of authors, the sex-ratio of first-born is greater than that of subsequent births, as demonstrated, for instance, in a table by Newcomb (1904). Lewis and Lewis (1906) report that in Scotland the sex-ratio of the first-born was 105.4, and that of subsequent births 104.8. The secondary sex-ratio is especially high as regards older primiparae, as shown by Ahlfeld (1872, 1876), Janke (1888), and Bidder (1893). That this is also due, in part at least, to different intrauterine mortality may be supported by the citation from Franz that abortions are more than twice as frequent in multiparæ as in primiparæ. Moreover, the first-born children are appreciably smaller than subsequent ones, as demonstrated by Schaetzel (1893)[1] and others, a condition which might suggest a lower rate of mortality during labor. According to Duncan and Duke (1917), however, still-births are more frequent among first-born than among second and third-born, in spite of their smaller size; only in the case of children from the sixth pregnancy does the percentage of still-births exceed the one of the first-born. However, inasmuch as abortions are much more frequent than still-births, comparatively little importance can be attached to this. The number of children in a family has also been correlated with the sex-ratio; Geissler (1889) found that in families with seven or more children there is a greater proportion of sons than in families with 2 to 7 children. Punnett (1903) reached just the opposite conclusion. The former result was confirmed by several other observers (von Körösy, Janke, and Nichols); Nichols considers it very probable that in large families the higher proportion of sons is due to a smaller number of abortions, leaving a larger number of children to be born alive, and thus their sex-ratio more closely approaches the primary sex-ratio.

Besides the above-mentioned causes for the variations found in sex-ratio, many more have been discussed in the literature in an effort to throw light on the question of sex determination. Only a few, if any, of these factors actually exert any influence upon the primary sex-ratio. The changes have all been found in the secondary sex-ratio and the probability is great that the factors causing them affected only the intrauterine death-rate. This is especially true in regard to

[1] Hansen (1913) reports that in Denmark the first born weigh on an average 3,457 grams; the second born 3,607 grams; the third born 3,698 grams, the difference between the first and second being much greater than between subsequent ones. The figures for weight at birth, given by Heiberg (1911), show an analogous relation.

changes resulting from locality, from age, nutrition, and health of the mother. Sormani (1883) reported that in Italy the sex-ratio of births in urban districts was 104.9 and in rural districts 107.0. Nichols, in contrast to this, states that in Paris the sex-ratio of new-born was 103.7 and in the remainder of France 104.3; while in Paris the mortality *in utero* was 7.7 per cent of births, in other parts of France only 4.4 per cent. In regard to the alleged influence exerted by the age of the mother on the sex-ratio of her children, the finding of Dempsey (1919) may serve as proof that this influence does not concern the primary sex-ratio. This author finds that still-births in women of 30 years of age and over were more than four times as numerous as in women under 30.

To briefly sum up the results of this study, the author believes he has succeeded in correcting two errors frequently found in the literature:

First, that the relation of the sexes at conception does not, as frequently stated, show an extremely high preponderance of males, but a surplus of 10 per cent at most.

Second, that a great number of factors claimed to influence the sex-ratio at conception, if playing any rôle at all, are only sex-eliminating during intra-uterine life and have no effect upon sex determination.

Further results of interest are the marked fluctuations in the sex-incidence of abortions and still-births in different periods of development and also the great changes in the death-rate during intrauterine life. These facts may serve as a helpful guide in the search for the cause of the greater mortality among male fetuses.[2]

---

[1] Schenk (1898) asserts that diabetic mothers bear more female than male children.

[1] This is not restricted to man, but has been found also for the rat. (King, 1921.)

CHAPTER VII.

THE OCCURRENCE OF LOCALIZED ANOMALIES IN HUMAN EMBRYOS AND FETUSES.

In a paper on the causes underlying the origin of human monsters (Mall, 1908), I made the assertion that localized anomalies were more common in embryos obtained from abortions than in full-term fetuses, without, however, adducing conclusive evidence in support of this theory.

In a footnote on page 27 of that publication I gave a list of embryos with their chief defects, comparing them with the percentage of frequency of monsters born at term. Objection might be raised to such a statement on the ground that there is not a complete correspondence between anomalies in the embryo and those found in the fetus at the end of pregnancy. For instance, spina bifida in young embryos is always complete, while at full term the open canal is covered over with skin. Cyclopia and exomphaly are the same in the embryo as at birth, but the deformities of the head and neck of the embryo are of such a nature that it can not survive long enough to admit of comparison with similar malformations found at term. With these difficulties clearly before me, I have made an effort to sharply define the anomalies in embryos, so that a satisfactory comparison might be made with those found in monsters at the end of pregnancy, as described in the literature.

Cyclopia is, perhaps, the type of anomaly which is now best understood, due largely to the excellent experimental work of Stockard, and also partly to the fact that the cyclopean state can exist quite independently of other marked deformities. I have already discussed the question of cyclopia in a separate publication (Mall, 1917[a]), and it is not therefore necessary for me to dilate further upon it at present. Hare-lip is also sharply defined in the embryo and is as readily distinguished as exomphaly. Other anomalies, however, are more difficult to recognize in the embryo as sharply defined malformations.

The pathological specimens of the first 400 accessions to our collection were reported in my paper on the origin of human monsters mentioned above. Since the embryological collection has been taken over by the Carnegie Institution of Washington it has grown at a very rapid rate, about 400 specimens being added to it each year. At present, however, only the first 1,000 will be considered, the remainder not having been sufficiently tabulated to be of statistical value. The specimens can clearly be divided into two groups according to their origin, *i. e.*, uterine and ectopic. In both of these the embryos which are normal in form are catalogued according to their sitting height, which we call crown-rump (CR). The chief difficulty, however, is to determine what constitutes a normal embryo, and here we must rely largely upon our experience in human and comparative embryology. A sharply defined, well-formed, white embryo, with blood-vessels shining through its transparent tissues, is considered normal. If it is partly stunted and opaque or disintegrating it is considered pathological. A further study of the

so-called normal embryos, however, shows that in many of them the membranes are decidedly pathological. For instance, the villi may be deformed, diseased, atrophic or hypertrophic, or the contents of the amnion and the exocœlom may be unusual. Nevertheless, in all of these cases we still classify the embryos as normal, although fully cognizant of the fact that the surrounding membranes are pathological; otherwise it would be difficult to account for the great number of spontaneous abortions. The theory is that the embryo was developed under pathological conditions, but that the chorion was not sufficiently affected to cause any apparent change in the embryo. If an embryo included in this group is apparently normal in all respects save one, we still consider it normal with a localized anomaly. In fact, we are gradually forced into this position, as an embryo, at first regarded as normal, may later prove to have a localized anomaly, such as spina bifida or cyclopia. As far as we can determine, such an embryo would have been able to survive longer had not something happened to its membranes, thus causing its expulsion. I am inclined to believe that pregnancies of this sort, if carried to term, would produce the ordinary monsters described by teratologists.

The second group of specimens, which are termed pathological, are in a way more interesting, and their study justifies our method of classifying localized anomalies with normal embryos. We have in this group a variety of changes ranging from those found in fetus compressus down to complete disintegration of the ovum, leaving only a few villi.

Having made numerous efforts to classify these specimens, I have finally resolved them into seven groups, which have been considered in a previous chapter. It can be readily seen that this classification into sub-groups is arranged somewhat in the order of the age of the ovum when it began to degenerate. Generally the changes are so pronounced that the embryo could not have lived through the duration of pregnancy, and this accounts for the abortion.

We naturally do not find localized anomalies in specimens from the first four groups, while in the remaining three groups we encounter only such as are very pronounced and stand out clearly in spite of other changes. Thus, for instance, with fetus compressus we frequently recognize club-foot; in stunted forms, hare-lip and spina bifida; and in cylindrical forms, spina bifida. If cyclopia is encountered in any of these forms, it is looked upon as a localized anomaly in a pathological embryo. On the other hand, a single anomaly in an embryo called normal can easily be recognized, and it is from this group that we should expect the development of monsters had the pregnancy progressed to term.

A few illustrations of localized anomalies are given here in order to show that they are identical with those found in infants at birth. Figures 83 and 84 represent, respectively, a cyclopean and a double monster, the embryos being otherwise normal. Figures 85 and 86 show hare-lip in an embryo and a fetus. Figures 87, 88, and 89 have pronounced localized anomalies and need no further explanation. Finally, figures 90 to 93 show anomalies of the hands. The first and last are of the hereditary variety, while figures 91 and 92 are acquired anomalies—that is, they were subsequently formed in an embryo whose development began normally.

It is proper to remark here that these illustrations are mostly from specimens from the second 1,000 of our collection. This is because we have recently made many more photographs, and, furthermore, many of the specimens in the first thousand have already been figured in my paper on monsters.

In order to render possible a comparison between localized anomalies found in pathological, and those found in normal embryos, six tables have been constructed. Table 7 gives the classified distribution of the first 1,000 embryos in the Carnegie Collection. The primary division comprises two classes—pathological and normal. The pathological specimens in turn are arranged in the seven groups just described. The normal are arranged in groups to correspond as nearly as possible to the ages of the embryos in lunar months. In order to define clearly which embryos belong in a given month, I have inserted their probable lengths for each month in table 12. Thus, for instance, the second month includes all specimens from 2.6 mm. to 25 mm. in length, etc. (Data upon the estimated ages of embryos may be found in my chapter on that subject in the Manual of Human Embryology, vol. 1.)

TABLE 7.—*Showing the distribution of first 1,000 accessions.*

Century.	Catalogue No.	Pathological, in groups.								Normal, in months.										
		1	2	3	4	5	6	7	Total.	1	2	3	4	5	6	7	8	9	10	Total.
1	1 to 98	1	5	1	6	4	3	4	24	3	41	17	8	7	0	0	0	0	0	76
2	99 to 205	0	9	1	8	6	13	6	43	0	25	21	7	2	2	0	0	0	0	57
3	206 to 295	2	5	0	3	9	11	7	37	1	24	28	7	1	1	0	0	0	1	63
4	296 to 380	1	7	1	4	9	16	7	45	1	21	12	14	2	2	2	0	0	1	55
5	381 to 476	4	2	3	4	7	9	3	32	3	41	11	11	2	0	0	0	0	0	68
6	477 to 571	4	10	7	7	9	8	6	51	0	21	16	4	5	1	0	2	0	0	49
7	572 to 652*c*	3	5	4	3	5	5	8	33	0	28	21	10	3	2	3	0	0	0	67
8	652*d* to 729	4	7	3	7	12	7	4	44	1	18	18	10	4	3	1	0	0	1	56
9	730 to 816*b*	8	13	1	5	7	4	11	49	1	12	15	15	7	1	0	0	0	0	51
10	817 to 900*g*	9	8	0	4	7	4	6	38	1	14	21	7	8	6	2	0	0	3	62
		36	71	21	51	75	80	62	396	11	245	180	93	41	18	8	2	0	6	604

It will be noted in these tables that the specimens are arranged in centuries; that is, each line in the table includes exactly 100 specimens. The first century includes specimens Nos. 1 to 98, the second, Nos. 99 to 205, and so on. This adjustment was necessary for the reason that frequently a single number is given to 2 or more specimens. Sometimes the first is called *a* and the second *b;* or the first may be given the number and the second the letter *a*, etc. The second century, passing from Nos. 99 to 205, includes more than 100 numbers, because specimens which are given a number are frequently found upon further examination to contain no remnants of an ovum, and for this reason they have to be discarded. In our catalogue they are later marked as "No pregnancy." Finally, the tenth century ends with embryo No. 900*g*. The individual entries are percentage records. Thus in the fifth century there are 41 normal specimens of the second month; that is, of this hundred specimens 41 per cent are normal embryos of the second month, whereas the total for the full 1,000 has brought down this percentage to 24.5.

In determining normality, the criterion used was the shape of the embryo, judging this as best we could by our own knowledge of human and comparative embryology, as well as by the experience of other students of human embryology. We have also used freely the atlases of His, Hochstetter, and Keibel and Else in making our decisions on this point. However, many of these specimens are inclosed in membranes which have undergone very marked changes. Thus, an embryo normal in form may be found to be surrounded by an excessive amount of magma and the chorion may have undergone very pronounced changes; but for purposes

TABLE 8.—*Distribution of uterine specimens.*

Century.	Catalogue No.	Pathological, in groups.								Normal, in months.										
		1	2	3	4	5	6	7	Total.	1	2	3	4	5	6	7	8	9	10	Total.
1	1 to 98	1	5	1	6	4	3	4	24	3	41	17	8	7	0	0	0	0	0	76
2	99 to 205	0	8	1	8	6	12	6	41	0	22	20	6	2	2	0	0	0	0	52
3	206 to 295	2	5	0	3	9	11	7	37	1	23	27	7	1	1	0	0	0	1	61
4	296 to 380	1	3	0	3	8	15	6	36	1	19	12	14	2	2	2	0	0	1	53
5	381 to 476	1	1	3	3	7	9	3	27	3	34	8	11	2	0	0	0	0	0	58
6	477 to 571	1	0	5	7	7	6	3	29	0	18	14	3	5	1	0	2	0	0	43
7	572 to 652*c*	1	4	4	3	5	5	8	30	0	24	21	10	3	2	3	0	0	0	63
8	652*d* to 729	1	4	3	7	10	7	3	35	1	13	18	10	4	3	1	0	0	1	51
9	730 to 816*b*	2	5	1	5	6	4	10	33	1	8	15	15	7	1	0	0	0	0	47
10	817 to 900*g*	2	4	0	3	5	2	5	21	1	11	18	7	8	6	2	0	0	3	56
		12	39	18	48	67	74	55	313	11	213	170	91	41	18	8	2	0	6	560

TABLE 9.—*Distribution of ectopic specimens.*

Century.	Catalogue No.	Pathological, in groups.								Normal, in months.										
		1	2	3	4	5	6	7	Total.	1	2	3	4	5	6	7	8	9	10	Total.
1	1 to 98	0	0	0	0	0	0	0	0	0	0	0	0	0	0	0	0	0	0	0
2	99 to 205	0	1	0	0	0	1	0	2	0	3	1	1	0	0	0	0	0	0	5
3	206 to 295	0	0	0	0	0	0	0	0	0	1	1	0	0	0	0	0	0	0	2
4	296 to 380	0	4	1	1	1	1	1	9	0	2	0	0	0	0	0	0	0	0	2
5	381 to 476	3	1	0	1	0	0	0	5	0	7	3	0	0	0	0	0	0	0	10
6	417 to 571	3	10	2	0	2	2	3	22	0	3	2	1	0	0	0	0	0	0	6
7	572 to 652*c*	2	1	0	0	0	0	0	3	0	4	0	0	0	0	0	0	0	0	4
8	652*d* to 729	3	3	0	0	2	0	1	9	0	5	0	0	0	0	0	0	0	0	5
9	730 to 816*b*	6	8	0	0	1	0	1	16	0	4	0	0	0	0	0	0	0	0	4
10	817 to 900*g*	7	4	0	1	2	2	1	17	0	3	3	0	0	0	0	0	0	0	6
		24	32	3	3	8	6	7	83	0	32	10	2	0	0	0	0	0	0	44

of classification we have found it necessary to arrange them all according to the shape of the embryo. A fairly large number of our specimens were obtained from hysterectomies. We believe with Hochstetter that we shall ultimately have to determine what constitutes a normally formed human embryo from specimens obtained in this way; but among about 25 hysterectomy specimens, we nevertheless found 3 which were markedly pathological and undergoing abortion.

Table 8 includes all uterine and table 9 all ectopic specimens. In comparing these three tables it will at once be noted that among the entire 1,000 nearly 40 per cent are pathological embryos and ova. Of this number 31 per cent were

obtained from the uterus, while slightly more than 8 per cent were ectopic. The comparative frequency of pathological and normal embryos can be ascertained, however, by comparing them within a given century, or for the whole 1,000 together. In the uterine specimens about one-third of the ova and embryos are pathological, as compared to two-thirds in the ectopic. In other words, pathological specimens are twice as frequent in ectopic as in uterine pregnancy.

Table 10 includes all the specimens in which there are pronounced localized anomalies. The character of the anomaly for the individual specimens recorded is given in tables 11 and 12. From these tables it would appear that there are about as many anomalies among the normal as among the pathological specimens, but when these figures are compared with the total number of specimens, both normal and pathological, it becomes evident that localized anomalies occur about twice as frequently in the pathological as in the normal embryo. Thus, 38 out of

TABLE 10.—*Distribution of specimens with localized anomalies (to be compared with table 7).*

Century.	Catalogue No.	Pathological, in groups.								Normal, in months.										
		1	2	3	4	5	6	7	Total.	1	2	3	4	5	6	7	8	9	10	Total
1	1 to 98	0	0	0	0	0	1	1	2	1	4	0	0	0	0	0	0	0	0	5
2	99 to 205	0	0	0	0	1	2	1	4	0	3	0	0	0	0	0	0	0	0	3
3	206 to 295	0	0	0	0	1	1	3	5	1	3	2	1	0	0	0	0	0	0	7
4	296 to 380	0	0	0	0	3	3	1	7	0	3	0	1	0	1	0	0	0	1	6
5	381 to 476	0	0	0	0	1	2	0	3	0	0	0	0	0	0	0	0	0	0	0
6	477 to 571	0	0	0	0	0	2	0	2	0	3	0	0	0	0	0	1	0	0	4
7	572 to 652*c*	0	0	0	0	0	1	4	5	0	2	0	0	0	0	0	0	0	0	2
8	652*d* to 729	0	0	0	0	2	0	0	2	0	1	0	0	0	0	0	0	0	0	1
9	730 to 816*b*	0	0	0	0	1	1	3	5	0	3	1	2	0	0	0	0	0	0	6
10	817 to 900*g*	0	0	0	0	2	0	1	3	0	0	0	0	0	0	0	0	0	3	3
		0	0	0	0	11	13	14	38	2	22	3	4	0	1	0	1	0	4	37

396 pathological specimens, or about 10 per cent, exhibit localized anomalies, as against 6 per cent in 604 normal specimens. The 38 pathological specimens with localized anomalies listed in table 10 were aborted in the early part of pregnancy, and only one of them (No. 649) grew to a sitting height of 90 mm., that is, to about the middle of the fourth month.

The number of normal embryos with localized anomalies tends to decrease before the fifth month, there being but 1 in the sixth, 1 in the eighth, and 4 in the tenth month, the end of pregnancy. In other words, all pathological specimens, either with or without localized anomalies, are aborted in the first half of pregnancy, as are also nearly all so-called normal embryos with slight malformations, very few of them reaching full term.

We have made an especial effort to collect specimens of full-term monsters as well as abortion material from all months of pregnancy. Only the first 100 specimens of the collection show an unusually large percentage of normal embryos. Although at first an effort was made to collect only good, normal specimens, the last 900, including all sorts of material, carry about the same percentage of normal specimens throughout. Among the first 1,000 specimens of our collection there are not many fetuses from the second half of pregnancy, but we are now

endeavoring to collect material covering all months. One monster at term, a sympus belonging in about the third 100, was not recorded in our catalogue, and should be added to the four full-term specimens given in table 10. This means that among 1,001 specimens there were 5 full-term monsters, while among 1,000 specimens there were 71 with localized anomalies, most of them being aborted early in pregnancy.

TABLE 11.—*Localized anomalies in pathological embryos.*

Catalogue No.	Length of specimen in mm.	Dimensions of chorion in mm.	Menstrual age in days.	Type of localized anomaly.
Group 5, cylindrical embryos.				
785	2	15×12×10	64	Spina bifida.
874*b*	3	35×30×20	80	Hydrocephalus.
189	4	28×25×15	.....	Spina bifida.
228	4	60×25×25	99	Hydrocephalus.
302	4	25×20×15	.....	Hydrocephalus.
466	4	29×23×16	.....	Spina bifida.
328	4.5	.....	.....	Hydrocephalus.
842	5	.....	.....	Eye detached from brain.
753	11	80×50×35	.....	Amyelia; ectopia of heart.
710	13	95×55×55	228	Amyelia.
365	14	.....	.....	Anencephaly; spina bifida.
Group 6, stunted embryos.				
433*a*	3	27×25×15	49	Hydrocephalus.
413	5	35×35	.....	Spina bifida.
510	10	60×45	.....	Spina bifida.
338*c*	11	.....	35	Spina bifida.
276	13.5	70×35×35	80	Anencephaly.
81	15	65×55×35	.....	Anencephaly.
344	16	45×45×45	.....	Rounded head; club-leg.
364	16	90×50×40	89	Exencephaly; hare lip; exomphaly; spina bifida.
499	17	45×45×40	.....	Hare-lip; spina bifida.
201	20	80×60×50	.....	Cyclopia.
Group 6, stunted embryos.—*Continued.*				
124	35	90×75×50	.....	Club-foot and hand.
797	35	65×35×35	.....	Club-foot and hand.
649	90	.....	.....	Spina bifida; exomphaly; without radii and without thumbs.
Group 7, macerated and fetus compressus.				
182	5.5	.....	.....	Head defective; spina bifida.
802	6	19×26×16	.....	Anencephaly.
212	15	.....	.....	Head atrophic.
732	19	.....	88	Exomphaly.
94	20	.....	.....	Spina bifida.
226	24	60×60×30	87	Anencephaly; spina bifida.
651*a*	27	70×45×45	.....	Spina bifida.
868	39	.....	193	Club-foot.
316	44	.....	.....	Club hand and foot; hand adherent to head; skin nodules.
627	45	80×50×35	.....	Club hand and foot.
740	56	.....	.....	Club-foot.
230	57	75×60×50	.....	Club hands and feet.
622	70	.....	.....	Club-foot.
646	85	90×60×50	.....	Exencephaly.

According to the table on the frequency of abortions, given in my monograph on monsters (Mall, 1908), there are 20 abortions to every 80 full-term births; therefore, the 1,000 abortions under consideration were probably derived from 5,000 pregnancies.

As we have calculated that there should be approximately 30 full-term monsters in 5,000 pregnancies, and as 5 of these were observed in our 1,000 specimens, it is apparent that the remaining 25 should be encountered in 4,000 additional full-term births. When these figures are considered in connection with the fact that 75 localized anomalies occurred in 1,000 abortions (7.5 per cent) it becomes apparent that in any similar numbers of abortions localized anomalies should occur twelve times as frequently as monsters at term. A similar result is obtained if the number of localized anomalies of the tenth month, as given in table 10, is compared with all of the localized anomalies of previous months, as given in the same table.

Our studies seem to justify the conclusion that pathological embryos, as well as those which are normal in form, are very frequently associated with localized anomalies and that abortion usually follows as a result of serious lesions in the chorion, as well as in its environment. Should the alterations in the embryo and in the chorion be very slight and the condition of the uterine mucous membrane,

TABLE 12.—*Localized anomalies in normal embryos.*

Catalogue No.	Length of specimen in mm.	Dimensions of chorion in mm.	Menstrual age in days.	Type of localized anomaly.
1 month, 0 to 2.5 mm.				
250	2	10× 9× 8	.....	Cytolysis.
12	2.1	18×18×18	41	Anencephaly; spina bifida.
2 months, 2.6 to 25 mm.				
779	2.75	16×14×12	44	Spina bifida.
164	3.5	17×17×10	.....	Spina bifida.
186	3.5	25×20×15	.....	Anomalous tracheal diverticulum.
112	4	.....	.....	Hydrocephalus.
808	4	.....	47	Spina bifida.
80	5	24×18× 8	.....	Deformed tail.
552	6	40×28×28	.....	Spina bifida.
676	6	35×20×17	52	Spina bifida.
796	6	30×20×15	48	Leg hypertrophic; head atrophic.
371	6.6	.....	.....	Hydrocephalus.
651*f*	7	25×20×15	.....	Spina bifida.
559	8	20×15×12	54	Cyclopia.
511	14	38×32×32	.....	Spina bifida.
338*a*	18	45×45	.....	Constricted cord.
293	19	.....	.....	Spina bifida.
242*a*	23	50×50×70	.....	Double monster.
242*b*	23	50×50×70	.....	Double monster.
6	24	40×40×40	.....	Cyst of spinal cord.
10	24	.....	.....	Hernia of liver.
31	24	50×30×20	62	Hernia of liver.
314	24	.....	.....	Atrophic head.
584*a*	25	50×42×40	.....	Hernia of liver.
3 months, 26 to 68 mm.				
249*a*	37	.....	.....	Double monster.
249*b*	37	.....	.....	Double monster.
789	50	.....	117	Extremities deformed; left radius probably absent; head atrophic.
4 months, 69 to 121 mm.				
768*c*	80	.....	.....	Stub coccyx.
768*b*	85	.....	.....	Left forearm and hand lacking.
306*a*	100	.....	.....	Only 2 fingers on right hand.
295	110	.....	.....	Rounded head, thickened scalp.
5 months, 122 to 167 mm.				
No specimens.				
6 months, 168 to 210 mm.				
335	190	.....	.....	Anencephaly.
7 months, 211 to 245 mm.				
No specimens.				
8 months, 246 to 284 mm.				
558	250	.....	.....	Spina bifida.
9 months, 285 to 316 mm.				
No specimens.				
10 months, 317 to 336 mm.				
370	After birth	.....	.....	Enormous tail.
862	At birth	.....	.....	Ectopia of bladder.
862*a*	At birth	.....	.....	Spina bifida.
862*b*	At birth	.....	.....	Stunted eyes.

which may be expressed by the term *inflammation*, be overcome, the pregnancy in all probability would go to term and end in the birth of a monster or an infant presenting a well-recognized malformation.

I have already pointed out the difference in frequency of malformations and destructive changes, as observed in the ovum, in tubal and in uterine pregnancies. Since the publication of my monograph on monsters I have reconsidered the question of tubal pregnancy and the specimens mentioned in the present paper are recorded in detail in a volume on tubal pregnancy (Mall, 1915).

It seems to me that the studies based upon our collection, as well as recent investigations in experimental embryology, set at rest for all time the question of the causation of monsters. It has been my aim to demonstrate that the embryos found in pathological human ova and those obtained experimentally in animals are not merely analogous or similar, but identical. A double-monster fish or a cyclopean fish is identical with the same condition in human beings. Monsters are produced by external influences acting upon the ovum; as, for instance, varnishing the shell of a hen's egg or changing its temperature, traumatic and mechanical agencies, magnetic and electrical influences, as well as alteration of the character of the surrounding gases, or the injection of poisons into the white of an egg. In aquatic animals monsters may be produced by similar methods. Whether in the end all malformations are brought about by some simple mechanism, such, for instance, as alteration in the amount of oxygen or some other gas, remains to be demonstrated. The specimens under consideration show such marked primary changes in the villi of the chorion and in the surrounding decidua that the conditions in the human may be considered equivalent or practically identical with those created artificially in the production of abnormal development in animals.

It would be quite simple to conclude that the poisons produced by an inflamed uterus should be viewed as the sole cause, but when it is recalled that pathological ova occur far more commonly in tubal than in uterine pregnancy, such a theory becomes untenable. Moreover, monsters are frequently observed in swine and other animals without any indication of an inflammatory environment. For this reason I have sought the primary factor in a condition buried in the non-committal term, *faulty implantation.* It would seem to be apparent that lesions occurring in the chorion as the result of faulty implantation can and must be reflected in the embryo. For example, before circulation has developed in a human embryo, pabulum passes from the chorion to the embryo directly through the exocœlom, and probably on this account we always encounter, as a first indication of pathological development, a change in the magma. In older specimens, before any other changes are noticeable in the ovum, the magma becomes markedly increased and a variety of changes are found between the villi. I shall not dwell further upon magma, as I have already dealt with the subject in detail (Mall, 1916).

It is perfectly clear that, in general, monsters are not due to germinal or hereditary causes, but are produced from normal embryos by influences which are to be sought in their environment. Consequently, if these influences are carried to the embryo by means of fluids which reach it either before or after the circulation has become established, it would not be very far amiss to attribute these conditions to alterations in the nutrition of the embryo. Probably it would be more nearly correct to state that change in environment has affected the metabolism of the egg. Kellicott (1916), who has discussed this question, seems to be disinclined to accept such an explanation, but I do not see that he has added materially to it by substituting the word *disorganization* for *nutrition,* as one might as easily say that the *altered nutrition* causes the *disorganization.*

In my paper on monsters I stated that on account of faulty implantation of the chorion the nutrition of the embryo is affected, so that if the ovum is very young the entire embryo is soon destroyed, leaving only the umbilical vesicle within the chorion; this also soon disintegrates, and the chorionic membrane in turn collapses, breaks down, and finally disappears entirely. In older specimens, on the other hand, the process of destruction takes place more slowly, and thus we many account for a succession of phenomena which correspond to the seven groups of pathological ova referred to above.

Kellicott, in his discussion of monsters, dropped the subject by stating that the embryo is a monster simply because it is disorganized. In my original study I really went, I believe, a step farther than Kellicott, for I attempted to analyze the process of disorganization more thoroughly and demonstrated that in the beginning it is accompanied by cytolysis, but as it progresses more rapidly it results in histolysis, and that these two processes do not act with equal severity on all parts of the embryo. When we consider the ovum as whole, it is the embryo itself which is first destroyed, while within the embryo the central nervous system or the heart is the structure first affected. Morphologically, these changes are accompanied by a destruction of certain cells and tissues, leaving other portions which continue to grow in an irregular manner. For this reason I speak of the tissues which are first affected as being more susceptible than the others. The entire process of disorganization, resulting in an irregular product, I have termed *dissociation.* In a general way this explanation is accepted by Werber (1915, 1916), but he employs the term *blastolysis* instead.

At the time I prepared my paper on monsters, Harrison was just beginning his interesting experiments in tissue culture in our laboratory. Since then this method of study has given us clearer insight into the independent growth of tissues. I was fully convinced from the study of pathological embryos that tissues continue to grow in an irregular manner, thus arresting normal development; but since we are more familiar with the growth of tissues, as revealed by Harrison's method, we can understand a little better the process of dissociation. In fact, we have in our collection two striking examples of tissue culture in human embryos. In one the cells had formed an irregular mass which was growing actively, but the contour of the organs had been entirely lost. In the other, from a tubal pregnancy, for some unknown reason the ovum had been completely broken into two parts, which in turn had cracked the embryo, and from each piece there had been a vigorous independent tissue growth, or, as we may now say, a tissue culture. Accordingly, when an embryo is profoundly affected by changed environment the development of one part of the body may be arrested, while the remaining portion may continue to grow and develop in an irregular manner. In very young embryos, tissues or even entire organs become disintegrated, as can be easily recognized by the cytolysis and histolysis present, and the resultant disorganized tissue can not continue to produce the normal form of an embryo. If this process is sharply localized, for instance, in a portion of the spinal cord or in the brain, spina bifida

or anencephaly results. To produce a striking result, as in cyclopia, a small portion of the brain must be affected at the critical time, and I think the work of Stockard has shown clearly that this is before the eye primordia can be seen. Consequently, in order to produce a human monster which is to live until the end of gestation, the effect of the altered environment must be reflected from the chorion to the embryo, so that the tissue to be affected is struck at the critical time in its development. It is inconceivable that cyclopia should begin in an embryo after the eyes are once started in normal development. Moreover, the same is true regarding hare-lip, for after the upper jaw has once been well formed, the abnormality can not develop. We may extend this statement to include club-foot, spina bifida occulta, and other types of malformation. In fact, in discussing the origin of merosomatous monsters, hardly more has been stated by most authors than that there has been an arrest of development, but I have attempted to point out that the primary cause is in the environment of the egg and that the arrested development is associated with destruction of tissue.

DESCRIPTION OF PLATE.

Plate 7.

Fig. 83. Normal embryo with cyclopia; in front of the eye is seen the cyclopean snout. No. 559. ×3.75.
Fig. 84. Normal double monster. No. 249. ×0.75.
Fig. 85. Specimen with hare-lip and exencephaly. No. 364. ×2.25.
Fig. 86. Specimen with hare-lip. No. 982. ×1.5.
Fig. 87. Stunted fetus with large hernia in umbilical cord. No. 1330. ×0.9.
Fig. 88. Normal embryo with exencephaly and spina bifida (the latter opposite the arrow). No. 1315. ×1.5.
Fig. 89. Normal fetus with hernia of mid-brain. No. 1690. ×6.75.
Fig. 90. Anomaly of left hand of No. 306*a*. Only the thumb and little finger are normal.
Fig. 91. Left hand, which is club-shaped, from No. 230, a fetus compressus 57 mm. CR. ×0.75.
Fig. 92. Deformed wrist with atrophic radius in a normal embryo. No. 789, 50 mm. CR. ×3.
Fig. 93. Right hand with six fingers from macerated specimen. No. 1749. There were six digits on each of the four extremities. ×3.
Fig. 94. Hydatiform villi. (After Gierse.) See Chapter VIII.
Fig. 95. Hydatiform villi showing vacuolation. (After Gierse.) See Chapter VIII.

83

84

85

86

87

88

89

90

91

92

93

94

95

CHAPTER VIII.

HYDATIFORM DEGENERATION IN UTERINE PREGNANCY.

To read even the titles of articles on "molar" pregnancies which have appeared during the last few decades is a rather wearisome task. The great majority of the articles concern themselves merely with the report of "a case" or (rarely) of "several cases" of hydatiform moles. The recent cancer literature stands in marked contrast to this, for not even the general practitioner would think of reporting a routine case of cancer of the breast, let us say. The significance of these facts is self-evident, and whatever else they may mean they do imply that hydatiform mole is still regarded quite generally as a *rare* condition. Indeed, many of those reporting "a case" frankly say so, and although the incidence of hydatiform degeneration is estimated variously by different authors and investigators, there seems to be entire agreement among them that it is a rare, even if not an extremely rare condition. This opinion seems to be shared also by those general practitioners whose long practice runs high up into the hundreds or even into the thousands of obstetrical cases. Indeed, many general practitioners declare that they have not seen a single case of hydatiform mole during the practice of a long life.

This prevailing opinion can not be attributed solely to the influence of the schools or to books, but is based upon the actual experience of the individual practitioner and upon his conception of what constitutes hydatiform degeneration. This is illustrated, for example, by Menu (1899), who said that a small hydatiform mole weighs 300 grams, a large one 8,000, with an average weight in his series of cases of 1,700 grams. But even specialists in charge of hospitals have reported experiences similar to that of the general practitioner. Pazzi (1909), for example, stated that although he had observed more than 6,000 cases of labor in his private and hospital practice, he never met with a case of hydatiform mole. Moreover, it would seem that only some specialists have come to regard the condition as somewhat less rare than was heretofore supposed. This is well expressed by Williams (1917), who wrote: "Hydatiform mole is a rare disease, occurring, according to Madam Boivin, once in 20,000 cases. On the other hand, the statistics of Williamson would indicate that it may be found but once in 2,400 cases." Williams adds, however, that in his own experience it occurred even more frequently than stated by Williamson; and Essen-Möller (1912), on the basis of 6,000 cases treated between 1899 and 1908, gives the incidence at the Frauenklinik at Lund as 3 per 1,000. My former colleague, De Lee (1915), in commenting on hydatiform degeneration, also stated that he "frequently found in aborted ova one or more villi degenerate and forming vesicles"; and similar remarks were made also by others, notably by Müller (1847), Marchand (1895), Veit (1899), van der Hoeven (1900), Hiess, and according to him also by von Hecker, Langhans, Weber, and Fränkel. Findlay (1917) also regards "it as fair to conclude with Veit, Freund,

and Dunger that abortive types of hydatiform mole are commonly overlooked," and although he gave no evidence for his opinion, Weber (1892) insisted that hydatiform mole "occurs much oftener than we are led to believe from books or other literature." Essen-Möller says König gave an incidence of 1 per 728 cases. Pazzi (1908[b]) stated that Dubisay and Jennin found in 1903 that hydatiform degeneration occurs once in 2,000 pregnancies, and that Cortiguera in 1906 declared that the frequency of hydatiform mole has a discouraging variation of from 1 in 3,000 to 1 in 700 labors, but that in his personal experience Cortiguera saw one case in every 300 labors. The latter incidence is only slightly higher than that given by Essen-Möller for the clinic at Lund, and somewhat below that of Kroemer (1907), who found 15 hydatiform moles in 3,856 births, or one in every 257 cases. Mayer (1911) reported 10 instances among 3,105 cases of labor, an incidence of 1 in 310 cases, and it is only necessary to add that Donskoj (1911) stated that the incidence of hydatiform mole in 28,406 cases at the Frauenklinik at München, between the years 1884 and 1910, was only 1 for every 4,058 births, to emphasize the discouraging variation of which Cortiguera spoke. Donskoj also stated that Engel gave the incidence as 1 in 800, and Korn as 1 in 1,250 births. Such a surprising fluctuation in the apparent incidence in adjacent communities points to differences in conception of what constitutes a hydatiform mole, and also to differences in character of the material upon which the calculations are based.

The existence of hydatiform degeneration in far greater frequency than commonly supposed is indicated also by the records of the Department of Embryology of the Carnegie Institution of Washington. However, the material covered by these records is not identical with that upon which the above opinions or those of other obstetricians are based. The opinion of the obstetrician is based upon material belonging very largely in the later months of pregnancy, while that in the Carnegie Collection, on the other hand, belongs very largely in the earlier months. Hence this material is not truly representative of the entire period of gestation. But the same thing is true of the material upon which the general practitioner, the obstetrician, and the gynecologists have based *their* opinions, for these are based largely upon material from the last months of pregnancy. Hence, the cases of hydatiform degeneration which survive mainly come to their attention.

But unless we can assume that the incidence of hydatiform degeneration is constant during the whole period of gestation, its incidence at any particular time of this period may very incorrectly express that at any other time. This could fail to be true only if the incidence of death of the conceptuses and their susceptibility to hydatiform degeneration were exactly uniform throughout every period of intrauterine life. But we know that neither is true, for it is common knowledge that by far the great majority of the cases of uterine hydatiform degeneration recorded in the literature are mature specimens of total or partial degeneration obtained in the later months of pregnancy. Although such specimens may contain villi in various stages of degeneration, they nevertheless represent end or near-end

results. Like the fetuses which rarely accompany them, they are full-term or near-term products when regarded as hydatiform degenerations, and unless we are to assume that conceptuses once affected by hydatiform degeneration always survive to near-term, statistical deductions based upon the cases that do survive can give us little idea of the actual frequency of the condition throughout the entire period of antenatal life.

That the specimens upon which past and also present opinion is based usually were large is confirmed by the belief in the prevailing clinical criterion of the existence of a disproportionately large uterus in cases of hydatiform mole. The emphasis laid on this by clinicians is well illustrated by Seitz (1904[b]), who said that cases in which the uterus is too small are the exception. Indeed, it seems that the validity of this clinical dictum has been questioned only very recently by Briggs (1912). Since most early conceptuses showing hydatiform degeneration have been inhibited in growth before being aborted, it probably is only the specimens which continue to grow that produce a uterine enlargement greater than could normally be expected. However, since, as emphasized by Gierse (1847), Storch (1878), Hiess (1914), and others, most hydatiform moles are expelled early and spontaneously, it is evident that these can not have been adherent—that is, have penetrated very deeply—or they would not have been expelled early and spontaneously. Furthermore, maceration changes so commonly present in aborted hydatiform moles indicate very clearly that a large percentage of them, together with the decidua, had been more or less completely detached from the uterine wall some time before abortion occurred.

As far as one can gather from the literature, the present opinion regarding the incidence of hydatiform degeneration would be paralleled quite correctly if, in the case of measles, we assumed that it was as common in octogenarians as in children. Measles, indeed, is an extremely rare disease in advanced age, but it nevertheless is very common in infancy. This is exactly the mistake we have made regarding hydatiform degeneration. It may be and undoubtedly is a rare disease at or near term, as Gierse also stated, but it probably is the commonest of all diseases during the earliest months of gestation. The typical large hydatiform mole is an end-result which it has taken long months to develop. No one seems to have followed its evolution, although hydatiform degeneration, whether total or partial, is, of course, gradual in its advent.

The records of the Carnegie Collection contained 8 cases of hydatiform mole in the first 2,400 accessions, showing a frequency eight times as great as that given by Williamson, or an excess of 700 per cent. Since the first 2,400 accessions contain 309 cases of tubal and 2 of ovarian pregnancy, only 2,089 uterine specimens remain. Hence the recorded incidence in the uterine specimens really is 8 in 2,089, or 1 in every 261 cases. This incidence is only slightly lower than that of Kroemer, and somewhat higher per 1,000 than that given by Essen-Möller for the Frauenklinik at Lund, or than the personal experience of Cortiguera.

The highest incidence of hydatiform degeneration previously reported is that of Storch, who estimated it as 50 per cent, but he unfortunately did not give a

record of his cases. However, he emphasized that the typical, completely hydatiform mole is a relatively rare form of the disease, and that all manner of transition forms between the normal chorionic vesicle and the completely degenerated one can be shown to exist. Storch further emphasized the commonness of hydatiform degeneration, especially in the early months of pregnancy, but as Veit (1899) well said, Storch somehow has not received sufficient credit for his investigations and Gierse was forgotten completely. This seems strange, especially in view of the fact that Storch's work was done in Copenhagen, where Panum (1860) had done and still was doing such fine and very suggestive, indeed epochal, work on the origin of monsters. Although Storch devoted part of his paper to myxoma fibrosum, and reported only 5 cases of hydatiform mole, one of which, however, accompanied a living fetus, his opinions on the whole were far ahead of his time. In order to make this clear I shall quote a very significant passage, which, in the main, needs but slight changes to serve as a conclusion for my own investigations:

"Nun sind aber bekanntlich Eier mit blasiger Degeneration der Zotten und fehlerhaft oder nicht entwickeltem Fötus ein sehr häufiger Befund bei Aborten aus den ersten Schwangerschaftsmonaten. Mehrere solche Eier sind schon in den bekannten Arbeiten von Dohrn und Hegar beschrieben worden. Ich habe im Laufe des letzten Jahres eine grössere Anzahl von Aborten untersucht und derartige kranke Eier in mehr als der Hälfte der Fälle gefunden. Nicht selten ist die Amnionblase völlig leer und enthält nur eine klare seröse Flüssigkeit. In anderen Fällen sitzt an der einen oder anderen Stelle der Innenfläche des Amnion ein kleiner rundlicher oder unregelmässig geformter, ½–1 Mm. grosser Körper, welcher aus Nichts als aus runden, schwach conturirten, zum Theil fettig entarteten Zellen und einer hellen, fast homogenen Zwischensubstanz besteht, und der durch einen feinen, 1–3 Mm. langen Strang von ähnlicher Natur mit dem Amnion verbunden ist. In noch anderen Eiern ist der Embryo zwar etwas weiter entwickelt, aber von den verschiedensten Formen von Missbildungen befallen. Seltener ist der Embryo einigermaassen wohl gebildet und von bis zu 2 Cm. Länge, wie dies auch Hohl nur einmal gefunden hat. Sehr gewöhnlich ist fettige oder lipoide Entartung des Embryo vorhanden; derselbe ist dann eine kürzere oder längere Zeit vor der Geburt abgestorben. Als die äussersten Glieder dieser Reihe von kranken Eiern stehen endlich die sehr seltenen Fälle, in welchen der Embryo seine Entwickelung ziemlich ungestört fortgesetzt zu haben scheint, und von denen die Fälle von Martin und der oben beschriebene dreimonatliche abort Beispiele sind.

"Die blasige Entartung der Chorionzotten kann demnach neben den verschiedensten Zuständen des Embryo gefunden werden. Sehr häufig ist letzterer der Sitz von mehr oder weniger eingreifenden Krankheitsprozessen gewesen, die in demselben verschiedene Missbildungen hervorgerufen und ihn in seiner Entwickelung gehemmt haben. Es sind diese Krankheitsprozesse wahrscheinlich immer sehr früh im Ei entstanden, und müssen mit Panum zunächst als entzündliche Vorgänge aufgefasst werden, welche nach ihrer Intensität und vielleicht nach dem Zeitpunkte, zu welchem sie im Keime auftreten, bald eine theilweise Verödung der Keimanlagen der meisten wichtigeren Organe mit Verkrüppelung des ganzen embryonalen Körpers, bald mehr locale Missbildungen einzelner Körpertheile hervorrufen können. Das Erstere ist in den hier besprochenen Aborten sehr häufig der Fall; der Embryo ist zu einem unförmlichen Klumpen umgewandelt, dem die meisten Organe deren Keime durch Entzündung zerstört worden sind, gänzlich fehlen. Von diesen verkrüppelten Amorphi finden sich in anderen Eiern alle Uebergangsformen zu mehr oder weniger entwickelten Missbildungen was auch Panum an einigen Beispielen nachgewiesen hat. Es Scheinen in der That die nicht zerstörten Keimzellen der ver-

schiedenen Organe, nach dem ablaufe des Krankheitsprozesses, ihren ursprünglichen Entwickelungsplan mit einer oft merkwürdigen Hartnäckigkeit, so gut sie es können, festzuhalten. Von diesem Verhältnisse liefern die bekannten herzlosen Amorphi, die durch einen Zwillingsbruder ernährt werden und dadurch zu einer oft bedeutenden Grösse heranwachsen können, ein schlagendes Beispiel. In unseren Aborten sind zwar diese Amorphi, die keinen Zwillingsbruder zur Erhaltung ihres Kreislaufes gehabt haben, frühzeitig zu Grunde gegangen, und ihre Gewebsteile sind einer fettigen (lipoiden) Entartung anheimgefallen; sie haben jedoch ihre Entwickelung eine Zeit lang fortgesetzt.

"Est is von den verschiedenen Verfassern vielfach von einer Auflösung der Embryonen in der Amnionflüssigkeit und von einer nachherigen Resorption derselben gesprochen worden. Ich glaube indessen, dass diesen Vorgängen eine sehr geringe Rolle beizulegen ist. Man findet in der That gewöhnlich Nichts, was auf eine solche Resorption deuten könne. Es scheinen vielmehr die abgestorbenen Embryonen auch lange nach ihrem Tode eine grosse Wiederstandfähigkeit gegen die Einwirkung, von Amnionflüssigkeit beizubehalten. Ich habe mehrmals ganz kleine, verkrüppelte Embryonen zwar fetig entartet, in ihrer Form aber völlig wohl erhalten, in Eiern gefunden, die bis zu 10 Monaten im Uterus zurückgehalten worden sind. Zudem ist die Amnionflüssigkeit in diesen Eiern meist ganz klar, oder sie enthält nur losgestossene, hinfällige Amnionepithelzellen suspendirt. Wenn daher die Eier ganz leer gefunden werden, so rührt dies gewiss am Häufigsten daher, dass der Primitivestreifen seiner Zeit völlig destruirt worden und somit gar kein Embryo zur Entwickelung gekommen ist. . . . Im Allgemeinen erreichen sie kiene bedeutende Grösse und werden zudem oft frühzeitig aus dem Uterus ausgestossen, in dem sie, wie oben besprochen, ein sehr beträchtliches Contingent zu den Aborten überhaupt liefern. . . .

"Die Traubenmole und die verschiedenen Uebergangsformen derselben, die an Aborten sehr häufig vorgefunden werden, ist als Hyperplasie und secundäre cystoide Entartung des (von Allantois nicht herstammmenden) Chorionbindegewebs vorzugsweise charactertisirt. Die Krankheit wird von pathologischen Zuständen der übrigen Eitheile, Amnion und Embryo (Missbildungen, Verkrüppelungen und frühzeitigem Absterben des letzteren) sehr häufig begleitet. Seltener ist der Embryo regelmässig entwickelt, stirbt aber meist auch dann wegen mangelhafter Vascularisation der (Chorion) Placenta frühzeitig ab. Sehr selten scheint der Embryo ungestört bis zur Geburt sich fortenwickelt zu haben."

But the unregarded observations and also the illustrations of Gierse, a few of which are reproduced in figures 94 and 95 (plate 7, Chap. VII), are still more startling than these opinions and observations by Storch, who knew of Gierse's observations published posthumously by Meckel. The latter quite correctly stated that such careful observations as those made by Gierse always introduce new points of view. If it be remembered that in these days, almost a century later, specimens of hydatiform degeneration which are 4 cm. in diameter still are reported separately as examples of *early* hydatiform degeneration, the great merit of Gierse's observations in this regard alone will be clearly evident upon recalling that he pictured a hydatiform villus from a chorionic vesicle the size of a hazelnut (about 12 mm.), the largest hydatids on which were only one-third of a line large. Moreover, Gierse added:

"Dergleichen geringe krankhafte Veränderungen finden sich an auserordentlichen vielen Abortus, und sie scheinen die häufigste Ursache des Abortus in den ersten Monaten zu sein."

How such an epoch-making conclusion not only could be forgotten, but absolutely overlooked or disregarded, by all but a few of the scores upon scores who

have written on hydatiform degeneration, it is difficult indeed to understand. Gierse, who also took steps to ascertain what normal villi look like, stated that villi with marked irregularities, as described by Desormaux, Breschet, Raspail, and Seiler, undoubtedly were abnormal, surmised that villi in abortuses seldom are normal, and added that between the slight pathologic changes in the caliber of the villi and the most evident hydatiform moles the plainest transitions can be found. Among other important things, Gierse also recognized the early fenestration of the stroma and pictured such a villus under a magnification of 250 diameters. Although reported very briefly, his findings, wholly confirmed here, still wait for general recognition.

Just as the great majority of specimens described in the literature are large, so 4 of the 8 specimens originally classed as such in the Carnegie Collection also are large, and none of the 8 is very young, as the following protocols show:

No. 70 (Dr. Charles H. Ellis) is a small, firm, degenerate-looking, almost solid mass 40 by 30 by 28 mm., composed of small cysts, degenerate decidua, exudate, and degeneration products. It is very similar to a very much larger specimen, No. 323 (Dr. V. Van Williams), a large, firm, felt-like mass 120 by 90 by 65 mm. The individual cysts, which vary from 1 to 20 mm., are packed together rather firmly, though a few large ones are free. The exterior of the specimen is formed by a thick layer of degenerate decidua and gives only a slight indication of its true nature upon closer inspection or upon examination of the cut surface. No fetal remnants were noticed, and microscopic examination shows that the specimen is composed merely of a large hydatiform mass which was retained for a long time and then aborted *in toto* with the surrounding decidua and exudate.

No. 749 (Dr. G. C. McCormick), on the contrary, is a fresh, loose, typical hydatiform mass composed of loose hydatids of various sizes. As the specimen floats loosely in fluid, it fills a half-liter jar about two-thirds. A considerable portion of the hydatid cysts are glued into a solid mass by blood, exudate and decidua, which form a layer on the exterior.

No. 1323 (Dr. J. W. Schlieder) is also a large mass very like the preceding, and completely fills a liter jar. It is accompanied by much clot and composed mainly of a large, thick-walled, hemorrhagic, necrotic mass 80 by 50 by 45 mm., containing a large, thin-walled cavity 65 by 30 by 25 mm., which is broken at one end. This cavity, which apparently is that of the chorionic vesicle, is empty, smooth, and thin-walled, except where it is composed of a characteristic hydatiform mass.

No. 1325 (Dr. Fred R. Ford) is a small, irregular mass 40 by 33 by 20 mm., the exterior of most of which is formed by a thin layer of decidua. Within this is a small group of quite typical hydatid cysts, the largest of which measures about 10 by 5 mm. The appearance of the specimen suggests that it is merely a fragment, though the amount of decidua present indicates that the entire specimen probably was not much larger. The history of this specimen is especially interesting because of the diagnosis of tubal pregnancy, caused by the presence of a cornual myoma and the occurrence of repeated bleeding.

By far the most interesting specimen, in some respects, of hydatiform degeneration among those diagnosed as such upon gross examination, is No. 1640. This abortus, received through the courtesy of Dr. J. W. Williams, measured 40 by 20 by 15 mm. Upon examination, Dr. G. L. Streeter found it to be composed of a flattened decidual and chorionic mass which, upon section, showed "pearl-like vesicular enlargements which suggest hydatiform degeneration." The exterior of this specimen is composed of a thin, hemorrhagic decidua which completely surrounds the villi. The hydatid nature of this clearly is recognizable upon close scrutiny with the unaided eye, and easily becomes evident upon magnification of 12 diameters with the binocular microscope. Examination of the histologic preparations reveals it to be a very fine specimen of relatively early hydatiform degeneration.

No. 1914 (Dr. G. C. McCormick) is a fine, very characteristic mass. It is like Nos. 749 and 1323, but very much larger, for in fluid it completely fills a 2-liter jar. This specimen was said to have accompanied a living 7-months' fetus, having been expelled between the fetus and the placenta. Only a small amount of clot, and what seems to be a small portion of placenta and membranes, accompanied it. Since the placenta was not saved, it is impossible to say whether the mass resulted from partial degeneration of the placenta belonging to the living child or whether it represented a degenerate twin placenta, which is rather unlikely but not impossible, in view of

the well-authenticated cases found in the literature. This specimen is of interest not only for the numerous large, clear cysts, one of which measures 30 by 25 mm., which it contains, but because it accompanied the birth of a living child and because of the relative rareness of such a coincidence. In regard to the latter, Dr. McCormick added that in his experience of over 1,000 labors he had never before met this coincidence. The rareness of the specimen is emphasized still further by the statement of Professor Williams that such an instance has not been observed in a series of over 17,930 osbtetrical cases from the Department of Obstetrics of the Johns Hopkins Medical School, as well as by the small series of such cases recorded in the literature.

No. 1926, a companion specimen to No. 1640, is composed of material from curettage received through the courtesy of Dr. Karl Wilson, of the Department of Obstetrics of the Johns Hopkins Medical School. It was removed from the same patient about a year after specimen No. 1640. Upon gross examination the hydropic nature of some of the villi is plainly evident, and upon microscopic examination the diagonosis of hydatiform degeneration could be confirmed, although the villi were extremely degenerate. The menstrual history of this case fortunately is known and is thoroughly reliable. The last menstruation occurred January 24 and curettage was done August 4. Bleeding occurred every two or three weeks during March and April and was repeated throughout May. Since the uterus, which had reached the symphysis, had not enlarged any for months, in view of the long duration of pregnancy the operation was performed. The major portion of the specimen is very small. The chorio-decidual portion was felt-like in consistency and extremely fibrous, due largely no doubt to the long retention. Most of the accompanying material looks like mucosa rather than decidua, although some of the larger pieces very evidently contained villi. Some of these were relatively thick and fibrous, and others were vesicular. All of the material was extremely fibrous, making it difficult to get a satisfactory teased preparation. Accompanying this material was a small body 5 by 7.5 by 30 mm. Both nodule and stalk contained some remnants of the embryo. Although the appearance of the stalk suggests the umbilical cord, it contains fragments of the body of the embryo, some of which evidently are composed of nerve-tissue.

Microscopic examination of the pedunculated mass further shows it to be composed of degenerate remnants of organs, tissues, and cells. It is partly denuded and partly covered by a layer of fibrous connective tissue which contains local thickenings. In other areas this fibrous layer gives place to a single or more-celled layer, or to polygonal, epithelioid cells. The interior of this specimen is composed of a degenerate jumble including fragments of the central nervous system, the heart, liver, and cartilages. The entire body is chaotic in its structure, and small fragments of the nervous system are scattered throughout its entire extent. This would seem to indicate that the disruption of the tissues was mechanical. The material in which the organic remnants are contained is composed of coagulum, some mesenchyme, cellular detritus, blood, and polymorphonuclear leucocytes, degenerated cells, which appear to have been phagocytic, but which are more likely fusion products or "symplasma" (as Bonnet called them). A few remnants of vessels are found only in the fragments of cartilage.

This short review of the gross appearance of the cases of hydatiform degeneration recognized by the unaided eye with the customary criteria, originally classed as such in the Carnegie Collection, shows that they vary decidedly in their gross, naked-eye characteristics, both as to size and appearance. No. 1640 scarcely is distinguishable as a case of hydatifo m degeneration from gross appearances alone, unless one's attention is directed especially to the matter, but all the rest of the specimens, both small and large, not only are easily recognizable, but are so characteristic that they could not possibly be overlooked. As was indicated above, the incidence of these specimens of hydatiform degeneration among the first 2,400 accessions in the Carnegie Collection was 1 in every 261 abortuses, or more than 8 times the incidence given by Williamson, and 1.3 times that given by Essen-Möller. Although this incidence is so much higher, it does not necessarily contradict the statements of Williamson, for it represents the incidence of hydatiform degeneration in abortuses belonging very largely below 7 months. Nor does it tell the whole story for these months, for since the incidence of hydatiform

degeneration given in the records of the Carnegie Collection is based upon determinations made essentially in the usual way—that is, by unaided inspection of the gross specimen alone—we must regard it also merely as an apparent, not as the *actual*, incidence. For, as will appear later, the actual incidence can be revealed only by a careful gross and microscopic study of all specimens, both normal and pathologic. Such a study has not as yet been completed, but 348 uterine specimens classed as pathologic, and 108 pathologic tubal specimens, contained in the first 1,200 accessions, were carefully examined.

The actual number of cases of hydatiform degeneration found among the 333 chorionic vesicles of uterine abortuses classed as pathologic in the first 1,200 accessions was 105, or 31.5 per cent of the whole. This includes some doubtful cases, but a revision probably would add more than it would exclude. The incidence of hydatiform degeneration in the pathologic tubal pregnancies was somewhat higher even, or 45 specimens of undoubted hydatiform degeneration out of 108, or 41.7 per cent. Since nearly all the tubal specimens are young, while the uterine series contains many more relatively older ones, the effect of this fact upon the determined relative incidence of hydatiform degeneration among the pathologic tubal and uterine specimens must be borne in mind. For a reliable conclusion regarding the relative incidence in the uterine and tubal pregnancies it would be necessary to select a series from each, composed of specimens of approximately corresponding ages. What the incidence of hydatiform degeneration is among the uterine and tubal specimens classed as normal I do not know, but it undoubtedly is far below that in those classed as pathologic. It is well to remember, however, that many, if not most, of the instances of beginning degeneration very likely will be found among the specimens classed as normal. This is well illustrated by a hysterectomy specimen, No. 836, represented in figures 96 and 97.

If we assume that the incidence of hydatiform degeneration among the pathologic specimens in the rest of the Carnegie Collection is the same as that among those in the first 1,200 accessions, then we get over 375 estimated instances of hydatiform degeneration in pathologic tubal and uterine cases alone. Since I have found a number of chorionic vesicles accompanying embryos classed as normal which also show hydatiform degeneration, this number would be increased still further; but unfortunately too few of the specimens classed as normal were examined to justify an estimate. Yet these normal specimens form 60.4 per cent of the first 1,000 and 40.7 per cent of the first 2,500 accessions. This supposed increase, due to inclusion of specimens contained among the normal, would be offset somewhat, however, by the fact that the first 1,000 accessions contain a somewhat larger proportion of young conceptuses, each succeeding 1,000 probably becoming somewhat more representative of actual life conditions. The difference between the composition of the first 1,000 accessions and that of the 1,000 between 1,500 and 2,500 is not very great, however, for the former contains only an excess of 17.6 per cent of cases falling in the first five groups of Mall's classification, which groups are composed largely of specimens below an embryonic length of 20 mm. Then, the relative proportions of tubal and uterine specimens in the different thou-

sands also must be taken into consideration. But in any case, the estimated incidence of hydatiform degeneration in the Carnegie Collection, calculated without regard to those contained among specimens classed as normal, is 8.7 per cent, and the actual incidence hence is probably more than 1 in every 10 accessions.

Estimated on the basis of hydatiform degenerations found among the uterine and tubal specimens classed as pathologic alone, the incidence would be 12.5 per cent of the first 3,000 accessions. Upon this basis the incidence among the uterine specimens alone would be 9.9 per cent, and among the tubal alone 28.1 per cent. This difference of 200 per cent between the tubal and uterine specimens may have some significance in connection with the cause of hydatiform degeneration. That this estimate is not altogether too high is indicated also by the last 392 accessions, the first gross examination of which, made by others than myself, revealed 21 hydatiform degenerations, or an incidence of 5.3 per cent. Since these accessions contained a disproportionately large number of older, naked fetuses unaccompanied by secundines, aborted during influenza, this incidence of hydatiform degeneration undoubtedly is too low. Moreover, no histologic examination has as yet been made. Nevertheless, the incidence among those accompanied by secundines and classed as pathologic was about 14 per cent and among those classed as normal about 4 per cent.

If, as alleged by various investigators, the great majority of abortions occur in the first three months, it is highly probable that many of these early conceptuses are lost and never come to the attention of anyone, and that therefore the proportion of early specimens in this or any other collection is no doubt too small. Moreover, in quite a number of specimens of the first 1,000 accessions the chorionic vesicles were too degenerate for examination and in others they were absent, but we have reason to believe that this is not true to the same extent in the material beyond the first 1,000 accessions. Then, too, since only a few relatively large sections from a single portion of the chorionic vesicles were examined, it is evident that some cases in which the degeneration may have been purely local were probably overlooked. Hence the actual as compared with the recorded incidence of hydatiform degeneration in this collection is probably not merely 8 times but 240 times as great as that given by Williamson (1900), and 33.3 times as great as that given by Essen-Möller.

Most persons will, I presume, be willing to regard an increase of 700 per cent above that of Williamson as possible, but one of 24,000 per cent above Williamson, or even 3,333 per cent above that of Essen-Möller, as wholly out of the question. Yet, strange as it may seem at first sight, this is not a random guess, but an estimate based upn the actual incidence of hydatiform degeneration as determined by a careful gross and microscopic examination of mounted and unmounted material from over 400 abortuses. However, I lay no special emphasis on these percentages, and am using them merely to emphasize the great frequency of hydatiform degeneration. It matters little whether we shall ultimately determine an incidence of 10 or 5 per cent, but it does matter considerably whether we regard the frequency as 5 or 0.05 per cent, for this is a difference in frequency of 10,000 per cent.

In view of the prevailing opinion, I realize that these findings may seem incomprehensible and perhaps incredible, unless it is distinctly borne in mind that it is not stated that this incidence refers to the later months of pregnancy or to term. What the incidence in the later months of pregnancy may be I do not know, but I have called attention to an apparently well-founded belief that it is a relatively rare condition, the estimates ranging from 1 in 2,000 to 1 in 728 or 300 cases.

In regard to the incidence of hydatiform degeneration in uterine specimens, it should also be remembered that the *life*, in contrast to the *laboratory*, incidence for the entire period of gestation is higher, not only because the chorionic vesicles were not included in many of the accessions and because others were too degenerate, but because I have not as yet been able to recognize the very earliest stages with entire certainty. Furthermore, many instances of hydatiform degeneration from the early months of pregnancy, especially the first and second, are inevitably lost. The increase due to these things would be offset somewhat, however, by the lower incidence of hydatiform degeneration in specimens from the last months of pregnancy, relatively few abortuses from these months being contained in the Carnegie Collection.

To what extent the material in this collection is truly representative of actual life conditions is difficult, if not impossible, to determine. This question could be answered only if all the abortuses and material from abortions actually reached physicians, and if the latter sent all of them to the laboratory. My own impression so far is that the material representative of a sufficiently large community probably would have a somewhat lower incidence, notwithstanding the fact that many specimens, not only of hydatiform degeneration, but of abortuses in general, especially from the first month of pregnancy, are lost. However, since the presence of hydatiform degeneration is especially common among early specimens, the inclusion of these might raise the incidence for the whole period of gestation more than the inclusion of all specimens (not excepting those of the last 3 months) would lower it. But the result obtained would represent the incidence of hydatiform degeneration in abortuses alone, and not that in all pregnancies. The latter could be obtained only by including all gestations which end normally. If we accept Pearson's (1897) estimate that approximately 40 per cent of all pregnancies end prematurely, then the incidence of hydatiform degeneration among abortuses would represent very nearly twice that in all pregnancies. Mall's (1908, 1918) estimate of 20 per cent prenatal mortality, on the other hand, would give us an incidence only one-fifth as great as that among abortuses. Hence, the actual life incidence of hydatiform degeneration in all gestations would then be 1 in 10, as based upon Pearson's, and 1 in 25, as based upon Mall's estimated prenatal mortality. But even if, as estimated upon this basis, 4 or 10 per cent of all conceptions end in hydatiform degeneration, this does not necessarily contradict the current opinion regarding its rareness at or near term.

A careful examination with the binocular microscope of all specimens has shown that hydatiform degeneration as a rule is sufficiently general even in young vesicles, so that sections of a single portion about 10 mm. square enable one to

make a fairly reliable diagnosis. Now and then, however, the process seems to be rather irregularly developed, especially in the larger specimens.

In order to determine accurately the question of distribution of hydatiform degeneration over various portions of the chorionic vesicle, it is necessary to examine a series of sections of portions of the chorionic vesicle for each small specimen. This has not yet been done, but since the portions used for microscopic examination had been taken at random *without previous knowledge of the existence of hydatiform degeneration* in any but the 8 specimens so recorded and above described, and since over 450 vesicles were examined, I can not believe that it can often be limited to any particular small area on relatively young vesicles. In these it usually is quite general even if not complete. It is of special interest in this connection that Muggia (1915), after reviewing the small list of cases of alleged hydatiform degeneration of the chorion læve in connection with a study of a case of his own, came to the conclusion that these cases are not really degenerations of the chorion læve, but merely partial degenerations of the placenta. Although I have given no thorough attention to the normal changes in the chorion læve, I am quite certain that they are not the cause of confusion in the series of hydatiform degenerations from the Carnegie Collection. Cases in which whole chorionic vesicles exquisitely hydatiform in character were contained in the tubes, and a number of others which still were implanted within the uteri showed equally exquisite hydatiform changes around the whole perimeter. Such cases as these ultimately confirm the opinion that in young vesicles the condition is, as a rule, general, except perhaps at its very inception. This is true particularly by the time the degeneration has reached a stage which can be considered at all typical in its gross development, as determined by careful examination of numerous specimens with the binocular.

It is especially interesting that, just as soon as typical, hydatid, elliptical villi or portions of the same begin to appear, the condition can be recognized with some certainty under a magnification of 12 to 20 diameters with the binocular microscope. It often was surprising how relatively early stages could thus be detected and the diagnosis confirmed later by histologic examination. Indeed, celloidin blocks of tissue from which sections had been cut gave splendid testimony when examined in fluid with the binocular. One of the not very early stages contained *in utero* and represented in figure 98 could be recognized with the unaided eye; and when examined with the binocular, under a magnification of about 12 diameters, the picture was unusually fine and wholly unmistakable, as shown in figure 99.

That hydatiform degeneration is incomparably more common in the earlier than in the later months of pregnancy, thus justifying the comparison made with measles, is substantiated by statistics covering the material examined. From these it is evident that, excepting cases of large hydatiform masses originally classed as hydatiform degeneration from inspection of the gross specimens alone, practically all of the specimens are relatively young. This is true especially of those from tubal pregnancies, and we may hence regard it as established that hydatiform degenera-

tion is a change which is exceedingly common in the earlier months of pregnancy, just as measles is common in childhood, and that it becomes progressively less common as the end of pregnancy is approached, just as does measles as senility is approached. The obstetrician does not see most of the cases of hydatiform degeneration, for they are merely reported as miscarriages and the specimens often are destroyed or retained unrecognized by the general practitioner or the midwife. They are often aborted spontaneously and completely with the decidua and rarely are still contained in a closed decidual cast when they reach the laboratory.

The spontaneity of the abortion, especially in early cases, was emphasized also by Storch (see page 208). Cortiguera (1906) is reported by Pazzi (1908[b]) also to have declared that many moles disappear wholly without leaving a remnant, even if occurring repeatedly in the same woman, and Donskoj (1911) also stated that many of those aborted do not come to the attention of physicians because of their harmlessness. This, however, does not imply that those which persist and develop into large masses are equally harmless, and it must be remembered that it is upon these that the current opinion regarding the tendencies to malignancy of the hydatiform mole is based.

The conclusion regarding the greater incidence of hydatiform degeneration in the early months of pregnancy is conclusively confirmed by its occurrence in 33 of the 45 tubal specimens, within the first two classes of the pathologic division of Mall, and in 100 of the 105 uterine specimens in the first six classes of this division. Most of the specimens in these classes are composed of villi, of empty chorionic vesicles, or of vesicles with embryos most of which have a length of less than 20 to 30 mm. That hydatiform degeneration is more common in the early months of pregnancy is indicated also by the well-known reports of Kehrer (1894) on 50 cases, and of Dorland and Gerson (1896), who found that 63 per cent of 100 cases had aborted in the fourth and fifth months of pregnancy. According to Seitz, Hirtzman (1874) also found that 62.8 per cent of 35 cases had aborted between the third and six months. Only 2 of Kehrer's 50 cases, or 4 per cent, and only 3 per cent of the cases of Dorland and Gerson aborted at the tenth month. Donskoj stated that 7 of the 10 cases reported by him aborted in the fourth month and none after the sixth month. He stated further that 56 per cent of Bloch's 50 cases aborted before the sixth month, 44 per cent later than this, one being retained until the fourteenth month. The latter case is especially interesting, because retention not only beyond term but after the death of the mole, seems to be regarded as relatively rare. This, however, does not imply that retention beyond the period of growth of the hydatid mole does not occur, although Sternberg (1910), who also emphasized the great rarity of this condition, erroneously stated that the German literature reveals only a single instance of missed abortion in case of hydatiform mole, viz, that of Poten (1901). In this case a hydatiform mole of the size of a duck egg was said to have been aborted approximately one month beyond term. Hence growth must have ceased long before and the mole have remained *in utero* as a "harmless body." To this case of Poten, Sternberg added

a case in which a hydatiform mole 14 by 9.6 by 4.3 mm. was aborted in the twelfth month after the cessation of menstruation. Although Sternberg included 4 cases from other countries among these missed-abortion moles, viz, those o Sheil (undated), Ferguson (also undated), Colorni (1908), and Gaifani (1908), one can hardly doubt that more cases could be added. Since the case of Sheil was one of twin pregnancy, in which one conceptus became hydatiform, it is not at all unlikely that some other cases among this rather small series of twin pregnancies accompanied by hydatiform degeneration may belong in this category.

Mayer (1911) also emphasized the fact that, although instances of retention of fetuses are very common, instances of retention of hydatiform mole are very rare, only a few cases having been recorded. Mayer referred to 2 cases by Kehrer, 3 of Dorland and Gerson, and 1 case of Lange, and reported 4 of his own. These 4 were found among 10 cases of hydatiform mole, an incidence of retention of 40 per cent. They are interesting, especially in connection with the observation of Briggs (1912) that, contrary to current belief, uterine enlargement often is not beyond the normal. Mayer reported that this enlargement was too great in but 1 of the 4 cases, and that retention lasted as long as 4 to 5 months.

At least 3 of the cases of hydatiform mole among those originally recorded as such in the Carnegie Collection belong among retained specimens, as the illustrations alone suggest. But a fair percentage of detached chorionic vesicles included in the list of cases here reported undoubtedly also was retained after the cessation of growth, and it is for this reason that I further emphasize the fact that the uterine volume in a considerable percentage of these cases also, instead of having been too great for the duration of the pregnancy, unquestionably was too small. This is well illustrated by the histories of specimens Nos. 70, 323, 1640, and 1926, and by the specimens themselves.

The average menstrual age of 51 of 112 uterine specimens of hydatiform degeneration—in which the data were available—was 66.6 days, or 2¼ months. As will be seen, this is a far lower average age than heretofore reported, a difference which explains itself from what has already been said. It is interesting that the average menstrual age of 5 of the 8 specimens in the Carnegie Collection originally classed as hydatiform degenerations is 168.2 days, or 2½ times as great, thus being in substantial agreement with the usual results. Three of these 5 are large specimens, the fourth measures 40 by 20 by 15 mm., and the other is composed of small fragments contained in material from curettage. From this alone it follows that the menstrual age is a very uncertain guide, especially to the size of a hydatiform mole.

It may seem superfluous to add anything to the good descriptions of the gross appearance of the *typical* hydatiform mole found in the literature. Such cases are so characteristic that even a novice can recognize them at sight. Yet if the findings reported here are reliable, or even approximately so, it nevertheless must be evident that, in the past, the great majority of specimens of true hydatiform mole have remained unrecognized merely because they did not happen to present the customary, well-known picture *to the unaided eye*. Small chorionic vesicles, such as No.

2077 (shown in natural size in figure 100), which attract no attention upon cursory inspection, may, and often do, present the most exquisite picture of hydatiform degeneration when seen under a magnification of 3 to 20 diameters, as illustrated in figure 101. This is true especially if the examination is made with the binocular microscope. Since I have adopted this method of examination it has been possible to recognize instances of decidedly general and typical hydatiform degeneration in chorionic vesicles less than 2 cm. in size, with later confirmation of the diagnosis by a histologic examination. However, I have not been able to recognize very early stages merely by examination of the gross specimens, for gross recognition is possible only when portions of at least some of the villi have become sufficiently elliptical or globular to attract attention. Histologic recognition is possible far earlier than this, as shown in figure 102.

The general appearance of the whole chorionic vesicle is sometimes an aid in gross identification, for the villi not infrequently are smooth, slightly branched, and unusually long, so that the vesicle looks shaggy, as illustrated in figure 103. Several hydatiform villi from this specimen are shown in figure 104. The typical gross *hydatid* or *watery*, translucent nature of the villi can not be relied upon in early stages, for normally shaped villi that have undergone considerable lysis may be almost transparent and also somewhat more than normally bulbous. However, save in the case of some specimens of tubal pregnancy, the swelling of the villi, due to maceration or to luetic changes, is quite different in character from that characteristic of hydatiform degeneration, and usually quite easily distinguishable from it. Judging from several specimens of villi which were macerated in distilled water during a period of weeks, post-partum maceration never should cause confusion, and the same thing undoubtedly is true of intrauterine maceration. The differences in appearance between macerating villi with disintegrating epithelium, stroma and blood-vessels, and others undergoing hydatiform degeneration, is well illustrated by villi from No. 640, shown in figures 105 and 106. Though photographs can not register all the distinctions, the contrast is so marked in this case that one can not fail to notice it.

Since numerous trophoblastic nodules are present also in other conditions, notably in retained placentæ, as found by Aschoff and others, I have not been able to regard their presence in unusual numbers, in some cases of hydatiform degeneration, as of crucial value, but the absence of placental differentiation at a time when it should be present, with a uniform and unusual development of the villi over the whole exterior of relatively large chorionic vesicles, is decidedly significant and has often been found to imply the presence of hydatiform degeneration. The same thing is true of a very irregular distribution of the villi, or of uniformly distributed fusiform enlargements on the villi and of the loss of the dull appearance of their cut surfaces, as seen under the binocular. As soon as the stroma becomes hydatiform, and even before liquefaction is present, the cut surfaces of hydatiform villi look somewhat shiny and waxy or, perhaps better still, paraffine-like. This was well shown in a previous paper (Meyer, 1920, fig. 21). A bluish tinge is always present, and this appearance is very characteristic. However, how easily a speci-

men of hydatiform mole can be recognized by examination with the binocular alone necessarily will depend also upon the condition of the specimen. If the villi are matted, glued, or macerated, not only the early hydatiform changes, but even fairly advanced ones, are often masked so completely that recognition is difficult or impossible without histologic examination.

In many early specimens the diagnosis could be made at sight from a histologic preparation under low magnification, even when it was impossible to make a diagnosis by examination with the binocular microscope alone. The field of sections of the villi also looks more scattered and the caliber of the villi shows greater variations. What further makes this possible is not, as has been generally assumed since Marchand's epochal work on chorio-epithelioma, the appearance of the syncytium or that of the Langhans layer or of the trophoblast, but the changes in the stroma, which precede those in the epithelium. The evidence in regard to this matter is overwhelming, and in the early stages, when the stroma already has been altered, it often is impossible to tell whether the epithelial development is normally or abnormally active. Moreover, in spite of Marchand's conclusion, extremely large hydatid vesicles often have but a single smooth layer of epithelium. This has been asserted repeatedly by other investigators also. The two layers of epithelium are not by any means always present, and, while there is no agreement in the matter, the opinion nevertheless seems to be that the grade of epithelial proliferation can not be used as a criterion for the determination of the presence of hydatiform degeneration.

Langhans (1902) also stated that Marchand overemphasized the presence of epithelial proliferation, and rightly declared that all sorts of gradations occur between normal and hydatiform villi. Indeed, unless hydatiform villi invariably arise as such when the earliest villi appear, or arise *de novo* later, all gradations necessarily must exist between normal and hydatiform villi, thus contradicting Marchand's conclusion.

Menu said that the presence of marked epithelial proliferation was emphasized early by Müller (1847), Ercolani (1876), Franque (1896), and Owry (1897), and according to Pazzi (1908[b]), Ercolani, and even Polano, denied the existence of connective tissue in the hydatiform mole. The same thing was asserted by Sfameni (1905), who claimed to have found further evidence of the exclusively epithelial nature of the hydatiform mole. According to Sfameni, the hydatiform mole does not result from a modification of existing chorionic villi, but from an entirely new growth which is wholly epithelial in character! But this opinion, which was accepted also by Niosi (1905), seems to exist among Italian writers only. According to Acconci (1914[a]), marked proliferation of the epithelium occurs also in toxæmia of pregnancy and in nephritis. A number of investigators have found it common also in long retention.

I am unable to confirm the observation of Nattan-Larrier and Brindeau (1908) that the syncytium of hydatiform villi breaks up into individual portions which do not undergo degenerative changes, but penetrate deeper into the decidua. These investigators thought that in normal villi the plasmodium always keeps its

continuity with the proliferating Langhans layer, and that the syncytial masses were more angular in form, of smaller size, and contained retracted nuclei. The syncytial masses on the hydatiform villus, on the other hand, were said to be more rounded in outline, elongated or polygonal in form, and to possess large nuclei very rich in chromatin.

Although Durante (1898) represented extremely long syncytial buds, he nevertheless found (1909) epithelial proliferation present only where certain vascular changes were present. Winter (1907) stated that the condition of the epithelium varies greatly, and Falgowski (1911) emphasized that he could not demonstrate the presence of an increased epithelial proliferation or of vacuolation of the syncytium. Amann (1916) also found that epithelial proliferation may be wholly absent.

That the degree of epithelial proliferation varies greatly, and necessarily so, not only in the villi of the different vesicles but in those of the same vesicle, is splendidly illustrated by the villi of No. 720*b*, shown in figures 107 and 108. In the former epithelial proliferation has not extended beyond that required by the increase in surface due to the increase in caliber of the villi, while in the latter a very long, branching epithelial framework and smaller processes are present. Likewise, in figure 109 (No. 540), the large villi show little epithelial proliferation, while the small villus to the right shows very marked proliferation. Nor are the variations in the degree of epithelial development limited to different villi of the same specimen, for they may be present even in the same villus. Ballantyne and Young (1913), on the contrary, found epithelial proliferation "so well developed that it suggested that it is an essential process in the formation of the mole." They further likened hydatiform degeneration to edematous growths and emphasized that both really are epithelial new growths. This opinion is accepted also by de Snoo (1914), who regarded the hydatiform mole as a neoplasm of the trophblast with secondary changes in the stroma.

There is no agreement at present as to whether the epithelial changes are primary or secondary. As is well known, Marchand (1895), and Müller, Ercolani, and Langhans long before that, regarded the epithelial changes as primary, but most investigators seem to have come to an opposite conclusion. Some share the opinion of Schroeder that hydatiform degeneration points to a stimulus resulting in hyperplasia of the entire chorionic villus. Nor is there agreement as to what the initial changes are. Durante (1909) regarded the presence of vessels with an imperfect endothelial lining and with thick infiltrated walls as the initial lesion in hydatiform degeneration. These changes were noted by him, especially in trunk villi, and epithelial proliferation was most evident where the vascular lesions were most pronounced. Durante further stated that the chain form of the hydatids is due to the fact that the vascular lesions occur at intervals along the villus. Unfortunately, the structure of long hydatiform villi does not confirm such an explanation nor Durante's conclusion that the hydatid cavities within the villi result from dilatation of the capillaries. Many investigators report the early disappearance of the blood-vessels, a phenomenon which some regard as secondary and others as primary to the death of the embryo.

In the course of this investigation a villus with a normal stroma and normal vascularization never was found to have undergone true hydatiform degeneration, but one with a normally active epithelium—both Langhans layer and syncytium—often was truly hydatiform. That is, it not only was watery in appearance, but also fusiform or globular, even in external form. In fact, Marchand (1895) himself found that "Das Epithel welches die Zotten und ihre Anschwellungen bekleidet zeigt ein sehr verschiedenes Verhalten." Yet even today the feeling on the part of many seems to be that unless a marked hyperplasia of the Langhans layer and of the syncytium is present the condition is not one of hydatiform mole. This position seems to me to be untenable, for, as Marchand himself said, the change in epithelium usually is least in the young villi, and it must be added that it is unrecognizable in the early stages and in young conceptuses. A perusal of the literature descriptive of the actual cases leaves little doubt upon this point, and a careful study of the advent of the earliest recognizable changes in hydatiform mole is absolutely convincing. The earliest *recognizable*, even if not the incipient, changes occur in the stroma and in the vessels and not in the epithelium. In passing, it may be noted that although Marchand stated that the change in the epithelium is primary, he nevertheless somewhat contradictorily added that the most important fact is the degenerative change in the stroma of the villi.

Although not applicable to what I have come to regard as the incipent changes in hydatiform degeneration, it nevertheless is true that the stroma often, if not always, quite early becomes hydatiform—that is, glassy or clear, though not necessarily watery. Moreover, the villous vessels often degenerate or disappear completely at a very early stage.

Various grades of hydatiform degeneration with vitreous stroma and vessels in various stages of disappearance are shown in figures 110 (No. 977), 111 (No. 516), 112 (No. 874*b*), and 113 (No. 396). The first and last of these specimens are in a splendid state of preservation, so that maceration changes really can be wholly eliminated. It is exceedingly difficult to make any definite statement as to what is typical regarding the epithelium. This has been said by others also. Indeed, this necessarily follows from the fact, agreed to by every one, that histologically there is no true line of demarcation between the ordinary benign hydatiform mole, the so-called destructive benign (?) hydatiform mole, whatever its status may be, and the malignant hydatiform mole or chorio-epithelioma. Such a conclusion alone presupposes the existence of the widest differences in the condition of the epithelium in these cases, and that such differences actually exist is beyond question.

Marchand's revolutionary investigation on chorio-epithelioma notwithstanding, the epithelium is not always two-layered, nor is it always thickened, in hydatiform mole. That the epithelium can not always be active beyond the normal follows also from the fact that the proliferative changes in it are subsequent to, even if not necessarily consequent upon, changes in the stroma. Furthermore, like the latter, they are gradual in their evolution and may stop or be stopped at any stage of their development. Then, too, the condition of the epithelium

depends very largely upon the preservation of the abortus, and this, as is well known, varies greatly. Finzi (1908) also found that the epithelium may be perfectly preserved or totally destroyed, and that central degeneration is the most noticeable thing and due to the absence of vessels.

However, the most striking thing about the epithelium usually is not its thickness, the presence of large masses of trophoblast, or of numerous syncytial buds, but its splendid state of preservation, especially as contrasted with that of the stroma. This is true of all except macerated or degenerate specimens, for the life of the epithelium seems assured as long as there are periodic accessions of fresh blood, which, as the clinical histories illustrate, is usually the case. The stroma, on the other hand, probably not being wholly independent of the contained capillaries, is deprived very largely of its sustenance during, even if not in consequence of, their degeneration. According to some, hydatiform degeneration of the stroma is the result of an accumulation of nutritive products in consequence of the absence of the vessels. Degeneration of stroma and vessels, however, may result from malnutrition due to poor implantation. Daels (1908[b]) reported that the stroma was densest where the syncytium was thickest, and most rarefied where it was thinnest, but I could not determine such a relationship.

The epithelium of the villi often was found single-layered without any syncytium whatever, or with at most a few syncytial buds. Nevertheless, both the syncytium and trophoblast very often show evidences of a marked activity not confined to implanted villi or to the epithelium of the villi as a whole, but which extended to that of the chorionic membrane as well. Surprisingly long, complex, syncytial buds, whorls, and festoons, as shown in figures 114 and 115, said to have been observed by Fraenkel, often are present, especially on the villi, although in a few instances fine buds and frameworks of syncytium also were seen arising from the epithelium of the chorionic membrane. This feature (shown in fig. 115) has, I believe, not been specially emphasized heretofore, though observed by Clivio (1908).

Mounds formed by the Langhans layer were common, especially on the tips of the villi where they frequently formed irregular masses of small nodules—the "appendici durate" of Crosti (1895). These gave the villous tree the appearance of a leafless orange loaded with fruit, only that the trophoblastic nodules are mainly apical, as shown in figure 116. In several instances syncytial buds were found far out on these trophoblastic masses, a fact which is of special if not of crucial significance in connection with the old question of the origin of the syncytium, for these buds undoubtedly had not been transported there. But, however one may regard these things, such appearances as represented in figure 9 (plate 1, Chapter IV) are unmistakable, for they show thickenings composed of Langhans cells and garlands of considerable length, portions of which are composed of absolutely distinct cells of the Langhans type, as well as other portions composed of syncytium with every gradation between the two. Nor do I believe that the assumption that syncytium can resolve itself into individual cells can be used to deny the implication of these facts.

Although hydatiform villi covered by a single layer of rather small cells of the nature of Langhans cells, sometimes without visible cell boundaries, frequently were seen, villi covered by typical syncytium only were never seen. The single layer present, although syncytial in places, suggested Langhans cells rather than the real syncytium. Moreover, since the cells of the Langhans layer usually were smaller rather than larger than normal, it follows from this alone that their proliferation nevertheless must have been marked, in order to completely cover the enlarged villus, in spite of the fact that the layer remained single-celled. Were this not the case the extraordinary increase in size which accompanies the formation of large hydatid cysts could not possibly occur without rupture of the covering layer.

Not infrequently proliferation of the epithelium without increase in thickness may manifest itself in another way. The caliber of the villi in the earlier stages of hydatiform degeneration sometimes does not increase much and no thickening of the proliferating epithelium is noticeable, yet the latter shows marked proliferation. Under these circumstances, the borders of the villi and of the chorionic epithelium may appear extraordinarily sinuous, as illustrated in figure 117, and epithelial invaginations from opposite sides may in rare instances meet in the center, as indicated in figure 118, and, by fusion, completely isolate a portion of the stroma. It is usually in these cases of very sinuous epithelium that the epithelial invaginations sometimes become constricted, leaving a closed epithelial vesicle or a nodule of epithelium attached to a stalk or wholly isolated within the stroma, as shown in figures 119 and 120. All stages in this process of vesicle formation were found, and rarely also extensions of epithelial sprouts, as described by Neumann (1897) and others, were seen, portions of which had become isolated in the stroma to appear later as typical syncytial giant cells. These facts, too, would seem to throw a sidelight upon the origin of the syncytium for those to whom this question is still an open one.

All these things abundantly testify to the activity on the part of the epithelium in many hydatiform moles, even when thickening of it is absent, but they are of diagnostic value only if present, and I wish to emphasize again that they may be wholly absent and also unrecognizable in the early stages. Moreover, the degree of epithelial proliferation varies greatly, as illustrated in figures 112, 121, and 122.

Until I am able to learn more about the structure of normal villi in various stages of development, I am not willing to commit myself regarding the earliest changes in hydatiform degeneration. These may be unrecognizable with present methods. However, it is possible to say that in young conceptuses the disappearance of the capillaries, which was regarded as a posisible cause for the development of hydatiform mole by Hewitt (1860, 1861), and which was emphasized later by Hahn (1864), Maslowsky (1882), and also by others, undoubtedly is a very early and possibly the very earliest *noticeable change in some cases.* I do not imply that death of the embryo is the cause of this disappearance, as Hewitt held, and I am not ready to say that the vascular change is the very earliest one in all cases. This would imply that hydatiform degeneration under no circumstances can

begin before the capillaries have appeared in the villi. There is some evidence which suggests that it possibly may appear before this time. If so, it would be incorrect to speak of a disappearance of the vessels in such chorionic vesicles, for if the advent of hydatiform degeneration can precede the appearance of the villous capillaries, vascularization of the villi may never occur. In older conceptuses, however, in which vascularization of the villi has supervened, the first recognizable change is the disappearance of these capillaries. Many specimens in which the latter were in various stages of degeneration were examined carefully, and the opinion of Hewitt (1860) that hydatiform degeneration can not arise in villi which have been vascularized can be regarded as of historical interest only. Different stages in the process of vascular degeneration are represented in figures 123, 124, and 126, and in figures 109 to 112, inclusive.

Coincident with the disappearance of the vessels, also noted by Vecchi (1906) in villi with vesicles only as large as a "millet" seed, changes in the stroma also are noticeable. Usually it tends to become glassy, the individual nuclei becoming separated farther. The stroma, though apparently solid, is uniformly slightly bluish and vitreous, with well-defined, rather small, pycnotic, pointed nuclei, but with not a vestige of a vessel, though the epithelium be splendidly preserved. The latter may be one or two layered, and may be accompanied by syncytial buds and trophoblastic masses and nodules. In such specimens the entire picture really is exquisite, and a mere glance through the compound microscope reveals the lack of vessels in the vitreous stroma, its sparseness, and the marked differences in size of the sections of the villi.

After these early changes, liquefaction of the stroma usually follows. As is well known, it generally begins in the interior and first appears in the form of vacuolation; but this vacuolation (which I can not regard merely as an edema) is not intracellular but intercellular, and as it becomes more pronounced it really takes on the nature of fenestration. Sections of the whole cross-section of the villi, even though large, may be composed of a series of fenestrae (see fig. 125) separated by exceedingly fine strands of the remaining stroma which may contain remnants of the nuclei. But finally, even the fine trabeculæ separating the fenestræ disappear, and the stage of the watery, old, hydatid condition has been reached. More generally, however, the vacuoles or small fenestræ lying in the middle become confluent at the center of the cross-section of the villus, which then is liquefied completely. As is well known, this liquefaction gradually extends to the periphery as the zone of the surrounding stroma is narrowed in the process. Not infrequently, however, liquefaction of the stroma occurs quite generally throughout the cross-section of the villus and is accompanied by the formation of numerous large cells—the wandering or migrating cells of earlier writers. A few of these cells almost always can be found, and rarely the whole section of the villus is studded with or even formed by these large, erratic cells, which usually lie in fenestræ in the stroma (fig. 127.) In other instances a large portion of the sections of the villi may be occupied by them, as shown in figure 128. The presence of these cells in villi regarded as normal has long been known. Their presence in hydatiform

moles was noted by Otto, Marchand (1898), Essen-Möller, and many others. Their occurrence in normal and pathological chorionic vesicles and their significance are considered in Chapter XV. No matter what the condition of the epithelium (or, more specifically, the Langhans layer), the syncytium, and trophoblast may be, the above-noted changes in the stroma always are quite typical. They are not the only changes noted, however, and may differ somewhat as to the time of their advent.

Not infrequently, changes quite comparable to those in the villi occur also in the stroma of the chorionic membrane itself, a fact which has not heretofore been emphasized. It, too, frequently is decidedly glassy; liquefaction may occur here and there and may become complete in the course of time. Hofbauer cells also are not uncommonly present. Among the changes noted in this membrane, the disappearance of the vessels is the most common and constant, although epithelial proliferation is not rare, as already stated. Moreover, when (as in one of Storch's cases) a hydatiform villus is 15 cm. long, one scarcely can doubt that the stroma also must have proliferated—not merely degenerated. Some of the strings of hydatid cysts in a specimen in the Carnegie Collection have a length of 10 to 12 cm., and in these cases also one can hardly assume that this increased length of the villi was unaccompanied by proliferation of the stroma. From these things alone it follows that the stroma can not remain passive always, although Gromadzki (1913) concluded that it never proliferates. Vecchi (1906), however, reported an increase in the stroma of the villi, and it will be recalled that Marchand also implied the presence of proliferative changes in the connective tissue when he wrote that they depend upon those in the epithelium.

I have never been able to find mitotic figures, a fact which may be accounted for, however, by the presence of degenerative changes due to intrauterine separation and retention of most specimens. Indeed, the failure to find mitoses speaks against proliferation in the stroma no more than in case of the epithelium, in which the presence of karyokinetic figures has been reported by a few investigators only. Yet pronounced proliferation of the epithelium is often present. The failure to find mitotic figures very likely is due to the condition of the material.

Careful scrutiny of a large series of specimens has revealed the fact that the disappearance of the vessels in the villi, in the chorionic membrane, and also in the umbilical cord is centripetal as a rule. However, in many specimens the vessels not only may be present in the chorionic membrane, although absent in the villi, but may be very numerous and even engorged with blood. It is difficult to say to what extent the engorged condition of these vessels and of those in the body of the abnormal embryos sometimes contained in these hydatiform moles is due to the propulsion of the contained embryonic blood before the advancing vascular constriction and degeneration, but I am inclined to believe that the centripetal movement of the process is not a negligible factor in this matter.

Although only a few instances of the birth of a living fetus or of a fetus which has reached the later months of pregnancy are recorded in the literature, it is now quite generally recognized that the fetus, though dead and too small for its men-

strual age, usually is present. This stands in contradiction to the earlier belief illustrated by the statement of Gierse (1847), that the fetus usually was reported as absent, and that when present (as in the cases of Meckel, Gregorini, Otto, Cruveilhier, and his own) it was usually less than an inch long, even when retained for a period of from 3 to 10 months.

This apparent contradiction regarding the presence of the fetus in hydatiform moles is explained easily by the fact that the cases in the earlier literature are old, far advanced in degeneration, while the more recent literature contains many more in the earlier stages of degeneration. Yet in spite of this fact the earlier opinion survives to the present day, for Graves (1909–10) spoke of "the very unusual presence of a normal fetus inside a mole," and Vineberg (1911) still more strangely held that the presence of a fetus excludes the specimen from the class of true hydatiform moles!

Among the specimens concerned in this report many contained a fetus. This was true of 24.5 per cent of 49 tubal and 64.4 per cent of 121 uterine specimens, including some (9) doubtful cases. The fetal length ranges from 1 to 90 mm. in the uterine and from 1 to 80 mm. in the tubal series. Although the average length of the embryo in the tubal series is 12.3 mm., and that of the uterine only 10.1 mm., 58 per cent of the tubal specimens nevertheless were below 7 mm. in length as contrasted with 52.5 per cent of the uterine. The presence of a fetus with a frequency almost three times as great in the uterine series again indicates that the abnormal conditions within the tubes lead to early death, digestion, and absorption, or at least to dissolution, of the embryo. This fact again points directly to a faulty nidus as causative agent, for if the absence of a fetus is to be laid to primary ovular defects, then one must admit that relatively far more of such diseased ova become implanted within the tube than within the uterus.

In some early specimens the fetus is in a state of excellent preservation. This is what one might expect, for the onset of hydatiform degeneration is gradual and may remain partial. The condition of the fetus alone in many of them also suggests that its death was secondary to the degeneration.

This is exemplified splendidly by No. 2099, shown in figures 129 and 130. This cyema shows the presence of undoubted maceration changes throughout, but especially in the branchial region and on the umbilical cord, and the shaggy chorionic vesicle shows the presence of a moderate degree of hydatiform degeneration. A more advanced instance is that of No. 1260, shown in figures 131, 132, and 133, in which the form of the cyema is greatly modified and the hydatiform nature of the villi much more obvious. That the death of the embryo is not the cause of hydatiform degeneration would seem to be evident also from such instances as No. 2250. In this case of twin pregnancy both fetuses are well preserved, as figure 134 shows, and yet the respective chorionic vesicles show the presence of well-developed and quite general hydatiform degeneration as can be seen in figures 141 and 142 (plate 14, Chap. X). Indeed, in this instance the fetuses show less maceration change than the vesicles, and it is particularly interesting that this

abortion was attributed to influenza, although, in view of the presence of hydatiform degeneration, it was inevitable. Influenza, to be sure, may have been the immediate cause and may have precipitated the abortion, but uninterrupted development of the hydatiform degeneration also would have done so. Moreover, the appearance of both fetuses suggests that they died shortly before the abortion, and this is confirmed by a comparison of the menstrual and anatomical ages, which differ by 6 and 10 days, if the larger or smaller fetus is used for the determination of the latter age. However, if we can finally assume that the menstrual age of all conceptuses exceeds their true age by about 10 days, then they must have lived up to the time of abortion, or, strictly speaking, a few days beyond it. That death of the cyema is not the cause of hydatiform degeneration is indicated also by such specimens as No. 2411, represented in figures 143 and 144 (plate 14, Chap. X), a twin, double-ovum pregnancy, in which both the cyemata and the chorionic vesicles show considerable and apparently the same degree of maceration (figs. 145 to 147). Since both chorionic vesicles also show the presence of quite general hydatiform degeneration, it is evident that if the latter had arisen only after the death of the cyemata the vesicles should not show anything like a corresponding degree of maceration, unless perhaps the time of retention had been considerable.

Many other specimens of single pregnancy could be used to illustrate the same thing, and since the development of hydatiform degeneration undoubtedly is not a fulminating one, it might be expected that considerable development of it might occur before the death of the cyema, which is due apparently to the obliteration of the villous circulation. Since blood-vessels can and do arise in the chorionic villi quite independently of those in the cyema, it also seems possible that young chorionic vesicles showing hydatiform villi with disappearing blood-vessels may be found, even if the intra-cyemic circulation never developed or never united with the extra-cyemic or chorionic circulation. Such a surmise does not imply, however, that hydatiform degeneration never begins before the blood-vessels appear.

Of the many explanations which have been offered for the advent of hydatiform degeneration, none seems to be better established than that of endometritis. This was first emphasized by Virchow (1863). Lwow (1892) also reported 4 cases in patients under his care in whom lues could be excluded, and in whom he held endometritis responsible. Emanuel (1895) was the first, it seems, to demonstrate the presence of cocci in inflammatory foci of round cells in the decidua accompanying a case of hydatiform mole. Veit (1899) also believed that disease of the decidua is the cause of hydatiform degeneration. Veit further stated that Waldeyer, Jarotzky, and Storch also believed that an irritative condition of the decidua is responsible. Stoffel (1905) also found cocci other than gonococci present, and says he can not avoid holding endometritis responsible in his case. The association of hydatiform degeneration and endometritis was noted also by Marchand (1895), Oster (1904), and Sternberg; also by Essen-Möller, who reported the phe-

nomenal case of a woman with endometritis, who had aborted a hydatiform mole 18 times in 9 years. Falgowski, on the contrary, concluded that the ova themselves were diseased and argued that hydatiform degeneration should be much more common if it were due to endometritis. Taussig (1911) also stated that leucocytic infiltration of the decidua is frequently present in hydatiform moles, but insisted that "leucocytic infiltration in the placenta then should not be interpreted as infection. . . . Inflammation and infection should be kept apart." I presume Taussig really meant *infiltration* and infection should be kept apart, and the question then turns upon the structure of the normal decidua and the significance of infiltration for the development of the ovum.

It may be recalled that Marchand (1904) reported the presence of isolated groups of small cells in the normal decidua which looked like mononuclears under low magnification, and which he believed have often been confused with them. But even granting this, and the further facts that the exact histologic changes in the decidua are not fully known, and that it is rather difficult to ascertain just what decidual changes are regarded as evidence of the existence of an endometritis, any one examining a large series of cases of hydatiform degeneration aborted with the decidua can not doubt the presence of marked decidual changes in a very large percentage of them. These changes are not limited to infiltration with scattered round cells or erythrocytes, or to focal accumulation of the same, but often extend to almost complete fibrosis, as shown in figure 135, plate 13 (see Chap. IX), so that experienced investigators have mistaken the thin, fibrous decidua for a part of the chorionic vesicle.

It is true that the existence of these changes in the decidua does not necessarily imply that they were antecedent to the implanation of the ovum, but fortunately the clinical histories and material from curettage often supply crucial evidence. From such cases and from the cumulative weight of evidence from the large series of cases here reported, the great majority of which showed decidual infiltration or other changes suggestive of endometritis, the frequent association of abnormal deciduæ with hydatiform degeneration is evident. The fact that the incidence of hydatiform degeneration in the tubal was considerably higher than that in the uterine series might be regarded as contradicting this relationship, but such is not the case. The mucosa of the tubes at best is an unfavorable nidus for implantation because of the absence of decidual formation alone. Hence, even if salpingitis were somewhat less frequent than endometritis, difficult nidification in the tube could easily more than account for the existing differences. Hence the higher incidence of hydatiform degeneration in the tubal series in fact becomes confirmatory of the conclusion that abnormal nidification really may be responsible for the advent of hydatiform degeneration.

The only fact which might be interpreted as indicating that germinal defects primarily are responsible for the development of hydatiform degeneration is the *relatively* higher incidence of the condition in older women. Against this, however, stands the other fact that such women also show the cumulative effects of endometritis and pregnancy upon the endometrium. Furthermore, since hydatiform

degeneration so often follows one or two normal births or abortions, it would be impossible to find an adequate explanation for the release of the defective ova so often after and not before these events.

I am reminded also in this connection of a case the detailed history of which is fully known. It is that of a robust young woman who successively gave birth to two moles and then to a normal full-term child and secundines. In this case curettage was done in connection with each mole. Apparently the new endometrium, which had formed after the second abortion and curettage, permitted normal implantation and normal development to progress to term. To ignore the condition of the endometrium in this case and attribute the development of hydatiform degeneration to the successive releases of abnormal ova would seem to disregard important facts—especially so since no one has established the occurrence of abnormal ova within the Graafian follicle, a possibility which I do not wish to deny, although Donskoj's report of a case of hereditary mole must surely be taken *cum grano salis.*

That an abnormal nidus may be responsible for the advent of hydatiform degeneration would seem to be indicated also by the fact that the process usually was better developed and more general in the tubal than in the uterine cases. That both endometrium and decidua show astonishing differences in structure under pathologic conditions is well known. The entire tubal mucosa, on the other hand, even when normal, forms an abnormal nidus which would affect all portions of early chorionic vesicles somewhat alike, and since, as found by Mall, inflammatory conditions in the tubes predispose to tubal implantation, the higher incidence of hydatiform degeneration in the tubes is easily explained. Nor does the existence of partial hydatiform degeneration argue against such an explanation.

Although Kehrer reported not a single fatality in 50 cases of hydatiform mole, Hirtzman (according to von Winckel) gave the fatality as 13 per cent, Dorland and Gerson as 18, and Williamson as 20 to 30 per cent. Von Winckel (1904) regarded these percentages as entirely too high, however, although Oster (1904) reported 2 cases of malignancy out of 15 cases in which the late results were ascertainable. This is an incidence of 13.3 per cent. Since none of 15 patients who had suffered from hydatiform mole had a recurrence, Oster concluded that the cause of hydatiform degeneration is a fortuitous one. Schickele (1906) stated that only 3 cases of hydatiform mole with coincident chorio-epithelioma were found in the literature; and Nattan-Larrier and Brindeau (1908) seem to avoid the implied difficulty by premising the existence of a histological as contrasted with a clinical malignancy, a distinction which recalls the conclusion of Schickele that it does not follow that not all hydatiform moles are malignant merely because not all of them cause the death of the patient. Kroemer (1907) found that chorio-epithelioma developed in 5 out of 15 cases of hydatiform moles, or in 33.3 per cent, but only twice in 3,841 "normal implantations." Daels (1908) says La Torre claimed a malignancy of 64 per cent, de Senarcleus one of 28.7 per cent, or 14 out of 49 cases. L. Fraenkel (1910[a]) emphasized that the estimates of the number of cases in which hydatiform degeneration is followed by malignant disease vary greatly, while

Robertson (1915) quoted Findlay as finding that 16 per cent of 250 hydatiform moles collected from the literature were followed by malignant disease. Briggs, who reported 21 cases of hydatiform degeneration with 2 of chorio-epithelioma, or an incidence of malignancy of 9.5 per cent, called attention to the "diminishing ratio in the tendency to malignancy" shown by his series.

Findlay (1917) stated that chorio-epithelioma developed in 131 out of 500 cases gathered by him from the literature, which is an incidence of 26.2 per cent, but, as already stated, most of these cases from the literature are old, advanced degenerations, many of which have been retained for a long time. The tendency to malignancy in these probably can in no way be compared to that in smaller and younger specimens, many of which are aborted entire with the surrounding decidua. Consequently it need not surprise us that out of 19 cases of this series, in which later reports were obtainable, none was reported as having developed chorio-epithelioma.

Perhaps I may add a word of caution in regard to a possible change in attitude toward the question of malignancy with a consequent relaxation of vigilance. It is true that out of the 21 cases of Briggs only 2 developed chorio-epithelioma; but it must not be forgotten that Briggs in part was, and I to a far larger extent am, dealing with a different class of hydatiform moles than those upon a study of which the prevailing conception of malignancy is based. Hydatiform moles which continue to grow and which survive for months after the death of the embryo evidently are more vigorous, and hence no doubt also more dangerous than those which are aborted early and spontaneously. Since the latter formed the great majority of all moles here considered, opinions regarding malignancy formed on this basis probably would lead to disaster if applied in practice. Such conceptions would be based upon a totally different incidence than the current one of 1 hydatiform mole in every 2,000 cases. Instead of relaxing our vigilance, it would seem wise to increase it, particularly in the cases of so-called spontaneous abortions—the cases in which no ascertainable cause for the termination of pregnancy can be found, especially if the chorionic vesicle is empty or if the embryo belongs in one of the early groups of Mall's classification.

The average age of 36 women aborting hydatiform moles was 31 years. Although I do not regard the *alleged* ages as necessarily the *actual* ones, this average age agrees very well with that of 6 cases reported by Poten, 10 by Donskoj, 23 by Briggs, 6 by Gromadski, and 8 by Robertson. The average age of Poten's cases was 32 years, of Donskoj's 25 years, of Brigg's 28 years, of Gromadski's 29.6 years, and of Robertson's 28.4 years. Pazzi (1908[b]), on the other hand, stated that Briquel placed the greatest frequency of hydatiform degeneration between 20 and 30 years. These averages are so far on the near side of the menopause that one can make liberal allowances for the proverbial disinclination of women to state their exact age, even to physicians, and nevertheless regard the prevailing opinion regarding the greater frequency of hydatiform mole near the menopause undoubtedly as ill-founded. If, as Lewis and Lewis (1906) stated, it is necessary to add only half a year to the average age of a large group of women in order to ascertain

the actual average age when considering general social statistics, then everyone will admit that still less allowance than this need be made in the case of women who are speaking to their physicians, knowing that whatever they may say will be regarded as strictly confidential. That it is unnecessary to make large allowances for understatement of their age on the part of these women is indicated also by the average duration of their married life before aborting moles. This in the case of 29 women was 7.1 years. Hence, if one bears in mind that the average age of first marriages, according to Webb (1911), is 25.1 years, one easily can see that the average age of the women aborting hydatiform moles, which was given as 29.6 years, probably is not too low at all, thus confirming the findings of Williamson, who denied that hydatiform mole was especially common near the menopause.

The conclusion that the average age of 29.6 years undoubtedly is near the actual is confirmed also by the fact that a hydatiform mole was the first abortion in 19 out of 41 women, or almost half the number; 12, or almost one-third, had aborted twice; and only 10 had aborted more than twice. But what is still more confirmatory is the existence of a surprising parallelism between the data on abortion and those on births; 9 of 33 women had given birth to but 1 child, and an equal number had given birth to but 2. Hence over 50 per cent of the 33 women had borne children twice, or less than twice, and only 15, or less than half, had borne oftener than this.

This undoubted evidence of the youth of these women is confirmed still further by the statement of Lewis and Lewis, who, from an analysis of 16,325 first births, found that nearly one-half of them occur between the ages of 20 and 24, and almost three-fourths between 20 and 29 years, although first births are more frequent between 30 and 40 than between 15 and 19 years. I realize that social statistics can not be translated from one country to another without modification, but in such a mixed population as ours this modification probably need be less, rather than greater, than in case of some countries.

The conclusion that the occurrence of but a single birth before the advent of hydatiform degeneration probably implies that such women are relatively young is emphasized still further by the statement of Lewis and Lewis that in one-third of the marriages in Scotland "the bride had a child when unmarried or was pregnant at the time of marriage," and that 50 per cent of the first births in Scotland occur within 9 to 24 months after marriage. Lewis and Lewis also give the average interval between marriage and the first birth in 16,176 cases as 13.54 months, but little more than one year. Since Lewis and Lewis stated that the interval between the birth of the first and that of the second child is but little longer than that between marriage and the birth of the first child, being only 3.07 years, it is evident that not even those women who had borne two children before the advent of hydatiform degeneration could have been near the menopause. This conclusion is emphasized still further by the fact that in 96.12 per cent of 16,176 fruitful marriages fertility was demonstrated within three years after marriage.

Nevertheless, in spite of the clear implication of all these facts, I wish to emphasize again that since what have been heretofore regarded as hydatiform

degenerations were large specimens mainly, it well may be, and according to certain authors it is true, that such cases occur later in the reproductive life of women. Yet it certainly is significant that Findlay, in tabulating 500 such cases from the literature, found that 275, or 55 per cent, occurred before the thirty-fifth year, and of 36 specimens from the Carnegie Collection 23, or 63.6 per cent, came from women below this age. It may also be recalled that 78 per cent of Kehrer's 50 cases and 90 per cent of Bloch's occurred before the fourth decade. That hydatiform degeneration may occur very early in life is suggested by the remarkable case of Stricker (1879) in a precocious child of 9 years.

Fourteen out of 23 cases, or 61.3 per cent of the uterine series, in which the age was given, occurred at or before the thirtieth year, and 18, or approximately 80 per cent, at or before the thirty-fifth year. These things abundantly emphasize the conclusion, reached by some investigators, that hydatiform mole is not *absolutely* more common at or near the menopause; but it nevertheless may be *relatively* more common. That is, the number of hydatiform moles aborted after 40, compared with the total number of pregnancies or births after 40, actually may be greater than this ratio before 40 years.

From calculations based on data given by Lewis and Lewis, the average number of births occurring after 40 years in Sweden, Norway, Denmark, Brunswick, Berlin, Budapesth, France, and Scotland is 9.9 per cent. This agrees remarkably well with Bloch's estimate of 10 per cent. But if 77.2 per cent of the cases of hydatiform mole occur below 40, and 22.8 per cent after that year, then it is evident that hydatiform mole nevertheless is relatively more common after than before 40 years, for approximately one-fourth of the cases of hydatiform degeneration would be associated with one-tenth of the births. This would be an increased frequency of 300 per cent after 40 years. A similar result would be obtained by comparing Findlay's or Williamson's series. Hence, hydatiform degeneration, though *absolutely* less, is *relatively* more frequent in later life. This fact, however, does not necessarily imply that age in itself is responsible for the increased incidence after 40. A comparison of the incidences of hydatiform degeneration in young and old primiparæ, of good health, might elucidate this question.

These statistics are not in agreement with the prevailing opinion that hydatiform moles are more common in multiparæ than in primiparæ. Indeed, they suggest rather that after the first conception, which was normal in a large percentage of these young women, something happened which interfered with the normal development of succeeding conceptions. That, it seems to me, is extremely significant and very suggestive. Here is a group of relatively young women, over 50 per cent of whom had borne but twice and some only once, and then gave birth to a hydatiform mole. While I realize the necessity for circumspection, especially in these matters, these facts seem to me to suggest that something happened to a normal endometrium. Other facts also point in the same direction.

DESCRIPTIONS OF PLATES.

Plate 8.

Fig. 96. Young chorionic vesicle *in situ*, showing hydatiform degeneration of the stroma and syncytial budding. No. 836. ×2.6.
Fig. 97. Same, under greater enlargement, with the cyema in view. ×3.75.
Fig. 98. Hydatiform degeneration. A small portion of No. 1189 still *in loco*. ×4.5.
Fig. 99. Another portion of the same specimen. ×22.5.
Fig. 100. External appearance of an apparently normal conceptus, partly surrounded by decidua. No. 2077. ×0.75.
Fig. 101. A portion of the same specimen, clearly showing hydatiform degeneration where in focus. The decidua is reflected. ×3.
Fig. 102. Portion of villi from No. 690, showing numerous syncytial buds, absence of vessels, and glassy stroma. ×37.5.
Fig. 103. A chorionic vesicle showing shaggy appearance. No. 2258. ×1.5.
Fig. 104. Hydatiform villi from same specimen. ×4.5.
Fig. 105. Macerated normal villi in blood clot. No. 640. ×71.
Fig. 106. Well preserved, early hydatiform villi from the same specimen. ×33.25.
Fig. 107. Hydatiform villi without marked epithelial proliferation. No. 720*b*.

Plate 9.

Fig. 108. Hydatiform villi with pronounced epithelial proliferation. No. 720*b*, also shown in figure 107. ×50.
Fig. 109. Hydatiform villi without (at left) and with marked epithelial proliferation (at right). No. 540.
Fig. 110. Fairly late stage in the degeneration of the villous vessels in hydatiform villi. No. 977. ×50.
Fig. 111. A slightly later stage in the degeneration of the villous vessels. No. 516.
Fig. 112. Almost complete disappearance of the vessels. No. 874*b*. ×50.
Fig. 113. Non-vascular, early hydatiform implanted villi. No. 396. ×50.

Plate 10.

Fig. 114. Portion of No. 435*a*, showing a small villus in the center with an extremely long syncytial bud. ×50.
Fig. 115. Framework of syncytium arising from the chorionic membrane and from the villi. No. 962*a*. ×50.
Fig. 116. Apical trophoblastic nodule. No. 516. ×6.
Fig. 117. A portion of the chorionic membrane from No. 714, showing decidedly sinuous epithelium. ×50.
Fig. 118. An early, non-vascular, hydatid villus from the same specimen, showing constrictions. ×50.
Fig. 119. Epithelial vesicles within the stroma. No. 872. ×180.
Fig. 120. Extremity of an epithelial vesicle within the stroma, same specimen. ×300.

Plate 11.

Fig. 121. Slight epithelial proliferation on markedly hydatiform villi. No. 134. ×50.
Fig. 122. Extremely marked epithelial proliferation on a small hydatiform villus with glassy stroma. No. 415. ×95.
Fig. 123. The disintegrating capillaries are represented merely by large, incomplete curved outlines. No. 749. ×50.
Fig. 124. Collapsed capillaries in process of obliteration. No. 712. ×95.
Fig. 125. Fenestrated, macerated, hydatiform villi among others which are quite fibrous. No. 651*d*. ×50.
Fig. 126. Villi showing only a trace of the capillaries. No. 651*g*. ×50.

Plate 12.

Fig. 127. Section of a villus from No. 510, showing scattered Hofbauer cells. ×300.
Fig. 128. Section of a villus from No. 749, showing accumulation of Hofbauer cells, especially at the right. ×50.
Fig. 129. A somewhat macerated normal embryo from a case of early hydatiform degeneration. No. 2099. ×6.
Fig. 130. The chorionic vesicle of the same specimen, showing early hydatiform villi to left where in focus. ×4.
Fig. 131. Basal area of No. 1260, showing pronounced hydatiform degeneration of the villi. ×1.
Fig. 132. The same specimen, opened in the capsular region to show the presence of the cyema. ×1.1.
Fig. 133. Marked macerated and deformed fetus from the same case. ×4.
Fig. 134. Twin fetuses, No. 2250*a* and *b*, a case of hydatiform degeneration. ×1. (See also figs. 141 and 142, plate 14.)

96

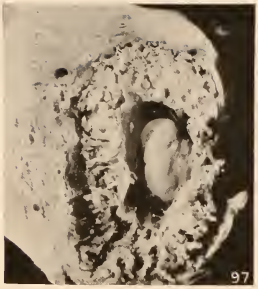
97

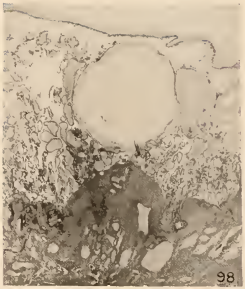
98

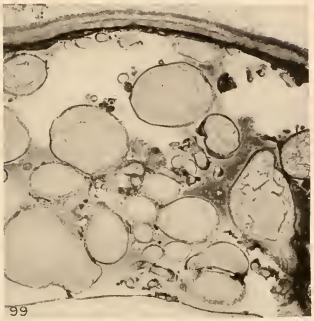
99

100

101

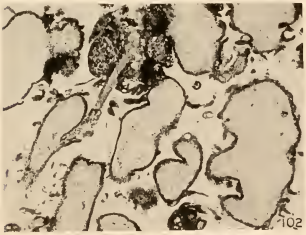
102


103

104


105

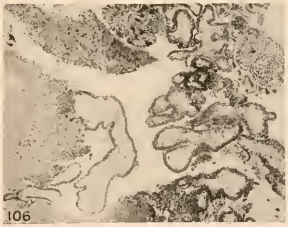
106

107

108

109

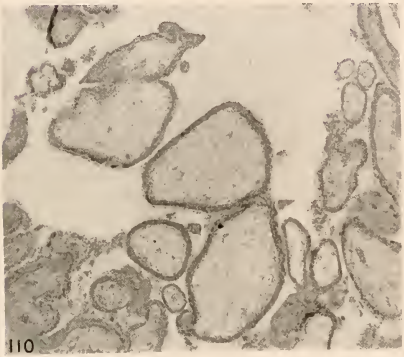
110

111

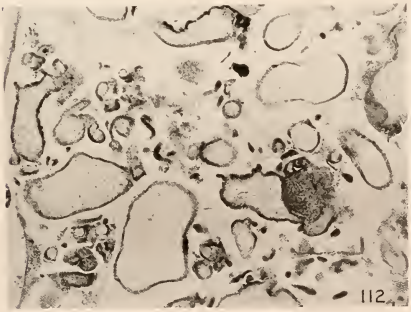
112

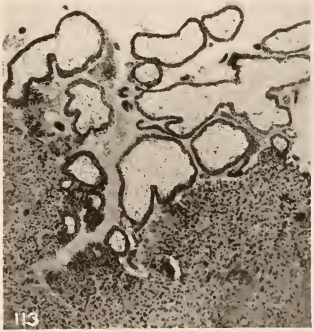
113

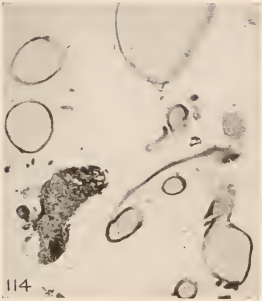
114

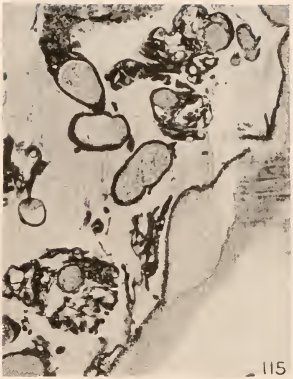
115

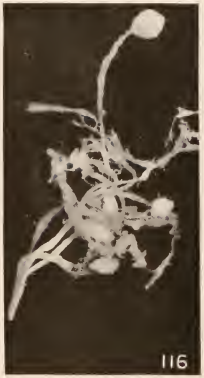
116

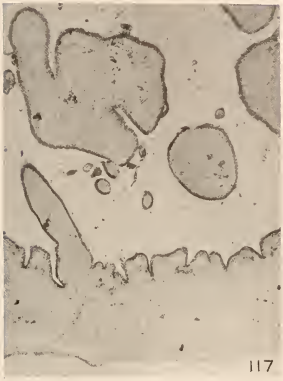
117

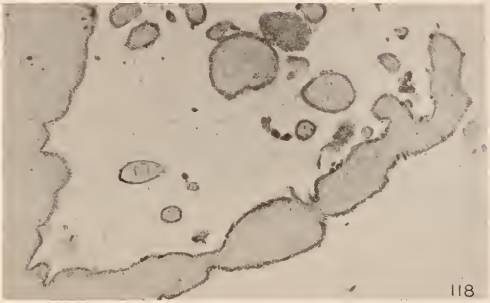
118

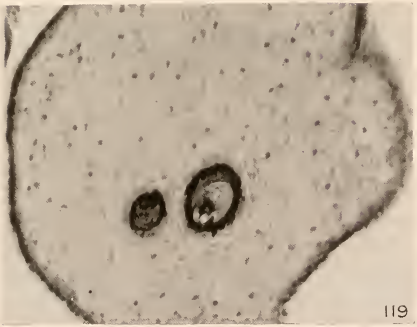
119

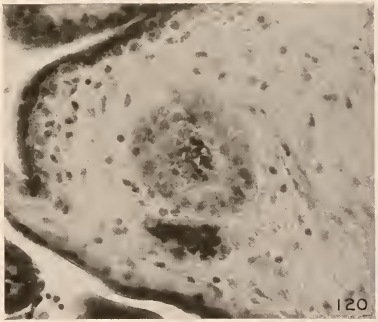
120

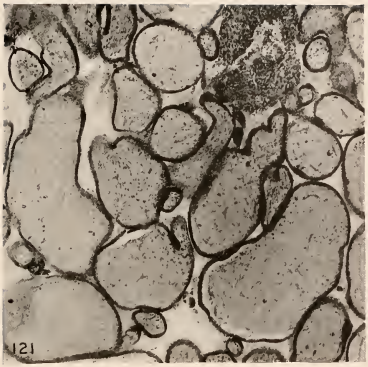
121

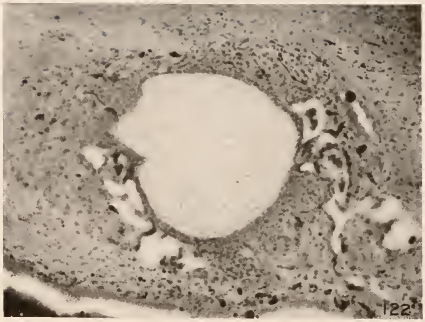
122

123

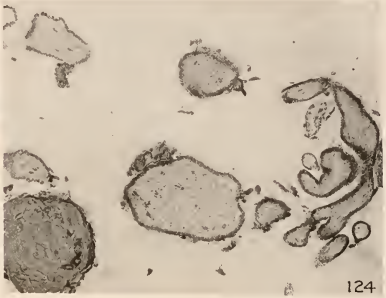
124

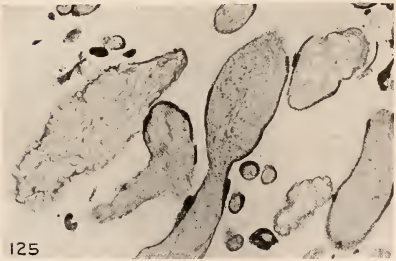
125

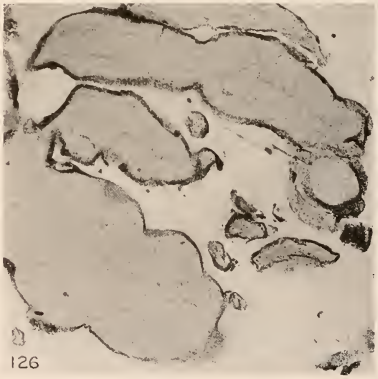
126

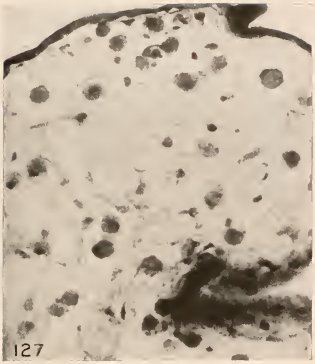
127

128

129

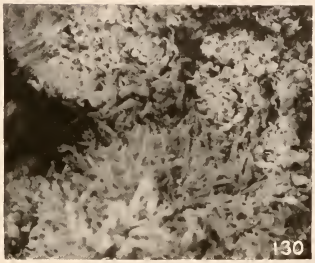
130

131

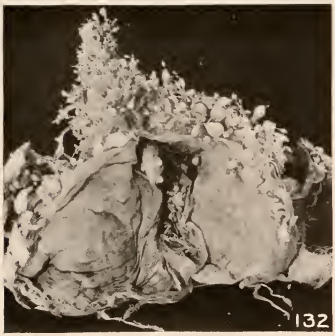
132

133

134

CHAPTER IX.

HYDATIFORM DEGENERATION IN TUBAL PREGNANCY.

Strangely enough, the occurrence of chorio-epithelioma arising from tubal pregnancy seems to be better known and also better established than the occurrence of hydatiform mole within the tube. This is especially surprising in view of the stress laid by Marchand (1895) upon epithelial proliferation in cases of hydatiform mole and in view of the fact that trophoblast formation and epithelial proliferation in general have been regarded as being greater in tubal than in uterine implantation. This is illustrated well by such cases as that of Fellner (1907), in which it was impossible to distinguish, by histologic examination, between the epithelial proliferation present in a case of tubal pregnancy and chorio-epithelioma. From these circumstances alone it seems to me that one might expect hydatiform degeneration to be relatively more common in the tubes. Moreover, when it is recalled that experts still regard it as impossible to decide upon the question of malignancy or benignity in cases of suspected uterine chorio-epithelioma from histologic preparations alone, this surmise gains more in probability. The presence of hyperactivity in the trophoblast in many cases of tubal as compared with that in uterine pregnancy was confirmed also by personal observation, and if, as stated by Teacher (1903), chorio-epithelioma arose in hydatiform moles in approximately 40 per cent of 287 cases, and according to Seitz (1904[b]) and Fraenkel (1910) even in 50 per cent, the occurrence of hydatiform degeneration in tubal pregnancy can hardly be doubted because of this fact alone.

Nevertheless, of the 7 cases of tubal hydatiform moles cited by him, Werth (1904) regarded only the case reported separately by von Recklinghausen (1889) and by W. A. Freund (1889) as well authenticated. Werth reserved judgment, however, on the case of Matwejew and Sykow (1901), a report upon which was accessible to him, and to me, in a short review only. Seitz, however, accepted the short review of this case as convincing, nor did he question the case of Otto (1871), or that of Wenzel (1893), and he incorrectly credited Wenzel with two cases. Werth, on the contrary, regarded these last two cases, and also that of Croom (1895), which was accepted also by Veit (1899), as undoubted instances of "simple hydropic degeneration of the connective tissue of the villi so common in aborted chorionic vesicles, both from the tubes and from the uterus." Werth unfortunately did not state just what he meant by "simple hydropic degeneration", but since he spoke of it as common in aborted ova, one may conclude that he referred to changes in the chorionic vesicle which followed its isolation within the uterus after complete detachment from its implantation site. For want of a better term, such changes may, I presume, be spoken of as maceration changes, although usually they occur under non-putrefactive conditions. However, I do not thereby imply that these changes are similar under sterile and under putrefactive conditions.

Since Werth spoke of simple hydropic degeneration in aborted ova, he did not, I take it, refer to a dropsical condition of the villi, possibly due to an obstruc-

tion of the venous return, for such a condition necessarily would be rare and not common. Moreover, this condition of necessity would have to arise before and not after the death of the embryo and detachment of the chorionic vesicle. As in one of the cases of Hiess (1914), such a specimen also should contain blood-vessels; for, as emphasized also by Ballantyne and Young (1913), the hydatiform villus is not merely an edematous villus.

That any one at all familiar with hydatiform degeneration, in its earlier as well as its later forms, could, upon gross and microscopic examination, confuse it with maceration changes in a fairly well preserved specimen in any but its very earliest stages does not seem possible to me. Normal villi contain capillaries, not to mention other things characteristic of them. Hydatiform villi, on the contrary, do not contain them, or only very rarely so, and only in the early stages. When a villus becomes hydatiform—that is, when liquefaction of the stroma occurs—this liquefaction appears in more or less restricted portions of the villus, thus giving rise to the long fusiform and later spherical vesicles so characteristic of hydatiform mole. But when a villus becomes macerated the change is general, and usually is noticeable also in the embryo and chorionic membrane itself, or at least within the epithelium. The latter usually is lifted from the stroma here and there, the caliber of the entire villus is increased, and the capillaries and the stroma show maceration changes as the villus becomes more translucent. This increase in caliber of the entire villus is not due to local liquefaction of the stroma, but to the pseudo-edema occurring in a villus of normal structure and form. In hydatiform moles, on the contrary, the epithelium not only is firmly attached but usually hyperactive. The changes characteristic of hydatiform degeneration may and often do appear in the villi while they are still implanted, and not only after the chorionic vesicles are detached. This does not imply, however, that the villi of a detached hydatiform mole can not also undergo maceration changes. They frequently do so, and it is in such cases as these that differentiation may be difficult or impossible, especially if it is to be made from an examination of ill-preserved fragments only. The same thing is true also of the villi in the early stages of hydatiform degeneration and maceration, especially when the latter masks the former. The difficulty would be still greater in case of whole chorionic vesicles which are almost completely dissolved, leaving only a shadow picture formed by a coagulum without nuclei, which nevertheless may retain almost perfectly the form of the chorionic vesicle and of the individual villi. It may long be impossible to differentiate such cases as these, but they form only a relatively small proportion of the whole. The many cases both of uterine and tubal chorionic vesicles which still were implanted and show exceedingly fine instances of hydatiform degeneration, as well as the many splendid examples of groups of villi which were still implanted in the tube or in the decidua, and which were equally good examples of hydatiform degeneration, leave no room for doubt as to the surprising frequency in the occurrence of this condition, even after due allowance is made for the doubtful cases.

A careful examination of the few cases from the literature which have been regarded as instances of pseudo-hydatiform degeneration leave one wholly uncon-

vinced as to the occurrence of such a phenomenon. No one will deny that many hydatiform chorionic vesicles are retained long after the death of the cyema. The material with which I dealt suggested very plainly that even isolated villi can and do survive a surprisingly long time; but Herzog (1898), from an examination of 7 tubal pregnancies, came to the conclusion that "chorionic villi degenerate with astonishing rapidity after the death of the embryo. This appears to be especially true of villi of young placentæ." Although the use of the word *placentæ* suggests that Herzog really was not speaking of very young conceptuses, he nevertheless added that only the most intimate acquaintance enables one to recognize villi after the embryo has been dead two or three weeks.

As stated in the preceding chapter, the cyema usually is absent in older, large hydatiform masses, only remnants of the chorionic membrane and villi remaining. Were these hydatiform vesicles not retained, the cyema would not be missing in any but possibly some extremely young vesicles, and if retention *per se* were the cause of hydatiform degeneration, then the latter should not only be best developed, but also most frequent among those longest retained. This, however, is not the case. Furthermore, the high incidence of hydatiform degeneration in tubal pregnancies, to which attention was called by Meyer (1919[a]), also shows that long retention is not necessary for the development of splendidly typical and universal hydatiform degeneration. Some of the finest specimens were found among tubal pregnancies in small chorionic vesicles in which cyemata still were present. If retention alone were the *sine qua non*, then hydatiform degeneration should not be so common under conditions which preclude long retention. Even Marchand (1895) found it well to emphasize that "Nicht jedes abortiv-Ei wird zur Blasenmole, nicht jede Blasenmole zeigt denselben Grad der Epithel Wucherung."

Werth further concluded that not one of the 7 cases of chorio-epithelioma regarded as having arisen from tubal pregnancies recorded before 1904 was sufficiently authenticated. Nevertheless, by 1910 Veit felt justified in saying that a considerable number of cases of chorio-epithelioma arising from tubal pregnancies had been described. He added that Risel (1895) gathered 11 cases from the literature and that a second case had been reoprted since Risel's paper. Since my interest in the subject is largely incidental, I have not taken the trouble to gather from the literature cases of chorio-epithelioma alleged to have arisen from tubal pregnancies which may have been reported since Veit wrote. Moreover, I could not presume to judge these cases critically. Hence I will accept the fact that chorio-epithelioma arising from tubal pregnancy is regarded as established by a number of investigators. If the conception regarding the relation of chorio-epithelioma to hydatiform mole is justified, then the occurrence of hydatiform degeneration in tubal pregnancy must follow on *a priori* grounds alone. Moreover, whatever the causes of hydatiform degeneration may be, one is possibly safe in assuming that the condition is not restricted to the uterus, and when I noticed that hydatiform degeneration was so very common in young uterine abortuses the surmise that it might be still more common in cases of tubal pregnancy seemed justified. Since over 100 specimens of tubal pregnancies from the Carnegie Collection were included

in the survey originally planned by Mall, a study of these specimens formed an excellent opportunity for observations on this subject.

That the case of Otto, with its pathetic history, really was one of tubal hydatiform mole, can not be doubted, in view of the careful description of the whole case—its clinical history, necropsy, and the histologic examination. This case is interesting also because the degeneration was in its early stages, the hydatids being only as large as a pinhead and the embryo still being present. Moreover, from Otto's description it is very likely that the specimen contained Hofbauer cells, discussed in a later chapter.

The history of the case observed by Wenzel in 1855 and reported in 1893 is equally complete and equally pathetic, as could be surmised by all familiar with the history of tubal pregnancy. In this case the mole was as large as a "hen egg," the hydatids varied in size from a dot to a "bird cherry" (wild? cherry), and the degeneration was universal, although the menstrual age of this specimen was given as only 51 days. It is significant that Wenzel expressed surprise that even excellent handbooks of the day had nothing to say about hydatiform mole in cases of tubal pregnancy, except perhaps to refer to the case of Otto. Nor does the case of Wenzel *seem* to be the first one observed or that of Otto the first one reported, for Storch (1878), in truly epochal, though largely ingored, observations on hydatiform mole, cited Hennig (1876) as stating that two cases of moles in the tube were reported by Blasius (very likely E. Blasius, 1802–75). Since Storch wrote on hydatiform mole, it is implied that Blasius saw one of these and not one of another type of mole, and since hydatiform mole is such a striking condition and has evoked much more interest than the other forms, an observation regarding it in the tubes well might travel down the decades, particularly since, until recently, the occurrence of hydatiform degeneration in the tubes was regarded as extremely rare. This is indicated also by the fact that Menu (1899) still referred to the case of Otto as a curiosity.

Pazzi (1908[b]) stated that two cases of extrauterine moles have been described each by Hennig (1872), Farell (1893), Donald (1902), and one case each by Otto, Freund, Theileher, Maret, Matwjew (Matwejew?) and Sycow (Sykow?), and Bland-Sutton, and one case of ovarian mole by Wenzel (1893). Wilkinson also is said to have described a case of rupture of the tube with reduction of the mole to the size of a cherry, and Lob (1902) a case of molar tubal pregnancy without cessation of menstruation. Since I am quoting Pazzi essentially verbatim, it is evident that he did not read the literature critically or discriminate between ordinary and hydatiform moles, but was misled by the old inclusive and confusing usage of the terms *mole* and *molar*, still current at the present day.

Krueger (1909) also reported a case of hydatiform mole with a cyst as large as a "walnut." The pedicle was 4 cm. long and attached to the amnion near the insertion of the cord. Krueger spoke of this as a placental cyst, but regarded it as a hydatiform-mole-like structure which, microscopically, was limited to a single villus. If this were the only evidence presented by Krueger, one might well question the nature of the cyst, but he added that microscopically the beginnings of

hydatiform formations could be recognized on other villi also. Hence it would seem that Krueger's case must be added to the authenticated cases of hydatiform degeneration in the tubes.

So far as I am able to learn, then, the literature contains reports of but 9 cases of hydatiform mole occurring in the tube, and of these 2 or 3 cases are not well authenticated. These 9 cases are formed by the 2 cases of Blasius or Hennig, that of Otto, of von Recklinghausen and Freund, and of Wenzel, the 2 of Croom, that of Matwejew and Sykow, and that of Krueger. A critical reading of Hennig's book on diseases of the tubes and tubal pregnancy makes it quite clear, however, that Hennig merely said that Blasius discovered "tubal moles" and that he observed 2 and Behm 1 case of abortion of tubal moles. From the context it is also very clear that Hennig was not discussing hydatiform moles, although it is not possible to say whether he meant that he himself or Blasius observed 2 cases. I should judge that the latter is the idea it was meant to convey. To these 7 authenticated cases I would add that of Maxwell (1910). In reading Maxwell's description one must feel that he himself regarded the case as one of hydatiform mole, but deferred to the opinion of the "committee." This is suggested also by the title of his article. The illustration which accompanies Maxwell's article is so very suggestive, and his description so characteristic of hydatiform mole, that it seems very probable indeed that the specimen really was such. Maxwell stated, for example, that "sections of the villi embedded in the wall of the tube have the typical structureless, bloated appearance of such pathological villi; and though there is no central cavitation in the villi, their structure, associated with the active proliferation of the Langhans layer, suggests that one is looking at a stage just short of vesicle formation." Moreover, as I am about to show, hydatiform mole is so very common in tubal pregnancies as to increase still further the likelihood that Maxwell's case actually was one of hydatiform mole. However, this is merely an opinion, and only a completer description or an examination of the specimen itself could decide the matter.

In connection with what was said before, it was interesting that Maxwell also emphasized that epiblastic activity is increased in all abnormal sites of implantation, but anyone interested in the problems of tubal pregnancy and acquainted with Mall's (1915) findings will be struck by Maxwell's statement that microscopical examination of many cases of tubal gestation lends no weight to the view that chronic inflammation of the tubes is at all a common causal factor of tubal pregnancy. Nor can I refrain, in this connection, from quoting the uncontradicted opinion of Doran, expressed in the discussion of Maxwell's case, that tubal gestation "probably represents some general deterioration in the generative power among civilized women."

To the 8 cases contained in the literature I wish to add 48 found among the first 1,200 accessions from the Carnegie Collection. Nor is it necessary to stop with these, for this collection contains many more not here included. It is merely a matter of recognizing the specimens by a routine examination, and since this paper has been written a number of specimens have been recognized among the daily

accessions of tubes received through the unselfish efforts and the scientific interest of practitioners in all parts of the nation.

In addition to over 100 free specimens of uterine hydatiform degeneration, I have also seen more than a dozen fine specimens in large sections of uterine implantation sites, and some entire specimens still embedded in pregnant uteri and tubes. Indeed, how many cases of hydatiform degeneration one can find in conceptuses in tubal or hysterectomy specimens will depend very much upon the care with which the examination is made, for the condition undoubtedly is extremely *common*, and not *rare*, as heretofore supposed.

Although the alleged menstrual age of these conceptuses ranged approximately from 6 to 218 days, most of them were young *empty* chorionic vesicles or mere remnants of such. Portions of quite a number were still implanted within the tube, however, and among these were two unusually fine ones in a rare specimen of twin pregnancy in a tube donated by Dr. Cecil E. Vest, of Baltimore. Since the question of superfetation has been raised also in connection with twin tubal pregnancies, I hasten to add that such a phenomenon, even if it ever occurs (which seems exceedingly doubtful), can be excluded absolutely in this case. Both chorionic vesicles were approximately of the same size and lay in practically the same cross-section of the tube, the surfaces of contact being flattened.

There were 40 tubes containing villi only, and in 14 of these hydatiform degeneration probably was present. In 10 specimens its presence was undoubted, but in 4 it was probable only. I realize that this margin of probability is exceedingly large, but this is easily understood if it is recalled that often only a few degenerate villi embedded in clot were contained in the cross-sections of the tubes, and that only a few sections were examined, not, of course, a complete series of each tube. Had the entire tubes been examined, or if more villi had been present, and if those present had been better preserved, the difficulty would have been almost wholly obviated. However, it is idle to set forth these things, because such conditions never will obtain, and the margin of probability becomes greatly reduced if it is remembered that in a large series the specimens necessarily supplement each other. Moreover, the changes in the villi often are so typical that they are unmistakable, even if only a few villi are present. Besides, examination in complete series undoubtedly would increase, not decrease, the number found. In some of the doubtful cases the existence of hydatiform degeneration became probable only upon comparison with the many uterine specimens previously examined.

The evidence offered by the 36 tubal specimens in the second group, which is composed of empty chorionic vesicles or parts thereof, was very conclusive, for the cut portions of most of these tubes contained considerable portions or even sections of whole chorionic vesicles, sometimes quite free from clot. Some of them were implanted almost perfectly in the wall of the tube, and although many of them were folded extremely and collapsed more or less, small areas of several were nevertheless implanted undisturbed within the tube. The villi in some of these implanted specimens were so characteristic and the whole picture so exquisite that the specimens rightly belong among the very finest instances of hydatiform degeneration found anywhere so far. This is true in particular of the case of twin pregnancy re-

ceived from Dr. Vest. In this specimen the two chorionic vesicles, the intervillous spaces of which were devoid of blood, lay in almost the same transverse diameter of the tube, and hence had distended the latter considerably. Both were implanted quite well over the entire area of contact, which included the whole perimeter of the tube. The chorionic vesicles were flattened at the region of mutual contact, which divided the tube somewhat unequally (fig. 13, plate 2, Chap. IV). Although the embryo and the amnion long had disintegrated completely, and although the chorionic membrane itself is thin, covered by degenerate epithelium and also disintegrating, the epithelium of the villi not only is well preserved, but is accompanied by large masses of trophoblast and considerable syncytium. Syncytial buds are found on the chorionic membrane also. The tubal mucosa is largely and the tubal wall partly destroyed by the invading trophoblast. Only a few small vestiges of the walls of the villous vessels remain, and the stroma of all the villi has undergone changes characteristic of hydatiform degeneration, as represented in figure 136. One villus also contains an epithelial cyst resulting from epithelial invagito nation with subsequent isolation of the distal extremity, a process to be referred later in connection with uterine specimens. Since most of the villi of this and similar specimens still are implanted in the tube, there can no longer be any question as to the time in which hydatiform changes in the stroma of the villi may be inaugurated. As illustrated in other instances in which isolated and small groups of villi were still implanted, the advent of degeneration of the stroma occurs, in part at least, before the villus is detached. Hence it is not merely a post-mortem or maceration change.

Another very interesting specimen of tubal implantation is No. 1771, received from Dr. H. M. N. Wynne, of the Johns Hopkins Hospital. The menstrual age of this specimen is 49 days, but its anatomic age, as based upon length according to Streeter's (1921) curve, is 37 days, thus showing a discrepancy of 12 days between the menstrual and anatomic ages. The embryonic length is only 12.5 mm., although with a menstrual age of 49 days it should be at least 18 mm. Upon examination, Streeter found the chorionic vesicle to contain a good deal of magma, some of which was still adherent to the embryo, as figure 148 (plate 14, Chap. X) shows. As has been repeatedly emphasized in the literature, the presence of this coagulum in itself probably indicates that the embryo died some time previously.

The wall of the tube is quite thin, as figure 138 shows, but the implantation is fairly well preserved around the whole perimeter of the specimen. The mucosa is destroyed throughout the greater extent of the section and the trophoblast is abundant, except in one rather degenerate and hemorrhagic area. The chorionic membrane is thin, but contains some vessels distended with blood. The stroma of many of the villi also contains vessels filled with blood, but the vessels in many others are very evidently in degeneration. The syncytium is scanty, and many of the villi are very plainly hydatiform, as seen in figures 137 and 139.

A third exceptionally fine specimen of tubal hydatiform mole is No. 2052, donated by Dr. C. L. Davis, of Washington, District of Columbia. Figure 140 shows a portion of the tube containing a hydatiform mole, some hydatiform villi

of which protrude through an incision in the wall of the tube. The whole opening is filled with typical hydatiform villi which are noticeable with the unaided eye and perfectly evident under an enlargement of 4 diameters. They present an extremely fine picture when seen with the binocular under a magnification of 10 to 20 diameters. Examination under a higher magnification shows that the preservation of the specimen is unusually good and that all the villi are markedly hydatiform. Trophoblastic proliferation is so marked that in some places it gives the appearance of decidual formation. Relatively little syncytium is present, but the trophoblast invades the muscularis in many places and a good deal of coagulum is present, most of it apparently having arisen from degeneration changes in the stroma of the mucosa and from similar changes in the trophoblast and the muscularis. The latter is moderately invaded by round cells. No remnant of the wall of the chorionic vesicle or of the amnion or embryo could be detected in the sections examined, both evidently having been absorbed completely, only some of the villi remaining behind; or, the chorionic vesicle may have been aborted and these villi left implanted within the tube.

Some exceedingly fine hydatiform villous trees were found among the specimens in this group. Scaffoldings or frameworks formed by proliferating syncytium arising from the epithelium of the chorionic membrane also were seen. Since the syncytial buds were found far out on proliferations of trophoblast which capped the villi, and also in the center of trophoblastic nodules, the origin of the syncytium from the Langhans layer again would seem to be exceptionally well confirmed. In some cases a detached hydatiform villus was fastened by opposite extremities to two portions of the tube wall. It is well to remember, however, that one of these attachments probably was gained before the separation of the particular villus from the chorionic vesicle.

Of the 36 cases remaining in this group of chorionic vesicles without amnion, after deducting 8 (7 of which belong in group 1 and 1 which belongs in group 2), 50 per cent showed the presence of undoubted hydatiform degeneration, and in 1 additional case its existence was doubtful.

Since only a few specimens are contained in each of the last five groups, I shall treat them as one. Among 28 specimens remaining in these groups, 12, or 43 per cent, showed the presence of hydatiform degeneration, and 4 others were doubtful. From this percentage it is evident that the incidence of hydatiform degeneration among tubal specimens seems to increase rather than decrease with advancing age of the conceptus, as was emphasized in connection with the uterine specimens. This probably can be attributed to the fact that the specimens in the first group are composed of villi only, and that many of the empty chorionic vesicles in group 2 were detached from the wall of the tube by hemorrhage before hydatiform degeneration had developed sufficiently to enable me to recognize it. Moreover, it must be remembered that all tubal specimens, no matter in what group they are classified, are in fact young specimens, and since those falling in the latter groups succeeded in maintaining a foothold in spite of repeated hemorrhages, a large number of them might rightly be expected to show the presence of a hydatiform change.

The incidence of hydatiform degeneration in the 108 tubal pregnancies classed as pathologic is 45, or 41.7 per cent of the whole. This is a somewhat higher incidence than was obtained in the uterine abortuses classed as pathologic, and may be accounted for partly, or even wholly, by the greater incidence of young specimens in the tubal series. That the tubal specimens undoubtedly were younger follows from common knowledge regarding tubal pregnancies alone, but it also is shown by the average menstrual age, which was 43.4 days in 25 tubal as compared with 66.6 days in 51 uterine specimens. Moreover, 32 of the 48 tubal specimens of hydatiform degeneration, or 66.6 per cent, fall into the first two groups, thus again showing that the majority are small, young specimens. However, by comparing the percentage of hydatiform degeneration in the first five groups of the pathologic tubal and uterine cases composed of conceptuses of approximately the same age, the same difference in incidence is noticeable, it being almost twice as great in the tubal as in the uterine series.

Although the incidence of hydatiform degeneration among the pathologic tubal specimens is but slightly higher than that among the pathologic uterine specimens, the incidence of hydatiform degeneration in all tubal specimens contained among both the normal and pathologic is twice as high as that among the same classes of uterine specimens. This can be explained only partly by the fact that a larger proportion of the tubal specimens are young and pathologic. The pathologic tubal specimens form 70.5 per cent of 153 normal and pathologic tubal specimens found among the first 1,200 accessions, but the pathologic uterine specimens form only 33.6 per cent of the normal and pathologic uterine groups among the same accessions. But the real question remains, for the incidence of hydatiform degeneration among the specimens classed as pathologic was essentially the same in tube and uterus. Hence an increased incidence of 200 per cent in hydatiform degeneration in the tubes may be due to the less favorable nidus found there. If so, it throws a very significant light upon the probable cause of hydatiform degeneration, which would seem to lie in the conditions surrounding the implantation and early development rather than in the ova or spermatozoa themselves.

The conclusion, reached in a study of uterine specimens, that hydatiform degeneration is *absolutely less*, not *more*, frequent near the menopause is confirmed also by the study of the tubal specimens. The average age of 20 women in the tubal series was 33.9 years, as opposed to an average of 31 years obtained from 36 women in the uterine group. This age difference offers a tempting opportunity for generalization, and did the statistics include thousands of cases one might be willing to say that it points to a progressive change as cause, which begins in the uterus and finally reaches the tubes. But strangely enough, the average number of years of married life of 15 women in the tubal series is exactly the same as that of 29 women in the uterine series, or 7.1 years. This fact at once guards against a venturesome hypothesis, for it allows a no longer period for the supposed ascending change to reach the tubes than the uterus.

Eight of 20 women from the tubal series had borne one child, 4 had borne two, and 3 more than two, thus again more than confirming the statistical findings in the uterine series, which show that 9 of 33 women had borne once and 18 but twice. The parallelism between these statistics is striking indeed, especially if the small numbers be considered; 14 of 23 women, or 60.8 per cent, in the tubal series had aborted but once, as compared to 19 out of 44, or 46.3 per cent, in the uterine series, a fact which again points to the middle rather than to the end of the reproductive life of these women.

I do not know whether or not hydatiform degeneration in the tube also is *relatively* more common near the menopause, for I have not been able to obtain data on the relative frequency of tubal pregnancy in the different decades in the reproductive life of women. However, since by far the greater number of pregnancies usually occur early in this period, it probably would be safe to assume that most of the tubal pregnancies occur also at this time. Consequently, it might well follow that the ratio of tubal hydatiform degeneration to the number of pregnancies occurring in the *later* actually might be greater than that in the *earlier* decades.

DESCRIPTION OF PLATE.

Plate 13.

Fig. 135. A portion of a rather fibrous decidua. No. 874*a*. ×300. (See Chap. VIII.)
Fig. 136. Hydatiform villi in section. No. 825. ×45.
Fig. 137. Cross-section of tube and vesicle. No. 1771. ×4.
Fig. 138. Cross-section of same, showing hydatiform villi. ×2.
Fig. 139. Hydatiform villi from same, in section. ×45.
Fig. 140. Hydatiform villi protruding through an incision in the tube wall. No. 2052. ×2.

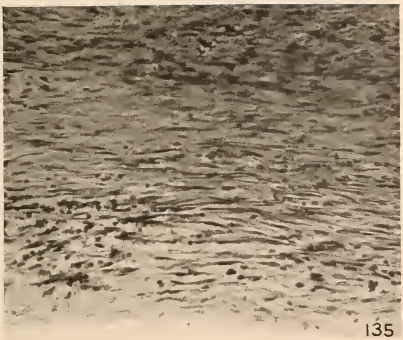
135

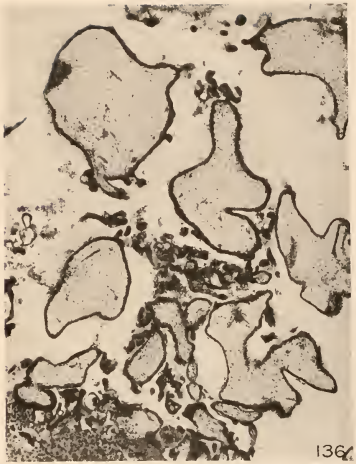
136

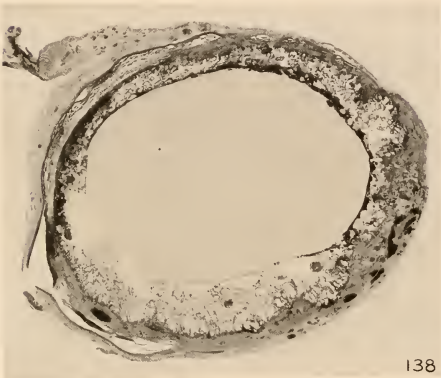
138

137

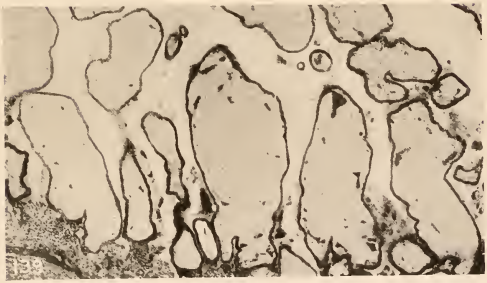
139

140

CHAPTER X.

ALLEGED OCCURRENCE OF SUPERFETATION.

From time to time reports of alleged and apparent instances of human superfetation appear in current medical literature. Reports of similar instances in other mammals occur also, although more rarely, in the nonmedical literature. As recent instances of the former may be cited the cases reported by Logan (1917) and Gustetter (1918). Of instances of the latter may be mentioned the cases of King (1913), Sumner (1916), and Harmann (1917, 1918). The latter group of cases were found in the rat, the mouse, the cat, and the cow, respectively.

Without accepting the alleged or apparent cases in mammals with bicornuate uteri as unequivocal, it is easy to see that, aside from ectopic implantations, the conditions under which superfetation necessarily would have to occur in the human uterus may be totally different from those that may obtain in bicornuate uteri. Since the usual intermenstrual period in women is 28 days, it would also seem, as often asserted, that the older of two fetuses in a case of human superfetation certainly would occlude the uterine cavity rather effectively, and alone make fertilization of any ovum, liberated at a subsequent ovulation, difficult. It would seem to do this, entirely aside from the possible effect of the cervical mucous plug so frequently referred to in the literature.

These things are true especially in such instances as that of Gustetter, in which the time interval between the ages of two fetuses is estimated to have been as great as 65 days. Moreover, it would seem that the development of the first fetus and that of the corpus luteum in such a case as this would have inhibited the occurrence of subsequent ovulations. An obstacle to the implantation might also be found in the condition of the decidua, even if later ovulation actually occurred. Since Loeb (1912) found that in the pregnant guinea-pig the endometrium can not be stimulated to form a new decidua, it is evident that the fertilized ovum might encounter insuperable difficulties if similar conditions obtain in the human being. However, if a young blastocyst really can become implanted on the bare surface of an ovary, or on the peritoneum even, then it may well be doubted whether a new decidual reaction is essential for implantation of the ovum in the human being. Furthermore, when implantation in the Graafian follicle occurs, there is no decidual reaction, at least nothing comparable to what occurs in the uterus, although the proliferating luteal cells may possibly act vicariously to some extent. However, there are other obstacles to superfetation, such as those mentioned above and the possible occlusion of the uterine tubal orifices in consequence of hyperplasia of the uterine musculature and mucosa.

Although it is being established that ovulation and menstruation apparently are not contemporaneous phenomena, succeeding ovulations nevertheless probably are periodic and separated by a considerable interval of time from each other. Such a conclusion seems to be fully warranted, although it is, of course, well known that ovulation may occur without menstruation in normal nonpreg-

nant women. This, however, does not establish the occurrence of ovulation during pregnancy. According to Fraenkel (1910[b]) and Miller (1910), ovulation normally precedes menstruation by about 9 days; but from a study of 100 cases in which the time of occurrence of the menstrual period and the approximate time of coitus were known, Siegel (1915) concluded that ovulation usually occurs between the seventh and fourteenth day post menstruum. Cosentino (1897) and also a few others have reported cases of ovulation during pregnancy in women, but we unfortunately know little as to the exact conditions which obtain, so that the entire matter remains as yet rather undecided.

Franco (1910), while reporting a case of spurious superfetation, gave a long list of Italian writers who were said to believe in the occurrence of superfetation. Unfortunately, this literature at present is largely inaccessible to me in the original, and such as is accessible remains unconvincing, as all of it apparently seemed to Cuzzi, who is reported by Franco as regarding superfetation only as a theoretical possibility. Nor does there seem to be good evidence that ovulation occurs during pregnancy in other higher mammals. The only case cited is the questionable one in a cat reported by Christopher (1886). At present it has not even been established that superfetation occurs in the rare cases of double ovarian or of combined ovarian and uterine pregnancies, although these cases would seem to furnish far more favorable conditions. Did the alleged occurrence of superfetation not involve a series of assumptions each one of which remains unproved, belief in it would seem easier. Consequently, in view of all these things, the conclusion of Gustetter that superfetation is "a frequent though often overlooked cause" of abortion in women seems rather venturesome, and anyone who critically examines Herzog's (1898) article will see that the evidence he presents really does not justify the claim that it "demonstrates fairly well that there is very little if any reasonable doubt left as to the occurrence of superfetation in the human race." Indeed, although the cases here presented would seem to offer far more conclusive evidence of the occurrence of superfetation than any presented heretofore, there is no doubt that such an interpretation of them would be a mistaken one.

The possibility of superfecundation, however, is not necessarily excluded by these considerations, for ova from the same ovulation still might be fertilized at somewhat different periods by some spermatozoa from the same or from subsequent coituses. But even while theoretically possible, it is evident that the relatively limited period of vitality of the unfertilized ovum, as contrasted with the duration of pregnancy, would make it extremely difficult, if not impossible, to recognize such cases. This would be true even if they occurred in the earlier stages of development, for normal growth differences are too great when contrasted with the greatest differences that could possibly exist under these circumstances. This would seem to be true even if we grant that the spermatozoa have a somewhat more tenacious life than ova. Mall (1918) considered evidence which seems to indicate that the life of the fertilizing power, even if not the life of the spermatozoon, is a decidedly limited one. Hence, if this be true, superfecundation is limited still further as a factor in the problem of superfetation.

In all instances in which the discrepancy in size or development between two fetuses is such as to suggest that one of them arose from an ovulation so far removed from the other as to produce unusual differences in size in the later months of prenatal development, the assumption of independent action of the ovaries, considered by King in the case of the rat, would not avoid the foregoing difficulties. Nor could the occurrence of deferred fertilization, which is advanced by Sumner as an explanation for the occurrence of supernumerary broods in mice, be used as an explanation in human cases, for the period of vitality of both the ovum and the spermatozoon would seem to be entirely too short to become responsible for marked development differences.

Sumner found supernumerary litters to occur in 3 per cent of 250 broods in young mice. Such litters were particularly frequent in young *deer* mice. The frequency of supernumerary broods would seem to vary greatly in closely allied mammals, however, for King observed only 2 cases, and these she regarded only as "seemingly" instances of superfetation, among 700 normal broods of rats. This is an incidence of 0.28, or a frequency only one-eleventh as great as that found by Sumner in mice. Sumner also stated that more than 80 per cent of the supernumerary broods survived nearly or quite nearly to maturity, and King added that all of those broods in rats were raised to maturity and that some were used for breeding purposes later.

Although both King and Sumner regarded the occurrence of superfetation with considerable reserve, neither seems to have considered the possibility of delayed parturition in one horn of the uterus as worthy of consideration in connection with supernumerary broods between which the time interval was short. Whenever this interval was relatively long as contrasted with the gestation period, such a suggestion is untenable, unless corresponding developmental differences were present. It might be helpful as well as interesting to make a careful gross and microscopic examination of the broods concerned in order to contrast the respective states of development.

Since L. Fraenkel (1910[b]) found that some rabbits copulate while pregnant, it would be of especial interest to know if supernumerary broods are particularly common in such rabbits, and whether supernumerary broods can be produced in mice should comparable conditions obtain. A particularly interesting question would seem to be raised by the occurrence of such cases as reported by Guerra (1909), in which a second implantation is said to have occurred while a dead fetus still was retained in utero. Under these circumstances the smaller, younger fetus should always be best preserved. Although ovulation, and perhaps also menstruation, could occur under such circumstances because of the occasional regeneration of the endometrium, even before abortion, one scarcely can regard such a sequence of events as established at present. However, Franco (1910) stated that there is no lack of cases in which a second pregnancy occurred under such circumstances. But that does not establish the occurrence of superfetation, for in a physiological sense death of a conceptus really terminates a pregnancy. Since at least partial regeneration of the endometrium may occur in the presence of a dead

conceptus, it is conceivable that a new implantation might occur in spite of the presence of a dead conceptus. This, however, would be a case of pseudo-superfetation only, for if the term has any real significance it can only mean the superposition of a second pregnancy upon one that is still living.

Sumner quite rightly called attention to the fact that in the great majority of cases of superfetation recorded in man, one or both fetuses were macerated before born, and King concluded that "many cases that have been reported as due to superfetation unquestionably are instances of superfecundation or of blighted ova." Nevertheless, King regarded the case in a sheep reported by Arrowsmith (1834) as probably genuine, and added that "although Christopher found that ovulation might occur during pregnancy in the cat, superfetation is not known to occur in this animal." However, Jepson, in 1883, reported such a case, and Harman (1917) another. Neither report, however, would seem to bear critical scrutiny, although both are quite as trustworthy as other reports of alleged superfetation. In the case of Harman it would seem more probable that intra-uterine death of one fetus with survival of the other was responsible for the misconception. It should be recalled that such instances are relatively common in the rat, guinea-pig, rabbit, ferret, marmot, pig, and some other mammals. These phenomena have been discussed by Strahl and Henneberg (1902), Henneberg (1903), L. Fraenkel (1903), Koebner (1910), Huber (1915), Mall (1915), and Meyer (1917[a]).

As is evident from figure 149, in which the so-called younger superfetus, reported by Harman in a cat, is contrasted with a normal cat fetus (fig. 210, plate 8, Chap. XIII) of approximately the same length, the latter has a totally different form. The same thing is evident also, although to a lesser degree, on comparing the illustration accompanying Harman's article with one from Kunz (1916), shown in figure 150. Since the latter, the larger of two macerated apparent superfetuses, in the report of Kunz, was deformed by retention, it may have measured a little more or less—probably more—than 10 mm. at the time of its death. However, even were it a trifle older than the fetus in figure 210, as its form would seem to suggest, the difference is slight and may be ignored for purposes of comparison. Kunz spoke of the larger fetus, shown in figure 150, as entirely normal, which it apparently was, for the deviations from the normal form (figure 210), which the illustration so clearly shows, undoubtedly are due to post-mortem, ante-partum changes so common in human abortuses. Kunz's conclusion that all three fetuses in his case in the cat resulted from ova which were fertilized approximately at the same time heartily commends itself. Kunz further concluded that these specimens furnish no evidence for the occurrence of superfetation, in spite of the fact that two smaller macerated distorted fetuses, which were only 9 and 10 mm. long, accompanied a nearly full-term fetus.

Harman (1918) also reported a case in the cow which, however, she regarded merely as one of "probable superfetation." Unfortunately this report rests very largely on the statement of a veterinarian, who made no further examination of the specimen. Hence it would seem that we have no unequivocal evidence regard-

ing the occurrence of superfetation, even in mammals other than man. Moreover, as far as man is concerned, the large amount of literature on the subject furnishes no cases more convincing than that of Calderini (1909). Most of them can be easily recognized, from the reports alone, as probable instances of twin pregnancy, in which one fetus died and then was retained until the birth of the other. Confusion is due largely to the fact that dead fetuses often are retained for a considerable period without showing very evident changes in form or gross structure. This seems to be due, in part at least, to retardation in the lytic processes in embryonic as compared with adult tissues, a phenomenon which has been referred to the slow post-mortem development of acidity in embryonic tissue.

Since external form is mainly relied on as a criterion by the general practitioner, it is easy to see how misinterpretation of the facts arises, and it is significant that it is only the specialist who has come to doubt that superfetation ever occurs in human kind. This assumes, however, that by superfetation is meant the partly simultaneous intrauterine development of two or more fetuses derived from ova liberated by independent ovulations separated from each other by a considerable period of time; or, in brief, the superposition of one pregnancy upon another.

Since most reports on superfetation concern fetuses in the later months of pregnancy, it occurred to me that a representation of certain instances of twin pregnancy from the earlier months of pregnancy might be of special interest, because such specimens could more easily and rightly be taken for examples of true superfetation. In the cases under consideration, one fetus evidently died some time before the abortion of both, a circumstance that resulted in considerable differences in age and form between the two. An examination of the accompanying cases will make it clear that all the instances here reported easily could be included among the alleged instances of superfetation found in the literature without doing the least violence to that literature. More than that, the instances here reported would form fine examples among such cases.

The youngest specimen contained in the Carnegie Collection which came to my attention, and which might be regarded as one of superfetation, is No. 587, donated by Dr. F. A. Conradi of Baltimore. The cavity of the larger chorionic vesicle in the fresh specimen measured 32 by 23 by 23 mm., and that of the smaller about 6 by 6 by 9 mm. The latter was empty, but the former contained a cylindrical embryo 7 mm. long which Mall found greatly dissociated with a practically solid brain and only a remnant of the intestine. The amnion was present, and as shown in figure 31 (plate 4, Chap. IV), both vesicles formed a single mass which was covered by infiltrated decidua. That these chorionic vesicles both once contained an embryo, no embryologist will doubt. It is evident also that both were retained for some time after life and growth had ceased. The gross and histologic appearance of the entire specimen alone is sufficient proof of this. Although the smaller chorionic vesicle was incorporated in the margin of the larger, its death did not lead to its abortion or to that of the surviving twin. Yet the smaller of these twins undoubtedly died a considerable period before the larger. This is indicated also by an examination of the specimens and by the presence of decidua between

the villi belonging to the respective vesicles at a point where they come in closest contact. An examination of this area shows that the ovum giving rise to the smaller conceptus was embedded independently, although undoubtedly also contemporaneously with the larger. Hence this specimen can not be rightly regarded as one of superfetation.

The next specimens of twin pregnancy which might be regarded as a case of superfetation are Nos. 788 *a* and *b*, donated to the Carnegie Collection by Dr. Anfin Egdahl. These twin chorionic vesicles, which were almost of the same size, measured 60 by 45 by 40 and 60 by 55 by 40 mm., respectively. Although of approximately the same size, the former contained a stunted embryo 17 mm. long, the latter a nodular one only 3 mm. long. The differences in size and in the character of the two embryos are so marked that they prompted Mall to make special inquiry of the donor as to whether these chorionic vesicles were really obtained from the same patient, as reported. This inquiry Dr. Egdahl was able to answer promptly and positively in the affirmative. Here we are again dealing with a case of twin pregnancy, in spite of the fact that the size of the embryos might seem to indicate that we really have a case of superfetation under consideration. But that the case is not such is shown also by the fact that the chorionic vesicles practically are of the same size. The smaller abortus with a partially inverted chorionic vesicle containing the better preserved of the twins is shown in figure 21 (plate 3, Chap. IV). Figure 19 (plate 2, Chap. IV) shows the appearance of the larger abortus, which contained the smaller nodular embryo only 3 mm. long. The latter is seen at a midpoint near the upper third of the illustration. Both illustrations are practically of natural size. The larger fetus, the external form of which was fairly preserved, had an approximate age of about 48 days, as estimated by the Streeter (1921) curve. Mall noted that the organs could all be outlined, but that they were dissociated, and that the mandibular region had fused with the skin of the thorax. The small nodule, which represents the only remnant of the embryo belonging to the larger chorionic vesicle, contains a large cavity, with thick, fibrous walls, but nothing save epidermis and a remnant of the nervous system could be recognized.

A far more convincing instance of apparent superfetation was found in a specimen of twins donated by Dr. Jane Ross of Binghamton, New York. The fetuses, Nos. 1840 *a* and *b*, contained in this abortus are shown in figures 151 and 152. The larger measured 31 mm., but the smaller only 15 mm., indicating respective ages of 63 and 45 days. The chorionic vesicles belonging to these twins, which formed a single mass, are shown in figures 153 and 154. The incised vesicle containing the smaller fetus is shown in figure 154, and the larger vesicle, which is somewhat inverted, in figure 153. Since the latter had been opened and the larger fetus exposed, I at first overlooked the smaller fetus and found it only at a subsequent examination made for the purpose of determining the cause for the peculiar consistency and appearance of this portion of the abortus. The condition of the smaller fetus, which is well revealed in figure 152 under a magnification of

4 diameters, is abundant evidence of the fact that it died a considerable period of time before the abortion occurred. This interval must have been several weeks. This specimen also nicely illustrates the fact that the death of one fetus does not necessarily result in the immediate abortion of it and its vesicle or of the other chorionic vesicle, as is sometimes still assumed.

Through the generosity of Dr. Gustetter, I am also enabled to present reproductions of the fetuses spoken of in his article. They are shown in figures 155 and 156 and from these illustrations it is clear that the smaller of the 2 fetuses probably stopped growth at about the sixth week. After this it became macerated and finally disintegrated, while the larger continued to grow, as in case of the specimen from Dr. Ross. The larger of these fetuses is practically normal in appearance except for the post-partum shriveling. It is approximately 100 days old.

Other specimens in the Carnegie Collection, such as No. 2036 *a* and *b*, well might be included here, for one fetus was grouped as normal and the other as macerated. Indeed, it is a not very rare occurrence to find that the fetuses in a twin pregnancy had to be placed in different groups by Mall and his associates at the Carnegie Laboratory. However, this was not done because such specimens were regarded as instances of superfetation, but because the fetuses, although of the same age, differed in form and appearance. It is interesting that Saniter (1903) also reported a case of two unequally developed tubal conceptuses, one of which was implanted in the isthmus and the other near the fimbria. The former was said to be only of the third to the fourth week, while the latter contained a fetus 4 cm. long. Both chorionic vesicles were said to have ruptured freshly. In commenting on this case of Saniter's, Werth (1904) said that he regarded the question as to whether it was a case of superfetation or merely one of twin pregnancy an open one.

It may be recalled that the occurrence of fetus papyraceus in cases of twin pregnancy also has been attributed in the past to superfetation. Moreover, as stated above, intrauterine death of one or more fetuses belonging to the same litter is relatively common in some mammals. However, since Jenkinson (1913) stated that the allantois and its blood-vessels and also the syncytium are regularly retained at birth in some marsupials, to be absorbed later through the activity of maternal leucocytes, it is evident that one must use caution in judging on the basis of experience in other mammals, especially the lower ones. In some of these the conditions are apparently quite different from those encountered in man. Strahl and Henneberg (1902) also pointed out that in the mole the entire placenta and membranes, as Hubrecht stated, are often retained for a month after parturition. No one would assert that the human uterus shows the same tolerance or the same resorptive power, yet the daily experience of physicians, as well as the literature in obstetrics and gynecology, is replete with instances of retention of the membranes or the entire conceptus long after the death of the fetus. Although the presence of a surviving conceptus in multiple pregnancy materially alters the intrauterine conditions, it also would seem to predispose to retention

rather than to hasten the expulsion of the dead mate. That is, the survival of one twin, especially in the earlier stages of development, may depress rather than enhance the factors that lead to abortion.

The impulses arising from the presence of the dead fetus may be counterbalanced or offset, for a time at least, by the presence of the living fetus, and thus tend to prolong the *status quo*. This would be the case particularly whenever, as in the specimen donated by Dr. Ross, the two chorionic vesicles are fused into a single mass; for then the portion belonging to the dead fetus, even if it forms one-half of the combined mass at first, soon is outstripped in size by the surviving vesicle, which, in the absence of infection, may continue to grow quite undisturbed, for some time at least; and even in the case of infection of the dead vesicle, prompt invasion of the living does not necessarily occur. Aside from clinical experience, this was indicated also by the experiments of Maffuci (1894) on incubating eggs and on pregnant rabbits and guinea-pigs. The apparent resistance of the young fetus to syphilis, the characteristic lesions of which have not as yet been successfully demonstrated in fetuses much before the second half of pregnancy, would also seem to point in the same direction.

From these considerations it would seem to follow that especially favorable conditions for the production of gross differences would exist in some cases of twin pregnancy. Hence it need not surprise us that these differences have been largely responsible for the quite general belief in the occurrence of superfetation in women. But at present it remains merely a possibility, for the evidence on which this belief rests is wholly inadequate. It is interesting to recall that, in the past, fetus papyracei have also been regarded as examples of superfetation, as illustrated by the specimens reported by Fasola (1887).

DESCRIPTION OF PLATE.

Plate 14.

Figs. 141–142. Hydatiform villi from No. 2250*a* and *b*, shown in fig. 134, plate 12, Chapter VIII. ×4.
Figs. 143–144. Twin conceptuses, both with hydatiform chorions. No. 2411*a* and *b*. (See Chap. VIII.) ×1.35.
Fig. 145. Enlarged fetus from same, showing maceration effects. ×2.
Figs. 146–147. Macerated hydatiform villi from the same case. ×6.
Fig. 148. Cyema covered with magma. No. 1771. (See Chapter IX.) ×2.67.
Fig. 149. Apparent superfetus from a cat. (After Harman.)
Fig. 150. Macerated, distorted normal cat fetus 10 mm. long. (After Kunz.)
Fig. 151. Slightly macerated twin fetus. No. 1840*a*. ×11.35.
Fig. 152. Pseudosuperfetus. No. 1840*b*. ×2.67.
Fig. 153. Opened, everted vesicle of No. 1840*a* and incised vesicle of 1840*b*. ×0.66.
Fig. 154. Opened chorionic vesicle of 1840*b* and placental area of 1840*a*. ×0.66.
Fig. 155. Twin fetus. No. 2036*b*. ×0.66.
Fig. 156. Pseudosuperfetus, No. 2036*a*, disarticulated by maceration. ×2.

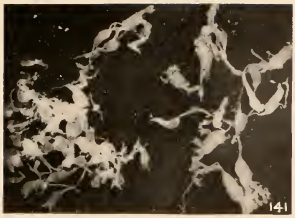
141

142

143

144

145

146

147

148

149

150

151

153

155

152

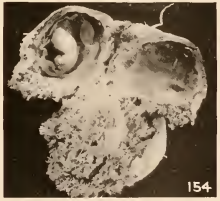
154

156

CHAPTER XI.

OVARIAN PREGNANCY.

Although the Carnegie Collection contains almost 3,000 specimens of abortuses and others from operations upon the tubes and uteri, it includes only 2 cases of ovarian pregnancy. The first of these (No. 550) was described by Mall and Cullen (1913) and the second (No. 1522) by Meyer and Wynne (1919). This is an incidence of only 1 in 1,500 miscellaneous accessions composed mainly of abortuses, but it is not at all unlikely that the near future will experience an increased frequency, if not among the accessions to the Carnegie Collection, at least in the cases reported. For, although the first case of ovarian pregnancy under that heading in the *Index Medicus* is that of Kouwer (1897 [van Tussenbroek, 1899]), careful scrutiny of the titles listed for the last decade reveals the fact that 5 cases of ovarian pregnancy were reported in 1908, 4 each in 1909 and 1910, 7 in 1911, 13 in 1912, 9 in 1913, 7 in 1914, 3 in 1915, 1 in 1916, and 5 in 1917. This makes a total of 58 apparent cases reported within this decade. Since the reports on some of the cases were published in three different journals, these were, of course, counted merely as one, and although the authenticity of 4 of the cases must be questioned on the basis of the titles alone, the series, nevertheless, is a large one in spite of these facts and of a marked decline in the number reported during the war. Since Norris (1909) stated that only 19 certain cases, approximately only one-third as many as all cases listed in the last decade, were reported in the decade between 1899 and 1909, it would seem that ovarian pregnancy is not only receiving increasing attention, but that a change in attitude as to what constitutes ovarian pregnancy is probably in progress. This conclusion would seem to be justified, even though a careful examination of the descriptions of the cases reported in the decade between 1908 and 1917 would reduce somewhat the number listed.

Lockyer (1917) accepted as authentic only 22 cases of those reported between 1910 and 1917, but his review is only a partial one. Even so, it shows that there is a decided increase in the number of cases which have been regarded as genuine from decade to decade. The marked increase in the number of genuine cases reported in recent decades becomes still more evident if one recalls that Williams (1910) found only 13 positive cases up to 1906, whereas Norris found 19 positive cases in the single decade between 1899 and 1909. That is, Norris found more positive cases reported in that decade than had been reported in all previous medical history up to 1906. This surely is striking.

The opinion that many, even if not all, cases of so-called hematocele, hematoma, apoplexy, blood-cysts, and rupture of the ovaries are probably nothing but cases of ovarian pregnancy in disguise has been held by various investigators for some time. Hence, if hematocele of the ovaries repeats the history of hematosalpinx, it is not unlikely that the near future will see a marked increase in the reported frequency of "a fact so curious and important in itself," as Granville aptly put it

a century ago. This would seem to be true in spite of the fact reported by Norris and Mitchell (1908) that only a single case of ovarian pregnancy was found among 44 extrauterine specimens and 58 hemorrhagic cysts contained in the collection of 1,700 gynecological specimens at the hospital of the University of Pennsylvania. At any rate, a careful microscopic examination of all such cases would seem to be indicated in the future in order to determine, if possible, which cases are and which are not conceptual in origin.

Werth (1887) is said to have collected 12 cases, among which he regarded only that of Leopold (1882) as authentic. Leopold (1899) reported 14. Gilford (1901), in a splendid, succinct review of the literature, gave 28 cases, 16 of which he regarded as undoubted and 12 as probable. Roche (1902) accepted only 12 cases, Füth (1902) accepted 21. Kantorowicz (1904), using the criteria of Leopold (1899), together with a microscopic examination, as a basis, grouped the cases recorded in the literature as certain, probable, and uncertain. He considered 17 as certain, 10 as probable, and 13 as uncertain. And to the 17 cases regarded as certain by him, Kantorowicz then added 2 of his own, basing his decision, however, mainly upon the presence of decidua in the ovaries, thus making 19 cases regarded as authentic by him. Freund and Thomé (1906) regarded 23 of all the cases reported up to that time as certain. Norris and Mitchell (1908) considered 16 as positive, 15 as probable, and 9 as fairly probable. Warbanoff (1909) collected 34 cases and Norris (1909) regarded 19 of those contained in the literature of the previous decade as positive; but Williams (1910), from a critical review of the literature up to 1906, and upon the basis of the criteria of Spiegelberg, regarded only 13 as positive, 17 as highly probable, and 5 as probable. Mapes (1914) collected 30 cases, but wholly from secondary sources, and Lockyer (1917) 42, from the years 1910 to 1917. Of these cases Lockyer accepted 22 as authentic and 20 as questionable and undecided from the evidence available to him.

This short summary suffices to show that there is as yet no consensus of opinion as to what constitutes an ovarian pregnancy. Although this fact finds its explanation partly in our lack of sufficient knowledge, it is due also to the meagerness of some of the reports. However, if complete disintegration and lysis of intraovarian conceptuses can occur, then it must always remain a question of opinion in the future whether some of the cases so reported really were or were not true ovarian pregnancies. This must remain true, no matter how thorough the microscopic examination, unless the clinical history or changes in the maternal organism can afford us crucial tests in such cases.

Anyone who reads far into the literature of ovarian pregnancy must also become aware of the fact that even very recently skepticism has been carried too far. Jacobson (1908), for example, placed the case of Kouwer-van Tussenbroek (a case which finally convinced Bland-Sutton) and that of Webster (1904) in the doubtful class! Furthermore, he also insisted upon the presence of an embryo or fetus as absolutely essential.

It must be emphasized, however, that even a liberal attitude on the part of a reviewer would not justify him in accepting all cases reported as genuine upon

the basis of the reports themselves, for they—especially the older ones—are often too meager to enable one to form a reliable opinion. This is illustrated also by such recent reports as those of Garrard (1916), Martin (1917), Sweeney (1917), and Mills (1917). Although it must be remembered that from the very nature of things it is sometimes impossible to make a report which in itself carries conviction, it is regrettable that in a number of relatively recent cases, in which such a report apparently could have been made, this was not done. Mills's case seems to have been an instance of ovarian implantation in a region other than the Graafian follicle, and hence recalls the first case of Granville and the cases of Franz (1902), Norris (1909), Paucot and Debeyre (1913), and perhaps also that of Kouwer (1897 [van Tussenbroek, 1899]).

Today it is no longer true, as stated by Freund and Thomé (1906) and by Sencert and Aron as late as 1914, that authentic cases of ovarian pregnancy belong to the great rarities. Yet the fact that many of our States, as well as many large clinics, have not a single case on their records seems to suggest that the condition is still seldom recognized, a century after Granville observed his first case. Moreover, a number of continental gynecologists and obstetricians, for a quarter of a century, have regarded the occurrence of ovarian pregnancy as undoubted. Anderson (1917) stated that German writers began to report cases of ovarian pregnancy with some frequency after 1901, and Gilford (1901) also called attention to the fact that continental opinion had long accepted ovarian implantation not only as possible, but as proved. Gilford further referred to the often-quoted opinion of Tait that ovarian pregnancy is as rare as "a blue lion or a swan with two necks," and in his article in 1899 also called attention to the opinion of Bland-Sutton that ovarian pregnancy not only has no existence, but that it is impossible. These opinions are particularly interesting in view of the careful reports made by Granville (1820 and 1834) in connection with the two cases which he then and which others since have regarded as cases of undoubted ovarian pregnancy, in spite of the absence of microscopic examination. In view of this lack, it is particularly fortunate that both of these reports of Granville are accompanied by splendid illustrations by Bauer, which also won him praise and admiration and which greatly strengthened his cases. It may be recalled in this connection that Werth (1901) accepted Granville's case recorded in 1820, but said nothing about his second more convincing instance reported in 1834.

Although there is as yet no agreement as to what constitutes an authentic case, a review of the literature justifies the growing and apparently well-founded belief that in the past too much emphasis has been laid on certain criteria which later experience has shown to be partly inapplicable. It is becoming clear that some cases, formerly excluded for reasons regarded as sufficient, with our present knowledge could no longer be rejected. Moreover, it does not seem at all improbable that some cases listed as *tubal* really were *ovarian* in origin. Nor must it be forgotten that not even the entire absence of remnants of the conceptus can positively exclude a case from the category of true ovarian pregnancy. In a number of cases in the literature, and also in our own cases, the clinical history

and gross anatomic findings suggest the conclusion drawn by Scott (1901), on *a priori* grounds alone, that the conceptus may be completely resorbed. It may, of course, also be aborted or disintegrate completely. That such an assumption is justified is indicated by the lysis of the embryo or fetus in a large number of cases of ovarian pregnancy, and also by the very degenerated condition of some of the vesicles and of the surrounding ovarian stroma. The possibility of such an occurrence in the ovary is established also by similar events in uterine and tubal pregnancies discussed elsewhere (Meyer, 1919[c]). It probably is illustrated also by such cases as those of Anning and Littlewood (1901), in which no mention is made of an embryonic disk in a translucent conceptus the size of a "pea." Then, to be sure, there are the cases of unruptured ovarian pregnancies containing villi only, as well as the rare case, probably of double ovarian pregnancy, of Holland (1911). Although one can not be certain that embryonic tissue was removed from the left ovary with the blood-clot which was forcibly expelled at the time of operation in this case, it is not at all improbable that the small plasmodial masses found in the left ovary were the only remnants of the conceptus. We realize fully that the conclusion that young conceptuses may be wholly dissolved is fraught with great uncertainty, but it nevertheless appears to be justified by the facts, and that it therefore is in the direction of truth. It could only fail to be so if every ovum that becomes implanted within the ovaries were aborted or were removed by operation before lysis was possible.

One can not rightly refuse to recognize the possibility of the spontaneous disappearance of an ovarian pregnancy. Since implantation in the ovary occurs under such abnormal conditions, it would seem that for this reason alone the great majority of such implantations inevitably must succumb. This would seem probable, wholly aside from considerations regarding the development of the corpus luteum, although lack of, or interference with, the development of the latter also would seem to condition early death of the conceptus if the results of the long series of experiments on rabbits by L. Fraenkel (1903, 1910[b]) are indicative of the rôle played by the corpus luteum in early implantations in man also. It surely is difficult, if not impossible, to see how implantation within the Graafian follicle, and especially the later development of the conceptus, can fail to interfere with the development of a normal corpus luteum. Cases in the literature, and also our case No. 1522, did not reveal the presence of any well-preserved or even true luteal cells at the time the pregnancy was terminated. Although this fact does not presuppose an entire lack of development of these cells in the earliest stages of the implantation, it undoubtedly does imply a defective development, which in itself may have become responsible for the death of the conceptus. Nor should the possible toxic effect of luteal cells upon the conceptus be forgotten in this connection.

It is not assumed that the clinical symptoms and signs alone should suffice finally to group a specimen as truly ovarian, but when these are indicative of the presence of an ectopic gestation, and when undoubted intrauterine decidual changes are present, in the absence of abdominal pregnancy or tubal involvement

and a normal corpus luteum, and the presence of a blood-clot within the ovary, there would seem to be little reason for doubting the authenticity of the ovarian implantation, even in the absence of embryonic remnants. Since changes suggesting decidual reaction in the ovary have been reported so seldom, it is doubtful whether much emphasis can be laid on them. One seems justified in saying this in spite of the fact that the presence of decidua in the ovary formed the only anatomic evidence upon which Kantorowicz (1904) confidently classed his two rather advanced cases of ectopic, among authentic ovarian pregnancies. Moreover, if it be true, as stated by Webster (1904), that changes which can not be distinguished from true decidual changes not infrequently occur in the ovary in connection with normal uterine pregnancies, then the presence of islands of pseudo-decidual cells in an ovary surely can not be regarded as indicative of ovarian pregnancy. Perhaps, however, with modern histochemical methods, it would be possible to distinguish genuine decidual cells. In making this observation, we are fully aware that various criteria have been advanced from time to time by means of which to judge ovarian pregnancies, and that many of these have met with objection and have hence been modified. Such modifications would seem to be inevitable as long as there is progress in the solution of an unsettled question.

The absence of the fetus in many of the recorded cases in itself demonstrates the entire inapplicability of the criterion added by Jacobson (1908). Moreover, the histologic appearance of the ovarian tissue around certain portions of the blood-clot in the present, and also in some of the cases in the literature, would seem to suggest that it may be very difficult to find remnants of ovarian tissue at several points in a case of pregnancy which has advanced far. Hence this criterion of Spiegelberg (1878) can not be regarded as necessarily crucial. Whenever the implantation is developed at the outer instead of at the inner margin of a follicle, as in the case of Banks (1912), early destruction, even if not early rupture, of the overlying ovarian stroma and capsule would seem to be inevitable. Indeed, whenever the layer of ovarian stroma overlying the placenta is thin, very early death of the fetus would seem to be inevitable from defective nutrition alone. On the other hand, when placental development occurs in the region of the follicle directed toward the body of the ovary, great destruction of the ovarian stroma would seem to be unavoidable, even if something akin to normal decidual formation actually took place. In the case of Engelking (1913), for example, not a trace of an ovary was found in an ovarian pregnancy which had become interstitial. Even without assuming the complete authenticity of this rather equivocal case, it would seem highly probable that the presence of ovarian tissue later in the pregnancy probably is determined very largely by the location of the fertilized follicle within or by the exact location of the implantation upon the ovary.

From evidence contained in the literature, it is clear that further reports of single cases are not needed for the purpose of emphasizing the occurrence of ovarian pregnancy, yet such reports nevertheless may help in the determination of the relative frequency of this novel and sinister condition, and also throw further light upon its genesis and the finer relations of the implantations, as well as upon

other matters. Moreover, the cases which are accompanied by a careful histologic examination, and which for this reason alone are wholly unequivocal from an anatomic standpoint, are still relatively few.

Specimen No. 550 of the Carnegie Collection is of interest to both the surgeon and the embryologist. It is also of great scientific value, for it shows conclusively that the ovum had lodged itself in the Graafian follicle, undoubtedly in the one from which it came, indicating that the sperm must have entered the follicle after it had ruptured. The fertilized ovum then found lodgment in the follicle, around which the corpus luteum developed. As in other cases which have been reported, no decidua was formed, showing that the decidua is not of embryonic origin.

This case illustrates well the advantage of cooperation in research. Under a special organization, with a properly equipped laboratory attached to a surgical clinic, specimens of great scientific value may be recognized and properly reported; and it is not necessary to have an entire medical faculty attached to each clinical laboratory in order to make progress in medico-biological science.

The specimen was sent to the Gynecological-Pathological Laboratory to be examined and the following record was made:

"The specimen consists of a tube and ovary from the right side. The tube at its outer extremity has been considerably mutilated. The portion received measures 6 cm. in length and is somewhat tortuous. It shows a few adhesions on the surface. Section through the middle portion of the tube shows the mucosa to be somewhat thickened and blood-tinged. Section through the distal portion gives a similar picture. There is no gross evidence of an extrauterine pregnancy. There is a portion of the fimbria present, but the portion of the tube between this and the middle is missing. There is nothing to suggest placental tissue. The mucosa appears normal in the sections.

"The ovary measures 5 by 4 by 3.5 cm. The surface shows a few old adhesions. On section the ovary shows a cyst 3 cm. in diameter. Clinging to the wall and bulging into the cavity is a blood-clot 2 cm. in width and 8 mm. in thickness. This on section appears to be corpus luteum. It is intimately connected with the walls of the cystic space. Further sections show villi in the clot attached to the inner surface of the space in the ovary."

The appearance of the specimen, with a section through the ovary, is shown well in figures 157 and 158. When received there came with it several sections from the Gynecological-Pathological Laboratory and these two drawings by Professor Brödel. These sections included the chorion, ovary, and uterine tube. The sections of the uterine tube appear normal, with a very extensive infolding of mucous membrane and occasional lymph-nodules in its walls. Doubtless the sections are from the distal or fimbriated end of the tube. The sections from the chorion are apparently at right angles to its main wall, as shown in the figure.

The villi, which are irregular in arrangement, show attachment to the main wall of the chorion, while at their distal ends they invariably abut against the blood-clot (figure 162). In no instance is there any sign of the decidua, nor do the sections through the villi contain any of the adjacent ovarian tissue. The blood-clot is well organized, with strands of fibrin extending in all directions and without

distinct red blood-corpuscles. Most of the villi have a fibrous mesenchyme; in some it is mucoid. Scattered through the mesenchyme of the chorion there are blood-islands, or rather groups of blood-cells, within the blood-vessels from the embryo. These are especially numerous where the villi are attached to the main wall of the chorion, showing that in its development the embryo must have been present at an earlier stage. The distal ends of the villi are apparently covered with a double layer of epithelial cells, which is as should be in normal development. However, a rich peripheral trophoblast is missing. In the trophoblast are numerous small masses of disintegrating cells. These appear to be pretty well intermingled with mesenchyme cells at the tips of the villi, as shown in the figure. Many polymorphonuclear leucocytes are present where the trophoblast comes in contact with the blood-clot. Among the leucocytes there are isolated cells of the trophoblast. At points the isolated cells are also embedded in the mesenchyme of the villi. Altogether, these processes are quite identical with those found in the villi of the uterine moles, where there is also every indication of degeneration of the villi and their trophoblast, due to either faulty implantation or to infection. In none of the sections is there any indication of the embryonic mass, nor do the sections which were sent show the character of the ovarian tissue adjacent to the clot containing the villi, although in a number of sections the chorionic wall is shown to be composed of two layers, which doubtless represent both the chorion and the amnion (figure 162, *Am* and *Ch*). In one section these two layers are blended for a short distance, and at this point there are numerous embryonic blood-vessels. The fact that the amnion, which is quite characteristic, is in close apposition with the chorion, and the presence of numerous blood-islands show quite conclusively that they are identical with an ovum which is sufficiently well advanced in development to contain an embryo about 15 mm. long.

When the specimen came to us it was composed of two pieces which were formed by cutting directly into it on the side of the rupture, as shown in figures 157 and 158. These are drawn natural size, and therefore give the dimensions of the ovary. A loose piece of clot was taken out and cut into serial sections, but upon close examination with a microscope no trace of the chorion could be found in any of them, so it appears as though we received only the clot and a small remnant of the chorion attached to it, which had possibly invaded the ovarian tissue and lodged itself freely within it. The ovary was then cut into slabs about 5 mm. thick, and at a distance from the cavity containing the villi a large corpus luteum, 10 mm. in diameter and entirely filled with blood, came into view (figure 159). New sections of the wall of the cavity were then made. These show that the cavity as a whole is lined with a smooth, grayish membrane barely 0.5 mm. in thickness. In the tissue between the corpus luteum and the main wall of the cavity there is an extravasation of blood which enters a few of the adjacent Graafian follicles. The arrangement of these follicles is well shown in figure 158, but the corpus luteum, which is filled with blood, is much nearer the proximate pole of the ovary, and is therefore not shown in this section. It is close to the point marked *Adh* (figure 157). Sections were then cut through the whole ovary, and

give the entire wall of the cavity containing the ovum. The sections, showing most of the structures, are at right angles to the ovary (directly through the letter *O* in the word *ovary*, figure 157). They were stained in a great variety of ways: hematoxylin, acid fuchsin, iron hematoxylin, orange G, and a number of connective-tissue stains. In general, they show that the ovary is active and not fibrous, apparently normal, containing numerous blood-vessels and a ring of large Graafian vesicles (figures 158 and 159), with an outside zone of small vesicles containing small ova. To all appearances this is as it should be in a young ovary.

The wall of the cavity, containing the blood-clot and villi, is lined almost throughout with a layer of lutein cells (figure 161). This layer is quite uniform, ranging from 0.5 to 1 mm. in thickness. Between the lutein cells are numerous strands of blood-vessels, but on their inner side is a layer of fibrin before the blood-clot begins. On the outside the lutein cells form small islands of more compact cells which stain more intensely in hematoxylin (figure 161, *Cl'*). The section reminds one very much of a section of the adrenal. We have here a layer of lutein cells well spread out, possibly due to the distention of its cavity by the ovum and representing the corpus luteum, which, according to our conventions, is about as old as this ovum appears to be. In other words, it is clear that the ovum developed within the cavity of the Graafian vesicle to which it belongs. The corpus luteum, filled with blood, near the proximate pole of the ovary (figure 160), which at first appears to represent the one from which the ovum came, is considerably more advanced in development than the one containing the ovum; therefore it belongs, in all probability, to a previous ovulation. Had it not been for the additional sets of sections we made, it would have been necessary to interpret this specimen as Teacher, Bryce, and Kerr (1908) did theirs. The hemorrhage in the ovary between the older corpus luteum and the cavity containing the ovum could easily be viewed to indicate that the ovum invaded the ovarian tissue, as shown by the illustrations of the authors mentioned.

The older corpus luteum demonstrates once more very clearly that it is imperative to standardize anew the development of the corpus luteum. It is encircled by a very marked corpus fibrosum, which is wavy and forms a uniform sheet about 0.5 mm. in thickness beyond the clot (figures 159 and 160). There are few lutein cells within it. On the inner side of the corpus fibrosum there is a thick layer of degenerated blood, and in the center a large mass of well-defined red blood-corpuscles. Within the very center of the clot is a cleft which is curiously lined and filled with red corpuscles, staining somewhat differently from those of the rest of the clot. Also, at the periphery of this clot there is a curious vesicle lying immediately under the outer fibrous layer, which may indicate a more recent hemorrhage. At any rate, the lutein cells encircling the cavity containing the clot and ovum prove quite conclusively that the ovum did not wander from a distant Graafian vesicle and become implanted freely within the tissue of the ovary. This conclusion has also been reached by Serebrenikowa (1912) in a report of a case of ovarian pregnancy, which confirms fully that of van Tussenbroek.

Bryce, Teacher, and Kerr have given an excellent review of the literature on ovarian pregnancy and Serebrenikowa has presented it from another standpoint. Both of the papers demonstrate that in ovarian pregnancy no decidua is formed, showing that a true decidua can not arise from the tissues of the ovary.

Since the cavity containing the ovum in ovarian pregnancy does not always seem to be encircled by a layer of lutein cells, it is concluded that the ovum either invaded the ovary from its surface or that it burrowed from the Graafian vesicle after fertilization. Undoubtedly the latter is the case in the specimen recorded by Bryce, Teacher, and Kerr. In it the growing ovum broke through the layer of lutein cells and made for itself a cavity in the vascular stroma of the ovary. This conclusion could also have been drawn from our specimen had not a second set of sections been made which shows that a beautiful and characteristic layer of lutein cells is present. In the first set of sections the wall of the cavity was faulty, while the second was perfect. We do not wish to question the accuracy of other observers in this respect; we want only to record our own experience. At any rate, the possibility of a secondary attachment of the ovum to the ovary through its direct wandering from the Graafian vesicle into the adjacent tissue, or indirectly through a reinvasion from the surface of the ovary, can not be denied until it is shown that the ovum is invariably lodged in a Graafian vesicle and surrounded by a layer of lutein cells of the same age as that of the ovum. Before this is possible it will be necessary to standardize the corpus luteum in relation to the ovum and embryo, and also to present as evidence only well-preserved specimens of ovarian pregnancy.

Specimen No. 1522, which was donated to the Department by Dr. H. M. N. Wynne, is a firm, nodular, dark-colored mass, 26 by 16 by 11 cm., shown in figures 163 and 164. In the gross, it especially recalls the specimens of Freund and Thomé (1906), Giles (1914–1915), and Jaschke (1915), and Lockyer's (1917) second case. The exterior is smooth though bosselated and formed by a rather injected layer which is extremely thin, showing the blood-clot beneath, around the greater extent of the specimen. The surface layer is eroded over several small elevated areas in which the blood-clot underneath is exposed. Hence, the capsule may have been ruptured in several or only in one of the areas as noted at the time of the operation. Near the region of amputation through the mesovarium shown to the right in the figure and marked by the corrugations of the hemostat, the tissue overlying the clot becomes more opaque, thicker, and also more yellowish. Here it is studded with small cysts, the character of which in itself suggests ovarian tissue. The color of the area to the right is also suggestive, and the cysts later were found to contain a clear, viscid fluid, so characteristic of cysts of the ovary. The location of the main portion of the ovarian stroma shows that implantation occurred near the mid-point of the free convex or posterior border of the ovary, and that the stroma forming the sides gradually was forced apart, not by the growing conceptus, except perhaps at the beginning, but mainly by the hemorrhage itself.

The major portion of the surface of the divided specimen shown in figure 165 is composed of blood-clot, the presence of which confirms the "blood-clot crepitus"

spoken of in the history. This clot contains an empty vesicle, the wall of which is formed for the greater part of its extent by a thin fibrous layer, except near the proximal or lower portion in the figure, where a thicker portion of ovarian tissue hoods the clot. Approximately only about one-third of the ovarian stroma seems to be preserved.

Near the exterior of the thicker portions of the latter, a small cyst with clear content is found directly beneath the surface, as indicated in figure 166. The distal or upper portion in the figure shows the clot to contain an empty, smooth-walled, degenerate chorionic vesicle, such as is frequently seen in tubal clots.

Examination of the cut surface with the binocular microscope shows the presence of only a few isolated, degenerated, and some hydropic villi scattered through the clot. Examination of the chorionic vesicle shows the presence of only a few attached villi and that the amnion is fused to the chorion. Since the entire specimen obtained at operation is covered still by a layer of ovarian tissue which is unbroken save in a few very small areas, it is evident that we are dealing with a very good example of an undoubted ovarian pregnancy in spite of the absence of an embryo. The latter undoubtedly did not escape through the small rupture in the capsule, for the chorionic vesicle seems entirely intact. Although the absence of a corpus luteum in the opposite or left ovary was not especially mentioned, lack of comment would seem to suggest that none was present, for the ovary very evidently was examined. Hence, this implantation probably took place within the Graafian follicle itself, and not in some other area of the ovary.

Celloidin sections of the excised portion show that the blood-clot contains no fibrin and that it is composed of relatively fresh and fairly well-preserved cells in the region near the main body of the ovarian stroma. The latter is quite normal, although decidedly vascular, and contains ova. The layer of the ovarian stroma which surrounds the clot becomes thinner and thinner the nearer the free border is approached. It also becomes more trabeculated, hemorrhagic, and degenerate. No overlying layer of smooth muscle, as mentioned by Young and Rhea (1911) and also by Kantorowicz, was seen. Some infiltration with polymorphonuclear leucocytes is noticeable. Degenerate villi are scattered about in the blood and a few others are apparently still attached to the equally degenerate ovarian stroma. Trophoblast is absent on these, although some of the villi that lie isolated in the clot possess a very evident epithelium and also are associated with a few small masses of very degenerate syncytium. Only a few degenerate, nonvascular villi are still seen on the chorion. Very little evidence of epithelial proliferation is present on these, despite the fact that the blood in which the vesicle is embedded is not very degenerate. This seems to suggest that the hemorrhage which caused the rupture of the ovary was comparatively recent, although the conceptus had been dead for some time. Some of the villi scattered about in the blood-clot are outlined by degenerate syncytium only, and nothing but small degenerate masses of the latter are seen on the chorionic membrane or lying about isolated in the degenerate blood found in other places. Nevertheless, the epithelium of the chorionic vesicle is thickened at several points. The amnion is fused with the chorion

and both membranes are very degenerate and destroyed amost completely in several places. The surrounding ovarian tissue, which is markedly vascular and degenerate, shows infiltration in places, especially where it is stretched over the large clot. No fibrous layer bounds the implantation cavity, as in the case reported by Seedorff. The ovarian stroma merely is slightly condensed here and there, and in places contains areas of hyaline degeneration, the exact origin of which could not be definitely determined. A few of these are found near the thin bounding layer of the ovarian stroma, but no lutein layer or even luteal cells could be recognized. The only objects seen which might be regarded as possibly luteal in origin are two microscopic rhomboidal areas which lie near a small depression upon the surface, indicated in figure 167. These areas, which were covered by a very thin layer of ovarian stroma only, were made up of parallel, degenerate, slightly separated cords consisting of a syncytium containing numerous rather pycnotic, unequal-sized nuclei. No pigment was seen in these areas, and were it not for the arrangement of the syncytial cords, one would not be reminded, even remotely, of a possible luteal origin. Although the germinal epithelium was wholly absent in the areas examined, these questionable areas nevertheless may have had such an origin. In the absence of lutein cells the present case corresponds to those of Freund and Thomé and others, and stands in marked contrast to the cases of van Tussenbroek, Franz, Anning and Littlewood (1901), and Thompson (1902). As in the case of Seedorff and others, no decidua was present, and nothing suggestive of an attempt at decidual formation, as reported by Franz, Webster (1904, 1907), Kantorowicz (1904), and Caturani (1914), was seen in the portions examined.

In describing his case, Seedorff declared that in some places of contact between the fetal and maternal tissues he could not discriminate between trophoblast and connective-tissue cells which looked like decidual cells and lutein cells. It is interesting that Seedorff also spoke of villi which were almost filled with Langhans cells, an observation which naturally makes one wonder whether by any possibility these could have been Hofbauer cells.

The preserved ovarian tissue which was found near the amputation stump contained hemorrhagic follicles, as observed also by Mall and Cullen (1913). A Graafian follicle 3 mm. in section, shown in figure 166, protruded above the rest of the stroma and was quite mature. The presence of this follicle might be taken as an evidence of the occurrence of ovulation during pregnancy, were it not for the fact that the presence of so degenerate a conceptus shows that as far as any effect upon the maternal organism was concerned, the pregnancy virtually had been terminated long before. That both ovulation and menstruation can and do return after the death of an ovarian conceptus, but before its removal from the ovary, is illustrated also by cases in the literature, especially by that of Norris (1909). One must assume, however, that few, if any, surviving fetal elements can be present under these circumstances. This conclusion also would seem to be confirmed by the remarkable case of Sencert and Aron (1919). These authors reported a case of ovarian pregnancy in which nothing but a portion of an umbilical cord 5 mm. long, containing Wharton's jelly, two arteries and a vein, and what was

regarded as a placenta, remained. The latter was said to be composed of a narrow layer of plasmodium and a much thicker layer of trabeculated syncytial trophoblast containing blood between the trabeculæ.

Because of the singular structure of this placenta and also because of the failure to find villi or any remnant of the membranes, the authors concluded that the chorionic vesicle therefore could not have reached the villous stage. How such a supposition can be reconciled with the survival of a portion of an umbilical cord entirely normal in structure it is difficult to see. The ovary concerned was brown, of the size of a "large fresh walnut," and contained a tumor, apparently the so-called placenta, which was 2 cm. in diameter. Although these fetal remnants had brought about not only almost complete amenorrhea for two years and also atrophy of the ovary and uterus, ablation of the affected ovary was followed not only by a return of the menses, but by a normal pregnancy within 7 months.

A second instance of ovarian pregnancy of special interest was that of Giles. No fetus was found, although the pregnancy was unruptured, and Giles estimated that the conceptus had died in the third or fourth week. The operation was not done until 5 months after the onset of the pregnancy. What is particularly interesting in this case is that Giles speaks of the mucoid degeneration of the connective tissue of the villi. The latter were found to be large, much branched, and had ramified in the clot. Since Giles also spoke of one of the illustrations as showing a vesicular state of some of the villi, it seems possible that this was a case of hydatiform degeneration, even though there were no signs of activity of the syncytium. Since the fetal membranes were isolated in a blood-clot, very much degenerated, and the villi were without a Langhans layer, one scarcely could expect to find much evidence of epithelial proliferation so common (but not essential) in hydatiform degeneration. Giles estimated that 4 months had elapsed since death of the conceptus, and if this specimen really was a hydatiform degeneration, it is the first one observed in ovarian pregnancy and hence of particular interest for this reason alone.

Several features in the clinical history of our second case deserve comment. First among these is the menstrual age as compared with the size of the chorionic vesicle. Since the cross-sections of the latter measure 15 by 18 mm. and since it and the amnion are degenerated and devoid of an embryo, it is evident that the latter must have died a good while before the time of operation. Hence, the menstrual period reported for June 25, 1916, very evidently was not the *last* period before pregnancy supervened, but the first period which recurred after the death of the conceptus. Consequently, this pregnancy undoubtedly dates from near April 13, the time of the first omitted period. Moreover, the conceptus must have died long enough before June 25 to have made inhibition of the succeeding period impossible. It should be noted, however, that the original menstrual cycle *apparently* was broken, for with the customary intermenstrual period of 28 days, menstruation normally would have fallen due on June 7 instead of June 25. Hence the maintenance of the original cycle would have brought rupture of this ovarian pregnancy, as indicated by the symptoms, on July 7, in direct

relation with the onset of menstruation. Nor does it seem unlikely that the hyperemia accompanying the return of menstruation on June 25, if such it really was, may have been partly responsible for the onset of a sufficiently large and persistent hemorrhage to cause the slight rupture indicated by the symptoms on July 7. It must also be remembered in this connection that cases of ovarian pregnancy have been reported in which menstruation was uninterrupted. But in the case of Chiene (1913), for example, the death of the conceptus may have occurred so early that the succeeding period was not inhibited, and the same thing may have been true in the case of Lea (1910).

Since the material from the curettage, done at the time of operation, showed the presence of a normal endometrium, the uterine decidua associated with this pregnancy must have been shed some time previously. Such a conclusion also would seem justified by the condition of the conceptus, which apparently was unable to prevent a return to the normal menstrual cycle. The absence of decidua at the time of operation also suggests that what was reported as a return of normal menstruation on June 25 may have been hemorrhage accompanying the expulsion of the decidua.

Since, in the present case, the chorionic vesicle was so degenerated and so completely isolated in a large clot, and especially since no well-implanted villi were found in the sections and gross portions examined, it is not at all probable that the hemorrhage that caused the rupture was due to a contemporaneous invasion of the vessels by the fetal trophoblast, such as occurs in uterine and tubal implantations, and as has been actually described also in ovarian implantations by Franz (1902) and by others. In the present and in similar cases in the literature it would seem that hemorrhage was made possible also by degenerative changes in the highly vascular stroma of the ovary, which had been greatly compressed and stretched by the proportionately large blood-clot, the organization of which would seem to have been precluded by its size alone.

The fact that relatively few unruptured ovarian pregnancies are recorded suggests that the old tenet that rupture is less likely the more advanced the pregnancy becomes, probably is open to serious doubt, as suggested by Banks (1912), who believed that the tubes can accommodate themselves more readily than the ovary. Banks stated that in the majority of cases of ovarian pregnancy rupture occurred in the first two or three weeks, and Caturani (1914) also expressed doubts regarding the dictum that rupture of the ovary is less likely the more advanced the pregnancy. No one will deny, I presume, that the symptoms of rupture may have been totally absent, as reported in the cases of Norris (1909) and Grimsdale (1913), but this does not necessarily imply that the ovarian stroma or the germinal epithelium still surrounded the full-term conceptus. Such an occurrence would be possible only if the ovarian stroma and the overlying germinal epithelium underwent an astonishing hyperplasia. Although such a thing is conceivable, it is decidedly significant that no one has reported any such finding or observed the presence of mitotic figures.

Instead of undergoing hyperplasia, the ovarian stroma in this case is found invaded, stretched, compressed, and degenerate, and the germinal epithelium is entirely absent. The fact that several observers have seen what they took for the fibrin layer of Nitabuch also shows that degenerative changes in the ovarian implantations may be extensive. Hence, it would seem to follow that the absence of symptoms of rupture merely may mean that the ovarian stroma and epithelium which happened to overlie the fetal membranes have gradually died and degenerated before being forced apart by the expanding conceptus or the increasing hemorrhage. That such a sequence of events is possible would seem to be undoubted, and mere distention of the ovarian stroma until it completely surrounded a full-term pregnancy is hardly conceivable; whereas, the absence of pain upon the yielding of an exceedingly thin degenerate layer of ovarian stroma is quite conceivable.

That rupture may occur very early is exemplified also by the cases of Chiene (1913), Seedorff (1915), and especially by that of Anning and Littlewood (1901) and of Holland (1911). In such curious instances as that of Grimsdale (1913) one can hardly assume that the ovarian tissue was preserved about the entire conceptus, and it is not at all unlikely that full-term ovarian pregnancies, which, according to Warbanoff, supplied a surprisingly large percentage of all cases collected by him, will form a far smaller percentage in the statistics of the near future. Indeed, they already form a far smaller percentage of those reported up to the present, and the advances in diagnosis alone make it very unlikely that in the future many cases of ovarian pregnancy will advance far before being detected.

A feature noticeable in both of these cases, and not heretofore described, we believe, is the presence of clubbing of some fibrous villi, as shown in figure 168. This is marked in the villi from case No. 550. It is less pronounced in case No. 1522. The villi and vesicles of both these specimens are so degenerate that one is almost led to surmise that these vesicles never became properly implanted, but depended very largely upon the surrounding blood for nutriment. As long as the fetal circulation was not established these conditions would seem to offer no special obstacles, for up to that time the conceptus necessarily is dependent upon other means of nutrition in uterine implantation also. Moreover, it may be doubted whether anything akin to true implantation can occur in the ovary or tube in the absence of decidual formation, and hence also of a capsularis. For even if the ovum buried itself in the ovarian stroma, the continued hemorrhage and the failure of a similar and proper response on the part of the ovarian stroma nevertheless would furnish decidedly abnormal conditions.

CLINICAL HISTORIES.

No. 550.

The patient, who was 24 years old, came to the Johns Hopkins Hospital June 1 with a diagnosis of appendicitis, which later was changed to ovarian pregnancy. The diagnosis was made unusually difficult by the patient's misleading statements.

When admitted to the ward the patient was not complaining of acute pain, but only of general soreness in the abdomen. There were paroxysms of pain, general throughout the abdomen, with intermissions in which she was somewhat more comfortable. With difficulty the pain was localized in both left and right sides of the abdomen.

When examined, general soreness of abdomen was found, the pain being more acute along the left side, shooting up to the right shoulder. The pain had not changed in character or intensity. There were sharp attacks of pain, especially in the left side, when the patient tried to move. There was also difficulty in breathing.

During the afternoon the condition of the patient was very uncomfortable, with repetition of the symptoms just given. The pains became more acute after taking ice. A renewed onset occurred at 11 p. m., and this continued with some nausea and occasional vomiting.

The pain had been sharp (not crampy), and had apparently gone up under the right C. M. in the morning. There had been pain also under the shoulder. The patient said she had never had any similar attacks, and was not constipated previous to this one.

On June 3 patient said she had a similar attack of abdominal pain three years before. This was general at first and finally became more pronounced on the right side, accompanied by nausea and vomiting. From this attack she did not recover entirely for 10 days. She had a similar but milder attack several months later. Dr. Finney writes:

"When I saw the patient I did not think it was appendicitis, but the history of similar attacks, which I had reason to believe afterwards were fictitious, and the patient's misstatements as to the subjective signs, together with the fact that the patient was unmarried, misled us as to the true diagnosis. Upon opening the abdomen, however, it was found to be filled with blood. At once the diagnosis was clear. I looked for the tubes, but found both intact. The right ovary was the point of bleeding; it was swollen and appeared as you found it in the specimen. The whole process was so definitely confined to the ovary that it seemed, clinically, to be a definite case of ovarian pregnancy."

No. 1552.

The patient, an Italian woman of 37 years, was admitted to the Gynecological Service of the Johns Hopkins Hospital July 12, 1916, complaining of a pain in the lower abdomen, nausea, and vomiting.

Family history.—Negative.

Past history.—General health good. She has never had any serious illness. For the past 5 years following a labor she has had recurring mild attacks of pain in the abdomen without nausea or vomiting.

Menstrual history.—Always regular every month, except when pregnant or lactating. Duration 4 to 5 days; painless, moderate flow. Last period June 25, 1916. Last preceding period, March 16, 1916. No intermenstrual bleeding before present illness.

Marital—Married 18 years; seven children, oldest 16, youngest born 1½ years ago (died, 1915). Has had three miscarriages. History of labors and puerperia vague.

Present illness.—Began 5 days ago (July 7, 1916) with sudden pain in lower abdomen, nausea, and vomiting. She has had marked dysuria and painful defecation. For 12 hours after onset there was rather profuse bleeding from the vagina and there has been a bloody vaginal discharge since.

(The patient does not understand English and her husband acted as interpreter.)

Physical examination.—T. 101.6 degrees F. P. 96. W. B. C. 8400. Hbg. 46 per cent.

The patient lies in bed grunting with pain. The skin is pale. The lips and mucous membranes are quite pale. There is a systolic blow heard at the apex and increasing toward the base, being loudest over the pulmonic area.

A drop of clear fluid was expressed from the right breast.

The abdominal respiratory movements are limited, although she does not complain of pain on deep inspiration. The flanks bulge somewhat. There is no demonstrable movable dulness. There is tenderness all over the abdomen, most marked over the lower left quadrant. There is increased resistance over the lower abdomen, but no muscle spasm. No masses can be made out.

There is a profuse bloody vaginal discharge. The cervix is pushed up behind the symphysis by a soft, exquisitely tender mass, filling the cul-de-sac. No crepitus is made out. Rectal examination confirms the vaginal. The fundus of the uterus is not felt.

July 13, 1916.—Ether examination.

There is a dark, bloody discharge from the vagina. There is no vaginal cyanosis. The cervix is lacerated, firm, and normal in size.

The fundus of the uterus is about normal in size and is in anteposition. A boggy mass fills the cul-de-sac and to the right of the uterus a fairly firm mass, the size of a small orange, which is somewhat movable, can be felt. Definite blood-clot crepitus can be felt on rectal examination.

Pre-operative diagnosis.—Extra-uterine pregnancy, ruptured.

Operation.—A free midline incision was made below the umbilicus. The peritoneum was blood-stained. The abdomen contained 200 to 300 c.c. of dark fluid blood and clots, and a large clot filled the cul-de-sac. Active bleeding had ceased. The left tube and ovary were normal and free of adhesions. The right tube, which was quite normal in appearance, lay over a mass which had replaced the right ovary. This mass was roughly spherical, 5 to 6 cm. in diameter and semi-solid in consistency. Over the surface there were six or eight nodular projections, about 1 cm. in diameter. At the top of one of these projections there was a very small opening, from which bloody fluid could be squeezed. The surface of this mass was white, with spots of bluish-black discoloration.

The appendix was normal, except at the tip, where it was adherent to a blood-clot.

The tumor was removed by clamping, tying, and cutting into the right infundibulo-pelvic ligament and the right utero-ovarian ligament. The right tube was not removed. The appendix was also removed and all blood and clots were cleaned out of the abdomen. The incision was closed without drainage. At the close of the operation the uterus was curetted. The uterine cavity measured 7.5 cm. in length.

A subcutaneous salt solution infusion was started on the table and continued on the ward until 2,000 c.c. had been absorbed.

The patient was in good condition at the end of the operation and made an uneventful recovery.

The *urine* on admission contained red blood-cells, white blood-cells, no casts, acetone, a trace of albumin, and no sugar. Several days after the operation it was negative, except for a faint trace of albumin.

August 2, 1916.—Discharged in good condition.

Gyn. Path., No. 22346.—Normal endometrium from curettage.

DESCRIPTIONS OF PLATES.

Plate 15.

Fig. 157. Drawing of posterior view of pregnant ovary with tube. No. 550.

Fig. 158. Transverse section of pregnant ovary cut at point of rupture.

Fig. 159. Outline of transverse section of ovary taken in the region of the letter *o* in "*Ovary*" (fig. 157). *Cl*, lutein cells; *Bcl*, Blood clot; *Cf*, corpus fibrosum; *G*, Graafian follicle. ×2.

Fig. 160. Drawing of portion of the corpus luteum, indicated by small square to the left in fig. 159 (marked fig. 4 in drawing). *Ot*, tissue of ovary. ×70.

Fig. 161. Drawing of a portion of the ovary, indicated by small square to the right in fig. 159 (marked fig. 5 in drawing). ×70.

Fig. 162. Drawing of a section through free surface of clot, illustrated in section in fig. 158, showing wall of chorion and a villus surrounded by clot. *Tr*, trophoblast; *L*, leucocytes; *Ch*, chorion; *V*, villus; *Coe*, cœlom. ×50.

Plate 16.

Fig. 163. External appearance of intact specimen. No. 1522. ×0.75.

Fig. 164. External appearance of same specimen, showing where block was removed. ×0.75.

Fig. 165. Appearance of cross section of pregnant ovary and tube, same specimen. ×0.75.

Fig. 166. Photograph of a section taken from the thick portion of the ovarian stroma near the mesovarium, showing a well-developed Graafian follicle. Same specimen. ×2.25.

Fig. 167. Section of part of the same specimen, showing the clot which contains the empty vesicle largely surrounded by ovarian stroma. ×1.9.

Fig. 168. Marked clubbing of villi of No. 550. ×2.25.

Fig. 169. Cross section of decidua and conceptus. No. 698. (See Chapter XII.) ×4.5.

Fig. 170. Section of conceptus, decidua, and muscularis. No. 970. (See Chapter XII.) ×4.5.

Fig. 171. Section of decidua and conceptus. No. 962. (See Chapter XII.) ×4.5.

Fig. 172. Section of a part of the conceptus, showing chorionic membrane, cyemic (?) rudiment (x) and yolk-sac. No. 1843. (See Chapter XII.) ×51.5.

Fig. 173. External view of No. 2047, showing the distended amnion. (See Chapter XII.) ×2.25.

Fig. 174. Section of the tube and the conceptus. No. 977. (See Chapter XII.) ×3.3.

158 157

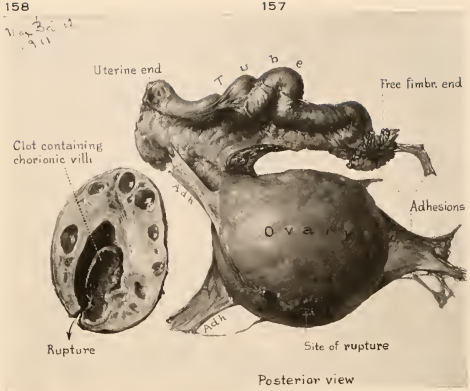

159

162

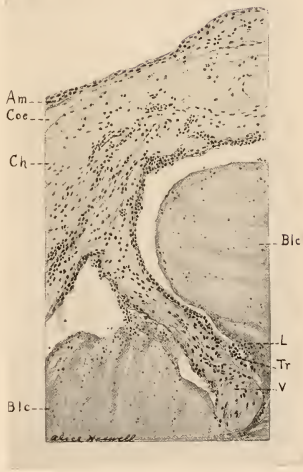

161

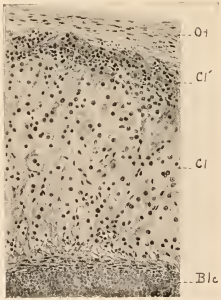

160

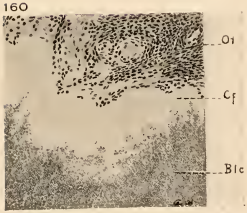

163

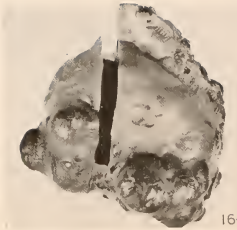
164

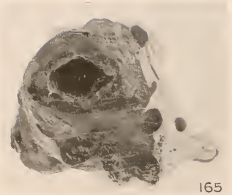
165

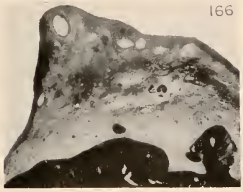
166

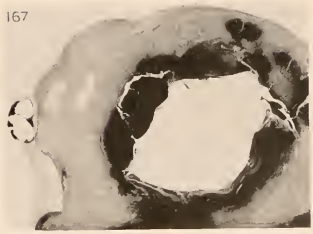
167

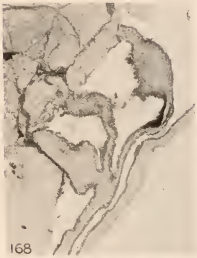
168

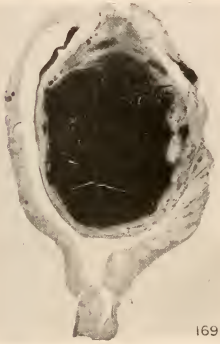
169

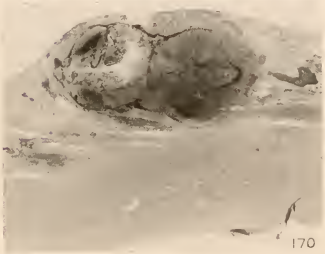
170


171

172

173

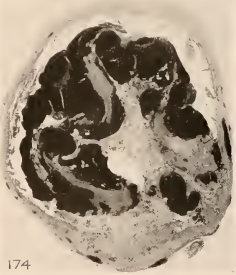
174

CHAPTER XII.

LYSIS AND RESORPTION OF CONCEPTUSES.

It has long been known that considerable intrauterine retrogression of a conceptus can occur in multiparous mammals. D'Outrepont, for example, on page 192 of the catalogue of his collection, is said (Müller, 1847) to represent the uterus of a rabbit, in which an apparently full-term fetus is found near the distal end of one horn, although the approximate portions of both horns contained but remnants of fetuses, one in each. According to Müller, the enlargement in the right horn contained a "cyst filled with rabbit hair embedded in a soft mass and that on the left side a similar convolute of hairs without a cyst." This, as far as I know, is the earliest reference to, even if not the earliest observation upon, a fetal retrogression. But since rabbits are born naked, one is left to speculate upon the validity of this observation. However, that the idea holds is indicated also by some experimental work.

Giacomini (1889) stated that he could effect absorption of the embryo in rabbits within a few days by killing the embryo upon the seventh or eighth day of *gestation.* Since this is just about the time that implantation of the ovum occurs in the rabbit, I presume Giacomini really meant on the seventh or eighth day after *implantation.* Giacomini added that these things show a close relation between nodular and atrophic forms and the entire absence of embryos. Strangely enough, Giacomini (1893) reported that puncture of or slight pressure upon the implantation cavity on the ninth day of gestation was followed by complete absorption of the conceptus by the thirteenth day, but he did not think that the human blastodermic vesicle can undergo simple degeneration.

Sokoloff's (1896) meager report also seems to indicate that in dogs bilateral ovariotomy leads to the death of the embryo and to abortion of it and of the entire conceptus. Strahl and Henneberg (1902) also found that conceptuses in different stages of retrogression occur quite commonly among normally developed ones in the ferret, marmot, and mole. They also found that the entire placenta and probably also the fetal membranes, as stated by Hubrecht, are normally retained for some time, even up to a month after parturition in the mole. Similarly, L. Fraenkel (1903) was able to cause the death and also the uterine absorption of conceptuses in rabbits up to the twentieth day of pregnancy, through destruction of the corpora lutea. Fraenkel found that after 14 days all that remained in the way of evidence of some pregnancies was an anemic ring which disappeared completely within three weeks. Henneberg (1903) also found that intrauterine death and retrogression of the guinea-pig fetus can be effected experimentally through various means, and, according to Koebner (1910), not merely ova or young fetuses are absorbed, but even the bones of older ones disappear completely under experimental conditions in the rabbit. It would seem unlikely, however, that such could be the case in any but the very earliest stages in the development of the skeleton, for a considerable degree of acidity would have to develop in order to make this

possible. Since it is believed that the development of acidity not only is slow but also slight in embryonic tissues, Koebner's conclusion regarding the bones seems to be open to some doubt. Wiener (1905) also found that autolysis is very slight in tissues with an alkaline reaction and that a slight increase in acidity greatly accelerates it.

Fraenkel (1910[b]) extended and confirmed his work done in 1903 by a very large series of experiments touching various phases of the corpus luteum problem, and among other things concluded that one corpus luteum can protect at least three ova sufficiently to insure continued development.

Although the degenerating ova found by Huber (1915) in the rat were very young, the significance of the facts would seem to be similar. Likewise Mall (1915), while writing "On the fate of the human embryo in tubal pregnancy," stated that "we have no data on the number of ova which disintegrate early, but the study of comparative embryology warrants the conclusion that many young ova degenerate and disintegrate. I am informed by Dr. Huber, who has studied with great care much material among rats, that some of the fertilized ova break down before implantation. The same seems to be true regarding the pig. We usually find more corpora lutea in the ovaries than embryos in the uterus, indicating that all of the ova do not produce normal embryos." Similar phenomena also were reported by Meyer (1917[a]), in regard to young conceptuses in the guinea-pig. Curtis (1915) also reported the absorption of ova in guinea-pigs in consequence of the injection of extracts of the human placenta, but unfortunately Curtis did not give convincing evidence regarding his knowledge of the presence of pregnancy in the animals concerned, nor did he make a microscopic examination. Since Curtis stated that injections of defibrinated human blood had the same effect as the injection of extracts of the human placenta, and that the injection of extracts of guinea-pig placenta and of guinea-pig blood had no effect whatever, one can not help but feel decidedly skeptical regarding the trustworthiness of his experimental proof.

It is well to remember in this connection that phenomena which occur in other mammals, or conclusions drawn from these phenomena, must be used with caution when referred to man. The uteri of other mammals may well show a greater tolerance to the presence of dead fetal tissue and also greater resorptive power. Robinson (1904) stated that Vernhout showed that maternal tissues are not shed at the time of birth in the mole, and that some of the fetal tissues are retained to be absorbed later. Hill, it seems, found the same thing to be true in *Perameles* and *Dasyurus*. Jenkinson (1913) also stated that in *Perameles* the allantois and its blood-vessels are regularly absorbed through the agency of maternal leucocytes by the parturient uterus and that fetal tissues are absorbed somewhat similarly in *Dasyurus*. However, since the young of some marsupials are in a very immature state during the first months of gestation and are then transferred to the marsupium as naked little fetuses, said to be only about an inch long in the kangaroo, it is clear that absorption of the secundines at this stage of development

would be something quite different from their resorption at the end of the gestation period in higher mammals, especially man.

Although we have considerable evidence regarding retrogression and the partial or even the total intrauterine absorption of conceptuses in various mammals, I have not been able to find any conclusive evidence in the literature regarding the occurrence of this phenomenon in man. It is true that cases of E. Fraenkel (1903), Rosenkranz (1903), Polano (1904), and cases reported by others also are referred to as such examples, but a careful examination of the reports shows that those cases can hardly be regarded as falling under the head of intrauterine absorption of ovum, embryo, or fetus. It is true that in the cases of Polano and Rosenkranz, the skeletal elements only were seen to have been discharged, but in the case of Polano the amniotic fluid nevertheless may have carried a great many fragments of embryonic tissue away with it beforehand. Furthermore, Polano did not claim his case as one of complete intrauterine absorption, but merely as one of remarkable intrauterine maceration under aseptic conditions.

The history of the case of Rosenkranz, on the other hand, shows quite clearly that the fetus was destroyed by putrefactive changes. Rosenkranz himself emphasized this, but strangely enough ruled out entirely the occurrence of maceration. He further stated that the patient herself noticed the discharge of some bones with the "menstrual" flow. However, under the above conditions the recurrence of true menstruation is exceedingly unlikely unless the fetus was dead a considerable period before the rupture of the membranes occurred, and the placenta had been detached at least partly, for only under such circumstances could some regeneration of the mucosa occur and thus make a return to true menstruation possible. It is nevertheless possible, however, that the time of abortion was coincident with the date on which menstruation might have recurred. A small number of cases in the Carnegie Collection have a history which makes such a suggestion probable. Just why the expulsion of a dead, retained conceptus should occur at the time when menstruation would have recurred normally had pregnancy not supervened it is difficult to say, but since the inhibitory effect upon the menstrual cycle exercised, directly or indirectly, by the living fetus is absent in cases of premature death and retention, it is possible that the abortion might occur at a time when the impulses of a return to the normal non-pregnant status of the maternal organism becomes more evident; that is, at the time of the recurrence of the normal menstrual cycle.

One can not but recall in this connection another group of cases which give a history of uninterrupted menstruation throughout the entire period of pregnancy. In some of these cases it is evident that it is a question of more or less regular hemorrhage rather than of true menstruation, and it may be possible that in the others these hemorrhages happened to fall at intervals of the same length as the normal intermenstrual periods. In the last group the exact status of the cases can not be discerned from the histories alone. However, since there is no endometrium, or at most a partial one, to shed, genuine menstruation manifestly can not occur throughout pregnancy. Indeed, it seems more probable that the

cases of supposed uninterrupted menstruation fall into the last group, although it is not impossible that rarely hemorrhage may occur only at the dates of normal recurrence. This would seem possible because of the defective inhibition of the returning normal impulses exercised by the dead or dying conceptus and the retrogressing corpus luteum. This conclusion harmonizes with the tendency to abortion which seems to be present at the time of periodic hyperemia and hyperirritability in some of these cases.

Although dissolution of the embryo or fetus alone has long been known to occur, there seems to be no convincing evidence in the literature of the occurrence of intrauterine autolysis and absorption of entire conceptuses. Moreover, as already stated, it is to be doubted very seriously whether complete intrauterine absorption is possible after the formation of the skeleton has been well begun. The fetal parts at this time are so resistant that the uterus is stimulated to expel the macerated remnants long before absorption of them can occur. Furthermore, complete absorption would also seem to be hindered by the physical conditions which obtain in the human female. Only so long as the decidua capsularis is relatively thick, and hence effectively prevents the escape of the products of autolysized embryonic tissue, does complete absorption of a young uterine conceptus seem to be possible. The same thing is probably true in some cases of tubal pregnancy, although the occurrence of early and repeated, or even prolonged, hemorrhage in them makes complete intratubal absorption much less likely. However, that complete intrauterine absorption actually seems to occur in the human female, it is my purpose to establish.

The occurrence of missed abortion and also of missed labor have long been matters of common knowledge among physicians. But these are phenomena usually connected with the later months of pregnancy. In the overwhelming majority of these cases the fetus was retained for a considerable period after its death and then aborted in a more or less macerated condition. Under these circumstances it may, to be sure, undergo absorption in part, but expulsion of macerated or even calcified remnants of the fetus nevertheless eventually occurs. That this is so, even after an exceedingly long period of retention *in utero*, is shown splendidly by the case of Schaeffer (1898). In view of the exceedingly common occurrence of retention of conceptuses *in utero*, it is surprising that as late as 1896 Graefe succeeded in collecting only 58 cases of missed abortion from the literature. Graefe stated, however, that he himself met with 11 cases in 7 years, to which number he added 12 observed by a friend. Nevertheless, from these facts one might assume that retention of conceptuses after death is a rare rather than a very common thing. The explanation probably lies in the fact that the term "missed abortion" is understood as referring to advanced rather than to early cases of pregnancy. Retention of the latter for varying periods of time is exceedingly common, however, and one might say that retention is the rule, for it is exceedingly rare that a fresh, wholly unmacerated conceptus is obtained through abortion unprovoked by mechanical means or acute disease. Hence post-mortem

prepartum changes must be expected in practically all other specimens which form the great majority of all abortuses.

Among the large series of over 2,000 abortuses in the Carnegie Collection, I have so far found only a few specimens of almost complete intrauterine absorption. In one of these, No. 698, only a few vestiges of syncytium and trophoblast remain. Not a single fragment of the chorionic or amnionic vesicle or of the embryo could be found upon microscopic examination. Were it not for the presence of decidua and the above microscopic remnants, one might doubt whether pregnancy really had supervened in this case. However, since the specimen shown in figure 8 (plate I, Chapter IV) was aborted with the entire intact decidua which still surrounded the remnants of the conceptus completely, as shown in figure 169 (plate 16, Chap. XI), there manifestly could have been no loss of embryonic tissue either before or during abortion. This abortus, which measured 50 by 20 by 13 mm., was donated by Dr. N. E. B. Iglehart, of Baltimore. It had a menstrual age of 56 days, but the condition of the few remnants and the size of the implantation cavity show that development did not proceed very far before growth was inhibited. Aside from the absorption of almost the entire conceptus, the decidua not only is infiltrated, but also shows degenerative changes. As illustrated by figure 169, which shows the intact capsularis separated by a narrow space from the parietalis, the former is filled completely by blood-clot. It is at the periphery of this clot that the isolated microscopic remnants of the syncytium and trophoblast, together with a few gossamer or shadow villi, are found. Since there is no blood between the capsularis and the parietalis, it would seem to follow that the hemorrhage was limited entirely by the capsularis, a conclusion which is indicated also by the absence of a history of bleeding. Since the last menstruation began on April 11 and the abortion occurred on June 6, it is seen that the latter occurred on the first day of the beginning of the second lapsed menstrual period. Although the appearance and the condition of the decidua seem to suggest that considerable regeneration of the endometrium had occurred, it is possible, though unlikely, that the bleeding accompanying the abortion was menstrual and that hence the abortion should be regarded as a mere incident accompanying the return of normal menstruation rather than as the predominating event.

That considerable restoration of the endometrium may occur while the conceptus still is within the uterus was shown by the case of Orloff (1895). In this case the endometrium was composed of a cylindrical epithelium and the uterine musculature showed no evidences of the presence of gestation changes. Iwanoff (1898) also found the decidua absent in a case of long retention and its place taken by a low cylindrical epithelium, although the placenta was still partly attached to the uterus. E. Fraenkel (1903) also emphasized the fact that regeneration of the endometrium may begin before abortion occurs, and these things make it possible that hemorrhage, which may occur at time of abortion, may largely be true menstrual hemorrhage.

The absence of blood between the capsularis and the parietalis and the absence of a history of bleeding do not imply that the development of this conceptus

progressed uninterruptedly until birth. The histologic picture alone is conclusive proof to the contrary. In the absence of any larger portion of the conceptus it is impossible to say about how far development had proceeded, but it is unlikely that it proceeded much beyond the first month. In any case, disintegration, solution, and resorption of almost the entire conceptus surely must have consumed several weeks at least. Indeed, it is possible that the ovum never became firmly attached, though embedded in the decidua.

In other cases it also seems likely that the fertilized ovum became embedded quite normally, but that it was strangulated by severe hemorrhage which loosened the attaching villi, thus interrupting the intervillous circulation. Since the resulting stagnation of the blood must make impossible the indispensable chemical interchanges upon which the life of the embryo depends, the latter probably dies first. It is decidedly interesting that considerable hemorrhage, sufficient, in fact, to result in the death of both the embryo and the chorionic vesicle, can occur while the whole conceptus still is surrounded by the decidua capsularis, without rupture of the latter. The failure of absolute or complete absorption of the last few small remnants of this conceptus probably may be attributed to the fact that the small remnants of degenerate trophoblast and syncytium which remain, or the influence of the corpus luteum, no longer were able to inhibit menstruation. Hence the decidua, together with these few small remnants of the conceptus, were expelled *in toto*, and it may be extremely significant that this occurred exactly two menstrual months after the beginning of the last period. Since 3 other specimens of a series of 17 composed of villi only were aborted at the time of recurrence of the regular period, the idea that abortion occurs oftener at this than at any other time would seem to receive some confirmation. Moreover, it would seem quite natural that a detached decidua which has subserved its functions would be more likely to be shed at this time and that an unabsorbed conceptus, which had been converted essentially into a foreign body, should then also be expelled. Since detachment of the decidua also permits regeneration of the mucosa and isolates the conceptus, it removes the inhibitory effects of the conceptus upon the maternal organism and clears the way for a return to the normal non-pregnant status.

It is impossible to decide how far the development of this conceptus had progressed before its death, but the marked extent of the absorption shows beyond doubt that the latter would have been completed long before the advent of the next or third menstrual period had the second period also been inhibited. Under these circumstances the empty decidual cast would then have been expelled alone and might well have directed attention to the possibility of the existence of a tubal rather than a uterine pregnancy.

A second case is No. 970, donated by Dr. R. W. Hammack, of Manila. This specimen is interesting not only because it is a case of marked intrauterine absorption, but also because it was obtained with the entire uterus at necropsy. The chorionic vesicle, which measured only 3 by 5 mm., together with the entire thickness of the decidua and the musculature, is shown in section in figure 170 (plate 16, Chap. XI). The uterine cavity contains some blood and the entire decidua

was covered with hemorrhagic nodules, the largest of which were about 10 mm. in diameter. One of these, which was a trifle larger than the rest, contained the conceptus. The cavity of the chorionic vesicle was filled with a homogeneous substance containing degenerate cells and portions of disintegrated chorionic membrane. The villi are about 0.5 mm. in length and are covered with trophoblast and syncytial buds. No trace of the embryo or of the amnion was found, although the whole conceptus is still covered by the capsularis, which, like the rest of the decidua, is infiltrated. Although lysis and absorption did not progress so far in this as in the previous specimen, the process nevertheless is far advanced. It proceeded no farther because the mother committed suicide, although the multiple hemorrhages in the decidua would seem to suggest that abortion nevertheless was seriously threatened, if not inevitable, before she took her life. That the focal hemorrhages in the decidua could be attributed to the hydrochloric acid swallowed with suicidal intent is extremely doubtful, for the histologic condition of the conceptus shows conclusively that the changes in it could not possibly have been produced in the short interval of 4 days which elapsed between the suicidal attempt and death. Since the menstrual history of the case remains unknown, it is impossible to determine the menstrual age of the specimen, but the degenerate chorionic vesicle would seem to imply an age of only about 10 or 12 days. However, as this young woman was but 16 years old and apparently illegitimately pregnant, it is more than likely that the suicidal attempt occurred, as so often is the case, during the time of the first lapsed period. Hence the surmise that the multiple hemorrhages in the decidua may have been provoked by the returning menstrual cycle gains somewhat in probability, especially so since the size and the condition of the conceptus both suggested that it must have died some weeks previous to the necropsy.

A third early specimen illustrating the progress of intrauterine absorption is No. 962, donated by Dr. Joseph M. Jackson, of Pittsburgh. In contrast to the preceding two, this chorionic vesicle contained a macerated embryo 4 mm. long. The menstrual age is unknown, but the chorionic vesicle measured 34 by 28 by 24 mm. and was covered almost entirely by villi. The latter, which contained degenerating vessels, are matted together with necrotic trophoblast and show other evidences of retention. As shown in figure 171 (plate 16, Chap. XI), which represents a section of the entire conceptus with the surrounding decidua, the amnion was preserved and contained some coagulum. Mall found the embryo greatly macerated and the organs and cavities partially obliterated. The slight break in the decidua capsularis may be the result of handling or of technical procedures. Since the specimen was aborted with the entire decidua, there can be no question of escape of a portion of the conceptus.

That it is not alone very young conceptuses which may undergo almost complete lysis is illustrated by No. 606, a chorionic vesicle measuring 18 by 13 by 18 mm. This specimen, which was donated by Dr. Charles S. Parker, of Baltimore, is covered with villi 2.35 mm. long. Yet Mall found no trace of an embryo and stated that, in spite of the outwardly normal appearance of the chorionic vesicle,

the villi and the chorionic membrane are structureless. In the absence of the clinical history one must needs be cautious, but I think it can be safely assumed that in this case neither embryo nor amnion disappeared solely as a result of postpartum maceration. That this assumption probably is correct is shown also by other specimens, the histories of which fortunately are known. Nevertheless, maceration, although not necessarily putrefactive maceration, undoubtedly was an important factor in the production of the state in which this specimen is found. This conclusion is confirmed by the occurrence of all manner of transitions between the almost perfectly preserved structure and the pure shadow or gossamer pictures such as are presented in the photograph of the cross-sections of the villi of this specimen shown in figure 11 (plate 1, Chap. IV). All that remains of the villi are spiderweb-like outlines, the fibers of which are exceedingly fine, but which nevertheless preserve the form of the villi and of the chorionic membrane so perfectly that Mall especially recorded that the external appearance of the chorionic vesicle was normal.

Since chorionic vesicles devoid of an embryo when examined form about 32 per cent of those classed as pathologic in the Carnegie Collection, it is evident that absence of the embryo itself is relatively common in early abortuses. It would be incorrect, however, to assume that they had undergone absorption in all these cases. A fine example of one of these empty chorionic vesicles is No. 1224, a portion of which is shown in figure 10 (plate 1, Chapter IV).

This specimen was found in an unopened uterus removed at hysterectomy for cervical myoma. The chorionic vesicle, which measured 36 by 25 by 13 mm., was collapsed, free from the uterus, and embedded in coagulum. The only content of this chorionic vesicle was a dark grayish coagulum which contained no remnant of the embryo or of the amnion. This almost amorphous so-called magma included only a few isolated cells. In spite of this fact, the trophoblast, which had markedly proliferated, is well preserved over large areas, and many of the vessels in the chorionic membrane are filled completely with erythroblasts. A few degenerate masses of trophoblasts and fused degenerate villi are also present. Some villi show evidences of maceration, others of "mucoid" degeneration, although they still may contain vessels. Some, however, are represented by a hyaline outline only. The stroma and the epithelium of many of the villi are well preserved, however, and the same thing holds for the chorionic membrane. The decidua shows slight general and very marked local infiltration. Some remarkably dense periglandular and perivascular zones of infiltration are also present. The mucosa, too, is infiltrated and contains islands composed exclusively of round cells. Besides maceration effects, many of the villi show marked changes, undoubtedly hydatiform in character. In this case it is possible that we are dealing not so much with absorption as with dissolution of the embryo, for the digestion products of embryo, yolk-sac, and amnion, instead of having been wholly absorbed, may still be contained in the fluid within the chorionic vesicle.

Before briefly considering the evidence regarding absorption offered by tubal and ovarian specimens, I wish to refer to No. 1843. This unique specimen, which

was donated to Stanford University by Dr. Eugene V. Falk, of Modesto, California, had the villi rather sparsely and irregularly distributed, as shown in figure 7 (plate 1, Chap. IV). However, the entire specimen was so splendidly preserved that investigators of unique opportunity and experience were uncertain as to its normality. Even after careful inspection under low magnification, the writer, too, felt uncertain, but on receipt of the specimen he informed Dr. Falk that it probably was pathologic. This opinion was based almost wholly on the irregular distribution of villi, their complete absence on part of the surface, the large size of the yolk-sac, the unusual translucence of the entire specimen, and upon the *apparent* absence of the embryonic disk. About one-third of the entire surface of the chorionic vesicle was devoid of villi, and where they were present they seemed to be in widely different stages of development. They differ markedly not only in length and in diameter, but also in the complexity of their branching. Some which were represented by fine threads were found to be represented by stroma only, the epithelium having been stripped, probably during the removal of the blood from which the specimen was freed before it was received at the laboratory. Other villi are torn, those which are preserved are clubbed but slightly, and some are so short that they look like little droplets on the surface of the chorionic membrane. Those near the bare areas are almost transparent, but nearer the other pole they become more opaque. The caliber varies from 0.16 to 1 mm. and the greatest length is 2.25 mm. The chorionic vesicle measured 6 by 4 by 5 mm. and the partially invaginated yolk-sac 2 by 2.6 by 1.8 mm. A smaller, less transparent vesicle, which was thought to represent the amnion, was seen between the yolk-sac and the chorionic membrane, but no embryonic disk could be recognized.

An examination of the microscopic sections of this vesicle showed that it was macerated. The epithelium is missing in many places and the histologic details are wanting. Hence this chorionic vesicle very evidently ceased to live some time before it was aborted, and this conclusion is corroborated also by the clinical history. The menstrual age of the specimen is 39 days, but the chorionic vesicle, which was approximately spherical, measured only 6.5 mm. instead of 35 to 40 mm. as implied by the menstrual history. That growth ceased long before the occurrence of the abortion is implied also by the fact that Dr. Falk stated that the patient had a slight uterine hemorrhage about 10 or 12 days before. It is interesting, and probably also significant, that the date of this hemorrhage also coincides with the time when the first lapsed period was due. This is possible because this conceptus apparently had been dead sufficiently long to fail to inhibit the return of menstrual bleeding. Since the size of the chorionic vesicle suggests an age of 10 to 12 days, this assumption seems warranted, especially since it may be assumed that development probably never proceeds undisturbed to the time of abortion whenever the pregnancy is terminated spontaneously, or perhaps better, without the intervention of external or internal mechanical forces or factors. It may be largely because of this fact that conceptuses from abortions resulting from intrauterine causes are always macerated.

Careful examination of the serial sections, generously made in the Carnegie Laboratory of Embryology, fails to reveal any remnant of the body of the embryo except, perhaps, a small nodule shown above the X in figure 172 (plate 16, Chap. XI). Yet, according to the menstrual age, the embryo should be 10 to 12 mm. long. The appearance of this nodule suggests that it may be a remnant of the primitive streak in spite of its deep location, although it may also be a rudiment of the allantois. The yolk-sac is large and invaginated and its size out of all proportion to that of the rest of the embryonic rudiment. In the latter there is a rather large mass of cells containing a space which, I take it, represents the amniotic cavity. An examination of this cavity and of the surrounding cells suggests that it resulted from splitting or cavitation, as is the case in bats and as is assumed also for man by Eternod and others. This cavity may have resulted from dissolution of the cells *in situ*, and if in fact it represents the early amniotic cavity, then, whatever its genesis, it is probable that it was not formed in consequence of folding.

It would seem, then, that we have here a conceptus in which the process of development of the embryo itself was inhibited very early but that the yolk-sac and the chorion continued to grow for some time.

Aside from showing a probable and hitherto unobserved stage in the formation of the amniotic cavity, this pathologic chorionic vesicle is of special interest also in the absence of coagulum or so-called magma. The chorionic vesicle and the space taken for the amniotic cavity were filled with perfectly clear fluid. Although this small conceptus is markedly macerated, it is only in the early stages of disintegration. Nevertheless, much longer retention might have resulted in its complete dissolution, even if not its complete absorption. Since this small vesicle was aborted in its entirety with blood-clot, it is highly probable that most of these degenerative changes occurred after it was loosened from the implantation site, probably by rupture of the decidua capsularis in consequence of hemorrhage.

In other older conceptuses in earlier stages of disintegration, as No. 2047, the amnion is preserved and distended, as shown in figure 173 (plate 16, Chap. XI). Both chorion and amnion are macerated and distended with clear fluid; and it seems strange indeed that the embryo and the yolk-sac may disappear completely without even a final clouding of the amniotic fluid. There may have been temporary clouding, but every now and then a specimen is received in which both the vesicles are distended with absolutely clear fluid, a fact which also implies that autolysis of the embryo occurred without digestion of the enveloping amnion.

Since only a pseudo-decidua forms, and then but rarely and very early, in cases of tubal pregnancy, the sequence of events leading to dissolution of the conceptus must be rather different. There can be no accumulation of blood in a capsularis. Hence the conceptus usually becomes isolated in blood or blood-clot within the tube, and undergoes degeneration as the hemorrhage continues and the tube becomes distended. If detachment of the conceptus occurs very early, it is conceivable that it may undergo complete disintegration also within the tube, that the latter may heal and the symptoms subside completely. While the occur-

rences of such instances of spontaneous cure of tubal pregnancy undoubtedly are exceedingly rare, evidence at hand seems to show that they can not be wholly excluded. This, I am told, agrees also with contemporary clinical opinion.

The possibility of tubal abortion with subsequent intraperitoneal disintegration, lysis, and absorption must also be borne in mind. The occurrence of nothing but fragments of villi in a tubal clot, as shown in the case of No. 977, represented in figure 174 (plate 16, Chapter XI), however, can not be accepted as positive proof that all the rest of the conceptus was absorbed intratubally. A portion may have been aborted, yet specimens such as Nos. 2035 and 1938 speak eloquently for the *possibility* of absorption. The embryo and yolk-sac in the latter specimen are disintegrated almost completely and the scarcely recognizable remnants lie isolated in the chorionic cavity, which is moderately filled with an amorphous coagulum. The stroma of the chorionic membrane is edematous and degenerate, but nevertheless contains some well-preserved vessels, a few of which contain some blood-cells. The same thing is true of the stroma and of the vessels of the villi, which also are in process of dissolution. A moderate amount of trophoblast is present, but there is very little syncytium. The epithelium of some of the villi has undergone hyaline degeneration. The blood-cells in the large clot in which this chorionic vesicle, which measured 8 by 5 mm. in section, was embedded, are preserved fairly well, especially near the vesicle. Nevertheless, the old conceptus very apparently is in a state of disintegration and lysis, the tube-wall is very thin, and the mucosa congested, hemorrhagic, and atrophic.

No. 2035, also a tubal specimen, likewise is an empty chorionic vesicle in process of disintegration, and many other specimens might be listed, but these examples suffice to indicate that intratubal as well as intrauterine lysis and, in part at least, of resorption of conceptuses undoubtedly occurs in the human being. It is of course exceedingly unlikely that in case of the uterus this can occur before the impregnated ovum is embedded, for, failing to embed, it undoubtedly would escape relatively promptly, although the observations of Kirkham (1916) show that the fertilized ova in mice suckling their young may lie unimplanted within the uterus for over a week.

A free fertilized or unfertilized ovum which disintegrated within the tube might be absorbed completely. The same thing holds for early conceptuses within the implantation cavity, for a relatively small amount of hemorrhage could detach them completely without rupturing the capsularis. Death, disintegration, and absorption, as illustrated in the cases above, might then occur. In case of older specimens, the hemorrhage responsible for the loosening of the conceptus would have to be proportionately much greater, for the attachment of the placenta is firmer, though rupture of the capsularis is probably easier. That this assumption is correct is shown also by the almost universal history of bleeding in these cases, and it is only in the early stages of development that the conceptus can be expelled intact while still contained in the implantation cavity and aborted, completely wrapped in the decidua, as in case of No. 698.

Since 12.8 per cent of all abortions and 32.3 per cent of all those classed as pathologic in the first 1,000 accessions in the Carnegie Collection are composed of villi only, of empty chorionic vesicles, and essentially of chorion and amnion alone, one might assume that all these specimens represent stages in the process of intrauterine disintegration and absorption. Most of them undoubtedly do belong in this category, but in many cases in which villi only are found the rest of the conceptus, and in others the embryo as well, has been lost. Since 46.4 per cent of all tubal specimens and 71 per cent of all those classed as pathologic are composed of villi only, of empty chorionic vesicles, and of chorion and amnion only, it might be assumed that digestion and absorption are more active within the tube than within the uterus. Such a conclusion is not justified, however, for almost all tubal specimens are isolated while young, and only exceptionally does one reach the later months of pregnancy. Hence, those falling in the above-named three groups of tubal specimens form a relatively larger percentage.

Cases of partial dissolution of the embryo are of course common, as almost every one knows. As far as I can learn, however, the two cases reported here are the only ones offering unequivocal proof that dissolution of the entire conceptus may be absolutely complete and that the intact empty decidua then may be aborted. Such an event could, for various reasons, probably occur only in the early stages of pregnancy and must undoubtedly be relatively rare. Nevertheless, I am convinced that careful examination of all material aborted will multiply the evidence. From these things it would also seem possible that rarely pregnancy might supervene and be terminated without having attracted any attention whatsoever.

The phenomenon of intrauterine lysis is interesting also from a chemical standpoint. What the anatomist would like to know is not merely in what respects the composition of the intra-amniotic and peri-amniotic fluids has been changed, but just what the enzymes are that have caused a complete lysis of the embryo, where these first arise and act, and how and why they become active. These and many other questions the chemist only can answer. For this answer fresh material is indispensable, but this the neighboring practitioners or a closely associated clinic can supply. That the lysis of these early embryos, and undoubtedly also of the chorionic vesicles, is not due primarily or even very materially to phagocytic activity is very evident, even upon cursory examination. In the presence of the intact chorionic and amnionic vesicles in some specimens, such a process is wholly excluded. Besides, one never sees any evidence of phagocytosis of the preserved fetal by the maternal tissue in human conceptuses. Evidences of the contrary process, however, are not wanting.

That the embryo or fetus usually is the first member of the conceptus to disappear has already been implied by stating that in 32 per cent of the abortuses grouped as pathological in the Carnegie Collection the embryo is missing. Although the absence of the embryo does not necessarily mean, in every case, that it underwent complete autolysis, this no doubt is true in by far the great majority of these cases. The fact that the embryo disappears first may be due to a lower

resistance on its part than that possessed by either amnion or chorion, or to a preponderance of enzymes within it. Autolysis of the body of the embryo before that of the membranes may also be due to the fact that the adnexa, especially the chorion, or at least parts of it, often preserve vitality long after the death of the embryo because of its direct relation to the uterus. Nevertheless, it often is surprising how long the form of a small retained fetus, or even of the amnion, has apparently been preserved, although it should be remembered that in some cases the preservation of external form gives little indication of the true state of the constituent tissues. If the advent of proteolytic fat- and carbohydrate-splitting enzymes in fetal tissues is gradual, the surprisingly long time during which some of the small embryos are preserved may be due to a considerable degree to this fact. Jones and Austrian (1907) found, for example, that the liver of a young pig embryo contains no nuclein enzymes, but that these increase as fetal development proceeds. The latter finding seems to be confirmed also by data given by Mendel and Leavenworth (1908), although these investigators found enzymes present at all ages. Schlesinger (1903), who was, I believe, the first to establish the occurrence of autolysis in retained human fetuses, also found that the rate of autolysis varied with age and other conditions.

Since the chorionic villi do not undergo autolysis first, the conclusion that heterolysis is not an important factor in lysis of the conceptus also seems justified. If enzymes of decidual origin played any large part in the process of lysis of the conceptus, one might, I presume, expect to find instances in which at least portions of the chorionic vesicle underwent lysis, although the embryo itself remained quite unaffected. This, however, never seems to be the case, and the same thing holds for the placenta and the chorionic vesicle and also for the decidua. That heterolysis probably plays only a very subsidiary rôle is indicated also by the fact that autolysis takes place in tubal implantations as well, and still more convincingly by its occurrence in ovarian implantations, as illustrated especially by the case of Holland (1911) and by other cases referred to by Meyer and Wynne (1919), in which the escape of portions of the conceptus from the ovarian implantation cavity could be wholly excluded. One reason for prolonged preservation of the decidua no doubt lies in the fact that it as a whole, or at least in large part, retains vitality because it remains quite undisturbed in its vascular relations.

CHAPTER XIII.

POST-MORTEM INTRAUTERINE CHANGES.

In discussing post-mortem changes, it is necessary to distinguish between the death of and changes in the cyema and the vesicles, that is, between intracyemic and extracyemic changes. Such a distinction would be unnecessary if the death of the one were impossible without that of the other. It has been assumed in the past not only that the latter is not the case, but that the fetal vesicles may survive the cyema for some time. Under such circumstances, then, considerable post-mortem changes might take place within the cyema and perhaps within the amnion also, while the chorion might remain largely, even if not wholly, unaffected. Since such an assumption involves the implication that the fetal circulation is not indispensable for the life of the chorionic vesicle even after the usual time of the advent of the former, an assumption of independent survival of the entire vesicle would seem somewhat venturesome, although it is highly probable that certain constituents of the chorion nevertheless might survive death of the cyema.

That the amnion, which usually is non-vascular, and which fuses with the chorion quite early in development, may survive death of the embryo is entirely possible, not only because it is nutritionally more independent, especially in its early stages, but also because survival of the chorion would condition survival of the amnion after the latter fuses with the former. The belief, not only in the survival, but also in the growth of the fetal vesicles after death of the cyema, is relatively old and rests largely upon the disproportion in size between the embryo and the chorionic vesicles so frequently seen, and upon the existence of a similar disproportion between the placenta and the fetus in cases of retained abortions. According to Panum, von Baer, describing a rather firm, brownish-red, bean-shaped lump, unlike an embryo of either bird or mammal, which was surrounded by an envelope and in relation to a vascular area, was said to have regarded it as a liver which had continued to grow after the death of the embryo. It seems that von Baer came to this conclusion, largely because of the color of the gross specimen and because he thought it possible that in poorly regulated incubators the "vegetative" portions of the body of the embryo very often continue to live, although the "animal" parts die. It must be added, however, that Panum (1860), from whose monograph this statement is taken, added that he thought von Baer only regarded these questions as propositions for investigation and proof, and not as established facts. However, Giacomini (1893) adduced experimental evidence in favor of such a belief, for he stated that the membranes also continued to grow in rabbits in which the cyema had been killed experimentally. He further stated that, although the embryo may be inhibited in growth or even be destroyed completely, the chorion and amnion not only may show no degenerative change, but actually may continue to grow. His (1891) spoke of evidence of an interrupted growth, and Giacomini (1894) also believed in the occurrence of an inhibition of growth before the death of the embryo occurred. According to Waldstein (1913),

von Winckel also spoke of a slowing in development before the death of the embryo occurred. Taussig (1903) stated that both Breus and Gottschalk concluded that retained "ova" grow, and Graefe (1896) called attention to the opinion of Veit that "ova" may continue to grow after the death of the embryo, but added that the existence of bare areas and the bunching of villi in some of the retained specimens argue against the conception of His that "ova" with these characteristics have continued to grow for some time.

No one seems to have suggested that the *entire* embryo may continue to grow after cessation of the fetal circulation, but Wallenstein (1897), who made a careful microscopic examination of some early abortuses, not only believed that cellular proliferation can occur in the embryo after its death, but that either the lateral or the dorsal or ventral halves may continue to grow independently of each other after the death of the cyema. Wallenstein believed, even, that the cyema can become diseased after its death, and concluded that intravascular cells not only outlive the rest of the cyema, but that they proliferate and invade the dead or dying tissues of the latter.

Schaeffer (1898) also stated that the chorionic and amniotic vesicles continue to grow, provided death of the embryo occurs before the fourth month, and Mall (1900, 1903) also spoke in favor of growth in them after death of the embryo. Engel (1900) believed that the caudal half of the body of an embryo may continue to grow after the cephalic half has died. However, Engel's conclusion regarding the proliferation of cells was based largely upon the observation that the volume of the disintegrating central nervous system was too great to be accounted for merely by the cells which normally compose it.

Giacomini (1894) believed that even the isolated amnion may continue to grow and that the chorion may continue to live after all else has died. That the individual portions of very young conceptuses undoubtedly have considerable power of *independent*, though not necessarily *post-mortem*, growth is shown by such specimens as No. 1843 (fig. 7, plate 1, Chap. IV), a conceptus in which the chorion and yolk-sac have reached a considerable size, although the embryo and amnion both are absent, except perhaps in the merest rudiments, as shown in figure 172 (plate 16, Chap. XI). However, it is highly probable that this power of independent growth is far greater before than after the time when the fetal circulation has become established in the cyema and chorion. Soon after this time cessation of the embryonic circulation necessarily would seem to interfere effectively with growth of the cyema and increasingly with the nutrition of the chorion and more indirectly also with that of the amnion. However, before the fetal circulation has been established, it is highly probable that even the embryonic disk may be much more resistant to inhospitable surroundings, and one could pronounce these very young conceptuses dead only after correlated cellular proliferation had ceased entirely.

Although the chorions of older specimens may die a more gradual death than the cyema, one scarcely would expect any villi to be formed anew after the death of the latter. The syncytium and trophoblast, however, both might con-

tinue to grow for some time and apparently often do so, for, as is well illustrated by many things, they are much more independent, not only of the fetal circulation, but also of the conceptus, than the other components. Strahl and Henneberg (1902) also found the ectodermic elements of the placenta in guinea-pigs more resistant than the mesodermic. Some investigators (His, for example) expressed the opinion that, although survival of tissues, within both the cyema and the vesicles, is possible after death of the embryo, one really can not regard such tissues as truly living, although cell proliferation nevertheless may be present. Giacomini and His both spoke of cell proliferation, and Mall later used the term *dissociation* as including both migration and proliferation of cells. It may be recalled in this connection that Müller (1847) also spoke of proliferation of the epithelium of the villi as being common in aborted ova, and that Giacomini (1888) stated that the cells of the central nervous system tend to become uniform and also seem to multiply because they no longer can be accommodated in the space provided for them. His, Giacomini, Grawitz, Mall, and Engel all believed that at least a proliferation of "round cells" occurs and that they are wandering or migratory in nature. Marchand (1895) also spoke of an infiltration of the conceptus by leucocytes, but did not believe, as did Grawitz, that they were autochthonous in origin. Although Daels (1908[b]) stated that maternal leucocytes can penetrate normal syncytium in order to reach a necrotic area beyond, Nattan-Larrier and Brindeau (1905[a], 1908) concluded that leucocytes never invade the stroma of the villi as long as the epithelium is intact. The conclusion of the latter investigators is wholly in accord with my own observations, and it would seem extremely difficult to determine whether leucocytes seen somewhere in the stroma of the villi or of the chorionic membrane really are fetal or maternal in origin. According to Windle (1893), the so-called *round cells* arise in the stroma of the villi, but Wallenstein believed that such an infiltration can occur only into dead or dying embryonic tissue. Berlin (1907) also spoke of the presence of extensive leucocytic infiltration in one of her cases, and Engel (1900) concluded that in one of the cases described by him the liver was completely destroyed by proliferating round cells which he apparently assumed to be phagocytic.

Microscopic evidence for the survival and growth of the cyema or certain parts thereof does not rest solely upon the transformation of various tissues and organs into "round cells," however. Giacomini and Wallenstein both stated that mitotic figures were observed by Chiarugi, but the latter seems to stand alone in regard to this observation. But, even if confirmed, the occurrence of mitoses locally would not establish the occurrence of a correlated proliferation which could rightly be designated as growth. Nor could the well-known independent survival or even growth of still-implanted villi or, more properly speaking, of the syncytium and stroma, in cases of hydatiform degeneration and chorio-epitheliomata, be regarded as establishing the occurrence of normal growth in the vesicles or the cyemata of conceptuses.

Post-mortem obliteration of the vessels would seem to fall more in this category, but the post-mortem occurrence of this phenomenon even is as yet unproved.

Besides, upon *a priori* grounds alone it would seem that the adverse conditions which cause the death of the embryo, and eventually also that of the entire conceptus, alone would make conditions of post-mortem growth rather unfavorable even for the most resistant of the dependent tissues. Other factors also would tend to make these conditions unfavorable for the occurrence of post-mortem proliferation, even for such growth as we have in recent years come to know as growth *in vitro*. I have rarely found appearances identical with those seen in certain artificial cultures, as figure 175 so well illustrates; but these appearances involved connective tissue only and always occurred in the interior of the chorionic membrane, or between the latter and the amnion when the two were separated somewhat. Nevertheless, the rareness of these appearances in itself throws much doubt on the occurrence of genuine growth after death, and in view of the fact that I have been unable to find any thickening of the chorionic and amniotic membranes at these places, I am more inclined to regard such appearances as these as due to a migration rather than to an actual proliferation of cells. Nor have I seen much evidence in favor of a post-mortem migration other than that of cells intravascular in origin. What has been termed lymphoid infiltration or transformation seems to be due rather to a degeneration of cells *in loco*, the degenerate forms simulating round cells and thus giving rise to misinterpretations. Indeed, the idea that a complete transformation of the entire body of the embryo into round cells can occur without the phagocytosis of the cells composing the various organs seems to imply that this so-called lymphoid infiltration really is a transformation *in loco*. That an apparent temporary increase in volume of the central nervous system has been noted is not surprising. But this does not postulate an actual increase in the number of cells any more than the old observation of maintenance in weight and volume of the central nervous system under conditions of inanition implied that the nerve-cells remained unchanged. That the latter is not the case was shown by Meyer (1917[b]).

It may be recalled that Merttens (1894) also reported finding obliteration of the blood-vessels due to proliferation of the intima. However, since Merttens found these obliterative vascular changes only in the chorion læve, his conclusion that these changes undoubtedly were post-mortem is open to very serious doubt. This doubt is greatly increased by the facts that Merttens suspected the existence of lues in a case in which these obliterative changes were present and that almost complete obliteration of the vessels was present in a specimen which was regarded as having been retained only 11 days. Since calcium deposits were present in this specimen, the latter estimate is open to grave doubt, however.

Berlin (1907), although aware of the fact that an *ante-mortem* obliterative endarteritis had been shown to occur in conceptuses, nevertheless concluded that the degree of obliteration found in the placental vessels roughly parallels the duration of the retention. She added that the processes found by her recall those observed in portions of a blood-vessel isolated by ligature and represented appearances within the placental vessels almost identical with those represented in figure 175. In spite of the similarity of these figures, it would seem unwarranted, however, to assume that phenomena identical with those observed in the chorionic

vesicles could lead to obliteration of vessels. In the chorionic vesicle the picture presented is that of migration rather than that of proliferation, and it is indeed a long step from these things to complete obliteration of blood-vessels, especially when it is recalled that the latter involves the growth of new capillaries, as was reported by Merttens and as is the case in the normal postnatal obliteration of the umbilical vessels. Schickele (1907) also observed obliteration by endothelial proliferation in the various vessels, but insisted that they do not occur with the frequency reported by Merttens. Schickele further stated that obliteration occurs rapidly and that it is not necessarily post-mortem.

Waldstein, who made a very careful histologic examination of some abortuses, stated that, although the regressive changes had not yet been sufficiently studied, he did not believe in a continued growth of the embryo, but merely in a further differentiation of some of the constituent tissues, and also in a round-cell infiltration. Waldstein claimed that in some specimens examined by him the striations in the central musculature were maturer than they should have been, and hence concluded that post-mortem differentiation had taken place in them. He believed that the round cells had an intravascular origin. Boerma (1912), who described a young macerated embryo, also stated that the amniotic cavity contained cell-masses from the embryo which he believed had survived the parent mass.

His (1891), Giacomini (1894), Schaeffer (1898), Mall, and the writer occasionally found local thickenings of and adhesions between certain epidermal surfaces. These adhesions and thickenings, referred to in Chapter IV, group 7, were present in the lower extremities of the fetus shown in figures 64 and 65 (plate 5, Chap. IV). In this case, as in those of Lomer and Schaeffer, the extremities are glued together by epidermis. The appearance of the lower extremities at this point also suggests that there has been an accumulation of sloughed epidermis in the region of contact. To what extent this gluing is due to fusion of dying tissues and cells, rather than to growth, it is difficult to say. In other cases, as stated by His (1891), the extremities may be glued to the trunk, or the head to the chest, as observed also by Mall and as illustrated in figure 176. The mandibular region may adhere to the chest and the lips coalesce so completely that the epidermis is absolutely continuous from the chest to the chin and also across the lips, as represented in section in figure 180.

Giacomini (1889) further described invaginations of the epidermis into the mesoderm on the dorsum, lateral to the spine in an atrophic embryo 5 mm. long. Although not regularly symmetrical, these epidermal invaginations nevertheless were said to have a metameric arrangement, there being 6 on the right and 10 on the left side. Giacomini stated that these epidermal growths reminded him of the lateral-line organs of elasmobranchs, and added that he saw them at the caudal extremity of another specimen. Epidermal accumulations in various places were noticed also by Mall in long-retained cyemata, but nothing justifying Giacomini's interpretation was encountered either by Mall or myself. The accumulations noticed by us were small, irregular, and rather poorly preserved mounds of epidermis, as illustrated in figures 76 and 77.

That the placenta may continue to grow during retention after death of the cyema was once firmly believed. This idea had its origin in the disproportion frequently present between the size of the placenta and that of the cyema. At present, belief in the growth of the placenta after death of the cyema seems to have been abandoned, however. It was in connection with the placental changes, and especially with changes in the vessels of the villi, that the question of the survival and growth of cyemic tissues attracted attention. Among the placental changes which suggested the presence of growth was the proliferation of the ectoderm of the villi, indicated in so many specimens. It is interesting that Schickele (1907) regarded this apparent post-mortem proliferation as a direct cause of cyemic death. Schickele believed that proliferation of the ectoderm of the villi results in encroachment upon the placental circulation and ultimately in death of the cyema. It seems strange, however, that Schickele (1905) stated that proliferation of the syncytium usually does not occur, except in cases of long-standing retention.. Litthauer (1887) also had believed in the continued growth of the placenta as a result of retention, and had concluded that the death of the cyema was attributable to interference with its nutritive supply through proliferation of the endometrium.

Taussig (1903) stated that the vessels in the villi of retained "ova" may be preserved for a long time, as reported also by Davidson, and Berlin believed that obliteration of the villous vessels is a purely post-mortem phenomenon. As previously stated, Berlin affirmed the belief of Merttens (1894) that the degree of vascular obliteration somewhat parallels the duration of the retention. If this obliteration actually occurs post-mortem, this conclusion of Merttens may be correct, for it is well known that the degree of obliteration of the umbilical vessels is dependent upon the duration since birth. However, the occurrence of ante-mortem vascular changes established by numerous investigators can not be excluded. Nor is it necessarily an easy matter to differentiate the ante-mortem from the post-mortem proliferative vascular changes. If the villi can continue to grow after death of the fetus the rate of obliteration will be very much affected, no doubt, by this fact. It is interesting that Graefe, although granting the possibility of independent growth of the villi in retained uterine conceptuses, stated that he saw hypertrophy of the villi only once. Schaeffer also believed that the villi are preserved for a long time after death of the cyema, and Mall (1915) stated that in cases of tubal pregnancy the villi may continue to grow independently after death of the embryo.

Crosti (1896) stated that if the ovum is not aborted immediately after death of the embryo the villous capillaries gradually disappear. Crosti also believed that the villi are preserved longer than the rest of the conceptus, and that even the "appendici durate" may become hydropic. It must be borne in mind, however, that the disappearance of the villous capillaries in consequence of maceration is one thing, and the obliteration of the vascular lumen by proliferative processes is quite another. Obliteration such as that represented in figure 177 illustrates the former process, which is a purely post-mortem phenomenon as far as the particular villus is concerned, while that represented by No. 317, shown in figure 178,

illustrates proliferative obliteration of the vascular lumen which undoubtedly was ante-mortem. However, it must be recalled that not all of a chorionic vesicle necessarily dies at the same time, and that implanted villi, or those in very young conceptuses which are not yet dependent upon the fetal circulation, may well continue to live and perhaps even continue to grow for some time. But such villi hardly can justly be designated as dead, and since death of the cyema does not necessarily result in simultaneous death of the entire conceptus, this distinction is not an unimportant one.

There seems to be no agreement among writers, however, as to which of the tissues of the cyema are most resistant to post-mortem changes. Litthauer (1887) found the muscles of certain fetuses well preserved, although the cartilages had lost all their normal structure. Virchow, Wyder, and Baumgarten, according to Litthauer, also found that the muscles are among the most resistant of structures. Giacomini (1888) thought the central nervous system very resistant, but Engel came to a contrary conclusion. Phisalix (1890) thought the epithelium the most easily affected by pathological processes, and while there is great difference of opinion, all investigators seem to be agreed that the cyema is affected before the vesicles.

Von Winckel (1904) spoke of three grades of maceration in the cyema, the first being that of bleb formation, the second that in which the epidermis is broken and shed in fragments, thus exposing the chorion, and the third stage that in which the joint capsules and ligaments are loosened, the joints consequently relaxed, and the extremities contorted. Von Winckel also set an approximate time-limit for the occurrence of these stages, the last stage being reached in three weeks. Nevertheless, von Winckel concluded that the degree of maceration could not be used as a criterion for the determination of the duration of intrauterine retention. Müller also was impressed by the post-mortem changes, and rightly stated that many embryos are deformed beyond recognition by maceration, bleb formation, and mummification.

Although it is incorrect to regard the changes which many conceptuses undergo after death and before abortion as maceration in the customary sense, no other word seems to be available. These changes undoubtedly are accompanied by softening, collapse, deformation, and no doubt also by autolysis. Whether imbibition and swelling are invariably present I do not know, but if they occur they usually are slight and their effects minor in character. Most of the changes enumerated here may occur under sterile conditions, and since maceration, even in this restricted sense, must effect changes, not only in the chemical composition, but also in the microscopic structure of cells, long before changes in external form of embryo or chorionic vesicle become apparent, a discussion of maceration changes really should begin with these. But the earliest modifications in microscopic structure remain very largely, and those in chemical composition almost wholly, unknown to us at present.

Although it undoubtedly is true, as stated by Müller (1847), that very young embryos may retain their form surprisingly long after death if retained in sterile

amniotic fluid, it does not therefore follow that they really remain structurally unchanged. However, I can not confirm the opinion of Herzog (1898) that chorionic villi degenerate with astonishing rapidity after the death of the embryo, which Herzog claimed was true especially in young placentæ. According to Herzog, only the most intimate acquaintance enables one to recognize the villi after the embryo has been dead two or three weeks. Since the villi are usually the last thing to disappear and may survive the death of the embryo by months, even in the case of early conceptuses, it is difficult to understand what may have been responsible for Herzog's opinion. Leopold (1882) stated that it has been shown that a bare fetus in the peritoneal cavity will macerate and become disarticulated, but that a fetus surrounded by the intact membranes will become dry and leathery. Just what the basis for this statement is I do not know, but it would seem that comparatively prompt disarticulation of any except perhaps very young cyemata must imply the presence of putrefactive conditions, for the length of time which dead tissues can survive depends very largely upon the advent of putrefaction.

Microscopic changes no doubt appear quite promptly after death in all conceptuses, but, strange as it may seem, the most pronounced internal changes may sometimes fail to manifest themselves externally. In one instance (No. 962), for example, Mall had noted that the shape of the embryo had been preserved so perfectly that the specimen seemed normal in form. Yet the slightest jar on the containing vessel resulted in its complete disintegration. Apparently this specimen was somewhat farther advanced than embryo No. 2197 (figure 29, plate 4, Chap. IV). The same thing may be true of the villi, the shape of which may be preserved perfectly, although structurally they may have become mere gossamers, as illustrated by the villi of No. 606, shown in figure 11 (plate 1, Chap. IV).

Since very few abortuses are expelled promptly, practically all are macerated to a greater or lesser degree. This applies to specimens classed as normal, as well as to those classed as pathologic. Nor can the mere fact that a specimen was obtained *in utero* at operation assure one that it is not macerated. No. 1224, for example, although obtained at operation, is a very greatly macerated, empty chorionic vesicle which was isolated completely in the uterine cavity. In another specimen (No. 1767), also obtained at hysterectomy, an abscess is found within the implantation site. No. 782, a third specimen of the same kind, and also other hysterectomy specimens, as previously stated, contain young hydatiform vesicles. Although the uterus and conceptus of No. 872 were placed in 10 per cent formalin after operation and kept in a thermostat for two days, the villi nevertheless are markedly macerated. They are also almost wholly non-vascular, remnants of the vessels being present in some of the villi only. The amnion is absent, the fibrous chorion also shows maceration changes, and the decidua is decidedly infiltrated. Hence it is important to remember that unless one is dealing with a normal implantation and a wholly normal uterus, the fact that the specimen was obtained at operation and preserved immediately with the best of care is not an absolute guarantee against the presence of early maceration changes. This is illustrated especially well by tubal specimens, which so frequently are embedded or isolated

in blood-clot, as was the case with Nos. 1938 and 2035, shown in figures 179 and 181. The embryo and yolk-sac of the former are almost completely disintegrated, for nothing but scarcely recognizable remnants lie isolated in the chorionic cavity, which is moderately filled with an amorphous coagulum. The stroma of the chorionic membrane is edematous and degenerate, but contains some well-preserved vessels, a few of which contain some blood-cells. The same thing is true of the stroma and of the vessels of the villi, which also are in process of dissolution. A moderate amount of trophoblast is present, but there is very little syncytium. The epithelium of some of the villi has undergone hyaline degeneration. The blood-cells in the large clot in which this chorionic vesicle, measuring 8 by 5 mm. in section, was embedded, are preserved fairly well, especially near the vesicle. Nevertheless, the whole conceptus is very apparently in a state of rapid disintegration and lysis. The tube-wall is very thin and the mucosa congested, hemorrhagic, and atrophic.

It is not difficult, as a rule, to identify maceration changes in the villi, for the appearances are rather characteristic, as figures 182 and 183 illustrate. But when other changes, such as the obliterative process shown in figure 184, are present at the same time, it is sometimes impossible to decide whether such changes as these were ante-mortem or post-mortem. In this case the lumina of the capillaries are plugged by what reminded Mall of "epithelial pearls," though he recognized that the cells were endothelial in origin. That such an obstruction of the lumina of blood-vessels can occur through a shedding, swelling, and clumping of the endothelial cells there can be little doubt, although proliferation of the endothelium can perhaps not be wholly excluded.

The earliest noticeable external post-mortem change in the color of the embryo is due to the occurrence of a greater opacity. The tissues lose their normal translucence, so that they look whiter and denser, and the surface also becomes less glistening. Later they also become yellowish and occasionally hemorrhagic, and the cutaneous surface becomes less smooth. Coincident with these changes, softening and some swelling also take place, as illustrated by No. 2146, shown in figure 187, and bleb formation occurs, especially on the abdominal extremity of the umbilical cord and elsewhere, as previously shown in figures 54, 70, 71, and 72 (plate 5, Chap. IV).

In consequence of the softening of the tissues, the upper extremities, if sufficiently developed, tend to gradually droop, as shown in figures 58 and 66 (plate 5, Chap. IV). Later, the caudal extremities also sag, and both pairs may gradually develop unusual curvatures. Changes occur also in the face, for the ocular margins become irregular and everted, or, if the lids have fused, they may prematurely open. But all these are relatively slight gross changes and merely herald the more profound modifications in form if retention continues under favorable conditions. What is now needed is a correlation between these early changes in external form and appearance and the histologic and cytologic changes. Although the advent of changes in color is quite prompt, it can safely be assumed from other evidence

that the incipient structural changes are microscopic and can be detected long before changes in external form and color occur.

Since the chorionic vesicle almost invariably is surrounded by more or less blood and decidua in cases of abortion, it is naturally difficult to detect early gross post-mortem changes in it by inspection alone. However, the earliest noticeable external change in the villi is a decrease in translucency and a dulling of their surface. The villi of very young specimens also seem to become somewhat larger in caliber and look stiffer and slightly bulbous in places. They also frequently are somewhat matted, as was the case in No. 1878, a very young specimen, a portion of which is shown in figure 188, the chorionic vesicle of which measured but 10 by 12 mm. However, in No. 1843, which is a still younger specimen, measuring 5 by 6.5 mm. (figure 7, plate 1, Chap. IV) and shows more marked maceration changes upon microscopic examination, these changes, nevertheless, were not evident to the unaided eye, for the vesicle was unusually translucent. The chorionic and villous epithelium has sloughed over most of this vesicle and the remaining tissues stain but weakly. The cell-boundaries also are rather indistinct and the yolk-sac shows marked changes.

The first noticeable change in histologic structure seen in routine preparations seems to be a blurring of the structural detail in the tissues and a haziness in appearance of the cytoplasm. This early state is followed, if not preceded, by autolytic changes. As has so frequently been emphasized, evidences of disintegration, noticeable particularly in the central nervous system, supervene very early and the brain and cord become swollen and the folds become effaced, as shown in figure 185. These changes are accompanied and may be followed by complete dissociation of the constituent elements, with some shifting if not migration of cells. All the constitutent cells become rounded, the cytoplasm may disappear entirely, and the nuclei become more pycnotic. When this stage is reached the structure of the brain and cord is quite uniform and cells of various origins may all be quite properly designated as round cells, for all look alike, the changed nuclei only remaining. The entire central nervous system, for example, may be composed of these densely packed round cells and be characterized quite properly upon superficial appearances alone as lymphoid, as suggested by Giacomini. Finally, however, the nuclei also disintegrate and form a fine, granular material, spoken of by Mall as *nuclear dust.* Morever, not only the nervous system, but all the organs of small fetuses, may be so transformed, as illustrated in figure 186.

These things, however, do not necessarily or materially change the form of the cyema, and the effects produced by retention *in utero* after death will depend not so much upon the exact duration of the retention as upon the age of the cyema. A few weeks may suffice not only to change greatly the external form or the internal structure of young cyemata, but to effect complete absorption. In case of an approximately mature fetus, on the other hand, such a short period of retention after death might modify the form inappreciably and result merely in maceration of the epidermis.

One might expect that maceration, even under sterile conditions, especially in case of young specimens, would result in general distention, but this does not always seem to be the case. Edematous areas do, indeed, frequently form locally, as previously illustrated and as generally observed; but swelling due to imbibition, such as occurs when fresh young specimens are placed in formaldehyde, was observed only in a minor degree, as illustrated by No. 2146, shown in figure 187. Sometimes this swelling is local, as represented by the cephalic region of No. 1750. A subsequent reduction in size is much more common and may be due to absorption of salts from the amniotic fluid, with resultant concentration of it and of extraction of tissue fluid from the cyema itself. In very young specimens, such as No. 786 (fig. 189), an embryo 4 mm. long, the first noticeable shrinkage change in form seems to occur in the cephalic extremity, the frontal prominence of which recedes and the outline of the vertex of which becomes more and more rounded and also is reduced in size.

In consequence of these changes, the cephalic extremity becomes relatively too small, as is well illustrated by comparing this specimen with No. 1380, shown in figure 190, a cyema of the same development but 5.5 mm. long and in an excellent condition of preservation. This reduction in size of the cephalic region would, to be sure, result in a reduction in length were the measurement taken from tip to tip, and were it not for the fact that during this process the cephalic extremity, if indeed not the entire embryo, usually unbends and in becoming straighter compensates for, or even more than compensates for, the loss in length due to reduction in size of the cephalic extremity. This does not always occur, however, as Nos. 1299 and 2216 so well illustrate (see figs. 191 and 192). These changes make the trunk look disproportionately large and the features somewhat stunted. Previous to these changes, or coincident with them, the tissues lose their elasticity and also become softer, and the surface of the specimen becomes duller, more opaque, and finally more yellowish. Other changes noticeable in the specimen just referred to are the loss in detail of the surface relief, evident particularly in the branchial region, and in the effacement of the myotomes. In other instances, such as No. 2035 (a portion of a tubal specimen), a marked change is very evident in the caudal extremity, which has become shorter, blunter, and straighter, although upon close inspection other changes also are noticeable. Because of these things the actual soon may become less than the original length and only roughly indicate the true age of the cyema.

The change in the cephalic extremity, the decrease in the natural curve which accompanies erection of the specimen, and the loss in detail just spoken of are illustrated still better by No. 187*a*, which is a somewhat older embryo, 7 mm. in length. Young embryos which illustrate the early changes in form are Nos. 208 and 1296, shown in figures 193 and 194—embryos which are respectively 7 and 4 mm. long in their present state.

A somewhat similar, though slighter, effect of maceration upon relatively young specimens is illustrated by Nos. 1697 and 1477, shown in figures 195 and 196, cyemata 15 and 18.5 mm. long respectively. In the first of these two speci-

mens the gaping mouth and blunted and rounded upper extremities are especially noticeable. That sagging of the upper extremities does not always occur, even in the presence of a more marked degree of maceration than present in the above specimen, is illustrated by No. 705, shown in figure 197, a somewhat older cyema with more marked maceration, and to a less degree also by No. 1477, both of which also show a rounding and shortening of the extremities.

A still more striking series of transformations is illustrated by the somewhat older specimens, Nos. 2244, 1891, 1655, 1260, 1333, 1926, and 1379, shown in figures 198 to 204 inclusive. Inspection of this series will show that the transition from one to the succeeding specimen is not very marked, although the difference in form between the first and last specimens is very great indeed, and could have been made more striking by accompanying each figure by a normal one of the same (or approximately the same) stage of development.

Such oddly shaped bodies as those shown in figures 203 and 204 scarcely can be identified positively as cyemic remnants by the unaided eye, and even under some magnification give little indication of their internal structure. The same thing is true, though to a lesser degree, of Nos. 885 and 1333, shown in figure 202, and also in figure 22 (plate 3, Chap. IV). In these specimens the limbs are still present in such an abbreviated form that the latter suggests amelia. Hence the question at once arises whether these specimens show mere post-mortem deformations or true developmental anomalies. This question is presented still more forcibly by smaller, younger specimens such as Nos. 1226 and 2361, shown in figures 205 and 206. These cyemata may be truly anomalous, but they also may be macerated young normal embryos, and in case of young specimens the question can be decided only by a microscopic study of the sections, as was illustrated while considering the nodular group in Chapter IV. It must be borne in mind, however, that minor external deformities may be obliterated completely by post-mortem deformations, and that in such cases no positive conclusion can then be reached.

An unbending or erection of the cyema does not always occur, as is illustrated by No. 208 (fig. 191), which also is a 7-mm. specimen. Although this cyema is markedly macerated, there has been but little change in the total outline, save as a result of pitting, increase in flexure, and shrinkage. Whether or not failure to unbend on the part of this specimen is due to an early coagulation of the amniotic fluid, and the tissues of the embryo itself, I do not know, but that this might be an important factor does not seem improbable. Similarly, early coagulation of the cyema itself might postpone other changes in form, similar to those shown in No. 589 (fig. 207), a cyema of 10 mm. This cyema very apparently was not surrounded by a coagulum. In such soft specimens the whole surface may be wrinkled, the hand plates may look excavated, and the head may be sunken deeply upon the chest. Since this particular specimen remained extremely soft and pliable, the extremities also were rotated somewhat and the body became rather collapsed, as if compressed. Just why some cyemata remain relatively stiff, firm, and opaque, and others become extremely soft, swollen, and more

translucent, remains unknown to me, but it is not impossible that the reaction of the amniotic fluid is the controlling factor.

In slightly older specimens the first marked changes in external form resulting from maceration sometimes are seen near the abdominal attachment of the umbilical cord, as illustrated in No 1523 (fig. 70, plate 5, Chap. IV), an embryo of 19 mm. Several blebs are sometimes located on opposite sides of the cord or surround it, as in the case of No. 1475, shown in figure 54 (plate 5, Chap IV). It is interesting that large blebs not infrequently are present in this location, even if the body of the cyema has suffered relatively little change. The size of these blebs, to be sure, may be considerable and, instead of local edema, the entire epidermis may be lifted and the entire cord may be swollen, but such a condition usually arises only later, during longer periods of retention. Sometimes the whole nuchal region is edematous, forming a marked prominence far above that normally present, or is occupied by a single large bleb. For some reason these blebs are common, especially on the head, the dorsum, and on the umbilical cord.

Sometimes a prominence on the dorsum is due to the swollen, macerated, and completely disintegrated central nervous system, which may form a marked ridge, as illustrated by No. 521*f*, shown in figure 208, a specimen in which lumbar spina bifida was present. Not infrequently, however, a marked prominence in the upper dorsal region is due to collapse of the brain and drooping of the head, as illustrated in No. 175, a cyema of 13 mm. This collapse of the central nervous system occurs most frequently in the brain of older specimens and is not infrequently followed by collapse of the calvarium in younger specimens. It may result in marked cutaneous depressions or sulci, as illustrated in No. 1250, a specimen 13 mm. in length (fig. 209). Rarely, these sulci or ridges may extend entirely down the dorsum of young specimens.

It is decidedly significant that some intrauterine changes in external form can be simulated by post-mortem extrauterine changes. This is splendidly illustrated by figures 210 and 211, which are photographs of a fresh and well-preserved and a poorly preserved cat embryo respectively. Similar changes have also been produced experimentally by incubation in sterile solutions, and are further illustrated by No. 1358*f*, shown in figures 212 and 213. The former shows the appearance of the somewhat macerated specimen before staining and preservation in alcohol, which very materially shrunk the tissues, as shown in the latter. Were the history of this case unknown, one would have been justified in calling it a rather decidedly soft, macerated specimen. Nor do two specimens of identical age, which existed under identical conditions, necessarily present exactly the same appearance. This is well illustrated by Nos. 2258*a* and 2258*b*, single-ovum twins, shown in figure 214.

The relatively early loss in detail in the normal relief of the cyema is illustrated extremely well by No. 2014 (fig. 215), an embryo 17 mm. long. The normal relief of this specimen is replaced by a molding due to maceration. These changes, which are noticeable over the entire body, show particularly in the eyes and ears and in the gaping mouth. The effacement of the normal features in young speci-

mens is sometimes very complete, but this is true also of older ones, so that the external form may suggest the amorphous group. An intermediate form between the latter and No. 2014 is represented by No. 1495*d* (fig. 216), a cyema 12.3 mm. long, but of approximately the same stage of development as the other two. A still more advanced change of this type is illustrated by No. 921, shown in figure 39 (plate 4, Chap. IV). The difference in length between some of these specimens of corresponding development is not infrequently due mainly to shrinkage accompanying maceration and retention. No. 1495*d* is interesting also because the placental site was marked internally by numerous subchorial hematomata (fig. 217). I do not wish to enter into a discussion of these so-called "Breus hematomatous moles" of which so much seems to have been made, but all the specimens which have come to my attention had been retained for a long time. It would seem that when, for some reason, the placental margins and also certain intermediate placental areas are more firmly adherent than the rest, the looser portions may be detached and forced inward by hemorrhage, thus producing a series of hummocks on the internal surface of the placenta. If the chorion and amnion over these areas rupture, blood may enter the amniotic fluid, and just in proportion as the latter is reduced in quantity the process of eversion of the placental site must be facilitated. It is, of course, entirely possible that a mixture of blood with the amniotic fluid, so common in these specimens, may help to preserve the cyema, but the abortuses with subchorial hematomata which I have seen did not give me the impression that their preservation was any better than that of the non-hematomatous type.

Blunting and rounding of the extremities of the cyema, with consequent shortening and loss of detail, are present in still more decided form than previously illustrated. Beginning sagging of the extremities is shown well in No. 1358, which is 18.3 mm. long, and in still older specimens, such as No. 1710 (fig. 66, plate 5, Chap. IV). The abnormal curvatures, and especially the blunting of the extremities, are exemplified still better, and the drooping mandible, gaping mouth, and locally edematous cord are also well shown in No. 797, a fetus 35 mm. long, represented in figure 218. Changes in curvature of the extremities are splendidly illustrated in No. 1860 (fig. 219), and become more pronounced the older the specimen, up to the period when skeletal development makes them extremely difficult or even impossible.

The changes in the extremities do not stop, however, with the production of abnormal curvatures, for not infrequently the hands and feet undergo an outward clubbing, shown in pronounced form in No. 1958 (fig. 220), a decidedly macerated specimen 41.5 mm. long. Separate views of the extremities of this specimen are given in figures 221 and 222. Earlier stages in this process are illustrated by No. 1751 (fig. 223), with separate views of the extremities in figure 69 (plate 5, Chap. IV).

Since the extremities in earlier stages of development are less resistant, they become soft and are more easily contorted; but at a somewhat later stage of development, when they are more resistant, it is not uncommon to find the arms especially assuming more extended positions of gesture. Hence grotesque figures occur, such

as exemplified in Nos. 1462 and 1309 (figures 224 and 225), which are purely accidental forms. As maceration becomes extreme, even without the presence of putrefaction, marked softening and distortion take place and the face may be drawn into grimaces, as illustrated by No. 1775 (fig. 226) and by other specimens previously represented. In these older specimens the epidermis, instead of falling off in flakes or hanging in streamers, especially from the extremities of the digits, may become rolled up and accumulate in welts, especially at points of contact of the extremities, as illustrated in No. 1859 (fig. 64, plate 5, Chap. IV).

If dehydration occurs under sterile conditions, the transition from such a specimen as No. 1859 to 1474*a*, shown in figure 61 (plate 5, Chap. IV.), is an easy one, and if continued beyond this stage it may eventually lead to typical mummification. If the amniotic fluid is finally completely or almost completely absorbed and the uterus then contracts upon the specimen, such rolled-up forms as Nos. 1525, 1976 (figures 227 and 228) and No. 1041 (figure 40, plate 4, Chap. IV.) may result. Sometimes the placenta and membranes of these long-retained, leathery specimens are found in the form of a firm covering with a small opening through which the fetus has escaped, as illustrated by No. 1850, a fetus of 17 mm., shown in figure 229.

In other instances the fetal tissues, instead of becoming dehydrated, as in case of the above and No. 1295*a*, shown in figure 230, remain soft, as represented in a comparatively early stage by No. 1350, 66 mm. long, shown in figure 61 (plate 5, Chap. IV).

A more advanced stage of this process is represented by Nos. 2034 and 1925, fetuses 96.5 and 147 mm. long respectively, shown in figure 234 and figure 48 (plate 5, Chap. IX). If this process of maceration becomes extreme, or if putrefaction supervenes, such disintegrated forms as No. 1515 (fig. 50, plate 5, Chap. IV) are finally produced, and the stage of disarticulation is at last reached.

That the advent of rigor mortis does not necessarily change the attitude of young embryos is suggested from occurrences observed personally under experimental conditions. As long as the amnion closely invests a mammalian embryo, the extremities of the latter can not become extended during rigor, and hence may retain the intrauterine position. The same thing holds, to a considerable extent at least, for the trunk also, for neither is it so free to extend as when the amnion has been opened or been removed. In the human conceptus the amnion soon becomes sufficiently large, however, but coagulum could have a similar influence.

Although little is known regarding intrauterine rigor mortis, Wolff (1903) stated that it is not rare, and held that an accumulation of waste products produced in consequence of circulating disturbances in the mother may be responsible for its early advent. In any case it probably is quite transitory, and the later rigidity of aborted cyemata undoubtedly must be due to something else.

At present we are not in position to accurately evaluate slight changes in bodily form of cyemata, for as long as the exact form of normal cyemata remains undetermined, it is inevitable that macerated specimens will be mistaken for and represented as normal in form, even in contemporary embryologies. Abnormal

forms likewise have been described as normal, and macerated normal specimens also as pathologic, although no one would, I presume, defend the opinion that a dead conceptus may become pathologic.

Although His emphasized that the softness of aborted forms easily results in unusual folds and flexures, he, it seems, greatly reinforced, even if he did not introduce, the idea that embryos that are abnormal in form are pathologic. He apparently came to this conclusion because he did not believe that post-mortem changes could be responsible for modifications in form present in the specimens which came to his attention. Giacomini (1888) also believed that many of the deformities so common in embryos of the first months are due purely to regression after death, but added that he did not care to stress the idea that post-mortem changes can account for many of the deformities seen. Later Giacomini evidently became skeptical, however, and decided that it remained to be determined whether the changes in the embryo are primary or secondary. Furthermore, in 1894, he declared that one never meets with changes in abortive forms which one can attribute solely to softening, and concluded that embryos that die soften and disintegrate quickly, only those which merely are inhibited in growth being preserved for months. Waldstein (1913) also stated that von Winckel spoke of a slowing of development before death of the embryo occurred. While it is conceivable, and even probable, that inhibition in growth may occur, experiments now under way show that dead mammalian fetuses nevertheless may be preserved in sterile nutrient and non-nutrient solutions at body temperature for extended periods of time—for months—without indication of growth and with very little change in external form.

Although one must frankly recognize that it is extremely difficult to simulate intrauterine conditions closely, these experiments nevertheless very seriously question the conclusion of Giacomini. His (1891) also emphasized that dead embryos may be preserved *in utero* for months, and there is abundant evidence in the Carnegie Collection corroborating this conclusion. But it is conecivable that slight modifications in body-form might arise from gradual inhibition in growth, as well as from post-mortem changes of secondary origin. Panum (1860), in discussing what he termed *monstruositates totales amorphoides* occurring among chicks, also expressed the opinion that the changes in embryonic form noticed by him arose during life. He claimed that these changes could not have resulted from maceration, because adhesions of the membranes were present, because the specimens showed a total divergence from the normal form, and also because of the differences in size and consistency found to exist among them. Panum was led to the conclusion that all the deformities noticed by him in chicks were the result of the conditions under which development occurred and through the absence of evidence supporting the opinion of Bischoff that the cause of monsters was germinal. But Panum nevertheless believed that gases formed from putrefaction might compress the embryo and produce a fetus papyraceous.

When considering these greatly modified or even bizarre forms of human embryos, one also is reminded of the fact that Panum believed that monstrous chicks resulted directly from a lowering of the temperature during incubation.

However, since Panum found deformations especially common in the cephalic extremity, and further stated that many of his so-called "monstruositates totales cylindricæ" were mummy-like, with features effaced, it seems more likely that he was dealing with maceration forms the death of which was due to the chilling. Just why some chick embryos, the heart-beat of which has been temporarily suspended by chilling, die quite promptly, and others only late in development, near the end of the normal incubation period, I do not know, but personal observations leave no doubt regarding this matter, and variation in vitality is all that I can suggest as an explanation at present.

It is only just to state that Panum considered the possibility that the anomalous forms were secondary in origin, and concluded that some were germinal in origin. His (1891), too, at first regarded certain abnormal forms of human embryos, such as the nodular, cylindrical, and flexed (geknickte), as germinal, but later inclined to the belief that they nevertheless arose from changes occurring after the death of the embryo, saying:

"Seitdem ich mir aber Rechenschaft gegeben habe von den histologischen Veränderungen welche eine Folge des Absterbens sind, von der Quellung des Gehirns und den Veränderungen der ursprünglichen Gewebe durch eine Zellenbrut, bin ich weit mehr geneigt, die abortiven Formen von Embryonen als secundär enstanden anzusehen. So werden speciell auch die so auffälligen Cylinderformen verständlich, sowie man sich davon Rechenschaft giebt, dass von dem früheren Embryo neben einem auffälligen Skelett fast nur noch die Haut übrig geblieben ist. Als ausdehnbarer Sack kann sich dieselbe mit fremdem Material, mit Wanderzellen und zum Theil mit Flüssigkeit ausfüllen und nun giebt sie die alten Körperformen nur noch in den allergröbsten Zügen wieder."

In spite of these words, His insisted that poorly preserved normal forms never show changes seen in so-called abortive forms, and emphasized that, although the cells in abortuses may not all be dead, we nevertheless can not speak of these abortive forms as living.

The mere fact that post-mortem changes may produce misleading modifications in form makes the identification of post-mortem deformations extremely important. If all conceptuses were aborted immediately after their death, the problem would be a far simpler one, for such an event would at once dispose of such difficult questions as, not only those of survival, but also of the independent growth of one or more members of the cyema, or of the whole of the vesicles, after the death of the cyema. That outward apparent stunting is a fairly common occurrence in young embryos is fully attested by the many specimens in the Carnegie Collection which illustrate this phenomenon, but I have not been able to find convincing proof indicating that it is also physiological. In the case of older fetuses with apparent brachydactyly, osseous development seems to have been normal and the modifications attributable to changes in the soft parts. Hence I am prompted to conclude that, although growth may be retarded in consequence of circulatory disturbances, it continues wholly normally, unless influenced by other things, until the heart stops.

It also may be difficult to tell whether a given condition arose before or after death of the embryo, merely because of the presence of maceration changes, even

when these changes may have occurred in a sterile medium. The difficulty of distinguishing between ante-mortem and post-mortem changes, which impressed Phisalix and also others, is very great, if not insurmountable in some cases. This is true especially if it be assumed that an irregular or uncorrelated growth can occur under post-mortem, ante-partum conditions, for such growth could easily produce anomalous forms. But it must be admitted that the existence of a genuine post-mortem growth is merely an inference at present.

In considering some of the strange forms to which attention has been called one can not disregard such instances in the newborn as that reported by Cowie (1914). The posture of this infant reminds one very strikingly of some of the fetuses in the accompanying illustrations. This seems very disconcerting at first thought, but there is, of course, no reason why a condition responsible for the occurrence of multiple intrauterine fractures, such as are present in this infant, should not result in very abnormal postures. Moreover, if fetal bone disease may begin very early, it is also probable that some of these strange, relatively early fetal forms well may be genuine fetal anomalies and pathologic in addition.

The cases reported by de Lima (1915), especially cases 2 and 3, also belong among those which simulate some early fetal forms. Nevertheless, in these, and also in the other 2 cases reported by him, de Lima found bony defects. The same thing was true of the outwardly similar cases in infants and children reported by McKenzie (1897).

However, in view of the occurrence of these outward resemblances, it is not always possible to distinguish normal specimens which have suffered post-mortem deformations or changes in posture of the extremities from true developmental anomalies by outward inspection alone. This difficulty is particularly great in connection with changes in form and position of the hands, the feet, and the head and neck, and greatest of all, in connection with the knees. Even a cursory examination of some of the accompanying figures must also show that we at present are unable to decide whether any of these young specimens with pronounced deflections of the head and neck are cases of genuine torticollis and others are genuine cases of club-hand or club-foot, or genu varus, or valgum, for example. Indeed, this difficulty could be avoided only if these conditions arose only late in pregnancy, or if the cyemata showing them never were aborted before term. Waiving the exact definition of *club-hand* and *club-foot*, it must strike the attention of anyone that caput obstipum and *apparent* club-hands and club-feet so often are associated in these relatively early specimens, most of which are decidedly macerated. In 10 out of 21 cases of club-hand and club-foot listed as such among 3,000 accessions, excluding 2 cases with an embryonic length of 2.5 and 16 mm., respectively, clubbing was present in all the extremities. This is a wholly different relationship from that which obtains between these anomalies at the time of birth, when they seem to be associated but very rarely. However, in practically all of these cases of universal clubbing of macerated specimens the anomaly is associated with other developmental defects, as is not infrequently the case in the congenital condition.

Three of these 21 cases of clubbing were classed among the normal and 18 among the pathologic. With the exception of 3 fetuses which had a length of 100, 130, and 220 mm., respectively, all were less than 100 mm., the average length being 48.9 mm. While it may be possible to recognize genuine clubbing, due to the absence of the bones or to defects in them so early in fetal life, by microscopic examination or by other special methods, this certainly can not be done by inspection alone. Hence it is clear that the term *club-foot*, as used in the classification of this collection, is without special implication, except that it tells something about the shape of the periphery of the extremities.

It would also seem that if all these cases of deformed extremities in fetuses were true developmental anomalies, they should be encountered in well-preserved specimens, and more frequently in the older ones. That other anomalies should be found associated more frequently also seems to follow from our knowledge of congenital club-hand and club-foot. Among these genuine cases defective development of the bones seems to be more frequently noted, for congenital club-hand nearly always is accompanied by absence of either radius or ulna, while in the cases under consideration here such an absence has not been established. Nor is it without significance that the most pronounced forms of club-hand and club-foot found in these fetuses always occurred in those longest retained and most macerated. Many of them also show quite general evidences of the presence of pressure defects, and unless it can be shown that a tendency to progressive elimination of specimens with double club-foot and hand exists, with survival of those suffering from club-foot alone, one can not harmonize the frequent association of these defects in fetuses with the conditions as known to exist at the time of birth. However, since certain forms of congenital club-foot are probably also the result of intrauterine pressure, the types found in fetuses if the latter survived would be quite similar or even identical, in a morphologic sense, with the condition in the newborn; yet in one case growth would have ceased before the pressure became effective, while in the other it continued. The fact that congenital clubfoot is relatively seldom due to bony defects would also seem to point to external factors as causes, but I have no final opinion on this matter and am calling attention to it merely to emphasize the fact that post-mortem intrauterine changes resulting from maceration and pressure, or from both, may easily cause confusion in young cyemata.

DESCRIPTIONS OF PLATES.

Plate 17.

Fig. 175. A portion of a chorionic vesicle, showing appearances identical with tissue cultures. No. 545. ×135.
Fig. 176. Fetus showing gluing of hand to face. No. 316.
Fig. 177. Villi showing obliteration of vessels by maceration and disintegration. No. 640.
Fig. 178. Villi showing obliteration of vessels by proliferation. No. 317. ×97.5.
Fig. 179. Macerated tubal specimen imbedded in clot and undergoing lysis. No. 1938. ×0.75.
Fig. 180. Fetus showing continuity of epidermis across the mouth, with obliteration of the labial slit. No. 885. ×4.5.
Fig. 181. Macerated tubal specimen, only the chorionic vesicle remaining. No. 2035. ×0.75.
Fig. 182. Slightly macerated villi. No. 275. ×37.5.
Fig. 183. Greatly macerated villi. No. 723*b*.
Fig. 184. Macerated, long-retained villi, with lumina of capillaries plugged with coagulum. No. 286. ×37.5.
Fig. 185. Fetus in sagittal section showing maceration, especially of the nervous system. No. 285. ×4.5.
Fig. 186. Cross section of cyema showing homogeneous structure produced by maceration. No. 205. ×11.25.

Plate 18.

Fig. 187. Slight swelling of fetus from brief maceration. No. 2146. ×2.
Fig. 188. Matted, slightly macerated villi. No. 1878. ×4.
Fig. 189. A macerated, disproportional cyema 4 mm. long, showing a development of 5.5 mm. No. 786. ×4.
Fig. 190. A well-preserved cyema 5.5 mm., of the same development as the preceding. No. 1380. ×4.
Figs. 191–192. Cyemata illustrating failure of extension of the body upon maceration. Nos. 1299 (×2) and 2216 (×4).
Figs. 193–196. Cyemata illustrating changes in form due to maceration. Nos. 208 (×2), 1296 (×2.67), 1697 (×2), and 1477 (×2).
Fig. 197. Illustrating beginning changes in form due to maceration. No. 705. ×1.35.
Figs. 198–204. Similar specimens, showing more pronounced changes. In figure 203 the structure of the specimen is chaotic. Nos. 2244 (×2.67), 1891 (×2), 1655 (×2.67), 1260 (×2.67), 1333 (×2.67), 1379 (×2.67).
Figs. 205–206. Doubtful normally developed cyemata. Nos. 1226 (×2.67) and 2361 (×4).
Fig. 207. A cyema illustrating post-partum changes. No. 589. ×2.67.
Fig. 208. Cyema showing maceration sulci and ridges, and drooping of the limbs. No. 521*f*. ×1.66.
Fig. 209. Cyema showing maceration sulci and ridges, and swelling of the cord. ×2.
Fig. 210. Normal, well-preserved cat fetus.
Fig. 211. Normal, poorly preserved cat fetus of approximately the same length.
Fig. 212. Appearance of fetus before fixation. No. 1358. ×2.
Fig. 213. The same specimen, showing wrinkling due to fixation and staining. ×2.
Fig. 214. Macerated, distorted single-ovum twins. No. 2258. ×2.67.
Fig. 215. Minor changes in relief, due to maceration. Swelling and constriction of cord. No. 2014. ×2.
Fig. 216. An intermediate maceration form. No. 1495*d*. ×2.67.

Plate 19.

Fig. 217. Interior of the chorionic vesicle showing subchorial hematomata. No. 1495*d*. ×0.77.
Fig. 218. A fetus and cord showing marked maceration changes. No. 797. ×1.35.
Fig. 219. An older fetus, showing bleb-formation and curvature in extremities, due to maceration and retention. No. 1860. ×1.35.
Fig. 220. A fetus showing marked clubbing of the extremities and obliteration of the features. No. 1958. ×0.87.
Figs. 221–222. Extremities of same specimen. ×2.67.
Fig. 223. External appearance of fetus *in situ*. No. 1751. ×0.57.
Fig. 224. An older, macerated fetus, with extremities extended instead of folded. No. 1462. ×0.77.
Fig. 225. A similar specimen. No. 1309. ×0.23.
Fig. 226. A long-retained, soft, rolled-up form, photographed in extension. No. 1775. ×0.47.
Fig. 227. A similar specimen with markedly flexed head. No. 1525. ×0.66.
Fig. 228. A similar specimen. No. 1976. ×0.47.
Fig. 229. A similar specimen with mummified chorionic vesicle. No. 1850. ×6.
Fig. 230. A decidedly mummified fetus. No. 1295*a*. ×0.77.
Fig. 231. Unilateral development of villi in a vesicle classed as normal (?). No. 2092. (See Chapter XV.) ×1.35.
Fig. 232. A somewhat macerated young vesicle with quite uniformly distributed villi which are slightly abnormal in form and structure. No. 1878. (See Chapter XV.) ×4.
Fig. 233. A portion of same specimen, showing the somewhat more than normally bulbous and rather matted villi. ×2.67.
Fig. 234. A very softened, macerated fetus. ×0.5.


175

176

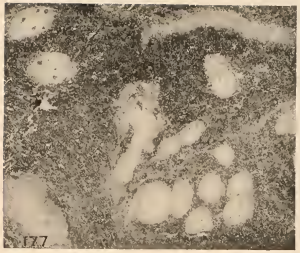
177

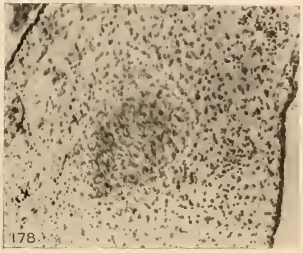
178

179

180


181

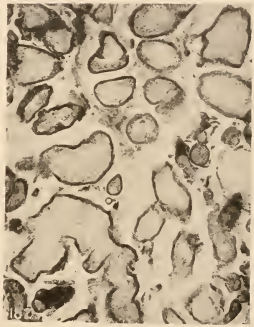
182

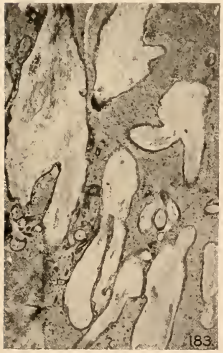
183

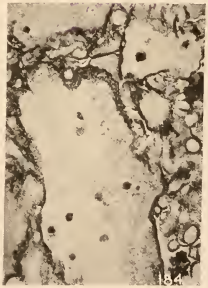
184

185

186

187

188

189

190

191

192

193

194

195

196

197

198

199

200

201

202

203

204

205

206

207

208

209

210

211

212

213

214

215

216

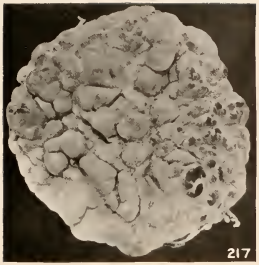
217

218

219

220

221

222

223

224

225

226

227

228

229

230


231

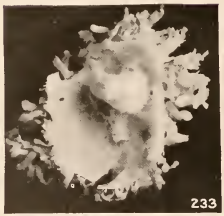
233

232

234

CHAPTER XIV.

HOFBAUER CELLS IN NORMAL AND PATHOLOGIC CONCEPTUSES.

The history of these cells illustrates very well how a *rediscovery*, when accompanied by a fuller description, succeeds in domiciling itself in anatomical literature as an original discovery. As we shall presently see, Hofbauer (1905) was impressed especially by a conspicuous phase in the life-history of a particular cell. He noted its reaction, in the fresh state, to certain stains, described it more fully, and speculated with some freedom on its functional rôle; but he did not discover this cell, as he supposed, in 1903. Although Hofbauer, in his book published in 1905, referred to his address given in 1903, he did not refer to or list the paper based on this address, published in 1903, in the title of which these cells are referred to as "hitherto unknown" and as "constantly occurring." Hofbauer's failure, in 1905, to recognize earlier workers was, I presume, an oversight, which apparently led Essick (1915) and others to assume that "Hofbauer first called attention to specific round cells appearing in the human placenta toward the end of the fourth week of pregnancy."

The type of cell which in recent years has been designated with Hofbauer's name was known previously, especially as *Wanderzelle*, and had been represented by various investigators. Minot (1911), in a footnote, referred to the latter fact and rightly added: "It has long been known that strikingly large free cells appear in the mesenchyme of the chorion. They are pictured in my Human Embryology." Reference to the illustration in this work shows a large, rather granular cell, with a somewhat eccentrically placed, vesicular nucleus, but without vacuoles. Moreover, previous to the publication of this Embryology, Minot (1889) not only spoke of large, granular, wandering cells in the stroma of the chorion, but also represented them. From Minot's familiarity with the work of Langhans (1877) and of Kastschenko (1885), it does not seem unlikely that, among others, he had these investigators particularly in mind when he referred to earlier descriptions.

In the absence of a more discriminating term for these erratic and largely ephemeral elements, the original designation of wandering cell would seem far preferable to the designation "lipoid interstitial cells," used by certain Italian writers. The former is a non-committal term and, although too inclusive, is for this reason no more objectionable than the expression *giant cell*. Although these cells may not—indeed, probably do not—wander in the sense of the amœba or the leucocyte, they nevertheless may change their location decidedly. The qualification "interstitial" is objectionable for the very reason for which it was chosen—the alleged analogy to the interstitial cells of the testis and ovary—and since they may contain lipoid substances merely because they are degenerate, the adjective *lipoid* is equally objectionable. For reasons to appear later, the designation "plasma cell" used by certain Italian writers since 1905, would not seem to be justified.

Virchow (1871) stated that isolated cells with clear vesicular spaces in their protoplasm are found in the stroma of the villi in cases of hydatiform degeneration,

and identified them with certain other cells (physaliphores) previously described by him. He found these bubble-like cells, as he called them, also in the thymus of the new-born, in cancer, etc., and, according to Virchow, they were not merely vacuolated cells. He seems to have regarded them as identical also with the vacuolated syncytial masses, for he stated that Müller described them as occurring in the chorionic epithelium. Since syncytial elements are not uncommon in the stroma, instances of confusion of these two cell types can be found in contemporary literature also.

Langhans (1877), in describing the stroma of the villi, said that it contained "sharply delimited large cells with many granules in the protoplasm. Their form is variable—circular, spindle, and star-shaped." These cells were said to lie mainly near the periphery. However, Langhans, who was interested mainly in other problems, did not represent them nor discuss their probable significance. But Kastschenko (1885) represented them and described them as being about 9 μ large, and as corresponding exactly in form and size to the white blood-cells of the same embryo. According to Kastschenko, the cytoplasm is reduced in quantity after the first month, so that the nucleus no longer is surrounded by it. The nuclei also are said to undergo a change and to appear later as solid structures. The latter observation can not fail to remind one of pycnosis and of one of its well-known significances. Kastschenko found these cells mainly near the epithelium of the villi and stated that they vary greatly in size, number, and occurrence in the same placenta. The fact that Kastschenko identified the cells found in the mesenchyme of the embryonic villi as leucocytes might seem to indicate that what he saw and described were other than Hofbauer cells. However, his illustrations, especially when considered in connection with those of earlier investigators and those of Minot, leave little doubt that all these investigators saw the same type of cell. Moreover, it is not improbable that Kastschenko was influenced in his interpretation of these cells by the origin and current use of the term "Wanderzelle." It will be recalled that von Recklinghausen (1863) showed that the leucocyte preeminently belonged in this class of cells, but even at the time that Kastschenko was writing, and far later, all cells which were regarded as foreign to the tissue in which they lay were still included in the designation "Wanderzelle." Reference to the literature of that period will make this fully evident.

The presence of these cells in conceptuses classed as pathologic was noticed repeatedly by Mall (1908), who also designated them as wandering or migrating cells in his earlier protocols. Chaletzky (1891) also saw and described these cells, but perhaps the best description from an earlier date is that given by Kossman (1892), who also referred to the Hofbauer cells as "Wanderzellen," and gave excellent representations of them. Indeed, from an inspection of the latter alone there can be no question as to the identity of these "Wanderzellen" and the Hofbauer cell. In speaking of them, Kossman said:

" . . . . Auffallend sind zahlreiche grosse Zellen, die eine sehr wechselnde, oft amöboide, niemals sternförmige Gestalt haben. Die Filarmasse ihres Protoplasma's ist durchaus fein, netzartig angeordnet und färbt sich stark in Hämatoxylin. Die Zellen

enthalten einen oder mehrere grosse blasenartige Hohlräume, von denen ich leider nicht sicher sagen kann, ob sie Fett führten, da sie mir erst nach Behandlung des Präparats mit Xylol auffielen. Der Kern dieser Zellen enthielt stets Nucleoli. Die Zellen sind also jedenfalls nicht in lebhafter Vermehrung; wahrscheinlich sind es Wanderzellen, und da sie auf einem wenig älteren Stadium wieder fehlen, mag ihr Vorkommen in einigem Zusammenhange mit der um diese Zeit beginnenden Vascularisation des Stroma's stehen."

Merttens (1894) found the same cells in abortuses, and, in describing the stroma of the villi of his first case, said:

"An den Ernährungszotten ist es kernreich, vielfach aufgelockert, mit stern- und spindelförmigen Zellen, in den Maschen jene oben für die normalen ersten Stadien beschriebenen grossen, runden oder polyedrischen Zellen mit körnigem oder auch vacuolärem Protoplasma mit grossem, bläschenförmigem, rundem Kern."

Merttens seems also to have suggested that these cells are swollen stroma cells, but since he made this observation somewhat disconnectedly I am not quite certain of his meaning; yet the mere suggestion is particularly interesting, in view of Minot's special emphasis upon the degenerate character of the Hofbauer cells. Marchand (1898) also wrote:

"Die durchsichtigen hellen Zellen im Stroma normaler oder pathologischer Zotten sind mir wohlbekannt, sie können denen der Zellschicht sehr ähnlich sein; ich halte sie jedoch für gequollene, rundlich gewordene Bindegewebszellen, da man Übergänge zu solchen findet, ebenso wie in andern Schleimgeweben."

Ulesco-Stranganowa (1896), who also saw these cells, says that if one compares the Langhans cells with round nuclei with these cells scattered about the stroma of the villi, and which have been named "Wanderzellen" by Kastschenko, one becomes convinced of the identity of these two types of cells. According to Ulesco-Stranganowa, then, the Hofbauer and Langhans cells are identical. Mall (1915) also called attention to this possibility, for, when speaking of the invasion of the mesoderm of the villi by trophoblast, he called attention to the presence of numerous Hofbauer cells, and added: "It would seem possible that these Hofbauer cells are free trophoblast cells within the mesoderm of the villus, an opinion already expressed in my paper on monsters." Neumann (1897) also noticed these cells and referred to Virchow's opinion regarding them, and von Lenhossék (1902) is credited by the reviewer of his paper in 1904 with having examined a large series of young human embryos, and having suggested that what Kastschenko regarded as "Wanderzellen" were mesenchyme cells. It should be noted, however, that von Lenhossék apparently came to this conclusion largely because of the absence of blood-forming organs or lymphatic centers in embryos, in the villi of the chorionic vesicles of which he found these cells. Strangely enough, Kworostansky (1903) also recorded the presence of these cells, and after describing the stroma of the villi wrote:

"Zwischen den genannten Bindegewebszellen giebt es in der wolkigen Grundsubstanz Lücken, und am Rande oder im Winkel derselben sitzen freie andere Bindegewebszellen, die sehr gross sind, lappige, runde Form, wabenartiges Protoplasma und gleiche Kerne wie andere Bindegewebszellen haben; ihre Kerne werden auch, hie und da stern-

förmig getheilt. Da sie stets nur in Gewebslücken gefunden werden, so glaube ich, sie als Lymphgefässendothelien, oder vielleicht als Lymphocyten bezeichnen zu dürfen. Man findet sie in späteren Stadien der Placenta nur sind dann natürlich die Zellen nicht mehr gross."

The illustration which accompanies Kworostansky's article, as well as his description, leaves no doubt that the cells seen by him are the same as those which we are considering, although his surmise that they are lymphocytes and that they arise from the endothelium of the lymphatics may, upon first thought, seem rather irreconcilable with such an assumption.

From these references alone it is evident that Minot's statement that the so-called Hofbauer cells were repeatedly mentioned in the earlier literature is well founded. Muggia (1915) stated that these cells were described also by Guicciardi (1899), Clivio (1903), Stoffel (1905),[1] Vecchi (1906), and Pazzi (1904). Indeed, many other names could be added, for surely any one of the many who studied even a small series of chorionic vesicles must have seen some of them in some villi, especially in unrecognized cases of hydatiform degeneration, but since they have been referred to as Hofbauer cells, it is his description that especially interests us. In describing the chorionic villi, Hofbauer (1905) spoke of certain gaps or spaces between the meshes of the mesenchyme of the villi which he thought might belong to the lymphatics or contain tissue fluid. In these spaces he found certain granular, round cells arranged longitudinally. He thought they were often spherical, with a diameter of 10.5 μ to 12.5 μ, but more commonly star-shaped or branched. By means of these branches they come into direct relation with other similar cells or with connective-tissue cells. However, Happe (1906) stated that he could not with certainty find cells united by their processes, as described by Hofbauer, in preparations stained after Hänsen. According to Hofbauer, the cell processes are delicate, and the cells contain one or two nuclei from 4.7 μ to 5.7 μ in diameter, oval or circular in form, eccentric in position, with a definite membrane and a dense chromatin network. Mitoses were common, and fragmentation of nuclei and indications of pluripolar mitoses also were seen. Hofbauer emphasized that the most characteristic thing in these cells which he regarded as being specific was the presence of vacuolation in the "plasma" and the existence of a perinuclear clear zone, which was said to be the result of fusion of "small light spots." As the cytoplasm becomes vacuolated the nucleus is said to become pycnotic, which stage is followed by failure to stain and finally by its complete disappearance. Hofbauer also noticed the presence of granules and fat droplets, and regarded the life-history of these cells as a circumscribed one. He did not find them present in real young villi. They were said to appear at the end of the fourth week, and were more common in young than in old placentæ. They reacted to vital stains like plasma cells, and Hofbauer regarded the vacuoles as having an assimilative and digestive function. A reference to the plates accompanying Hofbauer's monograph, however, suggests that vacuolation was not always present, and that the largest of the cells were almost twice the size of the smallest.

[1] A re-reading of Stoffel's article shows quite conclusively that he did not describe the plasma cells of Hofbauer.

In his earlier paper Hofbauer (1903) also said that his preparations, taken from material from the fourth to the ninth week of pregnancy and obtained at operation, showed these cells in all stages of mitotic division. Hofbauer further wondered whether the spaces surrounding these cells are lumina of capillaries, added that the cells discovered by him undoubtedly are found in capillaries, and made some rather unguarded surmises concerning them.

Berlin (1907), in writing on the changes in retained placentæ, also spoke of large, swollen, hydropic cells which lie in spaces. These cells she regarded as undoubted mesenchyme cells. However, Berlin did not believe that they are degeneration products, although her description certainly would lead one to suppose that they were such. Even when she stated that they bear no sign of degeneration, emphasizing that the chromatin network is fine, she nevertheless spoke of *swollen* nuclei which have gathered a larger amount of protoplasm about them, phenomena which she regarded as signs of luxurious nutrition. Moreover, Berlin never observed mitoses and never found the nuclei increased, in villi containing many of these cells, an observation wholly in harmony with that of others and directly opposed to the idea of proliferation.

Grosser (1910), who was plainly aware of the fact that Hofbauer was not the discoverer of these cells, also represented a cell, which, however, is non-vacuolated and binucleated, and added that their significance is still unknown.

I have given Hofbauer's description, partly to emphasize the vacuolation, for it was this which also impressed Minot (1911), who rightfully stated:

"We frequently find in the literature mention of wandering cells with vacuolated protoplasm, but they seem not to have been recognized as degenerating cells. . . . The disintegration by vacuolation has, so far as known to me, not been described heretofore, and consequently may be treated somewhat more fully. . . . . Renewed investigation has led me to the conclusion that we have to do with erythrocytes which have gotten into the mesenchyma and, remaining there, have swollen by imbibition and are undergoing degeneration by vacuolization of their protoplasm. . . . . We can explain the appearance of these cells by the assumption of imbibition, in which the nucleus has participated. . . . . Since I have found similar cells in a considerable number of placentas, I draw the conclusion that they are constant and normal. I regard the interpretation of the pictures unattackable as proof of progressive degeneration."

In association with these remarks, Minot represented a series of cells showing progressive degeneration, beginning with the nucleated red cells and ending with a highly degenerated, but nevertheless nucleated, Hofbauer cell which apparently is in process of disintegration. These cells were seen by Minot especially in a human embryo of 15 mm. length, from the Carnegie Collection.

As shown in the references to the literature above, it is not quite correct to say that the degenerate character of vacuolation has not before been recognized, for the surmises that Hofbauer cells contain fat granules may, and that they are swollen mesenchyme cells must, carry this implication. Moreover, those familiar with the effects of inanition know that investigators of this subject long ago called attention to vacuolation as one of the evidences of degeneration, although, certainly, no one contends that it always is such.

Instead of regarding these cells as degeneration products, certain Italian writers (notably Acconci, 1914[b]) regarded cells which they found, especially in the first half of pregnancy, as morphologically and functionally comparable to the interstitial cells of the ovary and testis. Acconci believed that certain cells which he and other Italian writers after him designated lipoid-interstitial cells, probably produce a special internal secretion. He, like Hofbauer, found these cells to contain lipoid granules, and regarded them also as equivalent to certain cells "described by Ciaccio in various parts of the organism, or by Brugnatelli in the interstitial tissue of the mammary gland." Acconci further emphasized certain similarities between the syncytium and the interstitial cells, both of which he conceived as exercising a protective rôle. Muggia (1915), too, instead of regarding the lipoid interstitial cells of Acconci as degenerate, emphasized his belief that they are particularly resistant to degeneration, being found perfectly preserved in the midst of detritus. Since the young connective-tissue cell loses, or rather retracts, its processes as it becomes converted into a Hofbauer cell, it need not surprise us that the latter survives the former. Retraction of the processes contributes to the apparent increase of cytoplasm of the rounded swollen cell and also is involved in the formation of the spaces in which these cells usually lie. Muggia, who considered the cells found by him in great numbers in a case of partial hydatiform degeneration as identical with those described by Acconci, gave a fine detailed description absolutely typical of the cells previously described in greatest detail by Hofbauer. Moreover, the excellent illustrations which accompany Muggia's article leave no doubt as to the identity of the cells or of their degenerate character. Muggia stated that these cells in normal villi increase until the end of the fifth month, when, according to Savare, they are most numerous. Muggia further found numerous cells very similar to the interstitial cells of Acconci, or "the plasma-like cells of Hofbauer," which he says are regaredd by some as early stages of interstitial cells and by others as mast-cells, concluding that he regarded the latter as partially differentiated interstitial cells.

Until I had seen sections of the chorion of No. 1531 I was largely at a loss to know why Hofbauer cells were so frequently described as lying in gaps or spaces in the mesenchyme. However, in this specimen cross-sections of a number of villi showed splendid examples of this condition, which alone made the cells very conspicuous. The cells often were very numerous, in fact more numerous than the mesenchyme cells which remained, although some well-preserved villi contained no Hofbauer cells whatever. Some of the younger specimens also contained none. This was true of a chorionic vesicle with an embryo 1 mm. in length. They were found most commonly in the villi, but not infrequently some of them lay in areas of the chorionic membrane which had undergone degeneration. They were not so common here, but sometimes were exceedingly numerous in small areas. They were found in the amnion also, in the umbilical cord, and in the tentorium cerebelli, and as isolated specimens in embryonic mesenchyme elsewhere. As emphasized by other investigators, there seemed to be nothing particularly characteristic about their distribution, except that they were more common in places where

the mesenchyme was degenerating. Sometimes a considerable number were contained in one villus and none in an adjacent one. As many as 12 might lie in one field and none in the next. In rare instances there was a solid mass of them, as shown at one side of the villus in figure 128 (plate 12, Chap. VIII), but usually they were scattered about at random, although groups were also seen. The better-preserved cells were small, the poorer-preserved larger, the size varying from 8.5 μ to 30 μ. The smaller cells were usually quite circular in outline, stained evenly, and possessed a non-granular cytoplasm with a nucleus quite centrally located. Binucleate cells, as described by Grosser, were not uncommon, and multinucleated cells—fusion products—were also found. The nuclei of the latter were frequently more unequal in size, and usually also more oval in outline, than the single nucleus of the typical Hofbauer cell. Measurements of some of the largest cells, made with a micrometer caliper, gave the following results: 25.5 by 20.4, 30.4 by 27.5, 18.0 by 12.0, 21.5 by 25.5, 18.0 by 14.0 μ. These figures are considerably above those given by Hofbauer, whose estimation of a size of 10.5 μ to 12.5 μ applies to the average-sized cell.

However, the size of the cells varied from specimen to specimen of chorionic vesicle, but not nearly so much as their state of preservation. This, no doubt, is partly due to the varying state of preservation of the villi themselves.

In outline they varied from irregular to circular, as stated by Hofbauer, and as represented by Minot (1911) in his series showing progressive degeneration. Although it was easy to distinguish the vacuolated Hofbauer cell from the well-preserved mesenchyme cell with cylindrical nucleus and many processes, specimens which represent transition forms, as stated by Marchand, and as shown in figures 235 to 237, were quite common. The latter generally were oval or slightly irregularly formed cells with a number of short processes, which latter, as well as the character of the nuclei and the form of the cell itself, certainly suggested a mesenchymal origin. They were also most numerous in villi, the stroma of which had become glassy, vacuolated, or fenestrated. In these the reciprocal numerical relationship between the Hofbauer and the mesenchyme cells was often especially evident. In certain areas in which almost no mesenchyme cells remained intact, numerous Hofbauer cells occurred in all stages of degeneration. In other portions of the chorionic membrane or of the villi, mesenchyme cells with processes in all stages of retraction were also clearly outlined in the homogeneous ground substance. Such evidences naturally remind one of Hofbauer's statement that Marchand called his attention to the fact that these cells were mesenchyme cells, a conclusion which Hofbauer accepted. My implication, however, is not that degeneration of the mesenchyme or of individual mesenchyme cells can proceed only through a Hofbauer stage, but that, especially in the chorionic villi, a form of degeneration of the mesenchyme seems to occur which gives rise to this peculiar cell-form, the degenerate character of which rightly impressed Minot. This relationship also attracted the attention of Mall (1915), who represented degenerating villi and stated:

"The core of the villus gradually breaks down and disintegrates. While this process is taking place we often see scattered through the stroma of the villus large protoplasmic cells. . . . . These cells, which I have repeatedly seen in the villi of pathological ova, may be a type of wandering cells; at any rate, when the villus is being invaded by the leucocytes and trophoblast it might be thought that they arise from the latter, but this is improbable."

It is of particular interest in this connection that Virchow (1863) stated that Schroeder van der Kolk (1851) had concluded that large, clear cells in the stroma of the villi, later classed among the "physaliphores" by Virchow, occurred too frequently to be correlated with hydatiform degeneration. This suggests that the so-called Hofbauer cells were known since the early days of cytology, and that some one must have noticed, even at that early date, that they were very common in some hydatiform moles. Whether or not this was van der Kolk himself I am unable to say, but that Hofbauer cells are especially numerous in some cases of hydatiform degeneration is undoubted. But it does not therefore follow that they are constantly present in this condition. Large numbers of Hofbauer cells were present in 17 out of the 61 cases of normal and pathological chorionic vesicles in which they were especially studied. Of these 17 cases, 14 were later independently identified as showing hydatiform degeneration, and the other 3 were considered as possibly such. In other words, every case of this series in which the Hofbauer cells were numerous was one showing hydatiform degeneration of the villi. It also is true, however, that 34 cases containing but a few or some Hofbauer cells were not identified as being hydatiform moles, although 3 cases containing small numbers of these cells were so recognized. Moreover, not a single case of this series of 61 specimens which contained no Hofbauer cells whatever was later identified as showing hydatiform degeneration.

Somewhat similar evidence was afforded by the study of 22 cases in the protocols of which Mall had previously noted that Hofbauer cells were present. Of these 22 cases, 13 were later identified as showing this degeneration. However, since a total of 153 cases of hydatiform degeneration were identified among 315 of those classed as pathologic among the first 1,200 accessions in the Carnegie Collection, it is evident that the presence of Hofbauer cells was especially noted in but a relatively small percentage of this series. Of 30 cases containing Hofbauer cells in sufficient numbers to attract especial attention in the course of a routine examination made for other purposes, 17, or 56.6 per cent, were later identified as instances of hydatiform degeneration. Since the 61 cases in the first series were examined especially for the purpose of study of Hofbauer cells, the higher percentage of correlation observed in this series may be due partly to this fact. At any rate, that such a correlation exists seems to be quite clear, although I do not conclude that the two conditions necessarily or invariably are associated.

It is interesting that Pazzi (1908[a]) considered a distrophy of the connective tissue with the development of cellular elements "not very well differentiated, but like the plasma cell of Hofbauer," as the initial and pathognomonic change in hydatiform degeneration. Pazzi further stated that the plasma cell of Hofbauer

may be in a state of hyperactivity or of degeneration, and questioned the statements that Hofbauer cells appear only at the end of the fourth week and that they have a short life. Pazzi regarded the Hofbauer cell as fundamentally a constituent of the villi, as the decidual cell is of the decidua. He, like Essick, attributed their origin to the endothelium of the vessels, and further suggested that the Hofbauer cell may have a special internal secretion intended to preserve the stroma of the young villus against degeneration. Pazzi also considered the question whether a Hofbauer cell can transform itself into an epithelial cell and finally into a syncytial cell, and added that the invasion of the stroma of the villus by epithelial growths, such as represented in figure 119 (plate 10, Chap. VIII), is only a special development of Hofbauer cells!

As already stated, Muggia also found these cells very abundant in a case of partial hydatiform degeneration, and held that their appearance and condition are correlated with proliferation and vacuolation of the syncytium, maintaining that, as the latter becomes vacuolated, the lipoid interstitial cells of Acconci appear, the changes in the two being wholly parallel.

Since 32 of the 51 chorionic vesicles in this series of 61 containing a few, some, or many Hofbauer cells had been classed among the pathologic, it follows that these cells were noticed more frequently in the pathologic than in specimens classed as normal. This becomes especially evident if we exclude from this series of 51 cases all those containing some or many Hofbauer cells, for of 27 of these, 19, or 70.4 per cent, had been classed among the pathologic. Moreover, since the great majority of the conceptuses classed as normal are abortuses, one would be entirely justified in questioning the strictly histologically normal nature of the chorionic vesicles which accompany some embryos classed as normal. At any rate, it is evident that the plasma cell of Hofbauer is associated with degenerative changes in the mesenchyme of the villi. Since such changes are more common in abortuses classed as pathologic, it is not surprising that Hofbauer cells are more common in the latter than in normal specimens, and, since degenerative changes in the stroma are especially pronounced in advanced cases of hydatiform degeneration, it is still less surprising that Hofbauer cells are particularly common in this condition. But they are not necessarily pathognomonic of hydatiform degeneration, although it is true that when at all numerous they are associated with hydatiform degeneration in about 75 per cent of the cases.

It also should be recalled that the great majority of the specimens classed as pathologic microscopically show the presence of both degeneration and maceration. However, it never was the most macerated but the most degenerate specimens in which Hofbauer cells were most numerous. Hence, whatever the cause of this transformation of the mesenchyme into Hofbauer cells, it may also be the cause of hydatiform degeneration.

After a careful survey of a considerable number of specimens, both normal and pathologic, ectopic and uterine, of human abortuses of widely different ages, I am led to concur entirely in the opinion of Minot that the typical vacuolated cell, as described by Hofbauer, is a degeneration product, *though usually not a*

degenerate erythroblast, as Minot concluded. However, in rare instances I have seen a chorionic vesicle in which the rather small, clear, isolated Hofbauer cells scattered throughout the stroma of a villus undoubtedly were erythroblastic in origin. In these villi capillaries in various stages of disintegration were present, and the erythroblasts could be traced directly to these degenerate capillaries. In the earlier stages of this degeneration these degenerating erythroblasts are not surrounded by spaces, however, and this is true also of early stages in the degeneration of the fixed or already detached mesenchyme cell, which later forms the typical degenerating wandering cell. However, it represents but one stage in this degeneration.

It is significant that, although Hofbauer suggested that these cells might have a digestive or assimilative function, he, too, frequently found fragmentation of the nuclei and complete disappearance of the cytoplasm and even of the cell itself. All stages of degeneration, as manifested by crenation of both cytoplasm and nucleus, even to complete disappearance of the cell, can easily be found. Signet-ring forms are common, and the nuclei are found in all stages of extrusion and degeneration. The cell boundaries are often ragged, the nuclei crenated and pycnotic, the cytoplasm granular, vacuolated, webbed, or fenestrated, until finally nothing but a faint ring or shadow form without a trace of a nucleus remains. However, in these transparent or shadow forms the nuclei, if not previously extruded or dissolved, are frequently represented by a mere outline or only by a faint trace of one. Since all stages between the latter and the well-preserved cells, without vacuoles and with well-preserved nuclei and cytoplasm, and also with processes, occur in well-preserved material, one can scarcely doubt their origin.

Undoubted instances of mitoses were never seen in any Hofbauer cells, no matter how well preserved. This no doubt can be accounted for by the fact that from the time the mesenchyme cells retract their processes and become isolated in the villus, they are in a stage of degeneration. Under such circumstances one would hardly expect to see instances of cell division, although it possibly may be simulated by necrobiotic phenomena.

Hofbauer (1905), as also in his first publication, stated that the cells described by him increase by mitoses which are frequent. He also found examples of what seemed to be instances of pluripolar mitoses, and also noted fragmentation of the nuclei. Acconci (1914[b]) also found mitotic figures in cells designated lipoid interstitial cells by him, but most investigators say nothing about this. On the contrary, a number of them specifically state that they could not find an actual increase in the number of nuclei present in the stroma of villi containing large numbers of these cells. Furthermore, every one except Muggia (and he also in his description and illustrations, as also Acconci) has noted characteristics and described the cells in such a way as to suggest the presence of degeneration changes. When at all distinct, the cells are of various shapes and sizes and are surrounded by a relatively large clear zone. Their occurrence is erratic, they contain lipoid granules or vacuoles, and have nuclei varying considerably in size, position, and staining reaction, as does also the cytoplasm. They are most frequent in degenerate villi

and not infrequently lie in detritus. The better preserved the stroma the fewer cells one finds, and in these observations on this rather large series of chorionic vesicles, some of which were obtained fresh—one living—in hysterectomy specimens, I have found only a few instances of what possibly could be regarded as mitotic figures. Since almost all are agreed that these cells are of mesenchymal or connective-tissue origin, it is easy to see that considerable difficulty must be encountered in deciding just when to regard a mesenchyme cell, which is its precursor, as a Hofbauer cell. Since I have not made this aspect of the question a particular subject of investigation, I have no evidence to offer on this point.

Since some of these cells, during the early period of degeneration, after they have become quite circular in outline and the nucleus has taken an eccentric position, have a decidedly granular or even a lumped cytoplasm, the confusion with plasma cells, or their earlier designation as granular wandering cells, need not surprise us. Nevertheless, the term *plasma cells* is hardly applicable, as many of them are not granular. Moreover, no one has shown that in fixed preparations these cells take the stains specific for plasma cells. Indeed, although he stained material with borax methylene-blue after Jadassohn, Happe (1906) did not find any of the Hofbauer cells impregnated. It must be remembered, however, that failure to stain may be dependent very largely upon the degree of degeneration which the particular cells have undergone, for, as already stated, Hofbauer found that in fresh material they reacted as plasma cells to vital stains.

The opinion of Minot that Hofbauer cells are degenerating erythrocytes can probably be accounted for by the fact that in the chorionic vesicle from which Minot's series, showing a progressive degeneration of the latter into the former, was obtained, it was impossible to distinguish between the two. This difficulty was due partly to the poor state of preservation of the particular specimen. A larger survey, especially of better preserved material, would have revealed the fact that Hofbauer cells are found in villi, the blood-vessels of which contain no erythroblasts. Moreover, as will appear later, the distribution of Hofbauer cells in the villi is not such as one rightfully would expect if they have their source in the vessels. However, since the final form of the typical Hofbauer cell is a mere shadow cell, it necessarily may be impossible to determine the kind of cell from which this shadow form arose, for, as is well known, the end-forms in the process of degeneration of many different types of cells are indistinguishable. Consequently, a group of swollen, highly vacuolated Hofbauer cells may also contain among them degenerated, nucleated red blood-cells, as Minot held. Indeed, degenerating erythroblasts which are indistinguishable from some Hofbauer cells can be seen occasionally not only in the vessels, but in the heart itself, and also within the cavity of the chorionic vesicle; but such findings do not prove that the Hofbauer cells of the villi arise from erythroblasts. That this is usually not the case follows also from the fact that well-preserved, non-vacuolated Hofbauer cells occur in villi which have not become vascularized or which, as stated above, no longer contain vessels. It is true that it is often impossible to distinguish between degenerate erythroblasts within the vessels and Hofbauer cells lying outside of, even

if near to them, in the stroma of the villus. However, this difficulty is entirely avoided by examining the older specimens without nucleated reds, for, since Hofbauer cells are always nucleated, except in their very last stages, confusion with nucleated cells is thus avoided.

Although the elimination of the erythroblast as the source of the Hofbauer cell was thus very easy, some difficulty was encountered, strangely enough, with regard to polymorphonuclear leucocytes. This is largely due to the fact that the nucleus of the latter often ceases to be polymorphous as these cells degenerate. Instances of this kind are quite common, especially in the membranes of hemorrhagic or infected abortuses. They are, however, also met with in the decidua. Since the polymorphous character of the nuclei of these leucocytes can usually be recognized without difficulty in degenerate accumulations of pus, I was at first predisposed against regarding a circular nucleus as possibly polymorphous in origin, but careful scrutiny of numerous specimens in which these misleading degeneration forms occurred soon left no doubt as to the facts.

As stated above, Hofbauer cells were found in the cavity of the chorionic vesicle in abortuses which contained blood or had become infected. In these specimens the degenerated polymorphonuclear leucocytes usually lie in groups, or more commonly in rows along the inner borders of the chorionic membrane, or in long narrow clefts or folds of the same. Some also were scattered about among the degenerating erythrocytes, but an examination of the contained blood usually surprises one by the entire absence, not only of well-preserved polymorphonuclear leucocytes, but of all leucocytes whatsoever. This is in marked contrast to what is found in the case of ordinary hemorrhages and is a fact full of significance for the question under discussion. Most of the degenerated polymorphonuclear leucocytes, many of which contained undoubted evidence of phagocytosis, possessed a relatively small, circular, vesicular nucleus which often was eccentric in position. Others were filled with a granular cytoplasm, or even with very discrete golden granules, while still others were filled with dark, black pigment granules corresponding in size to the golden ones. Here and there the field of degenerating erythrocytes may also be studded with masses of pigment which clearly declare their origin by the presence of all manner of transition forms between the well-preserved, easily recognizable polymorphonuclear leucocytes and the disintegrated pigmented detritus. The phagocytic nature of these cells is especially noticeable in the specimens of young chorionic vesicles, with nucleated reds, stained with iron hematoxylin, for in these the leucocytes are often seen filled with a mass of nuclei only.

Similar appearances can also be seen occasionally in the deciduæ from cases of endometritis, as well as in portions of a decidua in which the glands have undergone considerable maceration and degeneration. In the former the polymorphonuclear leucocyte is the misleading form, while in the latter the degenerating, cast-off glandular epithelial cells simulate Hofbauer cells in almost every morphologic detail. I have also seen similar specimens of degenerated polymorphonuclear leucocytes in ill-preserved hemorrhagic lymph-nodes, especially from cases of

septicemia, and, until the true nature of such degenerate leucocytes became evident, it was very puzzling to see why the Hofbauer cell, which never was found to contain evidences of phagocytosis when lying in the stroma of a villus, should become phagocytic when contained in a degenerated amniotic or chorionic membrane or when lying in a hemorrhagic area. Undoubted instances of phagocytic Hofbauer cells were never seen, although, in addition to those already mentioned, certain misleading forms, as shown in figure 238, were encountered also in pregnant tubes and in an ovarian pregnancy. Among these misleading forms were specimens of binucleate cells in which one nucleus had undergone almost complete chromatolysis, leaving only a nuclear membrane. These nuclear remnants or so-called nuclear shadows can easily simulate a phagocytosed erythrocyte. The same is true of small areas of cytoplasm which stain but faintly, and hence look more translucent, and particularly of vacuoles themselves.

Essick (1915) found what he regarded as morphologically similar cells in transitory cavities in the corpus striatum, and believed them to be macrophages. Consequently, he concluded that Hofbauer cells also are phagocytic and regarded them as having an endothelial origin. I have not been able to find any evidence for the latter origin, however, for in specimens in which the capillaries are plugged with degenerate endothelial cells, or in which they are composed of a layer of greatly enlarged edematous endothelial cells, so as to make the cross-section of the vessels look not unlike that of a duct, Hofbauer cells were never found in close proximity to capillaries or other vessels or in unusual numbers elsewhere in the stroma of such villi. Nor did I see any evidence for such an origin in villi taken from hemorrhagic or inflammatory cases, and although Hofbauer cells often lay near to, or even in extravasations in the villi, they were never found engorged with erythrocytes or pigmented. Nevertheless, if Hofbauer cells arise from mesenchyme cells, it stands to reason that they at least may be potentially phagocytic, and failure to find them so may be accounted for by the fact that they possess a lowered vitality in consequence of degenerative changes.

I am prompted to suggest, in connection with the question of phagocytosis, that, unless we regard the process as other than an actively vital movement on the part of the cell for the purpose of engulfing things, we have undoubtedly misused the term. That the mere incorporation of parts of cells, or even of whole cells, within the cytoplasm is not sufficient evidence for the possession of phagocytic activity on the part of a particular cell, seems to me beyond question. In some instances, for example, degenerating phagocytic leucocytes fuse with each other in groups of twos, threes, or even in greater numbers, thus forming large, multinucleated, and not infrequently vacoulated complexes. Similar phenomena can be seen also among degenerated erythroblasts and trophoblasts and in Hofbauer cells, as shown in figures 239 and 240. Although it would be incorrect to regard these degenerate fusion products as true, living giant-cells, they nevertheless simulate such very closely indeed. Moreover, when these larger fusion products fuse with an individual cell of the kind that gave rise to them, it would be quite natural to regard them as being phagocytic, while, as a matter of fact, the

process is merely one of degeneration. Another example of what we may call pseudo-phagocytosis is that represented by the isolated erythroblasts rarely seen in the stroma of a villus. In some instances two or three cells, whose boundaries for the most part still are clearly outlined, can be seen to have partly fused, forming a so-called giant cell. All transition forms and stages can be found, and were it not for this fact, the resultant large multinucleated fusion product, if seen to join with an isolated trophoblast cell, might be regarded as being phagocytic. Other instances of a similar nature were discussed briefly elsewhere (Meyer, 1918), and I am inclined to believe that the non-vital character of this kind of cell formation, which occurs under conditions of cell degeneration, needs further emphasis. It certainly would seem to be a non-vital rather than a vital phenomenon. It is indicative of degeneration and death rather than of regeneration and life.

Cells which are morphologically identical with certain stages in the degeneration of the Hofbauer cell can also be found in entirely different locations than those mentioned, as in the Graafian follicle, for example. In some of these, germinal epithelial cells which have become detached and displaced in the liquor folliculi become swollen and transparent and the nucleus takes an eccentric position. In all details of structure and ordinary staining reactions, as shown by hematoxylin and eosin, by iron hematoxylin, by van Gieson, and by Mallory, these cells are identical with phases in the typical Hofbauer cells, as illustrated in figure 241. This, however, does not justify us in designating them as such, unless we wish to extend the use of this name to degenerating and disintegrating forms of cells of very many different types and origins.

DESCRIPTION OF PLATE.

Figs. 235–237. Transition forms between mesenchyme and Hofbauer cells. No. 645, slide 3; No. 592, slide 1; No. 645, slide 3b. ×330.

Fig. 238. A phagocytic pseudo-Hofbauer cell. No. 645, slide 2. ×650.

Figs. 239–240. Fusing Hofbauer cells forming a giant cell. No. 645, slide 2. No. 985, slide 1. ×300.

Fig. 241. Pseudo-Hofbauer cells in the ovary. No. 970. ×650.

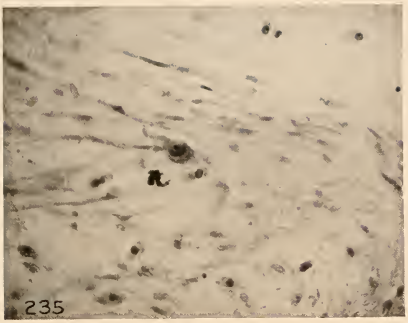
235

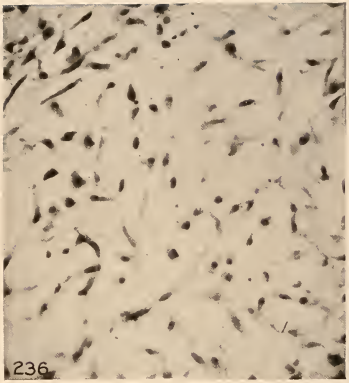
236

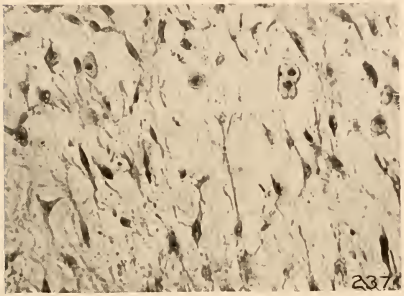
237


238


239

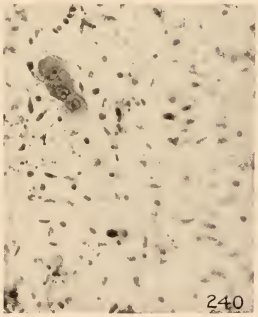
240

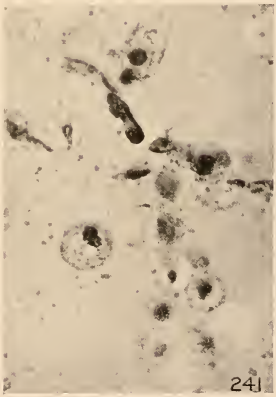
241

CHAPTER XV.

THE VILLI IN ABORTUSES.

As long ago as 1832 Seiler stated that, although he could not be certain from a magnification of 40 diameters, he did not think that chorionic villi were hollow. Although Seiler concluded even at this time that villi are filled with cellular tissue, the idea that they are hollow nevertheless persisted up to 1889. Seiler thought that the first vessels invaded the villi as late as the third month. He represented individual villi from chorionic vesicles from the fourth, fifth, and twelfth week as clubbed in form, and also pictured several good villous trees. It is of particular interest that he also represented a branching villus ending in a spherical termination, which suggests the "Zellknoten" of Kastschenko.

Müller (1847) claimed that villi may grow until they are 2 inches long by the fifth month, at which time he thought they still might cover two-thirds of the entire surface of the chorionic vesicle. However, Müller's statement that the villi are often cystic indicates quite clearly that he was not dealing with wholly normal material, and that he probably saw degenerate or even hydatiform specimens.

Robin (1854) apparently assumed that normal villi are hollow, for he stated that fibrous, fibrinous, scirrhous, tubercular, fatty, and calcareous changes of the placenta are made possible by fibrous obliteration of the cavities present in normal villi. Robin believed that such changes as these normally occur in the non-placental portion of the chorionic vesicle, and stated that unbranched and degenerate villi are found in placentæ of all ages. From his descriptions one may conclude that Robin noticed both the fibrinoid and the decidual layers of the placenta and possibly also the presence of so-called infarcts.

According to Winckler (1872), Bidder, Jr., showed that the villi are especially densely set and particularly thick in caliber at the margin of the placenta. Winckler himself distinguished three kinds of villi. He stated that atrophic villi are found everywhere, and that they never penetrate the maternal tissues beyond the closing plate (Schlussplatte) described by him. These villi, which were said to reach the cavernous spaces of the decidua, he declared to be uncovered by epithelium. Indeed, Winckler believed this to be true also of all other villi as long as they had not penetrated the closing plate of maternal tissue, into which his second class of villi were said to continue considerable distances without branching. He believed that the villi obtain a covering of epithelium only after they reach the cavernous spaces or blood-sinuses. His third class of villi, which also were said to be devoid of epithelium as long as they lay in the maternal tissue, differed from the second class only through their greater development.

Langhans (1877) emphasized the irregularities in the villi which had been mentioned by Müller, and concluded that villi always are vascularized.

Kölliker (1884) was especially impressed by the fact that the form of the villi varies so greatly that one can hardly make any generalizations. He found that

branching might occur even at right angles, and that terminal branches which do not reach the placenta remain free. These free endings were said to be present in placentæ of all ages, and to be filiform, cylindrical, pear-shaped, or club-shaped. Branching was said to be so frequent and the interlacing of these branches so common that only narrow intervillous spaces could be preserved in the placental area. Kölliker particularly distinguished branches which he called fastening rootlets (Haftwurzeln), which, according to him, were described by Ercolani and also by Langhans. These were said to always enter the placenta and to become attached to it so firmly that only considerable tension can separate the chorionic vesicle from the placenta. Kölliker stated that these fastening rootlets are commonest near the septa of the maternal tissues which separate the cotyledons, but that they nevertheless are found also in the center of the latter.

Kastschenko (1885), in a careful study of the epithelial covering of the villi, stated that they become more numerous in the region of the serotina by the end of the second month, and believed that villi grow only by means of terminal and never by lateral buds.

Minot (1889) accepted the opinion that villi are hollow during the earliest stages of development only, and stated that the villous nodules are especially common in older placentæ. In speaking of the collaginous tissue (Gallertschicht) composing the inner portion of the villi, Minot stated that it usually contains a considerable number of large, uninucleated, granular wandering cells, now frequently spoken of as Hofbauer cells and discussed more fully in the previous chapter.

Giacomini (1892), in describing a young tubal conceptus, the villi of which were not evident macroscopically, apparently regarded some of the syncytial buds as representing young villi, and later (Giacomini, 1893[c]), when considering chorionic vesicles devoid of an embryo, which had evidently undergone hydatiform degeneration, again spoke of the presence of many syncytial buds, some of which he again interpreted as being young villi.

De Loos (1897), who had no material from the first 6 months, believed that all early conceptuses are covered completely by villi which are solid epithelial buds in the earliest stages. He further believed that they become hollow later and are invaded by mesenchyme after vacuolation of the syncytial buds has prepared the way for this invasion. According to de Loos, all villi in contact with the decidua basalis become vascularized, and he distinguished between stem, or original, and fastening or nutritional villi. From a study of cross-sections of villi, he concluded that the number of villi with small caliber increases from the third to the fifth month, and that the caliber is greatest at the fourth month. De Loos also thought that the caliber of the villi decreases with the branching, and that there are relatively more villi of small caliber in full-term placentæ, which he regarded as evidence that new villi are constantly arising. Since Wiskott (1882) had found only syncytium present on villi at the sixth month, de Loos concluded that villi in older placentæ which still are uncovered by epithelium necessarily are hollow.

J. Kollmann (1898) found villi 1 mm. long and well developed in a chorionic vesicle of 6 mm. and stated that they might either be universally distributed or merely equatorial. This writer, who limited the term *ectoderm* to the Langhans layer, apparently referred the syncytium to a maternal origin. He also spoke of nonvascular villous branches about 1 mm. thick, which played the rôle of fastening villi, and distinguished two kinds, viz, ectodermic villi without a stroma and mesodermic villi with it. In 1907 Kollmann used the term *villi terminales* for villi which had traversed trophoblastic nodules, and *villi adherentes* for those the terminations of which ended in or were joined to each other by the trophoblast or a decidual plate.

Paladino (1899), although studying mainly the epithelium, stated that one of the vesicles, the age of which he estimated as 13 or 14 days, was covered completely by villi. Webster (1901), who devoted considerable attention to villi, recognized the presence of floating villi and found that villi, as a rule, are much more numerous and are branched by the sixth week. According to Webster, the mesoblast in the youngest villi is finely granular, vacuolated, and stains but faintly. He also found villi which were attached to the chorionic vesicle by syncytial stalks only, an occurrence which he attributed to failure of the mesoblast to penetrate the early plasmodial bud. He found many more small villi present by the fourth month, and stated that the mesenchyme around the vessels is usually condensed at this time. By the sixth month the villi were said to be slender and more branched, and lateral budding was said to be much less frequent. Aside from changes in the epithelium, Webster found the connective tissue of the small villi to be loose or mucoid as term was approached, and stated that the villi are more simple, possess fewer buds and branches, and are in part nonvascular in the region of the chorion læve by the sixth week.

Marchand (1903) found that villi 1 mm. long uniformly covered a chorionic vesicle 14 to 15 mm. in size, except at its mid-portion, in which a fold was located. None of the villi were said to reach the capsularis at this time and all were nonvascular. Marchand stated, however, that the mesenchyme cells frequently were arranged in rows so as to simulate young capillaries. In a second specimen, 14 mm. in size, the villi, on the contrary, were largely restricted to the region of the decidua basalis. Only isolated villi were found at the opposite poles, and but very few on the lateral surfaces. These were branched but slightly, but some of them were vascularized.

Bonnet (1903) described early lymphatics in the villi and represented a ciliated border and also a membrana limitans. It seems that Kupffer (1888) was the first to describe the ciliated border, reported later also by Marchand (1903), and even more recently by Friolet (1905), Stoffel (1905), Daels (1908[a]) and Herzog (1909), in all thin sections of the villi. Rossi Doria (1905) explained the so-called ciliated border by the manner in which the erythrocytes become embedded in the margin of the syncytium; and although a reticulum also has been described in the stroma of the villus, later histologic studies do not confirm the presence of it, of a membrana limitans, or of a ciliated border. These things, however, do not deny

the fact, confirmed also by Fossati (1906), that a network can be revealed in the stroma by the use of the Apathy, Golgi, Van Gieson, Mallory, and Cajal methods of staining. This, however, does not necessarily demonstrate the existence of a true reticulum.

Rossi Doria (1905) found young villi which had not yet been invaded by mesenchyme and emphasized that the two layers of chorionic epithelium had not yet differentiated in Peters's ovum. Nevertheless, a reference to the illustration accompanying Peters's monograph shows very clearly the presence of short villi containing stroma, even in this specimen. According to Rossi Doria, the mesenchyme begins to appear first in the villi during the second week, at which time they also begin to branch and become vascular.

Friolet (1905), who examined a chorionic vesicle 11 by 12 by 9 mm., the age of which he estimated as 3 to 4 weeks, concluded that villi arise by the extension of the fetal mesoblast into the trabeculæ of trophoblast, and regarded a brush border as a natural attribute of the syncytium. Friolet found the villi developed better in the region of the basalis and especially around the whole periphery of the mid-zone of the chorion. They were sparser in the capsularis, though without degenerative changes.

Kworostansky (1903) discussed the mesodermic structure of the villi, including the Hofbauer cells, finding the stroma much as we know it now; but Michaelis (1903) claimed to have found a granular line between the stroma of the villus and the Langhans layer, which he regarded as indicating the existence of a definite limiting membrane. Michaelis concluded that the existence of this membrane finally disposed of the idea that the Langhans layer may arise from the stroma, but anyone familiar with the appearances produced by Bielchowsky's stains between the epithelium and the stroma of the villi will question Michaelis' conclusions.

Von Lenhossék (1902) also recognized the existence of a basement membrane, and Frassi (1906), upon the basis of material stained with silver nitrate, stated that the villi in the greater number of moles have a limiting membrane, fibrous in nature, which he regarded as "identical in form and structure with that demonstrated and described in the villi of young placentæ." However, Daels (1908[a]), from the use of Weigert preparations, concluded that a layer of fibrin, the product of degenerative changes, forms between the exochorion and endochorion, and Friolet, who at first could not find a membrana limitans, said to have been described first by Langhans, found a definite hyaline zone in an abortus from the third month.

Happe (1906) found the villi of chorionic vesicles of the fourth to the sixth week branched and about 2 to 7 mm. long, but nevertheless nonvascular. The form of the youngest villi, which were about 2 mm. long, was said to be polyp-like, the ends being swollen. Most of the villi of the three conceptuses from the fourth to the sixth week showed an increase in caliber at the point of branching, the swellings being especially marked at the origin of the terminal branches of some of the villi. Happe stated that Hofbauer cells were not present in the youngest villi, and that those of the older conceptuses contained only a few.

Eternod (1909) divided the development of the villi into five phases: (1) a primordial, avillous syncytial phase; (2) an avillous trophodermic phase; (3) a trophodermic, transitory, zonal villous phase; (4) a diffuse, placental villous phase; and (5) a diffuse, chorionic, and chorion-frondosum phase. Eternod placed the conceptuses of Peters and Leopold in the second or avillous phase, in spite of the fact that both these vesicles had short villi containing mesenchyme. His third phase was illustrated by the specimens of Reichert and Ahlfeld and one of his own in which the villi had an annular or equatorial distribution. According to Eternod, the portions of the chorionic vesicle which later are in contact with the basalis and capsularis are devoid of villi during this phase, which he regarded as a transitory, but nevertheless necessary, phase. He believed that the bare areas upon the chorionic vesicles resulted from inequalities in the expansion of the chorion, and stated that in the specimen of Reichert and in one of his own, the ventral or capsular bare area is less evident than the basal or dorsal, as he called it. He believed that the ventral bare area disappeared earlier than the dorsal, only to reappear again, however, when the chorion læve developed. Although he was not absolutely decided in this matter, Eternod believed it improbable that young villi are interpolated between the older, concluding that the chorion frondosum is enlarged through the addition of villi at its periphery with far greater regularity than heretofore suspected.

The fourth phase in the development of the villi, according to Eternod, occurs in vesicles with a length of approximately 9 to 16 mm. In such the villi are branched and their terminations fused by trophoderm. The fifth phase follows the fourth very quickly, for it is said to be present in chorionic vesicles 17 mm. in size, and to be characterized by great inequalities of growth and by far greater complexity in the basal area than in that of the capsularis.

Dandy (1910), in describing a chorionic vesicle 16 by 14 by 12 mm., found the villi branched and about 0.1 mm. thick and 1.25 mm. long. He stated that they "are more numerous at the point of attachment of the Bauchstiel and gradually fade away on all sides until, finally, a clear zone results from their absence on the opposite pole. . . . From the epithelial layer of the chorionic membrane and villi numerous buds develop, some from the syncytial layer alone, others from both layers of the epithelium. These represent proliferating and new forms of villi."

Miller (1913), in describing a conceptus 0.83 mm. in greatest diameter, stated that the mesodermic villi were as yet absent, and that the Langhans and syncytial layers were structurally identical, although already distinct. Lazitch (1913) called attention to the fact that the conceptuses described by Peters, Leopold, Strahl and Beneke, and Fetzer showed the earliest villi to be mesodermal buds, and that the specimen reported by Jung already showed the presence of dichotomy. Lazitch stated that the villi are less irregular and more cylindrical in form in the fifth month, and that curious forms, such as "little-horns," are rare. She stated further that the villi became long at term and possessed fewer buds, some of which looked as though they were branches arrested in development. Lazitch also found

many ectodermic nodules or proliferating islands. In a conceptus measuring 26.5 by 22.0 by 14.5 mm., she found the villi 3 or 4 mm. long, with branches and trunks so oblique that they were almost parallel to the chorionic surface. According to her, the villi converge towards the poles of the chorionic vesicle, as stated by Eternod, but possess so variable a form that it is difficult to describe them, the caliber changing from thick to thin, from wide to narrow, from cylindrical to folded so quickly that a single branch sometimes possesses all these characteristics. She found anastomoses fairly numerous, but free villi ending in epithelial prolongations were rare. Most of the anastomoses seen resulted from ectodermic fusion, but villi separated by some distance and united by true villous bridges containing mesoderm were also seen. According to Lazitch, dichotomy occurred in 65 to 70 per cent of the villi, trichotomy in 20 to 25 per cent, and a more complex form in 10 per cent. The branching usually was at an acute angle, but branches which diverged 180° also were found. Since buds were present on the chorionic membrane, Lazitch concluded that a moderate amount of interpolation of new villi among the old undoubtedly occurs.

Johnson (1917) found the villi on a chorionic vesicle, containing an embryo with 24 somites, variable in size and 1.1 to 1.3 mm. long in the region of the chorion frondosum. Johnson stated that the villi were usually smaller at the bases, and that smaller villi, although few in number, were found among the larger.

Ingalls (1918) also found the villi on a chorionic vesicle 9.1 by 8.2 by 6 mm. to vary greatly in size and shape, but stated that the chorionic vesicle seemed to be covered by them over all of its surface. This finding of Ingalls seems to be in accord with observations upon the best-preserved and youngest specimens in the Carnegie Collection. Small chorionic vesicles, with one or two opposite bare areas, and others with sparsely set villi, are not rare, but at present we possess no evidence establishing the strictly normal nature of these specimens. Among these specimens is the vesicle represented in figure 7 (plate 1, Chap. IV). Isolated and sectioned villi from this specimen show the presence of but slight branching and rather cylindrical villi. The absence of some of the villi in this specimen is due to the mechanical means used in the removal of the blood-clot before the specimen was received.

A vesicle which, though macerated, deviates only very slightly from the normal, is No. 1878, the exterior of which is represented in figure 232 (plate 19, Chapter XIII), and the portion bearing the embryo in figure 233. As seen in the latter figure, these young villi look unusually matted and bulbous, though it must be remembered that young villi necessarily are united and covered by trophoblast in which they are implanted. Some isolated specimens of these villi are represented in figure 242, and what especially strikes one's attention is the presence of an exceedingly fine basal portion in the villus to the left. Although the caliber of normal young villi varies considerably, I do not believe that such forms as this can be regarded as strictly normal, and this belief is confirmed by an examination of sections of the villi, shown in figures 243 and 244. It is possible that maceration alone is responsible for some deviation from the normal form of

these villi, but it is not improbable that one of the specimens, shown in figure 244, illustrates incipient hydatiform changes.

In contrast with this specimen stands the vesicle, No. 2053, shown in figure 245. This is a somewhat older, but perfectly normal, chorionic vesicle, some of the villi from which are shown in section in figure 246. All of the villi of this specimen are of approximately the same development, and although trichotomy is present and simpler forms of branching are common, no marked diminution of the parent stem seems to occur at the point of branching. Moreover, the branches are approximately as large in caliber and sometimes even larger than the main trunk.

Somewhat older vesicles are Nos. 866, 2108, and 1892, represented in figures 247, 248, and 249. The first of these possesses decidedly fibrous, filiform villi, partly covered by decidua, such as are not uncommon in cases of retention. No. 2108 shows the characteristic towsled appearance of the villi in many chorionic vesicles with early hydatiform changes. The villi in these vesicles are usually longer than they ordinarily should be, and this fact alone shows that the stroma must have grown, unless one assumes, as did Daels (1908[a]), that it is mere y pulled along by the proliferating exochorion. In view of this belief, it is especially interesting that Daels thought that the stroma nevertheless might be increased instead of rarefied.

The villi in No. 1892 show early maceration changes, and that growth of this vesicle ceased some time before abortion is indicated also by a menstrual age of 54 days, although the size of the vesicle suggests an age of only 42 days. Some villi from this specimen, represented in figure 250, show the presence of maceration and also establish the fact that the villous trees have reached considerable complexity at this time. When maceration changes are more prolonged and lysis of the villi advances so far that they are structureless or almost so, one gets such shadow forms as those represented in No. 2197 (fig. 251). In these villi nothing remains but a mere gossamer, and the exterior of the entire chorion often has an eiderdown appearance, as suggested in a minor degree by this specimen (fig. 252) and to a far greater degree by No. 993, shown in figure 259. The villi of the former vesicle, the exterior of which measured 23 by 20 by 16 mm. and the interior 16 by 13 by 10 mm., although only 2 to 4 mm. long, nevertheless have reached considerable complexity in form, for a dozen or more branches sometimes leave the main stem at about the same place. Villi from other vesicles of approximately the same age may, however, be much longer, as illustrated by No. 1287, represented in figure 253, a specimen which also shows early hydatiform degeneration. In this case the relatively small size of the chorionic vesicle is evident at once upon inspection of the cross-section of the entire vesicle. The presence of matting and maceration is equally evident, and anyone at all familiar with these vesicles would not expect to find many traces of an embryo.

The presence of hydatiform degeneration is very common in abortuses of the fifth to sixth week. This is well illustrated by the villi shown in figure 255. A fairly normal villus and, for a specimen of this age, the largest found, is represented in figure 254. Many small knobs are seen along the branches of this villous

tree, to the right of which there also are some macerated villi and to the left others fused by trophoblast. The contrast in form, surface, and appearance between the hydatiform and the normal villous tree is very striking indeed, and it would seem that the hydatiform villus largely loses its power of branching, and, except for local increases in caliber, grows mainly in length.

A somewhat older, apparently normal chorionic vesicle with normal villi is No. 2361, shown in figure 256. In this vesicle, which measures 35 by 35 mm. and which has an age of about 4½ weeks, some of the villi in the basal area are very plainly hydatiform, although also macerated. Both of these changes are noticeable also in some degenerated villi shown in figure 257, but inspection of the capsular area of this chorion shows that no hydatiform change is evident *here*, nor is it evident on the external surface of the abortus represented in figure 258. This is due to the fact that the process is in its early stages, and because the conceptus is surrounded by decidua. Although the specimen has a menstrual age of 124 days, the abnormal embryo (shown in figure 206, plate 18, Chap. XIII) is but 3 mm. long and the chorionic vesicle only 35 mm. in diameter, measurements which indicate anatomic ages of 4½ and 6½ weeks, respectively. Hence, if the menstrual age can be relied upon, this specimen must have been retained 80 days. This does not imply, however, that the chorionic vesicle necessarily had been dead during all this time. Judged by the menstrual age, the fetus should be 150 mm. long, and as judged by the chorionic diameter it should be 13 to 14 mm. long instead of 3 mm., its actual length.

A second good example of the development of hydatiform degeneration, especially in the area of the basalis, in vesicles of this size is found in No. 2077 (represented in fig. 101, plate 8, Chap. IX). This vesicle, which measured 40.5 by 28.5 by 18.5 mm., was reflected from the underlying decidua, but was nevertheless left attached to it so as to expose a large field of exquisite hydatids, a portion of which is shown in focus in the center of the figure.

The eiderdown appearance due to maceration changes, which was referred to above and which is produced especially by post-partum maceration, is shown particularly well in No. 993, a portion of which is represented in figure 259. The only possibility of confusion of these changes with other conditions is that one might take an instance like this for intrauterine lysis, but usually other criteria will enable one to differentiate the two conditions. However, when the two conditions are associated such differentiation may become impossible. How very complicated the branching of the villi has already become in these vesicles of the sixth week, of a measurement of about 48 by 41 by 15 mm., is shown by the bush-like villus represented in figure 260. The thick main stem of this villus stands out in marked contrast to some of the branches, many of which are exceedingly fine and others matted and fused. Fine, thread-like villi are common, especially in the area of the chorion læve, as early as the sixth to seventh week. This is exemplified well by the specimens shown in figure 261. However, these fine villi, which usually have a fibrous, non-vascular stroma, occur also in long retention and elsewhere on the vesicle than in the area of the chorion læve. They are present in the macer-

ated but otherwise normal villous tree in figure 262, the branches of which bear decidual masses and trophoblastic nodules. Nothing could stand in more marked contrast to this and other normal villous trees than the excellent hydatiform villi in figure 263, which were taken from a vesicle 40 by 36 by 18 mm., of approximately the seventh week. This contrast is emphasized further by such normal specimens as the villi from No. 837, shown in figure 264, transition forms between which and the former are typified in the villi represented in figures 265 and 266, taken from vesicles 45 by 35 by 30 mm. and 80 by 60 by 50 mm., respectively, the former of which also shows maceration changes.

Other types of normal villi from vesicles of the eighth week are shown in figure 267. In these villi from a vesicle 54 by 50 by 43 mm., as in some older specimens to be referred to later, the most striking thing is the presence of many small knobs on all sides of the branches. This is illustrated splendidly by the villous tree shown in figure 268, which was taken from a placenta of the thirty-sixth week. There seems to be a great variation in the occurrence of this knobbing which probably does not signify beginning branching. The knobs are too numerous for this when they are at all well developed, and, since they are so uniform in size, one would have to think of a perfect shower of branches arising at the same time. Since the placentæ in which knobbing of the villi was especially evident look absolutely normal, I have come to regard its presence as typical for villi beyond a certain age, without, however, regarding those in which it is present only in a minor degree as necessarily pathologic. A villous tree in which sparse knobbing is evident only upon magnification is that shown in figure 269, in which rather miscellaneous branching is present. Other filiform villi, and a group of them from this placenta of the eighth to ninth week, are shown in figure 270.

What a contrast in external appearance villi from different placentæ may show is illustrated in figures 271 to 278, villi of the eleventh, twelfth, fourteenth, fifteenth, thirteenth, nineteenth, twenty-fourth, and twenty-fifth week, respectively. Nor are these variations in the external appearance of the villi to be attributed to age alone or necessarily to pathologic changes. The villi shown in figures 271, 272, and 274 look hydropic because of maceration, and those in figure 272 are decidedly fibrous and largely non-vascular. The chorionic membrane of this vesicle was decidedly infiltrated. The villus shown in figure 277 is also macerated, and the chorion likewise was infected, but the stroma in this case was edematous and had disappeared completely in places. Not infrequently the blood-vessels can be seen as fine white lines on the exterior of these macerated specimens. The villi shown in figure 273 came from a vesicle which had also been retained a considerable period of time, and those shown in figure 275, though filiform and fibrous, with nodules at the extremities, are also macerated.

Villi of small caliber are encountered quite frequently in apparently normal older placentæ, but are especially common in the capsular region, at a time when retrogression of the chorion læve is taking place. The contrast in form of the villi shown here is remarkable. Those in figure 278 appear like the leafless branches of an oak hung with streamers of lichen. These strange appearances are due to

the presence of many exceedingly fine branches and perhaps even of early villi, almost all of which, nevertheless, are highly vascular. Those in figure 276 are practically unmacerated, for they came from a fresh, normal abortus, and in spite of their extreme delicacy and curliness, I know of no reason to regard them as pathologic. That shown in figure 277 came from a retained infected conceptus, but to extent its form can be attributed to these facts is difficult to decide. It scarcely seems to me that such a marked diversity in form could exist in strictly normal villi, and it is possible that local conditions may to a large extent influence, even if they do not determine, the type of a particular villus.

I regret that it has not been possible to compare villi from placentæ of the same age, but from different pregnancies, in the same women, in order to determine the possible occurrence of variations in the type of villi in succeeding pregnancies. There seems to be no doubt that the diversity in form of villi increases rather than decreases with advancing age of the conceptus, and that the differentiation extends even to the last months of pregnancy. At this time, however, the more prevailing type of normal villus appears to be such as that from the thirty-first week, shown in figure 279.

Normal villi apparently vary greatly, not only in length and caliber, but also in complexity and manner of branching, and in the appearance of their surfaces, which change from smooth to extremely knobbed. It is not uncommon to find that exclusion of the villi reduces the measurement of a chorionic vesicle from one-third to one-half. This is illustrated by the specimens in figures 231 (plate 19, Chap. XIII) and 253, both of which are relatively small vesicles. Nor are these long villi always slender and unbranched, for frequently, as illustrated in figure 281, in which a more branched, bushy villus from a vesicle 70 by 50 by 40 mm. is represented, they are decidedly umbelliferous. However, as is usually the case, the villi of this specimen were somewhat unequally developed.

Extreme grades of fibrosis, as represented in figure 283 (plate 24, Chap. XVI), with vessels in varying degrees of disappearance, have been found to occur in cases of long retention in lues and also under conditions of infection. These particular villi were taken from a vesicle measuring only 55 by 35 by 20 mm. Rather unusually formed, clubbed, decidedly macerated villi from an ovarian pregnancy are shown in figure 168 (plate 16, Chap. XI). Anomalous development of villi seems to be more common in tubal, and perhaps also in ovarian, than in uterine pregnancy. In tubal specimens the villi not infrequently are but sparsely developed and bare areas seem to be much more frequent. Moreover, the chorionic vesicles are often too small in proportion to the contained fetus. This is illustrated well by No. 1151, shown in figure 280. To what extent this disproportion is the result of reduction in the size of the vesicles after death of the fetus or to retardation in growth because of an abnormal location, or to both, I am unable to say. Some of the villi of this small vesicle also show hydatiform degeneration, while others merely are macerated, as shown in figure 282.

Careful examination of young chorionic vesicles has failed to reveal villi which are purely epithelial or ectodermic, nor have I seen any formed by the extension

of mesoderm into the trophodermic trabeculæ. As soon as an area of the syncytium and the Langhans layer becomes elevated at a given point, the mesoderm accompanies them if this elevation represents a beginning villus. No matter how marked the syncytial development, I have never noticed the presence of a normal structure in the distal portion of a villus and a purely syncytial structure in the basilar portion. No matter how long or how complicated the syncytial buds became, they never were invaded by mesenchyme or became vascularized. However, this fact does not preclude the inclusion of blood within syncytial skeins or trophoblastic nodules, or within invaginations of epithelium in the mesoderm of the villi. All these appearances not infrequently are seen in specimens in which there has been considerable growth of syncytium or of the Langhans layer, but I have never seen evagination of these two layers without a mesodermal core. No matter how long vascularization of a villus is delayed, and in some cases this seems never to occur, such villi otherwise have the same structure as the rest, just as trophoblastic development on the early villi seems to be universal and not visibly influenced in its first stages by the location of the embryonic disk or the shape of the early conceptus. These facts undoubtedly are not without significance for the nutrition of the early conceptus. The universal presence of villi establishes conditions much more favorable to circulation of the surrounding fluids, besides very materially increasing the area of absorption. Hence I do not believe that bare areas in the basal and capsular regions of a young conceptus can be regarded as normal.

Branching of the villi occurs exceedingly early and does not seem to develop any special plan or be limited to any particular plane. The angle generally is an acute one, probably because of the fact that the branches aim to reach the trophoderm or the decidua. It is not at all uncommon to find several branches arising at the same level, or they may leave the parent trunk in quick succession.

Although considerable variation in size and complexity of the villi seems to exist even in normal chorionic vesicles, these differences are not necessarily so pronounced in the same as in different specimens. However, one not infrequently meets with simple, unbranched villi among others of great complexity, but I did not get the impression that, except in the first few months, much interpolation of villi occurs later in development. It is quite surprising how large a placental area can be formed by a single villous tree, and placental differentiation occasionally seems to be present in chorionic vesicles with embryos of a length of only 17 mm., which implies an age of only about 7 weeks. Indeed, it does not seem improbable to me that close observation will show that some placental diffentiation exists as early as the sixth week.

DESCRIPTIONS OF PLATES.

Plate 21.

Fig. 242. Isolated villi from No. 1878, shown in figures 232 and 233, plate 19, Chapter XIII. ×4.5.
Figs. 243–244. Appearance of villi in section, same specimen. ×7.5.
Fig. 245. Cross-section view of an entire normal vesicle with cyema and adnexa. No. 2053. ×3.
Fig. 246. Section of villi from same. ×36.
Fig. 247. External appearance of conceptus, showing filiform villi. No. 866. ×1.5.
Fig. 248. External appearance of conceptus, showing presence of hydatiform villi. No. 2108. ×2.25.
Fig. 249. Sparsely villous area from No. 1892. ×1.5.
Fig. 250. Isolated villi from same specimen, showing maceration changes. ×3.
Fig. 251. Isolated shadow or gossamer villi. No. 2197. ×9.
Fig. 252. External appearance of same specimen. ×1.5.
Fig. 253. Cross section of No. 1287. ×1.5.
Fig. 254. Villi from No. 1466. ×2.25.
Fig. 255. Hydatiform villi from No. 2233. ×4.
Fig. 256. Section of chorionic vesicle with hydatiform villi in basal area. No. 2361. ×1.5.

Plate 22.

Fig. 257. Isolated villi from No. 2361, showing both maceration and hydatiform degeneration. ×6.75.
Fig. 258. External appearance of abortus, same case. ×0.75.
Fig. 259. Changes in external appearance of villi, due to maceration alone. No. 993. ×3.
Fig. 260. Isolated villous tree from same vesicle. ×3.
Fig. 261. Isolated filiform villi. No. 1639. ×3.
Fig. 262. Isolated villous tree. No. 2336. ×6.75.
Fig. 263. Fine hydatiform villi. No. 1797. ×3.
Fig. 264. Normal villi. No. 837. ×2.25.
Fig. 265. Transitional villi between normal and hydatid. No. 432. ×2.25.
Fig. 266. Transitional hydatiform villi. No. 437. ×2.25.
Fig. 267. Normal, knobbed or budded villi. No. 1063. ×2.25.
Fig. 268. Villous tree from a normal specimen, illustrating many small knobs. No. 2335. ×6.75.
Fig. 269. Villous tree showing few buds or knobs. No. 1840*a*. ×2.25.
Fig. 270. Filiform villi and a portion of the vesicle from the same specimen. ×3.
Fig. 271. Villi showing maceration changes. No. 2348. ×6.75.

Plate 23.

Fig. 272. Villi showing maceration changes. No. 2339. ×6.75.
Fig. 273. Villous tree with smooth villi. No. 2253. ×6.75.
Fig. 274. Villous tree with knobbed villi. No. 2372. ×6.75.
Fig. 275. Filiform villus. No. 2326. ×6.75.
Fig. 276. Fine, frowsy villus. No. 2414. ×6.75.
Fig. 277. Massive villous tree. No. 2283. ×6.75.
Fig. 278. Knobbed, curly villi. No. 2384. ×6.75.
Fig. 279. Mossy villi. No. 2249. ×4.5.
Fig. 280. Tubal conceptus (No. 1151), showing disproportion between the chorionic vesicle and the fetus, sparse development of the villi, and some hydatiform degeneration. ×1.5.
Fig. 281. Villous tree from No. 651*b*. ×2.25.
Fig. 282. Villi from No. 1151, shown in figure 280. ×3.

242

243

244

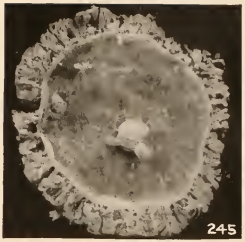
245

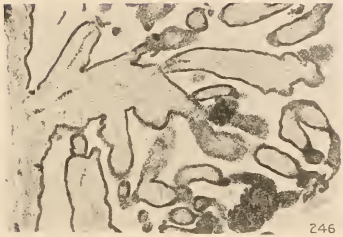
246

247

248

249

250

251

252

253

255

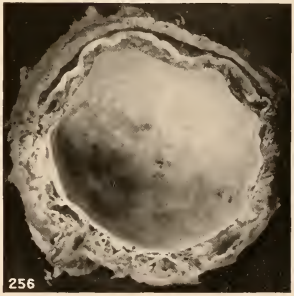
256


254

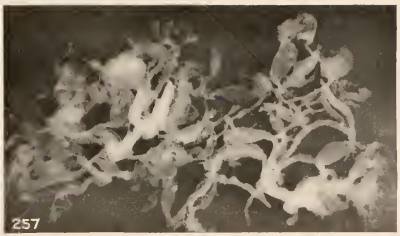
257

258


259

260

261

262

263

265

264

267


268

266

269

270

271


272

273

274

275

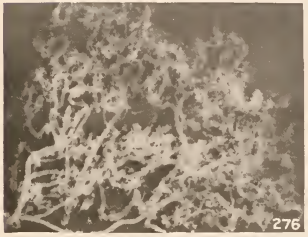
276

278

279

277

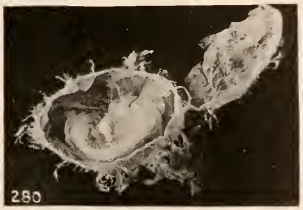
280

281

282

CHAPTER XVI.

VILLOUS NODULES.

That the occurrence of numerous small nodules on the villi of young conceptuses must have attracted the attention and aroused the curiosity of early embryologists, one can not doubt. They often are so conspicuous, so spherical, and, when located on the tips of the villi, also so striking in appearance, that they could not be easily overlooked. Hence it does not surprise one that Müller (1847), in his interesting monograph on moles, described them, and that Sömmering (1799) had represented them, as figure 284, reproduced from the latter, shows. Müller remarked that he did not always find them, and that they sometimes were absent in normal specimens. As will appear later, this is a very interesting and probably also a significant observation. Langhans (1877), in connection with a thoroughgoing microscopic examination of the placenta, spoke of these appendages as "insular nodules of maternal tissue," and also represented one. Langhans spoke of them as being 1 mm. in diameter, and said that their white color and turbid nature distinguished them from the more transparent swellings of the villi themselves. Their form was said to vary, and some were found to be located on the curved, enlarged processes of the villi, while others capped these processes. Microscopically, they were said to be composed of large, oval, round, polyhedral, spindle- and star-shaped cells, usually a little flattened, which could easily be distinguished from the fetal cells by their size alone. Langhans stated that the cells composing these islands were decidual in origin, but that their nuclei were the size of the nuclei of the epithelium which separated them from the stroma of the villus. Langhans regarded them as decidual prolongations which penetrated the fetal placenta, and which hence might appear on the surface of the chorionic membrane itself.

As long as the exact origin of the placenta had not been decided at this time, it need not surprise one that Langhans should speak of these nodules as being composed of maternal tissue. Moreover, everyone who has examined conceptuses still implanted in or aborted with the decidua will admit that often it is impossible to draw a definite line of separation between the cells composing these nodules and the adjacent decidua. But it is not unlikely that exact differentiation between the two tissues is possible by the use of histochemical methods.

Kastschenko (1885) referred to the insular nodules of Langhans merely as cell nodules (Zellknoten), and stated that they are always composed of chorionic epithelium. It is not clear to me, however, whether Kastschenko did not, after all, confuse these nodules with syncytial buds. Besides, he stated that, although these cell nodules develop from the epithelium of the chorion, they later become serotina cells.

Heinz (1888) stated that the "insulæ of maternal tissue" are especially common in placentæ from the third to the sixth month, and that he never found them at term. He concluded that they are always composed of maternal tissue, that

they are firm, and are located halfway between the serotina and the tips of the villi. In figures 3 to 5 accompanying his article, good representations of sections of villi with nodules partly embedded in the stroma of the villi are found. Heinz believed that they became separated from the rest of the maternal tissues by the growth of the villi, and thus became isolated and related to the latter. He thought that as the villi develop they begin to devour the maternal tissue with which the implanting conceptus is in contact, and that these nodules represented the only remnants of these maternal tissues. While Langhans thought that these nodules are formed merely by the invasion of the maternal by the fetal tissues, Heinz believed that they resulted from an invasion of the maternal tissues by villi, with accompanying destruction of the former. In support of his opinion, he referred to the well-known destructive power of the villi first revealed by Virchow, who called attention to the invasion of the maternal blood-vessels by fetal villi.

Minot (1889), contrary to Heinz, declared that the nodules within the villi are commoner in old placentæ, a conclusion which prompts the inference that Minot may have regarded them and the so-called *decidual islands* of contemporary literature as identical.

Hofmaier (1890), in describing his Case V, a conceptus 20 by 5 mm., containing an embryo of 4 mm., stated that small nodules the size of the head of a pin were present everywhere on the villi. These nodules the author regarded as composed of decidual cells.

Kossman (1892) also spoke of insular nodules of maternal tissue and made fine drawings of sections cut 3 to 4 μ thick. He declared that it was plain that these nodules were composed of decidual tissue in which some of the villi became embedded, his idea being that portions of decidua became isolated from the rest and then were retracted by villi which lost their attachment to the decidua. Kossman stated that he never found nodules covered entirely by syncytium, as reported by Kastschenko, and doubted the occurrence of such. He further concluded that the cells composing these nodules do not simulate those composing the Langhans layer nearly as closely as Kastschenko had stated.

Crosti (1896) also spoke of these nodules and referred to them as *appendici durate*, saying that they become hydropic in retained conceptuses.

In discussing conceptuses of the sixth week, Webster (1901) stated that he could distinguish three kinds of "Zellknoten." One was said to be composed of "undoubted decidual cells, along with a mass of cells which evidently belong to the proliferated Zellschicht at the end of an attached villus." These were said to be surrounded more or less by syncytium and might contain portions of it and also of the villi. Webster regarded this form of nodule as due to decidual elevations upon which the villi were implanted. A second form of Zellknoten was said to be composed solely of closely placed villi, along with several processes or strands of the syncytial layer. The third variety was said to be composed of villi surrounded by fibrin.

Pfannenstiel (1903) thought that the villous nodules are composed partly of decidua, but Rossi-Doria (1905) frankly stated that they are nothing but proliferations of the Langhans layer, especially common on the tips of the villi. Rossi-Doria nevertheless believed that the syncytium also may take part in their formation through proliferation by amitosis. This investigator, who made a careful examination of a conceptus 9 by 8 mm., stated that the trophoblastic nodules which form on the ends of the branches of the villi begin to appear after the second week of pregnancy. He concluded that they form not only on the free, but also on the fastening villi (Haftzotten), and doubted whether syncytium really can invade these nodules, as held by some investigators. J. Kollman (1907) also reported them in a conceptus 8 weeks old, and showed villi joining after passing through the nodules, forming what he called "villi adherentes."

If these nodules, found in such number on villi of many abortuses, and represented so well in the conceptus from Sömmering, shown in figure 284, are decidual in origin, then it is clear that their substance is in fact preformed, and if they antedate the formation of the villi it would seem that they might appear very soon after the formation of the latter. If, on the other hand, they are products of the epithelium of the villi, then a short interval after the formation of the latter is necessary to enable such accumulations to form. No one has held that they are direct products of the ovular ectoderm, which secondarily become related to the villi, and, from what has been described in the earliest known implantation stages, it would seem that this is not the case. Although the ectoderm of the implanting ovum apparently is extremely active, probably especially so during the invasive stage of the implantation, these nodules apparently do not arise directly from it.

In the description of some of the cases, and also in publications, I have sometimes used the term *trophoblastic nodule.* The cells composing these nodules, however, undoubtedly arise from the Langhans layer, the syncytium usually being absent; and since the nodules really are not remnants of the early trophoblast, it would perhaps be better to relinquish this term altogether and to refer to them merely as villous nodules. However, I have been greatly puzzled to find a good name for these special masses of cells arising from the Langhans layer. The term *insular nodule,* introduced by Langhans, would be entirely acceptable did it not carry with it the possibility of confusion with decidual islands, for if they really were islands, confusion would be particularly likely, because Langhans thought that they were maternal in origin. The term *cell-nodule* (Zellknoten), introduced by Kastschenko, also is not without objection for the same reason. The designation "appendici durate" used by Crosti does not recommend itself either, because one scarcely can speak of most of them as appendages, for the simple reason that they are almost wholly embedded in the stroma of the villi. Then, too, they are so small that one scarcely feels justified in speaking of them as hard. In very young villi the designation *trophoblastic* or *trophodermic* nodules would seem quite appropriate, especially since they frequently contain syncytial masses among the Langhans cells; but later on, long after the trophoderm or trophoblast has ceased to exist as such, this designation seems far less appropriate.

Nor is the term *villous* nodules wholly unobjectionable, for they are not, as a rule, composed to any appreciable extent of villi, though a group of 6 or more villi not infrequently pass through or are united by them. But since it seemed the least objectionable term, I have adopted it.

That these nodules really have the origin attributed to them by Rossi-Doria seems undoubted, although it is not impossible that rarely they may contain some adhesions or inclusions of decidual cells. These would be entirely accidental, however, and would result from portions of the decidua adhering to or being surrounded by the proliferating Langhans cells, and thus becoming included in the nodules. If, as Rossi-Doria stated, and as I believe, they arise from the Langhans layer of the villi, then the fact that they frequently contain masses of syncytium within their interior or at their margins offers no difficulties to those who believe that the syncytium arises from this layer. Nor would it be difficult to explain the presence of included syncytial masses within the nodules upon the assumption that the syncytial layer has an origin independent of the Langhans layer. But in any case, an origin from either of these layers would imply that they might be expected to be especially numerous in any condition in which unusual activity occurs in these layers. Hydatiform degeneration is such a condition, and that these nodules are especially numerous in many of the specimens of hydatiform degeneration can easily be demonstrated. Whenever the epithelial proliferation is very pronounced, however, it does not manifest itself in the formation of nodules, but in the production of irregular trabeculæ, garlands and even trellis-works of cell-cords, such as represented in figure 9 (plate 1, Chap. IV). It also is conceivable that these spherules might form during the stage of spontaneous regression of hyperactivity of the epithelium or in the earlier stages of hyperactivity; for a more or less spherical nodule manifestly could result only from proliferation in *many* instead of predominatingly in one or two directions only.

I have also found these nodules common upon the ends of the villi, as is shown so well to the left in figure 285 and still better in figure 116 (plate 10, Chap. VIII). But, as noticed by previous investigators, and as shown in figures 285 and 286, they are not limited to these locations. I have never found them stalked, but always sessile, and embedded in the stroma of the villi even, as shown in figure 287. Indeed, not infrequently the epithelial proliferation, instead of resulting in an elevation upon the surface of the villi, extends largely into the stroma, so that sections of nodules were completely surrounded by it. All manner of transition stages between extravillous and intravillous locations were seen, and more or less hemispherical accumulations also were found directly upon the chorionic membrane.

It is not at all uncommon to find these nodules located nearer the base of a villous tree, as shown in figures 288 and 289. This does not, however, imply that those so located were not apical once, for they may have formed on a short side-branch which they completely surrounded. Not infrequently several villi, even up to half a dozen or more, may be united by and terminate in a single nodule, as shown in figure 291; or they may penetrate it, as represented by Kollman. Not infrequently considerable groups of nodules are found in a single small region,

as illustrated by the teased preparation shown in figure 290. It is not uncommon to find half a dozen or more nodules in section in a single field of the microscope under low magnification of cross-sections of villi, and when they are so numerous as this the villi in these areas may look matted in consequence.

They never seem to attain any considerable size, seldom becoming larger than 1 to 2 mm. This would seem to imply that, whatever the cause of their formation, the process is self-limited. I have never seen a chorionic vesicle in which large areas were capped or united by these proliferations, as are the early villi by trophoderm, for example; but they are decidedly resistant and persist long after the villi have degenerated. Nor have I ever seen them detached, for they seem to retain their hold even after the villi become decidedly macerated, as illustrated in figure 292. I, too, have found them most common in relatively small chorionic vesicles, and never have seen one on mature, normal villi.

Since I used no special microchemical methods, I can add but little to what is recorded in the literature regarding their structure. I do not believe, however, that the syncytial inclusions are syncytial in origin, or that they are ordinarily degeneration products. They seem to arise directly from the cells composing the nodules. Hence, as stated elsewhere (Meyer, 1918), this conclusion, if correct, offers further confirmatory evidence of the origin of the syncytium from the Langhans layer. It can easily be demonstrated that the villous syncytium is penetrated rapidly, as a rule, by proliferation of the underlying Langhans layer, and all stages in this process of protrusion of the cellular accumulations, through the underlying syncytium, can be found. Since marked proliferation of the Langhans layer can occur without hyperactivity on the part of the syncytium, it also is clear that the syncytium may for this reason alone fail to take part in the formation of these nodules. No matter how numerous the syncytial buds in cases of exquisite early hydatiform degeneration, for example, I have never seen appearances suggesting in the slightest the origin of these nodules from syncytium. It is difficult to form an opinion of their functional significance, but it does not seem improbable to me that they may result from an attempt on the part of the younger branches of the villi to gain contact with the decidua and so restore better nutritional conditions.

DESCRIPTION OF PLATE.

Plate 24.

Fig. 283. Cross section of intensely fibrous villi from No. 765*b*. (See Chapter XV.)
Fig. 284. Conceptus showing numerous trophoblastic nodules. (After Sömmering.)
Fig. 285. Portion of chorionic vesicle showing an apical villous nodule to the right and others elsewhere. No. 1495*a*. ×2.4.
Fig. 286. Chorionic vesicle showing numerous small villous nodules. No. 2197. ×1.6.
Fig. 287. A villous nodule completely surrounded by stroma, except at its free surface not shown in the figure. No. 556.
Fig. 288. A villous nodule near the base of a villous tree. No. 2365. ×7.2.
Fig. 289. Villous nodules and lichen-like streamers on a villous tree. No. 2204. ×7.2.
Fig. 290. A group of teased villi bearing numerous trophoblastic nodules. No. 2225. ×4.8.
Fig. 291. Several villi ending in a single trophoblastic nodule. No. 308. ×4.8.
Fig. 292. A macerated villous tree, one branch of which bears a noduleon its extremity. No. 2472. ×7.2.

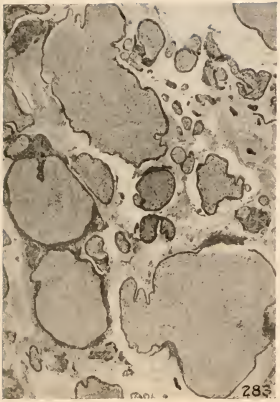

284

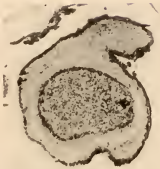

287

CHAPTER XVII.

CHANGES SUGGESTIVE OF LUES.

Since Schaudin's discovery, attention naturally has been directed very largely from placental lesions of syphilis to the presence of spirochætæ. But unfortunately the hope that the presence of this organism would form not only a crucial but also an infallible criterion for the determination of fetal lues does not seem to have been realized. The search for spirochætæ seems to have been attended by such uncertain results that a routine examination of the placenta has not even been recommended by prominent obstetricians. Slemons (1917[b]), for example, stated that the presence of spirochætæ in the placenta can be demonstrated in only about one-third of the cases of lues, and Mraček (1903) found no histologic evidence of lues in 82 out of 160 placentæ from syphilitic women. Slemons found the examination of stained sections more satisfactory than a gross examination of the villi, and stated that a proliferative inflammation of the vessels in the terminal villi constitutes the beginning change in lues. The lumina are said to become obliterated, the connective tissue of the villi increased, and the villous epithelium not only proliferates, but also invades the stroma.

Some uncertainty still seems to attach to the use of the Wassermann test, for Williams (1917) emphasized that lues may develop in an infant even when this test applied to the mother was found negative at the time of its birth. As stated by Williams, others also have observed the contrary condition of a positive Wassermann in the newborn, later becoming negative spontaneously. Slemons, however, found the Wassermann reaction and the placental histology to coincide in 95 per cent of 345 cases, and in 99 per cent even, if misleading cases of toxemia of pregnancy were first excluded. Lues was present in 10 of the 345 cases examined by Slemons, who emphasized the fact that areas in which the structure of the placenta is normal may be present. From these things it seems that, regarding the existence of lues in early specimens, one is thrown back again upon the old question whether fetal lues in its early stages is characterized by any lesion or by any group of lesions which can be regarded as pathognomonic. Since it is recognized that the existence of maternal lues does not necessarily imply its existence in the fetus, the importance of independent criteria regarding its existence in the fetus becomes much greater. This is true in spite of the fact that belief in the transmission of paternal lues direct to the offspring without infection of the mother now seems to be quite generally abandoned. This was inevitable as soon as the cause of lues became known.

Even in this day there seems to be no agreement upon what constitutes valid histologic evidence of the existence of fetal lues, but the opinion that recurring abortion of a macerated fetus, in the absence of other causes, is strongly indicative of lues seems to be held quite generally. It was the belief of obstetricians and gynecologists that abortion or premature labor occurred in a large percentage of cases in which maternal lues antedated conception by several years. Seitz (1904[a])

credited Lutowski as finding that such a result inevitably followed, and himself found gestation interrupted in 91.6 per cent of such cases. Seitz classified 50 per cent of these interruptions of gestation as premature, 16.6 per cent as immature, and 21 per cent as abortions. Fuoss (1888) also quoted Ruge as saying that the fetus is still-born in 80 per cent of the cases of lues. The number of cases in which children which were born prematurely, but living, died soon after birth, is also surprisingly large in the series of Thomsen (1905), in spite of recourse to anti-luetic treatment, and Slemons (1916) reported that all luetic children among 17 which were prematurely born died.

Thomsen found that lues could be excluded with considerable certainty in only 11 out of 27 controlled cases which had given birth to macerated fetuses. But more important still is the fact revealed by examination of Thomsen's protocols, that 24 out of 27 still-born fetuses of luetic mothers were macerated. It should be added, however, that no evidence of the existence of lues was present in 8 of these 24 macerated fetuses. Premature labor occurred in only 62 per cent of Thomsen's series of luetic mothers, as compared with 91 per cent in that of Seitz, and 100 per cent in the series of Lutowski. However, Urfey (1901) cautioned against the assumption that repeated abortion in the later months of pregnancy always is due to lues, and held that a non-specific chronic endometritis is not infrequently the cause. This indeed seems highly probable when considering the marked changes which may be produced in the decidua by chronic inflammation. Unfortunately, Thomsen's protocols do not state whether the evidence of lues was based on gross or upon microscopic examination or upon both. This is especially regrettable, because this series included cases which bore no gross but only microscopic evidence of the existence of lues.

The foregoing statement abundantly emphasizes the lack of correlation existing between the effects of lues upon the life of the conceptuses and the continuation of the gestation and the histologic and bacteriologic evidences contained in the conceptus. If neither spirochætæ nor characteristic histologic changes can be found in many of these prematurely born and macerated, luetic conceptuses, then one would seem to be compelled to assume not only that death of the conceptus is due to the influence of toxins, but that toxins may cause its death without producing any recognizable structural change in either placenta or fetus. The use of anti-luetic treatment may be responsible for the differences in the varying frequency with which luetic mothers give birth to luetic babies, and it is possible that the use of antiluetic treatment may affect the time of appearance of fetal lesions. Surely, a chronic systemic disease, which is believed almost invariably to cause the death of the conceptus and premature birth, especially after the sixth month of gestation, can scarcely be presumed to produce no structural fetal changes whatsoever before this time. This would seem to be possible only if the maturing fetus showed a decidedly diminishing resistance, both to the luetic disturbances and to infection.

How early luetic lesions may appear in the fetus has been especially considered by Engman (1912), who thinks that many placental lesions which have been

referred to lues probably may not be such. This opinion was expressed also by Williams (1917), and Thomsen called attention to the fact that luetic changes in the fetal organs, so common in the seventh to the tenth month, are exceptional in the first 6 months of gestation. But it is well to remember in this connection the caution of Mraček (1903) that cases of abortion occurring in the third and fourth, and especially in still earlier months, usually do not come to hospitals for treatment, and that observations on the placental lesions in lues hence have been made very largely upon material from the seventh and eighth months. Mraček found luetic placental lesions as early as the fifth month, and Slemons (1916) slightly earlier than this. Since 10 of the placentæ in a series of 78 examined by Mraček weighed from 200 to 300 grams, it is evident from this fact alone that he dealt with some rather early cases of gestation. In a routine examination of 400 placentæ, Slemons found luetic lesions present in 6 out of 17 premature deliveries in which the fetus had a length of 30 to 40 cm. and a weight of 1,000 to 2,000 grams. Since fetuses in the Carnegie Collection with a length of 30 to 40 cm. have an age of approximately 34 weeks, and those weighing 1,000 to 2,000 grams an age of 28 to 35½ weeks, it is evident that the weight of these luetic fetuses examined by Slemons was relatively low, as might be expected.

The appearance of fetal luetic lesions may depend upon many factors, and Thomsen's observation, that luetic inflammatory changes in the extra-abdominal portions of the umbilical vessels never were present before the fifth and sixth month, can not be regarded as final, in view of the differences of opinion concerning the specific nature of these changes. Thomsen also implied that the vascular were accompanied by other changes in the fetal organs.

That changes which are entirely comparable to what has been called "granulation cell proliferation" by E. Fraenkel (1873), or "granular hyperplasia" by Ercolani (1871, 1873) occur in very young villi, is abundantly evident from an examination of specimens in the Carnegie Collection. However, it does not therefore follow that such specimens are necessarily luetic. Thomsen, too, recognized that these changes in the villi, to which, and edema, he attributed the disproportion in weight between fetus and placenta, possibly occur in other conditions, but it is significant that he never found them present in controls. Thomsen further emphasized that this hyperplasia of the stroma of the villi is never so pronounced in other conditions as in lues, and that the degree of hyperplasia of the stroma and of infiltration of the extra-abdominal portions of the umbilical vessels run parallel with the severity of the infection. Thomsen also concluded that, although other diseases can cause similar changes in the umbilical vessels, such occurrences are extremely rare. Mraček found changes in the cord present in only 10 out of 78 cases of lues, and Simmonds (1912) in 20 out of 40 full-term labors in which the presence of maternal lues had been established. Moreover, Simmonds found inflammatory changes in the cord present in 32 cases in which lues was excluded, and the fact that vascular changes have been found to be uncommon near the placental, and spirochætæ near the abdominal end of the cord still waits for explanation.

If such changes as these alone could be regarded as pathognomonic of lues, it would be a relatively easy matter to determine its presence. Thomsen also laid great stress on the presence of abscesses in the placenta, accompanied by hyperplasia of the stroma, and stated that he had never observed such a coincidence in any condition except lues, adding that although he found placental abscesses only 8 times in 100 cases in which maternal or fetal lues had been established, he never found them present in 1,250 placentæ in which lues could be excluded with considerable certainty. Thomsen further stated that infiltration of the membranes, although not specific, nevertheless is quite characteristic of lues, and is most marked when the syphilitic infection is severe.

If Thomsen's conclusion were justified, one would be compelled to believe that fetal lesions which are pathognomonic of lues nevertheless exist. It may be recalled in this connection that Schwab (1905) also emphasized the necessity for considering the "*tout ensemble*" and claimed that a fairly reliable diagnosis of lues can be made from an examination of the placenta alone. According to Schwab, the lesion complex consists of (1) a disproportion in weight between the fetus and the placenta, with an excess in weight of the latter; (2) hypertrophy of the villi; (3) perivascular cirrhoses; (4) inconstant proliferation of the syncytium; and (5) arteritis of the decidual vessels. Schwab recognized that any of these lesions may be present in other conditions, and laid special emphasis on the total picture. Solowij (1902) had gone much farther than this, however, for he held that lues is the cause of most placental lesions, even in the cases in which neither parent shows evidence of the presence of the disease in active form. Solowij even regarded this as established clinically, and held that lues alone produced the changes in the arteries described by him.

Slemons believed that the most trustworthy evidence of the existence of fetal lues is found in the chorionic villi, which are clubbed and the vessels of which are not apparent in luetic cases. Slemons asserted that "when delivery occurs prematurely, the placental findings are significant; for in that case the question of syphilis may always be fairly raised." Since Slemons found placental evidences of lues in 10 per cent of 400 placentæ accompanying a living child of the fifth or later months, it would seem that a higher percentage of cases from the earlier months would contain evidences of lues, unless it can be assumed that early conceptuses are more resistant to infection. The failure to find spirochætæ in conceptuses before the fifth month would seem to suggest that no lesions can be expected before this time unless they can result from the influence of toxins. Should this be considered as impossible and the failure to find spirochætæ be accepted as conclusive evidence of their absence, then lues apparently must be excluded as a cause of abortion before the fifth month, except in so far as the disease may affect the health of the mother adversely, or cause changes at the implantation site.

While considering the probable factors in the termination of gestation in the case of abortuses in the Carnegie Collection, it became evident that mechanical interference—therapeutic or otherwise—and hydatiform degeneration seemed to be the predominating causes. These can be recognized with some certainty, but

the customary difficulty was encountered regarding lues. Consequently, a series of abortuses from the group of fetus compressus, in which lues was present in mother or offspring, were selected for special study. From the findings in these cases, and taking the entire specimen as well as the clinical history into consideration, an attempt was made to isolate a group of specimens which might be regarded as probably luetic.

Even if it be incorrect, as variously stated, that a large percentage—even up to 95 per cent—of all long-retained macerated abortuses are luetic, the mere fact that a very large percentage of luetic fetuses are retained for some time before being aborted introduces a special difficulty into the examination of them. It is relatively rare that a satisfactory teased preparation of the villi can be obtained even in early conceptuses. Hence, for this reason alone, the existence of clubbing of the villi, even if present in early cases, is much more difficult to determine. This is true of all specimens which have been retained sufficiently long so that the villi have become macerated, glued, and more or less compressed. Such glueing, or matting, apparently can arise in a relatively short time, for it is present in placentæ which accompany fetuses which are not markedly macerated. Although often not due to lues, this glueing makes a gross examination of the villi very difficult and unsatisfactory.

So-called typical, granular hyperplasia of the stroma of the villi can be found present in very small chorionic vesicles and probably can be caused by other things than lues. But obliterative arteritis was not seen in any very young chorionic vesicles, although present much earlier than the fifth month. In some of these cases the obliterative changes were present not only in the vessels of the villi, but in those of the chorionic membrane as well. It was noticed but rarely in the umbilical vessels, but since the entire cord was included in relatively few specimens, no thorough examination could be made regarding this matter. Considerable thickening of the chorionic and amnionic membranes as a result of fibrosis was quite common, however. When present in a marked degree, the fibrous change in the stroma of the villi and the obliterative changes in the vessels, both of those in the membranes and of the larger villous stems, often were so typical that on the basis of these alone, especially when they were accompanied by some infiltration with mononuclear leucocytes, one is justified, I believe, in regarding these specimens as very probably luetic. The placentæ of such of these specimens as had been retained for some time after fetal death showed the presence of coagulation necroses—so-called infarction—with the presence of considerable masses of degenerate trophoblast, and usually also of some calcification. The accompanying decidua also not infrequently showed the presence of fibrosis and later also of endarteritic changes in the decidual vessels.

If spirochætæ are absent in the conceptus before the fifth month, then it would be unjustifiable to assume that the cases showing these changes were definitely leutic, unless fetal lesions can arise in the absence of the specific organism within the conceptus. Nevertheless, I feel justified in emphasizing that these morphologic changes seem to be characteristic even if not pathognomonic of lues.

Whether they could be produced before the advent of the organism itself I am not in a position to say. But if lues can lead to the premature birth of a living child and also to retention of conceptuses which died because of the existence of maternal infection, it would seem that the presence of this serious disease in the mother could be expected to affect the life of the conceptus more profoundly in other ways than through the direct effect of the characteristic lesions themselves. Moreover, it would seem that when other causes can be excluded clinically, one would be justified in suspecting the existence of maternal lues. I am aware of the fact that retention alone, wholly regardless of the cause of death of the conceptus, has been suggested as responsible for changes similar to those attributed to lues, but I am quite certain that the changes in some of the cases here concerned undoubtedly are not due to retention.

The gross appearance of these specimens is so well known that a full description is unnecessary. The fresh decidua is frequently markedly macerated, the placental area of the chorion, when differentiated, is pale and firm and its maternal surface furrowed, the ridges being formed by fibrinoid masses and badly preserved decidua and the sulci by pink, better-preserved decidua. The membranes are degenerate or necrotic even, and thickened, especially in the placental area. The amniotic fluid usually is reduced considerably in quantity and the fetus greatly macerated. The cut surface of the fixed placenta shows the presence of some intervillous blood, in spite of the existence of large waxy areas, which, upon microscopic examination, are found to be composed of degenerate decidua, trophoblast, so-called infarcts, and apparently fibrous areas constituted by large villous stems and coalesced villi.

As is well known, a history of repeated abortion is common in these cases and the presence of lues frequently unsuspected. In one such case, in which attention was directed to the probable nature of the specimen, further inquiry and examination revealed the existence of relatively recent maternal lesions, including mucous patches. Although this may be a mere coincidence, I am quite certain that the subject deserves further attention.

The placental changes in most of these specimens remind one somewhat of the placenta accompanying a fetus 12 cm. long, reported by Welch (1888) under the caption, "Hyaline metamorphosis of the placenta," and it is interesting that Welch stated that the changes in the stroma of the villi in this case reminded him of those attributed to lues by Fraenkel. Although the few cases in the Carnegie Collection in which the infant was known to be definitely leutic were of considerable value in this matter, those in which lues was suspected or even reported, or in which the Wassermann test was negative or positive, were of little value, because of the well-known disagreements between the clinical findings and the occurrence of luetic lesions in the fetus.

CHAPTER XVIII.

SOME ASPECTS OF ABORTION.[1]

In considering the possible reasons for the interruption of gestation, one must not only distinguish between the alleged and the real causes, but must also bear in mind the fact that we still speak of the occurrence of spontaneous and habitual abortion. It is scarcely necessary to emphasize that there can, of course, be no such thing as spontaneous abortion, for no gestation can be presumed to be interrupted without a cause, whatever its nature. This is self-evident, and I gladly would let the matter pass without comment were it not for the fact that the conclusion that a certain abortion was spontaneous often ends further inquiry.

Hegar (1904) directed especial attention to the presence of pathologic changes in the conceptus as a cause of abortion, thus clearly recognizing that the difficulty may not lie in the maternal organism, although it must not be forgotten that many of the so-called pathologic changes present in conceptuses nevertheless may be due to adverse influences, somatic and maternal rather than germinal in origin. However, since the presence of anomalies in the fetus usually is determined by inspection of the gross specimen, it is evident that only the presence of external deformities generally is noted. But from dissecting-room experience alone we know that pronounced anomalies commonly are present internally without having become evident externally. This may be true of such extreme anomalies as situs viscerum inversus even, and when one considers how much more disadvantageous for the development of the cyema such a condition must be than such minor things as polydactyly and brachydactyly, hare-lip, cleft palate, or club-foot and hand, it becomes apparent that *internal* must far more frequently be the cause of fetal death than the *external* anomalies. The latter have long been recognized as probable causes of fetal death and the subsequent termination of gestation merely because they are so evident. It is true that external not infrequently are associated with internal anomalies, but the effect of the latter upon the life of the cyema probably has been underestimated largely because they can be revealed only by painstaking examination. However, the frequent presence of marked internal anomalies in the bodies of individuals who have passed middle life, or even the proverbial threescore and ten, also indicates that the rôle of external anomalies in the termination of gestation probably has been overestimated. For aside from such major defects as the various forms of cranio-rachischisis, it is difficult to see how minor external anomalies, such as polydactyly or brachydactyly, hyperphalangism, cleft palate, or hare-lip or anarthroses and synarthroses, in themselves can lead to the death of the fetus and hence to the interruption of pregnancy. The same thing is true of anomalous renal development, except in so far, perhaps, as it is extremely pronounced or associated with anomalies in the organs of internal secretion. Cardiac anomalies, especially septal defects, and internal hydro-

[1] The word *abortion* is here used in the general sense of an interruption of gestation, regardless of the time or the cause.

cephalus, on the other hand, probably would very seriously affect the further development of the cyema, even if not evident externally.

It is strange that we know so little regarding the anomalous development of the chorion as a factor in the termination of pregnancy. That the cause for the latter not infrequently may be sought in the ovum or spermatazoon one can scarcely doubt, for otherwise one would have to assume that the human reproductive cells are characterized by a unique immunity and perfection. That this is not the case has been abundantly shown for the human spermatazoon, but we are still quite ignorant concerning the occurrence of pathologic unfertilized ova. Jones (1897), however, came to the conclusion that they were common, and Detleftsen (1914) reported that abnormal ovaries commonly occur in guinea-pig hybrids—that is, crosses between the domestic and the wild cavy species. Furthermore, Huber (1915) found abnormal fertilized ova which disintegrate even before implantation in the rat.

Crosti (1896) believed that abortion in the first 8 or 10 weeks is always due to defects inherent in the ovum, and Szasz (1903) stated that fetuses from the early months of gestation may show malformations not found in the later months. If this be true, then it demonstrates what one would seem to be able safely to assume, that the existence of some fetal anomalies makes continued development impossible. Such anomalies, hence, never should be met in the newborn, but should be found in the early fetus only. This conclusion of Szasz would also seem to be justified if fetal anomalies were more common in the earlier than in the later months of pregnancy. This was the conclusion reached by Mall (1917), who found that localized anomalies are twelve times as common in abortuses as are monsters among fetuses at term. But since not only acardiac monsters, but also small nodules, such as reported by Slemons (1917[a]) under the caption "Fetus amorphous anideus," may sometimes survive until term, it is difficult to substantiate the assertion of Szasz at present, except perhaps indirectly by the greater infrequency of anomalies at term and by the occurrence of such heretofore unknown specimens as No. 1843 (Meyer, 1919[e]), in which survival was manifestly impossible. Such vesicles as this, wholly devoid of a cyema, apparently never can continue to develop for any length of time, and, as far as I can learn, never have been observed before; for the large hydatiform degenerations, composed of portions of a chorionic vesicle and villi only, really belong in another category.

No one will doubt that the presence of certain developmental anomalies tends to fetal death and hence also to early abortion, but until more material is available it will be impossible to make reliable statistical deductions and determine the relative frequency with which various anomalies occur in the different months of pregnancy or even at the time of birth. However, there is no doubt that small primary nodular forms, which are true developmental anomalies, such as those shown in figures 205 and 206 (plate 18, Chap. XIII), are far more frequent among young than among older specimens in the Carnegie Collection. This, however, does not wholly confirm the statement of Szasz, though it is in entire accord with Mall's conclusion. If one considers the external form and the structure

of these small masses, one feels quite certain that some of them belong in the category of rare, full-term specimens such as that reported by Slemons. Few of these probably survive till term on account of an insufficient blood-supply, and the occasional survival of one in association with a normal, full-term fetus is an extremely interesting occurrence.

One need only to regard the question of abortion historically and recall the practices of primitive races to be reminded of the fact that in such a matter as this human custom, conduct, and frailty play a very large rôle. Nor need attention be directed to the practices of primitive or uncivilized peoples alone, even if Robinson's (1919) estimate that 1,000,000 criminal abortions are performed annually in the United States can not be accepted without question. Since the number of annual births in the United States, estimated on the basis of the registration area, is only about 2,400,000, this would imply that 1 criminal abortion is performed for every 2.4 births. Or, to put it another way, if somewhat less than 40 per cent of all pregnancies terminate prematurely, as Pearson (1897) estimated, then, according to Robinson, 1 out of every 4 pregnancies is terminated criminally. But the highest estimates of the ratio of abortions to pregnancies are those of Taussig (1910) and myself. Those of Taussig were based upon the experience at a St. Louis gynecological clinic, and mine upon about 700 selected histories from the Carnegie Embryological Collection. From these data it seems that there is 1 abortion to about 1.7 to 2.3 pregnancies. Hence, if we accept Robinson's estimate of the incidence of criminal abortion in the United States as 1 to every 2.4 births, it would follow that in the women considered by Taussig or myself about 70 per cent of all pregnancies which terminated prematurely were terminated criminally! Furthermore, upon the basis of Pearson's estimate of prenatal mortality, the criminally induced actually would exceed the abortions due to all other causes by over one-half, while upon the basis of Mall's earlier estimate of a prenatal mortality of about 20 per cent, the criminal abortions in the United States, as estimated by Robinson, actually would exceed the grand total of abortions from all causes by 200,000 cases annually!

It is regrettable that we are left partly to surmise regarding the exact incidence of prenatal death. Ahlfeld (1898) estimated that there is 1 abortion for every 4 or 5 normal births. This would be 1 to every 5 or 6 pregnancies. A. Hegar (1863) estimated that 1 out of 8 or 10 pregnancies ends prematurely. Michailoff (1897), as reported by Chazan (1904), gave a frequency of 10.18 per cent, and Keyssner (1895) a frequency of 15.1 per cent, or 1 abortion to every 5 or 6 births, an estimate confirmed also by Williams (1917). According to Lechler (1883) and Chazan (1904), this was also the figure reached by Busch and Moser (1840), upon theoretical grounds alone.

Stumpf (1892) found 1 abortion for every 3.56 pregnancies, a mortality of 28 per cent, and Keyssner still less, or 1 abortion in 9 pregnancies, or a mortality of but 11 per cent.

Since the causes responsible for postnatal mortality differ so widely from those which operate before birth, it is wholly unlikely that a curve of postnatal mortality,

if extended through prenatal life back to conception, as done by Busch and Moser and by Pearson, would tell the truth. Indeed, it could do so only by the merest chance, for the curve of postnatal mortality is based upon a totally different set of conditions. Besides, it undoubtedly is true that the rate of mortality varies from month to month in prenatal much as it does from decade to decade in postnatal life, although probably in a totally different way. It could fail to do so only if a perfect uniformity of conditions obtained throughout the period of gestation. Since this is not the case, the curve of postnatal mortality is of course based upon a totally different set of conditions.

Upon theoretical grounds, Pearson (1897) decided for a mortality of 37.6 per cent, or 1 abortion in every 2.7 pregnancies, an estimate which Mall (1917[c]) regarded as too low. This opinion of Mall would seem to be confirmed by Taussig (1910), who, from data obtained in 201 gynecological dispensary patients, concluded that there was 1 abortion to every 2.3 pregnancies, a mortality of 43.4 per cent; and also by the present series of almost 700 cases, which indicates a prenatal mortality of 58 per cent.

If we take the statement of certain social workers or propagandists, who allege that a conservative statement of the total number of criminal abortions annually performed in the United States is 250,000, then on the basis of Pearson, 1 in every 6, and on the basis of Mall's earlier estimate, 1 in every 3 interrupted pregnancies, is terminated criminally. However, Taussig (1910), on the basis of histories obtained from 293 patients at the St. Louis gynecological dispensary, reported that only 36 out of 371, or approximately 10 per cent, of the abortions in these women were *admittedly* mechanical. The histories in the Carnegie Collection present similar evidence, but these percentages undoubtedly are too low.

It should not be overlooked, however, that the surprisingly high percentages of prenatal mortality in the above women undoubtedly do not represent the actual life conditions of the whole population. They merely represent the conditions in women who have aborted. How much the inclusion of all those women who never had aborted would have lowered these percentages it is impossible to say, but one scarcely can doubt that the lowering would be considerable. After a fuller consideration of the literature, Schultz, page 183, estimated the prenatal mortality among the general population at 22.0 per cent, a figure somewhat higher than Mall's *earlier* but considerably below his *later* estimate.

Since the women in the present series do not constitute a dispensary group, but very largely also represent cases in private practice, one can not contemplate the amazing prenatal mortality in these women without the profoundest concern, not alone because of its significance upon the birth-rate, but also because of its relation to the wellbeing of these women and the effect of such practices upon public morals. Nor can one be quite certain that the indicated antenatal mortality is on the decrease or that it is high in these women alone, for Malins (1903), for example, believed that abortion is more common among the economically more fortunate classes. This opinion seems to be shared also by others. Nothing even remotely like it seems to be known in the case of the domestic animals,

except in such conditions as contagious abortion. Aside from this affection, abortion in some domestic animals seems to be a rather rare phenomenon, having occurred, according to Malins, only 131 times in a series of pregnancies which resulted in 3,710 living colts. This is a ratio of only 1 abortion in every 29.1 pregnancies, or less than one-seventeenth the frequency found in the women in the present series.

But it is very clear that we lack sufficient data upon which to base reliable opinions regarding these matters. Social workers undoubtedly far overestimate the prevalence of criminal abortion, though it should at once be admitted that professional obstetricians very likely underestimate its frequency, for their opinion is based upon a rather different experience. However, that the estimate of the former is entirely too high can be shown also by their estimate of the deaths due to abortion. It has been stated publicly, for example, by enthusiasts for birth control that there are 8,000 deaths due to abortions, annually, in New York alone, and 50,000 in the entire country. Since the total number of deaths from *all causes* among *all women* between the ages of 15 and 40, regardless of whether they are child-bearing women or not, as estimated on the basis of the registration area according to the United States census for 1916, was only 139,642, one-third of all deaths in women of these ages would, according to these advocates, be due to criminal abortion!

No mention was made of the occurrence of previous abortions in 11.4 per cent of the 697 selected cases of abortion in which the clinical histories were quite complete and apparently reliable. This small percentage stands in marked contrast to the findings of Malins (1903), who stated that 63.4 per cent of the women in a selected series of 2,000 hospital and private cases had not aborted before, and that of the childless 3.2 per cent had aborted. Only 3 cases among the 697 were specifically stated to have suffered no previous abortions. In the rest of the 11.4 per cent the matter was not mentioned. Only 1 of these 3 women had borne children, and the remaining 2 were recorded as having had neither previous abortions nor children.

Malins, who found 14.2 per cent sterile women in a series of 2,000 selected private and hospital cases, stated that 3.1 per cent of these had aborted, but had had no children. Although it is not recorded in 78 cases that the women had either had children or abortions, one can not assume that they had neither, else the percentage of primiparæ would be 11.4 as compared to 4.86 per cent in the series of Franz (1898). Graefe (1896) found only 2 out of 38 cases in primiparæ, a percentage of 5.5 per cent, and stated that Litthauer found only one such case. However, such small groups as these really can not contribute anything of statistical value, except when combined. Out of Hellier's series of 1,800 married women belonging to the laboring classes, 184, or over 10 per cent, never had been pregnant before, and 1,616, or 89.7 per cent, had one or more abortions. The latter was true of 92.9 per cent of the cases in the Carnegie series, and although repeated abortion occurred in a considerable percentage of these women, only 5.6 per cent had aborted more than 5 times.

The above 78 cases also represent the women in this series of 697 cases who may not have aborted *previously*. However, all of them had aborted once, or they would not be represented in the Carnegie Collection. The only exceptions to this statement may be a few instances of spurious pregnancy in which hemorrhage or membranous dysmenorrhea may have been taken for genuine evidence of pregnancy because of an irregularity in the menstrual history.

A single previous abortion had occurred in 56.6 per cent of 608 cases, and two previous abortions in 22.9 per cent. About 79 per cent of these women, as contrasted to the 66 per cent of Stumpf's series of 446 cases, had aborted once or twice *previously*, and 69.1 per cent once or twice only. Hence the great majority of the specimens in the present series came from cases of first and second abortions, as indicated in table 13. However, one should, I presume, recall in this connection that it always is easy for a woman to say that she has aborted only once or not at all. Yet the records probably are not very defective in this regard, for, as will appear later, most of the women were relatively young.

As shown in table 14, 394 out of 692 women, or 56.9 per cent, aborted before the beginning of the fourth month of gestation. Hence it is evident that most of the conceptuses from this series are small. Only 3 cases aborted during the last 2 months and 78.6 per cent before the beginning of the fifth month. The marked increase in the frequency of abortion from the first to the second month, as well as the marked decrease from the sixth to the seventh month, is not without significance. The same factor probably is at least partially responsible for both. Knowledge confirmatory of the fact that she is pregnant would come to a woman with the advent of the second month, while the viability of the fetus would act as a deterrent to interference with the gestation especially after the fifth month.

Only 33.4 per cent of the women of this series aborted in the third month, as compared to 59 per cent in the series of Dührssen (1887), and to 42.7 per cent of Franz's (1898) cases, taken only, however, from the first 7 months of gestation. However, since only 3 of the present series of 692 cases aborted during the last 2 months, and only 14 during the last 3 months, it is quite immaterial whether or not the cases in this series from the last 3 months are included, for 98.2 per cent aborted before the seventh month. Although Franz stated that only 15.45 per cent of the cases collected by him had aborted before the twenty-eighth week, the summary given at the end of his paper would seem to make this percentage 76.9, which compares fairly well with the 98.2 per cent found in this series.

That no existing collection of specimens or of histories correctly represents the actual facts in the world at large would seem to be indicated by a comparison of the results obtained by different investigators, as given in table 15. With the exception of the results of Stumpf and myself, and some of those of Lechler for the third, fifth, sixth, and seventh months, the divergencies are striking—probably irreconcilable—and suggest that a far larger series of cases than that dealt with at present is necessary before any results closely approximating the truth can be obtained. The only regard in which the findings of Franz, Hellier, Stumpf, and myself are in surprising agreement is the average number of pregnancies to abor-

tions per woman. This was 4.77 in Franz's, 4.59 in Hellier's, 4.15 in Stumpf's, and 4.58 in the present series. Hellier's group came largely from the laboring classes of Leeds. The Carnegie series comprises women from widely different stations in life and from widely scattered communities, and those of Franz and Stumpf came from different regions of the European continent. Since these four series included 3,762 women, it would seem that one can assume that the average of these groups, or 4.54 full-term pregnancies per abortion, probably approaches the truth very closely indeed. This truly remarkable agreement found in women from three countries also seems to imply that the proportion of births and abortions per woman is largely, if not wholly, independent of nationality and environment.

A very large proportion of the women in the histories of whom the matter was recorded were childless. This, as shown in table 16, was true of 143 out of 585 cases, or of 24.4 per cent. Hellier found the childless to form only 1.3 per cent of his series of 1,800 gynecological cases from among the working classes of Leeds. Approximately the same percentage of the present series as was childless had but a single child. A somewhat smaller number had two children, the childless and those who had one and two children forming 67.1 per cent of the whole group. Yet one woman had borne 14 and another 16 times.

Franz found that primiparæ formed only 4.86 per cent of his series of 844 cases, but if we could assume that all the cases in the Carnegie series which were reported as childless actually were primiparæ, then the percentage of the latter in this collection would be 24.7. However, since such a marked discrepancy exists between the percentage recorded by Franz and the latter figure, it is more than likely that a considerable number of the women recorded as childless in this series were not primiparæ after all. This is indicated also by the fact that only 78 out of 697 women, or 11.2 per cent, of which number the 585 included in table 16 form a part, were unrecorded as to offspring or previous abortions. Only 2 additional cases were recorded as not having suffered an abortion previously. Consequently only 80 out of these 697 women, or 12.9 per cent, *apparently* were in their first pregnancy.

Franz found abortion twice as common in multiparæ as in nulliparæ. From clinical cases Graefe (1896) concluded that women who had borne three times aborted most frequently, but he added that this finding was not confirmed in his private practice. Stumpf found the ratio of abortions to births 1 to 5.1 in primiparæ, but only 1 to 2.21 in multiparæ having up to and including 5 children, and 1 to 2.22 in multiparæ having more than 5 children.

As shown in table 16, the average number of abortions per woman is practically the same in the childless and in those having had one child, but with the second child a rise of almost 16 per cent takes place, for the average number of abortions per woman changes from 2.5 to 2.9. Another smaller advance is shown to occur with the fourth child, although there are relatively slight fluctuations in women having had 4 to 7 children. Since the number of women having borne 8, 9, and 10 children was so small, no conclusions could be drawn regarding them.

In all groups except the first two, composed of women having none or but one child, the average number of abortions lies between 2.9 and 3.6 per woman. Moreover, this ratio is practically the same in the groups having borne 2, 4, and even 6 children, but since the total number of cases involved in this table is only 585, the number in each group is necessarily small, being over 100 in the first three groups only.

Upon comparing the total number of *previous* abortions suffered by 697 women with the total number of children borne by them, we find that there was 0.84 *previous* abortion for every child. However, if the 697 abortions represented by the specimens which brought these women to our notice be included, then the ratio becomes 1.3 instead of 0.84 abortion per child; yet Malins, on the basis of 2,000 selected private and hospital cases, found but 1 abortion to every 5 children. A similar proportion is recorded also by Hellier, who, on the basis of 6,974 births and 1,288 abortions in 1,800 married women, found one abortion for every 5.5 children. Keyssner (1895), on the basis of 9,381 births and 1,194 abortions, found a ratio of but 1 abortion to every 8 births. Although the statistics of Keyssner were taken from the clinics, polyclinics, and gynecological journals, and those of Malins from selected private and hospital cases, one is at a loss to explain the great disparity between them and those in the present series.

In this series of 697 women with 1,351 children and 1,843 abortions, there were 1.3 abortions for every child or 1 abortion for every 1.7 pregnancies. This result differs somewhat from that recorded by Taussig for the cases in the St. Louis Gynecological Clinic, which was 1 abortion for every 2.3 pregnancies. The lack of correspondence between the estimate made by Taussig and that in the present series is not surprising, for the Carnegie series is fairly representative, being composed to a considerable extent of material obtained from the general practitioner. However, it is surprising to find that this ratio of children to abortions is lower in these women than in the cases from a dispensary, unless we accept the opinion of those who hold that abortion is more common among the economically more favored classes.

The relative constancy in the ratio of abortions to children in families with 3 to 7 children seems to imply that whatever the factors responsible for the interruption of pregnancy, they act with unexpected regularity in women of widely differing ages and with decidedly different reproductive histories. This would seem to imply that in these women there is no tendency to limit the family to any particular number of children through interference with the gestation, for were such the case abortion should be more frequent in connection with the particular number to which it is attempted to restrict the size of the family. This could fail to be true only if we could assume that this supposed limitation in the size of the family were due to causes other than interference with the gestation.

Only 29.1 per cent of the 607 women whose ages were given were less than 25 years old, but, as shown in table 17, 56.1 per cent were less than 30 and 77.4 per cent less than 35 years. In the series of Stumpf this was true of 23.3, 51.7, and 71.8 per cent, respectively. Upon considering the relation of the different age

groups as shown in table 18, nothing unusual appears. The average number of abortions per child is highest in the 15 to 19 year group, in which it is 4.8. In the 20 to 24 year group it has dropped to 1.6, and then, as might be expected, a gradual decrease, both in the number of children and of abortions, is noticeable in each half-decade from 15 to 50 years, where it is 0.14.

The number of abortions per woman ranges from 1.1 in the 15 to 19 year group to 2.7 in the 40 to 44 year group. There is a decided drop in this average in the 45 to 49 year group, but since this group contains only 3 cases, it must be disregarded. In the 15 to 19 and 20 to 24 year groups, the average number of abortions per woman exceeds the average number of children, but after that the reverse is true, these ratios being almost equal in the 25 to 29 and 30 to 34 year groups. The greatest disproportion between abortions and children is reached in the 40 to 44 year group, in which the ratio is 2.08 children for every abortion.

Taussig found 870 full-term births in 293 women, the average number of children per woman being considerably higher, or 2.9, instead of 1.9 as in this series. The average number of abortions in 201 women was 1.8, instead of 2.6 as in this series. Hellier (1901) found that 1,800 selected married women had borne 6,974 children, or an average of 3.87 each, and in Franz's series of 4,255 women, the average number of children per woman was still higher, or 4.77, as compared with 1.9 of the present series of 697 women.

The series of 446 cases of Stumpf form a striking contrast to the present one, for, although the actual number of cases of pregnancy in essentially the above age groups ranges from 89 in the group over 40 to 365 in the 26 to 30 year group, the ratio of abortions per pregnancy differed markedly, as an inspection of table 18 will show. Aside from the entire lack of correspondence between the two sets of percentages shown there, especially as far as women below 20 are concerned, in whom the difference is practically 1,600 per cent, Stumpf found two maxima of abortions to births, instead of a gradual decline as in the Carnegie series. Stumpf's first maximum occurred between 26 and 30, and the second after 40. It also is peculiar that although Stumpf's ratios are 200 to 1,600 per cent below mine in women below the age of 40 years, they are 200 per cent higher than mine after this age. Since the discrepancies are so great, it is very likely that a number of unknown factors are involved. Hence it is hardly worth while to try to reconcile the remarkable difference.

The 21 *admittedly* unmarried women in this series had 25 abortions, or 1.2 abortions per woman, and 11 children, or 0.5 child each. Both of these figures are below the average for the *professedly* married women, yet, as might be surmised, the ratio of abortions to children is considerably higher in this group of the unmarried than in the case of all groups of the married except the 15 to 19 year group. It is 2.2 abortions per child. Since the average number of abortions per child in the 15 to 19 year group of professedly married women is more than twice as high as in the small group of the unmarried, it would seem that there is something in the marital relationship of women of these years, or in the attitude toward abortion

on the part of the married, which is responsible for this difference. However, until a far larger group can be obtained, such a surmise remains unsupported.

In contrasting the number of abortions per woman in 344 women giving birth to conceptuses classed as normal with those suffered by 264 women who aborted conceptuses classed as pathologic, we find (table 19) that the former had sustained an average of 1.7 abortions and the latter only 1.79, or practically the same number. However, upon referring to table 20, it will be seen that a slight tendency to earlier abortion of pathologic conceptuses is indicated. Yet table 21 indicates that abortion of a conceptus classed as pathologic strangely enough seems to have had no discernible effect in reducing the number of children per woman. This is, of course, contrary to what one should expect, and undoubtedly contrary also to the facts. The 256 women giving birth to conceptuses classed as pathologic really had more children on an average than the 337 who had aborted conceptuses classed as normal, for women giving birth to conceptuses classed as pathologic had an average of 2.3 children, but those aborting conceptuses classed as normal only 2.1 children. Hence, one would seem to be led to the startling and impossible conclusion that pathogenicity of the conceptus, whatever its cause, does not reduce, but enhances, fertility!

It may be recalled in this connection that Hellier found that 96.5 per cent of the 1,800 married women who had abortions "almost up to the maximum" nevertheless later bore one or more children. But the explanation for the above anomalous and self-contradictory result probably lies in the fact that many conceptuses classed as pathologic very likely are merely macerated normal specimens, the form of which was changed during long retention.

The women aborting conceptuses classed as pathologic aborted somewhat earlier, for 86.7 per cent of them had done so before the beginning of the fifth month of gestation, as compared with 76.5 per cent of those who aborted specimens classed as normal. Since the groups in table 20 contain 402 normal and 290 pathologic cases, this difference in percentages of early abortions might seem to imply that conceptuses classed as pathologic actually had developed under unfavorable conditions, died, and were aborted sooner. Since, as previously stated, most of these are young, while those classed as normal are relatively older, one may assume that young conceptuses are retained relatively longer after death than older ones. This conclusion is borne out also upon comparing the *menstrual* with the *estimated* or anatomic ages of specimens grouped as normal and pathologic. From such a comparison it is evident that the specimens classed as pathologic were retained relatively longer after death than those classed as normal, and that had they been aborted as soon after their death as were those classed as normal, a still larger percentage of them would have been aborted before the fifth menstrual month than actually was the case.

From table 22 we learn that 50 per cent of the women aborting conceptuses classed as pathologic and 60.9 per cent of those aborting conceptuses classed as normal were below 30 years. Hence the women aborting conceptuses classed as pathologic would seem to have been somewhat older.

Upon contrasting the conditions in the small group of negro women, as revealed in tables 18 to 22, with those in whites, one is not justified in drawing any definite conclusion regarding the possibility of racial differences, because the group of negro women is so small; but nevertheless it strikes one's attention that self-induction of abortion is unrecorded among them. Psychic and accidental mechanical causes also are unrecorded. Therapeutic intervention occurred in only 1.3 per cent of the colored women, but in 6.6 per cent of the white. As shown in table 18, families with single children seem to be rarer among these negro women, but the average number of children was less, a fact in agreement with the statement in our last national census to the effect that, with the exception of the cities of Baltimore and Washington, the average family among negroes in cities of a population of 10,000 and over is somewhat smaller than that among whites.

Abortions among the negro women also seemed to fall somewhat later in gestation than among the white, only 65.4 per cent of them aborting before the fifth month, as contrasted with 79.7 per cent of the white women. The negro women, however, did not differ materially in age-grouping, as shown in table 22.

Could one take the figures deduced from the records of specimens classed as pathologic at their face value, one would be justified in concluding that but a very small percentage of the abortions here concerned were due to interference on the part of the patient. It also must be remembered that a smaller proportion of abortuses classed as pathologic than of those grouped as normal probably result from interference by the patient. This follows from the inference that a normal gestation may be presumed to continue uninterrupted in its development far more frequently than a pathologic one, a conclusion reached also by Giacomini and by Mall.

As shown in table 23, abortion was recorded as self-induced in approximately 34 per cent of 198 histories selected from the Carnegie Collection, in which other causes than disease are mentioned. But these percentages do not truly represent the situation, for such interference no doubt occurred in a far larger percentage of cases, for the simple reason that physicians are disinclined to record and report, and patients still more disinclined to state, such a fact. That the alleged causes are not always the true ones is a matter of common knowledge.

The interference was alleged to have been medicinal in only two of these cases. In the rest it was said to have been mechanical. This was true of 68 out of 90 cases in which the termination of the gestation was alleged to have been due to medicinal, accidental, or psychic causes or to mechanical interference on the part of the patient. This is a percentage of 70.8. Associated diseases were mentioned in only 54 out of 252 cases, or in 21.4 per cent. The abortion was recorded as having been spontaneous in 2 cases only, although no cause was recorded in 463 of the 697 cases. Therapeutic abortions formed 24.7 per cent of those in which a cause was assigned.

A comparison of the part played by various alleged causes of abortion as recorded in histories classed as normal and pathologic is given in table 24. What particularly strikes one's attention is the fact that tumors and displacements of

the uterus are recorded more frequently as a cause of abortion among specimens classed as normal and self-induction more frequently among the pathologic cases. In a higher percentage of these the presence of associated diseases was mentioned, however, and miscellaneous and psychic causes also were recorded. Interference might be presumed to occur more frequently in cases involving pathologic conditions, yet it is recorded more frequently in connection with conceptuses classed as normal. It is not unlikely that the explanation given for the apparent increase in fertility with the increase in frequency of abortion applies also to this contradictory result. However, therapeutic intervention was somewhat more common among the pathologic in a somewhat larger percentage of which no cause for the termination of the gestation was assigned. The latter was the case in 76.6 per cent of 264 pathologic and in 63.3 per cent of 344 normal cases out of a total of 608. Miscellaneous causes, such as exertion, purgative drugs, coitus, etc., were assigned as frequently in the one as in the other class of cases, but the total number in each group is so small that these percentages probably are not very reliable.

That the abortion was inevitable in many, even if not in the majority, of the so-called spontaneous or habitual cases, is corroborated by the fact that most of the abortuses in the pathologic division are young, by far the greater majority of the older fetuses falling among the normal. Moreover, many of the larger conceptuses also are received fresh, and in the case of those which were received as the result of such complications of pregnancy as toxemia, pernicious vomiting, placenta prævia, febrile conditions, and other similar causes, these causes are recorded.

There often is no way of accounting for the termination of the so-called spontaneous cases from an examination of the conceptuses alone. However, it was very interesting to frequently find that the chorionic vesicle and the decidua had undergone pronounced changes in the case of abortions which were reported as spontaneous. Many of these fell into the first four groups of Mall's classification and showed the presence of hydatiform degeneration, thus contradicting the statement of Hegar (1904) that hydatiform moles almost invariably occur only later in pregnancy, and confirming the statement of Solowij (1899), who claimed that clinical experience teaches that hydatiform moles are aborted *in toto* only in the first months of pregnancy.

Indeed, pathologic conditions of the chorion and decidua seem to be especially frequent causes for the termination of pregnancy during the early months, although one must recall that decidual and possibly chorionic changes may be the consequence of previous interference alone. It may long remain impossible to determine the true or original cause of antenatal death, for the secondary or immediate cause may completely mislead one. Hegar (1902) concluded that the cause of abortion not infrequently lies in the decidua alone, and that the death of the cyema usually can be shown to be due to degenerate changes in the villi. He came to this conclusion because he found no evidence of pathologic changes in the chorions of some abortuses. That endometritis and other uterine conditions pre-existent to the implantation may be responsible, especially for early abortions,

one can not doubt, for the changes in the endometrium and decidua frequently seem to be so profound.

Certain alleged minor causes to which recourse is had by patients recur so frequently in the histories that this fact alone suggests that they probably are not the true or ultimate causes. Among such causes, a slip or a slight fall on the stairs and minor psychic disturbances may be cited. That psychic disturbances may interrupt gestation seems quite likely, but they probably merely are the immediate, not the ultimate, cause of the abortion. They could be regarded as the ultimate cause only if the conceptus is aborted well preserved, for otherwise one would have to assume that psychic causes can produce uterine contractions sufficiently severe to cause the death of the conceptus, and that later, after the conceptus has become macerated, recurring similar psychic disturbances finally effect the expulsion of the macerated specimen.

Since infectious diseases no doubt very often are the immediate rather than the ultimate cause of abortion, as Harris (1919) found in the case of influenza, it undoubtedly may be assumed that many of the abortions caused by such and similar complications would have occurred later. They remind one of the defective fruit which persists insecurely upon the tree until a sudden gust of wind showers it to the ground. The findings of Harris regarding the effects of influenza and pneumonia upon gestation, seem to be confirmed also by the small series of cases of abortion among the present series in which the abortion was attributed to an infectious disease. But in considering the alleged causes of abortion, one must bear in mind that when a woman knows of a plausible exonerating reason for the termination of the gestation she has every incentive to state it. That this is the case is indicated by the various strange and, to the initiated, highly improbable or even impossible reasons often assigned for the interruption of a pregnancy.

Associated constitutional or venereal diseases were recorded in only 76 out of 697 selected histories. In 463 of these 697 cases the cause of abortion was not given. In 52 out of the 76 cases in which associated diseases were present, other causes for the termination of pregnancy also were recorded. Hence the suggestion that the associated diseases probably were merely the immediate or incidental causes in these cases seems decidedly probable.

What strikes one's attention in the perusal of some of the histories is the long period during which many of these young conceptuses really were in process of abortion, as indicated not only by the *anatomic* as contrasted with the *menstrual* age, but also by the repeated hemorrhages. Since in most of these cases the abortion probably was inevitable from the beginning, it would seem that the conclusion of Giacomini, reached also by Mall, that one should not temporize with such cases, but promptly relieve the patient of an abnormal, dead or dying conceptus, would seem to be justified. That some general practitioners apparently are beginning to realize this situation is instanced by Dr. Bacon, who, in connection with a recent specimen donated to the collection, wrote: "This makes the second or third case in which I have apparently delayed an abortion and, when the gestation finally was ended, was rewarded with an abnormal child for my pains. I

wonder if it really pays humanity?" However, the practitioner no doubt meets with great and often insuperable difficulties in determining the exact status of affairs, and in the present state of our knowledge he must temporize so as not to be led into unjustifiable procedures. There is no doubt, however, that conservative symptomatic treatment, no matter how unavoidable because of our inability to determine the condition of the conceptus, often is directly opposed to the best interests of the patient.

No case confirmatory of that reported by Jackson (1838) came to my attention among those in the Carnegie Collection. It seems strange that one of a pair of human twins can be aborted weeks or even months before term and the other continue in uninterrupted development to the end of normal gestation. Moreover, since the authenticity of Jackson's case rests solely upon the statement of "a very intelligent lady" who was "too intelligent to be deceived and too honest to deceive," one scarcely can feel convinced by it alone. However, Jackson stated that Nancrede had observed a similar case in which one fetus was aborted at 4½ months and the other went to term, and Fuertes (1879) reported such an instance as one of superfetation. In this case a woman of 27 years gave birth to a male child on March 13 and to a female on July 27. The former, which lived only 15 days, was regarded as having been born in the seventh month of pregnancy, and the latter at full term. Bonnar (1865) also reported a series of cases of this sort in connection with a review of the question of superfetation. It is true that the alleged *denouement* in dystocia and also in cases of interrupted labor seems to suggest that even vigorous contractions of the uterus are not inconsistent with retention of attachment by the placenta, but expulsion of one with retention of the other fetus for some months afterward would seem to fall into a somewhat different category.

In examining the histories one is impressed by the frequent cases of so-called habitual abortion. These sometimes begin with the married life of a young woman and continue more or less interruptedly throughout her child-bearing period. This is illustrated by the cases in which a birth at term was followed by several abortions, and by another birth at term and again by abortions. Regarding some of these cases, it is clearly stated that the patients took steps to terminate the unwelcome pregnancies, and in others the histories concerned mothers who had given birth to 6 or more, even up to 13 children, and then suffered one or more successive abortions, without a history of previous abortions. This is illustrated by the following seven cases, for example, in which the women had borne 6, 8, 9, 10, 11, 12, and 13 children, respectively. The first woman had experienced 4 successive abortions, the following 5 one abortion each, and the last, 3 successive abortions. In some of these cases it is fairly evident that weariness with such heavy burdens of child-bearing probably was responsible for the termination of pregnancy, while in others abortion may have resulted from exhaustion due to a large series of quickly succeeding gestations, and in still others to pathologic or other causes. Experience with higher domestic animals, too, would seem to

suggest that abortion not infrequently follows too closely repeated pregnancies, especially under the stress of advancing years.

If the condition of the uterine mucosa at the time of implantation of the impregnated ovum may show variations in structure at all comparable to those seen in deciduæ accompanying abortuses, then it is easily conceivable that the fate of the conceptus may be determined by the structure of the implantation site. Not infrequently a small area of the decidua about an abortus shows all the transitions shown in figures 75, 76, 77 (plate 6, Chap. IV), and 135 (plate 13, Chap. IX). The first figure shows the fine, clear, large, polygonal decidual cells, practically wholly infiltrated, and hence presents a rather homogeneous appearance. Figure 76 shows considerable infiltration and autolysis, and also marked change from the usual polygonal cell found present in the post-menstruum by Hitschmann and Adler (1908) to a fibroblast form. In figure 78 (plate 6, Chap. IV) the normal decidual cells have become still more elongated, and in figure 135 the decidua is represented by a decidedly fibrous mass totally different from what it once was. I do not know how far these changes of fibrosis of the decidua may have progressed before implantation occurred, but if the changes in the mucosa are at all pronounced, one scarcely can believe that they can fail to profoundly affect the nutrition and growth of the conceptus.

It may be urged that fibrosis of the decidua is but an effect of the death and retention of the conceptus rather than an indication of the pathologic conditions pre-existent in the mucosa. However, the many instances of abortuses in which the decidua is very degenerate and also infiltrated would seem to argue against such an assumption. Besides, many of the deciduæ found surrounding retained specimens do not show comparable changes. Moreover, Orloff (1896), Iwanoff (1898), and L. Fraenkel (1903, 1910[b]) found that restoration of the mucosa may begin before the conceptus is expelled from the uterus. This fact also seems to suggest that fibrosis probably is pathologic in significance. Moreover, in the few cases of partial regeneration of the mucosa which came to my attention, the decidua was not in the fibrous state shown in figure 135. Infiltration of the decidua no doubt more frequently might arise after death of the conceptus, but that it frequently is present long before this time would seem to be indicated also by the fact that the presence of fibrosis does not seem to bear any definite relation to the duration of the retention, and that the condition of the mucosa before implantation can markedly influence the course of gestation is indicated also by the findings of Punto (1906) in cases of pregnancy complicated by myomata.

TABLE 13.—*Total number of cases (608), grouped according to the number of previous abortions.*

	Number of abortions.													Total.
	1	2	3	4	5	6	7	8	9	10	11	12	13	
Normal white	178	75	31	8	12	5	.....	2	2	1	1	2	.....	317
Pathologic white	137	56	33	11	5	.....	1	.....	.....	.....	.....	.....	.....	243
Normal colored	16	4	2	4	.....	1	.....	.....	.....	.....	.....	.....	.....	27
Pathologic colored	12	4	.....	2	.....	1	.....	1	1	.....	.....	.....	.....	21
Total	343	139	66	25	17	7	1	3	3	1	1	2	.....	

TABLE 14.—*Total number of cases (692), grouped according to the time of last abortion in months.*

	Month of gestation.										Total.
	1	2	3	4	5	6	7	8	9	10	
Normal white	14	75	103	95	36	29	13	3	1	.....	369
Pathologic white	7	57	112	45	17	13	8	7	0	2	268
Normal colored	1	4	8	8	9	3	.....	.....	.....	.....	33
Pathologic colored	1	4	8	2	1	4	1	1	.....	.....	22
Total	23	140	231	150	63	49	22	11	1	2	

TABLE 15.—*Comparative time of abortion.*

Author.	No. of cases.	Month of gestation.									
		1	2	3	4	5	6	7	8	9	10
		p. ct.	*p. ct.*	*p. ct.*	*p. ct.*	*p. ct.*	*p. ct.*	*p. ct.*	*p. ct.*	*p. ct.*	*p. ct.*
Franz	824	0.12	33.1	43.6	16.0	4.4	2.5	.....	.....	.....	.....
Graefe	25	.....	.....	.....	3.7	14.8	.....	7.4	18.5	11.1	.....
Kneiss (Taussig)	500	1.2	44.4	14.6	7.4	1.0	.....	.....	.....	.....	.....
Lechler	520	0.8	12.8	52.0	12.5	10.8	5.0	7.0	.....	.....	.....
Meyer	692	3.3	20.2	33.3	21.6	9.0	7.0	3.1	1.6	0.14	0.29
Stumpf	446	.....	9.8	30.8	7.6	9.3	7.1	3.3	11.0	13.6	7.1
Average	.....	1.36	24.1	34.9	11.5	8.2	5.4	5.2	10.4	8.28	3.7
No. of cases	3,007	2,536	2,982	2,982	3,007	3,007	2,482	1,683	1,163	1,163	1,138

TABLE 16.—*Total number of cases (585), grouped according to the number of children.*

No. of children.	No. of cases.	No. of abortions.	Average No. of abortions per woman.	No. of children.	No. of cases.	No. of abortions.	Average No. of abortions per woman.
0	143	359	2.5	7	18	65	3.6
1	142	364	2.5	8	4	9	4.7
2	108	323	2.9	9	7	24	3.4
3	64	212	3.3	10	4	21	5.2
4	40	125	3.1				
5	36	122	3.5	Total..	585	1093	
6	12	37	3.0				

TABLE 17.—*Total number of cases (607), grouped according to the age of the mother.*

	Age of mother (years).							Total.
	15 to 19	20 to 24	25 to 29	30 to 34	35 to 39	40 to 44	45 to 49	
Normal white	21	80	91	60	44	18	.....	314
Pathologic white	9	49	63	56	37	28	2	244
Normal colored	4	4	9	7	4	1	.....	29
Pathologic colored	2	8	1	6	1	1	1	20
Total	36	141	164	129	86	48	3	

TABLE 18.—*Ratio of abortions to children in the various age-groups. Total number of cases, 576.*

Age group.	No. of cases.	Average No. of abortions per woman.	No. of cases.	Average No. of children per woman.	Ratio of average No. of abortions to average No. of children.	Stumpf (446 cases).	
						Age.	Average No.
15–19	29	1.1	20	0.23	4.8	Before 21	0.30
20–24	134	1.4	133	0.84	1.6	21–25	0.31
25–29	161	1.7	156	1.9	0.89	26–30	0.45
30–34	124	2.2	123	2.6	0.84	31–35	0.36
35–39	80	2.2	78	3.4	0.64	36–40	0.37
40–44	45	2.7	44	5.6	0.48	40+	0.75
45–49	3	1.0	3	7.0	0.14		

TABLE 19.—*Total number of cases (608), grouped according to the number of abortions, race, and the nature of the conceptus.*

	No. of abortions.													Total.
	1	2	3	4	5	6	7	8	9	10	11	12	13	
Normal	194	79	33	12	12	6	.....	2	2	1	1	2	.....	344
Pathologic	149	60	33	13	5	1	1	1	1	.....	.....	.....	.....	264
Total	343	139	66	25	17	7	1	3	3	1	1	2	.....	608
White	315	131	64	19	17	5	1	2	2	1	1	2	.....	560
Colored	28	8	2	6	.....	2	.....	1	1	.....	.....	.....	.....	48
Total	343	139	66	25	17	7	1	3	3	1	1	2	.....	608

TABLE 20.—*Total number of cases (692), grouped according to time of abortion by months, race, and nature of the conceptus.*

	Month of gestation.										Total.
	1	2	3	4	5	6	7	8	9	10	
Normal	15	79	111	103	45	32	13	3	1	.....	402
Pathologic	8	61	120	47	18	17	9	8	.....	2	290
Total	23	140	231	150	63	49	22	11	1	2	692
White	21	132	215	140	53	42	21	10	1	2	637
Colored	2	8	16	10	10	7	1	1	.....	.....	55
Total	23	140	231	150	63	49	22	11	1	2	692

TABLE 21.—*Abortions grouped according to the number of children, race, and the nature of the conceptus. (Total number of cases, 593.)*

	No. of children.																	Total.
	0	1	2	3	4	5	6	7	8	9	10	11	12	13	14	15	16	
Normal	79	91	58	39	24	17	8	9	2	2	3	3	1	....	1	....	....	337
Pathologic	68	50	51	26	17	19	4	9	2	5	2	1	....	1	....	....	1	256
Total	147	141	109	65	41	36	12	18	4	7	5	4	1	1	1	....	1	593
White	133	134	102	61	40	35	9	15	4	5	3	3	1	1	1	....	1	548
Colored	14	7	7	4	1	1	3	3	....	2	2	1	....	....	....	....	....	45
Total	147	141	109	65	41	36	12	18	4	7	5	4	1	1	1	....	1	593

TABLE 22.—*Abortions grouped according to the age of the mother, race, and the nature of the conceptus. (Total number of cases, 607.)*

	Age of mother (years).							Total.
	15–19	20–24	25–29	30–34	35–39	40–44	45–49	
Normal	25	84	100	67	48	19	.....	343
Pathologic	11	57	64	62	38	29	3	264
Total	36	141	164	129	86	48	3	607
White	30	129	154	116	81	46	2	558
Colored	6	12	10	13	5	2	1	49
Total	36	141	164	129	86	48	3	607

TABLE 23.—*Total number of cases (697), grouped according to the causes of abortion.*

	Cause of abortion.									Total.
	Unrecorded.	Spontaneous.	Self-induced.	Therapeutic.	Accid. Mech.	Psychic.	Assoc. disease.	Tumor and malposition.	Miscellaneous.	
Normal white	233	1	48	31	9	5	25	18	17	387
Pathologic white	189	1	20	12	3	5	24	10	7	271
Normal colored	25	.....	.....	5	.....	.....	1	4	1	36
Pathologic colored	16	.....	.....	1	.....	.....	4	1	1	23
Total	463	2	68	49	12	10	54	33	26	717
Less duplicates	.....	.....	.....	.....	.....	.....	.....	.....	.....	20
Total cases	.....	.....	.....	.....	.....	.....	.....	.....	.....	697

TABLE 24.—*Causes of abortion (252 cases).*

Alleged causes of abortion.	Pathologic (88 cases).	Normal (164 cases).
	p. ct.	*p. ct.*
Self-induced	29.2	22.7
Therapeutic	21.9	14.7
Tumor and malposition	12.5	13.4
Associated disease	31.8	15.8
Miscellaneous. Psychic. Accid. mech.	18.1	19.5

The cause was unrecorded in 76.6 per cent of 264 pathologic and in 63.3 per cent of 344 normal cases out of a total of 608.

BIBLIOGRAPHY.

Acconci, G., 1914*. Recerche sull' anatomia, patologica della placenta. II. Folia Ginecol., vol. 9.

———, 1914*. Sulla fine struttura della placenta. Internat. Monatschr. f. Anat. u. Physiol., vol. 30; Folia Gynecol., vol. 9.

Ahlfeld, F., 1872. Die Geburten älterer Erstgeschwängerter. Arch. f. Gynäk., vol. 4, p. 510.

———, 1876. Ueber den Knabenüberschuss der älteren Erstgebärenden, nebst einem Beitrag zum Hofacker-Sadler'schen Gesetze. Arch. f. Gynäk., vol. 9.

———, 1880–82. Missbildungen des Menschen. Leipzig.

———, 1898. Lehrbuch der Geburtshilfe, 2. Aufl.

Amann, J. A., 1916. Ueber destruiernde Blasenmole. Monatschr. f. Gebh. u. Gynäk., vol. 43, p. 11–18.

Anderson, S., 1917. Primary ovarian gestation. Intern. Clin., vol. 27, ser. 2.

Anning, G. P., and Harry Littlewood, 1901. Primary ovarian pregnancy with rupture 14 days after last menstruation. Trans. Lond. Obst. Soc., vol. 43; Lancet, 1901, vol. 1.

Arrowsmith, R., 1834. Superfetation (?) in the sheep. Lond. Med. Gaz., vol. 14.

Auerbach, E., 1912. Das wahre Geschlechtsverhältnis des Menschen. Arch. f. Rassen- u. Gesellschaftsbiologie, Jahr. 9, p. 10.

Baker, J. E., 1910. City life and male mortality. Pub. Amer. Statis. Ass. Boston, vol. 11, p. 133.

Ballantyne, J. W., 1902. Manual of antenatal pathology and hygiene. The fœtus. Edinburgh.

———, 1904. Manual of antenatal pathology and hygiene. The embryo. Edinburgh.

———, and J. Young, 1913. Fatal case of hydatiform mole. Obst. Trans. Edin., vol. 38.

Banks, A. G., 1912. A case of ovarian pregnancy. Jour. Obst. and Gyn. Brit. Emp., vol. 21.

Bardeen, Charles R., 1901. Born's method of reconstruction by means of wax plates as used in the anatomical laboratory of the Johns Hopkins University. Johns Hopkins Hosp. Bull., vol. 12, p. 148–151.

Bell, A. G., 1918. The duration of life and conditions associated with longevity. A study of the Hyde Genealogy. Washington.

Berlin, Maria, 1907. Ueber Veränderungen in retinierten Placenten. Leipzig. Also Beitr. z. Gebh. u. Gynäk., 1907, vol. 11, p. 357–384.

Berner, H., 1883. Om Kjönsdannelsens Aarsager. En biologisk Studie. Christiania.

Bernoulli, C. Quoted by Rauber, 1900.

Bertillon, J., 1896. De la mortinatalité et des naissances prematurées selon l'âge du fœtus et selon l'âge de la mère. Revue d' hygiène, vol. 18, p. 473.

Bidder, E., 1878. Ueber den Einfluss des Altera der Mutter auf das Geschlecht des Kindes. Zeitschr. f. Gebh. u. Gynäk., vol. 2.

Bidder, F., 1893. Ueber alte Erstgebärende. Diss., Mitau.

Billings, J. S., 1904. A discussion of the vital statistics of the twelfth census. Bureau of the Census, Bull. 15.

Birth statistics for the registration area of the United States. Mortality statistics U. S. Census, Washington, 1916.

Birth control movement, 1917. Report of the Committee of One Hundred, National Birth Control League. New York City.

Bloch, Marcus, 1869. Die Blasenmole in wissenschaftlicher und praktischer Beziehung. I. D., Freiburg.

Block, M., 1878. Traité théorique et pratique de statistique. Paris.

Bluhm, A., 1912. Zur Frage nach der generativen Tüchtigkeit der deutschen Frauen und der rassenhygienischen Bedeutung der ärztlichen Geburtshilfe. Arch. f. Rassen- u. Gesellschaftsbiol., Jahr. 9, p. 330–454.

———, 1918. Zur Kenntnis der Gattungsleistungen der Industriearbeiterinnen im Kriege. Arch. f. Rassen- u. Gesellschaftsbiol., vol. 13, p. 75.

Boerma, N. J. A. F., 1912. Een zee jong menschelijk ei. Feestbundel opgedragen aan Hector Treub. Leiden.

———, 1913. Beitrag zur Kenntnis der Einbettung des menschlichen Eies. Monatschr. f. Gebh. u. Gynäk., vol. 37.

Bonnar, G. L., 1865. A critical inquiry regarding superfetation with cases. Edinb. Med. Jour., vol. 10, Pt. 2.

Bonnet, R., 1903. Ueber Syncytien, Plasmodien und Symplasma in der Placenta der Säugetiere und des Menschen. Monatschr. f. Gebh. u. Gynäk., vol. 18.

Born, G., 1883. Die Plattenmodellirmethode. Arch. f. mikr. Anat., vol. 13.

Boudin, 1862. De l'influence de l'âge relatif des parents sur la sexe des enfants. Bull. Soc. d'anthropol. de Paris, vol. 3.

Briggs, H., 1912. On the relative size of the uterus in cases of hytadid mole with illustrative cases and specimens. Jour. Obst. and Gyn. British Emp., vol. 21.

Broman, Ivar, 1911. Normale und abnorme Entwicklung des Menschen. Wiesbaden.

Brooks, W. K., 1887. Note on the ratio between men and women. Johns Hopkins Univ. Circ., Baltimore.

Bryce, Teacher, and Kerr, 1908. Contributions to the Study of the Early Development and Imbedding of the Human Ovum. Glasgow.

Bücher, K., 1892. Ueber die Verteilung der beiden Geschlechter auf der Erde. Allgemeinea Statistiches Arch., vol. 2, p. 374.

Bucura, C., 1905. Geschlechtsverhältnis der Neugeborenen mit besonderer Berücksichtigung der mazerierten Kinder. Zentralbl. f. Gynäk., Jahr. 29.

Busch and Moser, 1840. Handbuch der Geburtskunde: Abortus. Berlin. (Quoted from Lechler, 1883.)

Calderini, G., 1909. Ueber einen Fall von Superfötation. Gynäk. Rundschau, Jahr. 3.

Carlberg, N., 1886. Die Bewegung der Bevölkerung Livlands in den Jahren 1873–1882. Reval.

Carvallo, M. E., 1912. La masculinité dans les naissances humaines. Compt. rend. Assn. franç. pour l'avancement des sciences, 41, Sess. Nîmes, p. 145.

Caturani, M., 1914. Ovarian pregnancy with report of a case. Amer. Jour. Obst., vol. 49.

Chaletzky, Eva, 1891. Hydatidenmole. Bern.

Chazan, S., 1904. Die Fehlgeburt, ihr Vorkommen, Verlauf und ihre Behandlung. Von Winckel's Handbuch der Geburtshilfe, II². Wiesbaden.

Chiene, G., 1913. A case of ruptured very early primary ovarian pregnancy. Edin. Med. Jour., n. s., vol. 10.

Christopher, W. S., 1886. Ovulation during pregnancy. Amer. Jour. Obst., vol. 19.

Clivio, I., 1908. A proposito di un caso di mola vescicolare iniziale. Folio Ginaecol. vol., 1.

Cosentino, —, 1897. Ovulation während der Schwangerschaft. Centralbl. f. Gynäk., vol. 21.

Cowie, D. M., 1914. A case of multiple intrauterine fractures. Trans. Clin. Soc. Univ. Mich., vol. 5.

Croom, J. H., 1895. Two cases of extra-uterine gestation operated upon at the fourth month. Edin. Med. Jour., vol. 40, Part 2.

Crosti, G., 1895–6. Contribuzione allo studio dell' aborto di origine ovulare. Atti dall assoziazione medica Lombardo, No. 3; Rev. in Centralbl. f. Gynäk., 1896. vol. 20.

———, 1896. Beitrag zur Aetiologie des Abortus. Centralbl. f. Gynäk., vol. 20.

Cummings, J., 1918. Negro population, 1790–1915. Bureau of the Census, Washington.

Curtis, A. H., 1915. Experiments in the production of abortion and labor by use of placental extracts. Surg., Gyn. and Obst., vol. 20.

Daels, F., 1908*. Zur Histologie der Blasenmole. Arch. f. Gynäk., vol. 86.

Daels, F., 1908b. Au sujet de l'étiologie de la môle hydatique. Ann. Soc. de méd. de Gand.

Dandy, W. E., 1910. A human embryo with seven pairs of somites measuring about 2 mm. in length. Amer. Jour. Anat., vol. 10.

Dareste, C., 1877. Recherches sur la production artificielle des monstruosités. Paris.

———, 1883a. Nouvelles recherches sur la production des monstres, dans l'œuf de la poule, par l'effet de l'incubation tardive. Compt. rend. Acad. Sci., Paris, vol. 96, p. 444–446.

———, 1883b. Recherches sur la production des monstruosités par les secousses imprimées aux œufs de poule. Compt. rend. Acad. Sci., Paris, vol. 96, p. 511–513.

Debeyre, A., 1912. Description d'un embryon humain de 9mm.9. Jour. del'anat. et physiol. norm. et path., vol. 48.

De Lee, J. B., 1915. The Principles and Practice of Obstetrics. Philadelphia.

Dempsey, M., 1919. Infant mortality; results of a field study in Brockton, Mass. U. S. Dept. Labor, Children's Bureau, Pub. 37.

Detlefsen, J. A., 1914. Genetic studies on a cavy species cross. Carnegie Inst. Wash., Pub. No. 205, Paper No. 23, Station for Exp. Evolution.

Dohrn, R., 1888. Hat das enge Becken Einfluss auf die Entstehung des Geschlechts? Zeitschr. f. Gebh. u. Gynäk., vol. 14.

Donskoj, Dimitry, 1911. Beiträge zur Kenntniss der Blasenmole. I. D., München.

Dorland and Gerson, 1896. Cystic disease of the chorion, with a tabulation of one hundred cases. Univ. Med. Mag., vol. 8.

Dührssen, A., 1887. Zur Pathologie und Therapie des Abortus. Arch. f. Gynäk., vol. 31.

———. Quoted by Hirsch, 1913.

Dumont, A., 1894. Natalité et masculinité. Revue scientifique, vol. 1, s. 4, p. 752.

Duncan, B. S., and E. Duke, 1917. Infant mortality. U. S. Dept. Labor, Children's Bureau, Pub. 20.

Durante, G., 1898. Variétés, histologiques et nature de la môle hydatiforme. Arch. de méd. expér. et d'anat. path., vol. 10, p. 571–591.

———, 1909. Lésions des vaisseaux fœtaux dans le môle hydatiforme (nature et pathologie de la môle). Gynec., Par. I, p. 13.

Düsing, C., 1884. Die Regulierung des Geschlechtsverhältnisses bei der Vermehrung der Menschen, Tiere und Pflanzen. Jenaische Zeitschr. f. Naturwissensch., vol. 17.

———, 1890. Das Geschlechtsverhältnie der Geburten in Preussen. Jena.

Dutton, A. S., 1910. The greater frequency of stillbirths and deaths under a year among males than females. Medical Press and Circular, London, vol. 89, p. 468.

Emanuel, R., 1895. Demonstration zur Lehr von der Endometritis in der Schwangerschaft. Zeitschr. f. Gebh. u. Gynäk., vol. 31.

Engel, Georg, 1900. Rückbildungsvorgänge an abortiv-Embryonen. Beitr. z. path. Anat. u. allg. Path., vol. 28.

Engelking, Ernst, 1913. Intraligamentar entwickelte Eierstockschwangerschaft. Ein Beitrag zur anatomischen Diagnostik vorgeschrittener Fälle. Monatschr. f. Gebh. u. Gynäk., vol. 37.

Engman, M. F., 1912. Einige Bemerkungen über die Pathologie der Syphilis der Placenta. Dermat. Wchnschr., vol. 55.

Ercolani, G. B., 1871. Delle malattie della placenta, memoria. Bologna.

———, 1883. Sulle alterazioni patologiche portale delle sifilde nella placenta umana. Bologna.

Essen-Möller, E., 1912. Studien über die Blasenmole. Wiesbaden.

Essick, C. R., 1915. Transitory cavities in the corpus striatum of the human embryo. Contributions to Embryology, vol. 2. Carnegie Inst. Wash. Pub. No. 222.

Eternod, A. C. F., 1909a. L'œuf humain. Genève.

———, 1909b. Inégalités de croissance du chorion ovulaire humain et localisation consecutives en chorion læve et chorion frondosum. Compt. rend. de l'Réunion de l'Assn. des Anat., Nancy.

Evans, H. M., 1913. Undated circular of the Department of Embryology of the Carnegie Institution of Washington. (Printed privately.)

Ewart, R. J., 1918. Sex ratio and sex determination. Brit. Med. Jour., vol. 2, p. 358.

Falgowski, W., 1911. Kritische Würdigung eines Falles von Blasenmole bei Zwillingsschwangerschaft mit einem ausgetragenem Kind. Monatschr. f. Gebh. u. Gynäk., vol. 34.

Fasola, E., 1887. Alcune considerazioni sopra tre gravidanza gemelle. Ann. di ostet., Supp. 9.

Fellner, O. O., 1907. Ueber periphere Langhanszellen. Zeitschr. f. Geburtsh. u. Gynäk., vol. 59, p. 63–71.

Fetzer, 1910. Ueber ein durch Operation gewonnenes menschliches Ei, das in seiner Entwickelung etwa dem Petere'schen Ei entspricht. Anat. Anz., vol. 37, Ergänzhft., p. 116.

Findlay, P., 1917. Hydatiform mole; an analysis of 500 cases. Amer. Jour. Obst., vol. 75.

Finzi, C., 1908. Sulla fine struttura della mola vescicolare. Riv. veneta di ec. med. vol. 48. Venezia.

Fossati, G., 1906. Di nuovo su un reticolo dei villi placentari. Ann. di ostet., vol. 2, p. 93–100. Milano.

Fraenkel, E., 1873. Ueber Placentarsyphilis. Ein Beitrag zur Pathologie der Placenta. Breslau. Also, Archiv f. Gynäk., vol. 5.

———, 1903. Ueber "missed labor" und "missed abortion." Volkmann's Samml. klin. Vortr., n. F. No. 351 (Gynäkol.).

Fraenkel, L., 1903. Die Function des Corpus luteum. Arch. f. Gynäk., vol. 68.

———, 1910a. Rückbildung von Ovarialtumoren nach Blasenmole. Monatschr. f. Gebh. u. Gynäk., vol. 32.

———, 1910b. Neue Experimente zur Function des Corpus luteum. Arch. f. Gynäk., vol. 90.

Francke. Quoted by Newcomb, 1904.

Franco, Enrico E., 1910. Ueber vorgetäuschte Superfœtation. Arch. f. Gynäk., vol. 91.

Franz, K., 1898. Zur Lehre des Aborts. Beitr. z. Gebh. u. Gynäk., vol. 1, p. 277.

———, 1902. Ueber Einbettung und Wachstum des Eies im Eierstock. Beitr. f. Gebh. u. Gynäk, vol. 6.

Frassi, Luigi, 1906. Studio sulla fine struttura della mola vescicolare. Ann. di ostet. vol. 1. Milano.

Freund, H. W., and R. Thomé, 1906. Eierstocksschwangerschaft. Virchow's Arch. f. path. Anat. u. Phys., vol. 183.

Freund, W. A., 1889. (No title) See "Berichte über die Verhandlungen der gynäkologischen Sektion der 62; Versammlung deutscher Naturforscher und Ärtze zu Heidelberg," 1889. (A reference to the case only.) Centralb. f. Gynäk., Jahr. 13, p. 69.

Friolet, Heinrich, 1905. Beitrag zum Studium der menschlichen Placentation. Beitr. z. Gebh. u. Gynäk., vol. 9.

Fuertes, Ricardo, 1879. Superfetacion. Tesis inaugural de Escuela Medicina de Mexico.

Fuoss, Herman, 1888. Beiträge zur pathologischen Anatomie der Placenta; Veränderung bei Syphilis und Nephritis. I. D., Tübingen.

Füth, H., 1902. Ueber Ovarialschwangershaft. Beitr. z. Gebh. u. Gynäk., vol. 6.

Garrard, J. I., 1916–17. A probable case of ovarian pregnancy. Jour. Med. Ase. Georgia, vol. 6.

Geissler, A., 1889. Beiträge zur Frage des Geschlechtsverhältnisses der geborenen. Zeitschr. d. sächsischen statistischen Bureaus, vol. 35.

Giacomini, Carlo, 1888. Sur quelques anomalies de développement humain. Arch. ital. de biol., vol. 9.
———, 1889. Sur quelques anomalies de développement de l'embryon humain. Arch. ital. de biol., vol. 12.
———, 1892. Sur quelques anomalies de développement de l'embryon humain. Ve. Observation. Grossesse tubaire. Arch. ital. de biol., vol. 17.
———, 1893a. Sur les anomalies de développement de l'embryon humain. Communication IV: Ovule complet avec embryon atrophique. Arch. ital. de biol., vol. 18, p. 86.
———, 1893b. Sur les anomalies de développement de l'embryon humain. Communication V: Produit abortif avec forme noduliaire. Arch. ital. de biol., p. 400.
———, 1893c. Sur les anomalies de développement de l'embryon humain. Communication VI: Absence de l'embryon. Kystes de l'amnios. Formations épithéliales dans le chorion et dans le stroma des villosités. Arch. ital. de biol., vol. 19, p. 82.
———, 1894. Die Probleme, welche sich aus dem Studium der Entwickelungsanomalien des menschlichen Embryos ergeben. Ergebn. d. Anat. u. Entw., vol. 4, p. 617.
Gierse, August, 1847. Ueber die Krankheiten des Eies und der Placenta. Verhandlung. der Gesellsch. f. Gebh., Berlin, vol. 2.
Giles, A. E., and C. Lockyer, 1914–15. Case of ovarian pregnancy. Proc. Roy. Soc. Med., Lond., vol. 8; Obst. and Gyn. Sec. 2–10.
Gilford, Hastings, 1899. Two further instances of extra-uterine (one tubal and one ovarian) gestation in which rupture occurred before the first month; operation. Lancet.
———, 1901. Ovarian pregnancy. Brit. Med. Jour., vol. 2.
Goehlert, V., 1889. Die Schwankungen der Geburtszahl nach Monaten. Biol. Zentralbl., vol. 8.
Graefe, Max, 1896. Ueber Retention des menschlichen Eies im Uterus nach dem Fruchttode. Festschrift für Carl Ruge. Berlin.
Granville, A. B., 1820. A case of a human fetus found in the ovarium of the size it usually acquires at the end of the fourth month. Philos. Trans. Roy. Soc., London, Pt. 1.
———, 1834. Graphic Illustrations of Abortion and the Diseases of Menstruation. London.
Grassl, J., 1912. Einiges über den Generationswechsel. Arch. f. Rassen- u. Gesellschaftsbiol., Jahr. 9, p. 718.
Graves, E. W. H., 1909–10. A specimen of tubal mole. Proc. Roy. Soc. Med., London, Obst. and Gyn. Sec. 1.
Grimsdale, T. B., 1913. Case of ovarian pregnancy with full-time fetus. Jour. Obst. and Gyn. Brit. Emp., vol. 23.
Gromadzki, Heinrich, 1913. Ein Beitrag zur Lehre von der Blasenmole mit besonderer Berücksichtigung deren Pathogenese. I. D., Halle.
Grosser, Otto, 1909. Vergleichende Anatomie und Entwickelungsgeschichte der Eihäute und der Placenta. Leipzig.
———, 1910. The development of the egg membranes and the placenta: Menstruation. Manual of Human Embryology, Keibel and Mall, vol. 1, chap. VII.
———, 1913. Ein menschlicher Embryo mit Chordakanal. Anat. Hefte, vol. 47.
Guerra, 1909. Un caso de superfetazione. L'arte ostetrica, vol. 15.
Gustetter, A. L., 1918. Abortion due to superfetation. Jour. Amer. Med. Ass., vol. 70.
Guyer, M. F., 1903. On the sex of hybrid birds. Biol. Bull., vol. 16.
Hahn, C. F. O., 1864. Ueber ein cystenartiges Gebilde im Nabelstrange einer Traubenmole. Leipzig. Also Monatschr. f. Geburtsk. u. Frauenkrankh., 1865, vol. 26.
Hansen, H. T., 1913. Undersøgelser over nyfødte Børns Vaegt. Meddelser om Danmarks Antropologi udgivne of den Antropologiske Komité, vol. 2, p. 1.
Happe, H., 1906. Beobachtungen an Eihäuten junger menschlicher Eier. Anat. Hefte 1a, p. 171–209.
Harman, Mary T., 1917. A case of superfetation in the cat. Anat. Rec., vol. 13.
———, 1918. A probable case of superfetation in the cow. Anat. Rec., vol. 14.
Harris, John W., 1919. Influenza occurring in pregnant women: A statistical study of 1350 cases. Jour. Amer. Med. Ass., vol. 72.
Heape, W., 1909. The proportion of the sexes produced by white and colored peoples in Cuba. Philos. Trans. Roy. Soc., London, ser. B, vol. 200, p. 271.
Hegar, A., 1863. Beiträge zur Pathologie des Eies und zum Abort in den ersten Schwangerschaftswochen. Monatschr. f. Gebk., vol. 21, Supp. Hft.
Hegar, Karl, 1902. Beitrag zur Lehre vom Abort. Beitr. zur Gebh. u. Gynäk., vol. 6.
———, 1904. Der Abort. Die deutsche Klinik am Eingange des zwanzigsten Jahrhunderts. Geburtshülfliche und Gynäkologische Vorlesungen, vol. 9.
Heiberg, P., 1911. The weight of newborn children. Med. Danmarks Antrop., vol. 1, p. 335.
Heinz, Robert, 1888. Untersuchungen über den Bau und die Entwickelung der menschlichen Placenta. I. D., Breslau.
Hellier, J. B., 1901. A note on the occurrence of abortion. Brit. Med. J., vol. I.
Henneberg, B., 1897. Wodurch wird das Geschlechtsverhältnis beim Menschen und den höheren Tieren beeinflusst? Anat. Hefte, vol. 7, 2 Abt., p. 697.
———, 1903. Experimentell erzeugte Rückbildungsvorgänge am graviden Säugertieruterus. Anat. Anz., vol. 24.
Hennig, Carl, 1876. Die Krankheiten der Eileiter und die Tubenschwangerschaft. Stuttgart.
Heron, D., 1906. On the inheritance of the sex ratio. Biometrika, vol. 5, p. 79.
Hertwig, R., 1912. Ueber den derzeitigen Stand des Sexualitätsproblems, nebst eigenen Untersuchungen. Biol. Zentralbl., vol. 32, H. 1–3.
Herzog, Maximillian, 1898. Superfetation in the human race. Chicago Med. Recorder, vol. 15.
———, 1909. A contribution to our knowledge of the earliest known stages of placentation and embryonic development in man. Amer. Jour. Anat., vol. 9.
Hewitt, Graily, 1860. On the hydatiform or vesicular mole; its nature and mode of origin. Obs. Trans., London, vol. 1.
———, 1861. Hydatiform degeneration of the ovum. Obs. Trans., London, vol. 2.
Hiess, Viktor, 1914. Ein Beitrag zur Pathologie und Klinik der Blasenmole. Gynäk. Rundschau, Berlin u. Wien, Jahr. 8.
Hirsch, M., 1913. Ueber das Verhältnis der Geschlechter. Zentralbl. f. Gynäk., 37 Jahr., No. 12.
Hirtzman, 1874. Mentioned by Seitz, 1904. Thèse, Paris.
His, Wilhelm, 1882. Gestalt- und Grössenentwicklung menschlicher Embryonen bis zum Schluss des zweiten Monats. In Anat. menschl. Embryonen, Part II. Leipzig.
———, 1891. Offene Fragen der pathologischen Embryologie. Internat. Beiträge zur wissenschaftlichen Medicin. Festschr. f. Virchow, vol. 1.
———, 1892. Der mikrophotographische Apparat der Leipziger Anatomie. Leipzig.
Hitschmann, F., and L. Adler, 1908. Der Bau der Uterusschleimhaut des geschlechtsreifen Weibes mit besonderer Berücksichtigung der Menstruation. Monatschr. f. Gebh. u. Gynäk., vol. 27.
Hofbauer, J., 1903. Über das konstante Vorkommen bisher unbekannter zelliger Formelemente in der Chorionzotte der menschlichen Placenta. Wien. klin. Wchnschr., vol. 16.
———, 1905. Grundzüge einer Biologie der menschlichen Plazenta. Leipzig.

Hoffmann, A., 1887. Hat das enge Becken der Mutter Einfluss auf das Geschlecht des Fötus? Diss. Würzburg.

Hofmaier, M., 1890. Die menschliche Placenta. Beitr. z. norm. u. path. Anat. Wiesbaden.

Hohlweg, Herman, 1903. Fötus papyraceus und kurze histologische Betrachtung der retinierten Placenta. München.

Holland, E., 1911. A case of ovarian pregnancy; probably bilateral. Jour. Obst. and Gyn. Brit. Emp., vol. 20.

Huber, G. C., 1915. The development of the albino rat *Mus norvegicus albinus*. II: Abnormal ova: end of the first to the end of the ninth day. Jour. Morph., vol. 26.

Ingalls, N. William, 1918. A human embryo before the appearance of the myotomes. Contributions to Embryology, vol. 7. Carnegie Inst. Wash. Pub. No. 227.

Iwanoff, N. K., 1898. III: Ein interessanter Fall von "missed abortion." Centralbl. f. Gynäk., Bd. 22.

Jackson, Samuel, 1838. Abortion of one twin, the other remaining. Amer. Jour. Med. Sci., May.

Jacobson, S. D., 1908. True primary ovarian pregnancy; operation; recovery. Contributions to the Science of Medicine and Surgery, N. Y. Post-Grad. Med. Sch. and Hosp.

Janke, H., 1888. Die willkürliche Hervorbringung des Geschlechts bei Menschen und Haustieren. 2 Aufl. Berlin u. Leipzig.

Jaschke, R. T., 1915. Ovarialgravidität mit wohlerhaltenem Embryo. Ztschr. f. Gebh. u. Gynäk., vol. 78.

Jendrassik, E., 1911. Ueber die Frage des Knabengeburten-Ueberschusses und über andere Hereditäts probleme. Deutsche med. Wchnschr., vol 37, p. 1729–1732.

Jenkinson, J. W., 1913. Vertebrate Embryology.

Johnson, F. P., 1917. A human embryo of 24 pairs of somites. Contributions to Embryology, vol. 6, Carnegie Inst. Wash. Pub. No. 226.

Jones, Mary A. D., 1897. Diseased Ova. Amer. Jour. Obst., vol. 36.

Jones, W., and C. R. Austrian, 1907. On the nuclein ferments of embryos. Jour. Biol. Chem., vol. 3.

Jung, P., 1908. Beiträge zur frühesten Ei-Einbettung beim menschlichen Weibe. Berlin.

Kantorowicz, Ludwig, 1904. Eierstockesschwangerschaft. Samml. klin. Vortr., Volkmann, n. F., Nr. 370, Gynäk., 136.

Kastschenko, N., 1885. Das menschliche Chorionepithel und dessen Rolle bei der Histogenese der Placenta. Arch. f. Anat. u. Physiol., Anat. Abth.

Kehrer, F. A., 1894. Ueber Traubenmole. Arch. f. Gynäk., vol. 45.

Keibel, F., and F. P. Mall, 1910. Manual of Human Embryology. Philadelphia. (German ed.: Handbuch der Entwicklungsgeschichte des Menschen. Leipzig.)

Kellicott, W. E., 1916. The effect of lower temperature upon the development of *Fundulus*. Anat. Rec., vol. 20.

Keyssner, E., 1895. Ueber die relative Häufigkeit der vorzeitigen Unterbrechung der Schwangerschaft. Centralbl. f. Gynäk., vol. 19, p. 1348.

King, H. D., 1911. The sex ratio in hybrid rats. Biol. Bull., vol. 21, p. 104.

———, 1913. Some anomalies in gestation of the albino rat (Mus norvegicus albinus). Biol. Bull., vol. 24.

———, 1918. Studies on inbreeding. III: The effects of inbreeding, with selection, on the sex ratio of the albino rat. Jour. Exper. Zool., vol. 27, p. 1.

———, 1921. A comparative study of the birth mortality in the albino rat and in man. Anat. Rec., vol. 20, p. 321.

Kirkham, W. B., 1916. The prolonged gestation period in suckling mice. Anat. Rec., vol. 11.

Knöpfel, L., 1907. Ueber die spezifische Sterblichkeit der beiden Geschlechter. Allgem. statistisches Arch., vol. 7, p. 227.

Koebner, Franz, 1910. Knochenresorption bei intrauterinem Eischwund. Arch. f. Gynäk., vol. 91.

Kölliker, Albert, 1884. Grundriss der Entwickelungsgeschichte des Menschen und der höheren Tiere. 2d Aufl. Leipzig.

Kollman, J., 1889. Die Körperform menschlicher normaler und pathologischer Embryonen. Arch. f. Anat. u. Physiol., Anat. Abth., supp. vol.

———, 1898. Lehrbuch der Entwicklungsgeschichte des Menschen. Jena.

———, 1907. Hand Atlas der Entwicklungsgeschichte des Menschen, vol. 1. Jena.

Kollmann, P., 1890. Der Einfluss des Alters der Eltern auf das Geschlecht der Geborenen nach statistischen Ermittelungen. Allgem. statistisches Arch., Jarh. 1890–91.

v. Körösy, 1898. Die Sterblichkeit der Hauptstadt Budapest. Berlin.

———, 1905. Neue Beiträge zur Sexualproportion der Geburten. Bull. de l'Inst. internat. de Statis., vol. 14.

Kossmann, Robby, 1892. Zur Histologie der Chorionzotten des Menschen. Leipzig.

Kouwer, B. J., 1897. Ein geval van ovarialzwangerschap (zwangerschap in ein Graafschen follikel). Nederl. Tijdschr. v. Verlosk en Gynaec., Haarlem, vol. 8.

Kroemer, P., 1907. Klinische Beobachtungen über Aetiologie und Therapie des Chorionepithelioms insbesondere über die Behandlung der Blasenmole. Deutsche med. Wchnschr., vol. 33, p. 1246.

Kroon, J. P., 1917. Jets over de verhouding der sterfte von mannen en vrouwen. Nederlandsch Tijdschr. voor Geneeskunde, vol. 61, p. 1564.

Krueger, M., 1909. Eine seltene Form der Placentarcyste; ein Beitrag zur Lehre von der Blasenmole. Zeitschr. f. Gebh. u. Gynäk., vol. 64, p. 315–319.

Kunz, Albert, 1916. A note on superfetation. Interstate Med. Jour., vol. 23.

Kupffer, C., 1888. Decidua und Ei des Menschen am Ende des ersten Monats. Münch. med. Wchnschr., vol. 35, p. 415.

Kworostansky, P., 1903. Ueber Anatomie und Pathologie der Placenta. Arch. f. Gynäk., vol. 70, p. 113–192.

Ladame, H., 1904. Contribution à l'étude de la mortinatalité suisse. Bern.

Lanohans, Theodor, 1877. Untersuchungen über die menschliche Placenta. Arch. f. Anat. u. Physiol., Anat. Abth., p. 188–267.

———, 1902. Syncytium und Zellschicht Placentarreste nach Aborten. Chorionepitheliom und Hydatenmole. Beitr. z. Gebh. u. Gynäk., vol. 5–6.

Lazitch, Emilie, 1913. Les villosités choriales humaines, leur formes, leurs modes de ramification. Thèse, Nancy.

Lea, S. W. W., 1910. A case of ovarian pregnancy with diffuse intraperitoneal hemorrhage. Jour. Obst. and Gyn. Brit. Emp., vol. 18.

Lechler, E., 1883. Pathologie und Therapie des Abortus. I. D., Berlim.

Lehr, J., 1889. Zur Frage der Wahrscheinlichkeit von weiblichen Geburten und Totgeburten. Zeitschr. f. d. ges. Staatswissensch., vol. 45.

Le Maire, M., 1906. Geschlechtsverhältnis der Neugeborenen mit besonderer Berücksichtigung der mazerierten Kinder. Zentralbl. f. Gynäk., 30 Jarh., No. 5.

v. Lenhossék, M., 1902. Ueber das Chorionepithel. Mathematikai es Termeszettundánanyi Estesitő, 85–100. Rev. in Zentralbl. f. Gyn., 1904, vol. 28, p. 229.

———, 1903. Das Problem der geschlechtsbestimmenden Ursachen. Jena.

Leopold, G., 1882. Ovarialschwangerschaft mit Lithopädionbildung von 35-jahriger Dauer. Arch. f. Gynäk., vol. 19.

———, 1899. Beitrag zur Graviditas extrauterina. Arch. f. Gynäk., vol. 58.

Lewis, C. J., and J. N. Lewis, 1906. Natality and fecundity; a contribution to national demography. London.
Lewis, Warren H., 1915. The use of guide planes and plaster of Paris for reconstruction from serial sections: Some points on reconstruction. Anat. Rec., vol. 9, 719–729.
Lillie, F. R., 1917. The freemartin; a study of the actions of sex hormones in the fetal life of cattle. Jour. Exper. Zool., vol. 23, p. 371.
de Lima, J. A. P., 1915. Sôbre alguns casos de hemimelia e de ectrodactilia. Arch. d. Anat. e Antrhop., vol. 3.
Linden, A., 1884. Hat das enge Becken einen Einfluss auf die Entstehung des Geschlechtes? Diss. Marburg.
Litthauer, Max, 1887. Ein Beitrag zur Lehre von der Retention abgestorbener Früchte im Uterus. I. D., Berlin.
Lockyer, C., 1916–17. Two cases of primary ovarian pregnancy, with a review of the literature, 1910–1917. Proc. Roy. Soc. Med., London, vol. 10; Sect. Obst. and Gyn.
Loeb, L., 1912. The influence of pregnancy on the cyclic changes in the uterus. Proc. Amer. Physiol. Soc., 1912–13, vol. 25.
Logan, J. C., 1917. A case of superfetation. Jour. Med. Ass. Georgia, vol. 7.
de Loos, C. C., 1897. Das Wachstum der menschlichen Chorionzotten. I. D., Freiburg.
Lorenz, O., 1898. Lehrbuch der gesammten wissenschaftlichen Genealogie. Berlin.
Lwow, J. M., 1892. Mola vesiculosa. Centralbl. f. Gynäk., Jahr. 16.
McKenzie, B. E., 1897. Congenital defects of the long bones. N. Y. Med. Jour., vol. 65.
Maffucci, A., 1894. Ueber das Verhalten des Embryo gegen Infectionen. Centralbl. f. allg. Path. u. path. Anat., vol. 5.
Malins, Edward, 1903. Some aspects of the economic and of the antenatal waste of life in nature and civilization. Jour. Obst. and Gyn. Brit. Emp., vol. 3.
Mall, F. P., 1900. A contribution to the study of the pathology of early human embryos. Johns Hopkins Hosp. Reports, vol. 9.
———, 1903. Second contribution to the study of the pathology of early human embryos. Contributions to Medical Research, dedicated to Victor Clarence Vaughan. Ann Arbor, Michigan.
———, 1904. Pathological human embryos. Wood's Ref. Handbook Med. Sci., New York.
———, 1908. A study of the causes underlying the origin of human monsters. Jour. Morph., vol. 19.
———, 1910. Determination of the age of human embryos and fetuses. Human Embryology, Keibel and Mall, vol. 1 (chap. 8).
———, 1913. A plea for an institute of human embryology. Jour. Amer. Med. Ass., vol. 60, p. 1599–1601.
———, 1915. On the fate of the human embryo in tubal pregnancy. Contributions to Embryology, vol. 1. Carnegie Inst. Wash. Pub. No. 221.
———, 1916. On magma réticulé in normal and in pathological development. Contributions to Embryology, vol. 4, Carnegie Inst. Wash. Pub. No. 224.
———, 1917[a]. Cyclopia in the human embryo. Contributions to Embryology, vol. 6. Carnegie Inst. Wash. Pub. No. 226.
———, 1917[b]. Note on abortions, with letters from the Health Commissioner of Baltimore and from the Chief of the Bureau of Vital Statistics of Maryland, regarding registration and shipment of embryos to the Carnegie Laboratory of Embryology at the Johns Hopkins Medical School. Circular No. 20, January 20. (Printed privately.)
———, 1917[c]. On the frequency of localized anomalies in human embryos and infants at birth. Amer. Jour. Anat., vol. 22; also chapter VII of this volume.
———, 1918. On the age of human embryos. Amer. Jour. Anat., vol. 23.
Mall, F. P., and E. Cullen, 1913. An ovarian pregnancy located in the Graafian follicle. Surg., Gyn. and Obst., vol. 17.
Mapes, C. C., 1914. Ovarian gestation—being principally a review of the literature. Amer. Jour. Surg., vol. 28.
Marchand, Franz, 1895. Ueber den Bau der Blasenmole. Monatschr. f. Gebh. u. Gynäk., vol. 132.
———, 1898. Ueber das maligne Chorioepithelioma. Zeitschr. f. Gebh. u. Gynäk., vol. 39.
———, 1903. Beobachtungen an jungen menschlichen Eiern. Anat. Hefte, vol. 21.
———, 1904. Beitrag zur Kenntniss der normalen und pathologischen Histologie der Decidua. Arch. f. Gynäk., vol. 72.
Martin, R. S., 1917–18. Three interesting cases. Virginia Med. Semi-Monthly, vol. 22, May 11, p. 71.
Maslowski, W., 1882. Zur pathologischen Anatomie der Traubenmole. Centralbl. f. Gynäk., vol. 6, p. 145–151.
Matwejew, G. F., and W. M. Sykow, 1901. Blasenmole in der Tuba Fallopii und cystische Degeneration des Ovariums. Sitzungsb. der Mosk. gyn. Gesellsch. Wratsch, No. 24. (Rev. in Zentralbl. f. Gyn., vol. 26, 1902.)
Maxwell, R. D., 1910. Tubal mole with edema of the connective tissue of the villi. Proc. Royal Soc. Med., London, vol. 3; Sect. Obs. and Gyn.
Mayer, Karl, 1911. Retention von Blasenmolen. Med. klin. Berlin, Jahr. vii, Th. 2.
v. Meinzingen, F., 1899. Ueber die Sexualproportion der Geborenen. Mitth. Anthrop. Gesell., Wien.
Mendel, L. B., and C. S. Leavenworth, 1908. Chemical studies on growth. V: The autolysis of embryonic tissues. Amer. Jour. Physiol., vol. 21.
Menu, Adolphe, 1899. La môle vésiculaire. Tumeur maligne. Thèse, Paris.
Merttens, J., 1894. Ueber Obliteration fötaler Gefässe in retinierten Placenten. Ztschr. f. Gebhurtsh. u. Gynäk., vol. 30.
———, 1895. Beiträge zur normalen und pathologischen Anatomie der menschlichen Placenta. Ztschr. f. Geburtsh. u. Gynäk., vol. 30–31.
Meyer, A. W., 1914. Retrogressive changes in the fetal vessels and the suspensory ligament of the liver. Amer. Jour. Anat., vol. 16.
———, 1917[a]. Intrauterine absorption of ova. Anat. Record, vol. 12.
———, 1917[b]. Some morphological effects of prolonged inanition. Jour. Med. Research, vol. 36, p. 51–77.
———, 1918. Hydatiform degeneration, with deductions from over one hundred and fifty new cases. Amer. Jour. Obst., vol. 78.
———, 1919[a]. Hydatiform degeneration in tubal pregnancy. Surg., Gyn. and Obst., vol. 28.
———, 1919[b]. On the nature, occurrence, and identity of the plasma cells of Hofbauer. Jour. Morph., vol. 31.
———, 1919[c]. A suggestion from Plato, with others. Science, vol. 49.
———, 1919[d]. The occurrence of superfetation. Jour. Amer. Med. Ass., vol. 72.
———, 1919[e]. Uterine, tubal, and ovarian lysis and resorption of conceptuses. Biol. Bull., vol. 36.
———, 1920. Hydatiform degeneration in tubal and uterine pregnancy. Contributions to Embryology, vol. 9. Carnegie Inst. Wash. Pub. No. 272.
———, and H. M. N. Wynne, 1919. Some aspects of ovarian pregnancy with report of a case. Johns Hopkins Hosp. Bull., vol. 30.
Michailoff, ——, 1897. Durchschnittsziffern der Geburtshülfe in Russland in 50 Jahren. J. f. Geburtsh. (S. 859. Russian).
Michaelis, H., 1903. Zur normalen Anatomie der Chorionzotten. Beitr. z. Geburtsh. u. Gynäk., vol. 8.
Miller, John W., 1910. Die Rückbildung des Corpus lutem. Arch. f. Gynäk., vol. 91.

MILLER, JOHN W., 1913. Das jüngste operativ erhaltene menschliche Ei. Corpus leuteum und Schwangerschaft. Berl. klin. Wchnschr., vol. 50.

MILLS, H. M., 1917. Probable ovarian pregnancy. Amer. Jour. Obst., vol. 76.

MINOT, C. S., 1889. Uterus and embryo. I: Rabbit. II: Man. Jour. Morph., vol. 2.

———, 1892. Human Embryology. New York.

———, 1911. Die Entwicklung des Blutes. In Keibel and Mall's Handbuch der Entwicklungsgeschichte des Menschen, vol. II. Leipzig.

MORGAN, T. H., 1913. Heredity and Sex. New York.

MRACEK, FR., 1903. Die Syphilis der Mutter und der Neugeborenen. Wien. klin. Wchnschr., vol. 16, p. 519–528.

MUGGIA, VIRGINIO, 1915. Contributo allo studio della parziale degenerazione vescicolare partiale della placenta. Folia gynec., Pavia, vol. 2.

MÜLLER, HEINRICH, 1847. Abhandlung über den Bau der Molen. Würzburg.

NATTAN-LARRIER, L., and A. BRINDEAU, 1905[a]. Nature de la môle hydatiforme. Compt. rend. de la Soc. de Biol., vol. 58, p. 97. Paris.

———, ———, 1905[b]. Conditions histologiques du placenta dans l'hérédo-contagion. Compt. rend. Soc. de biol., vol. 59, p. 468. Paris.

———, ———. 1908. À nature de la môle hydatiforme. Rev. de gynec. et de chir. abd., vol. 12. Paris.

NEUMANN, JULIUS, 1897. Ueber Blasenmole und maligne Deciduom. Monatschr. f. Geb. u. Gyn., vol. 6.

NEWCOMB, S., 1904. The probability of causes of the production of sex in human offspring. Carnegie Inst. Wash. Pub. No. 11.

NICHOLS, J. B., 1905. Sex-composition of human families. Amer. Anthropologist, vol. 7, p. 24.

———, 1907. The numerical proportions of the sexes at birth. Mem. Amer. Anthrop. Assn., vol. 1, p. 247.

NILSSON, A., 1917. Svenska Läkaresällskapets Förhandlingar.

NIOSI, FRANCESCO, 1905–6. Corionepitelioma maligno primitivo bilaterale dell' ovaia, non embriomatoso, indipendente da gravidanza e con incipiente formazione de vescicole molari. Atti della Soc. ital. di Ost. e Gin., Roma, vol. 11.

NORRIS, C. C., 1909. Primary ovarian pregnancy and the report of a case combined with intrauterine pregnancy. Surg., Gyn. and Obst., vol. 9.

———, and C. B. MITCHELL, 1908. Primary ovarian pregnancy, with a report of a case. Surg., Gyn. and Obst , vol. 6.

ORLOFF, 1895. Ueber einen Fall von langdauernder Retentio ovi in utero. Prager med. Wchnschr., vol. 20, p. 232.

———, 1896. Ueber einen Fall von langdauernder Retentio ovi in utero. Centralbl. f. Gynäk., vol. 20, p. 262.

ORSCHANSKY, J. G., 1894. Étude sur l'hérédité normal et morbide. Mém. de l'Acad. Imp. des Sciences, St. Pétersburg, vol. 42.

———, 1903. Die Vererbung im gesunden und krankhaften Zustande und die Entstehung des Geschlechts beim Menschen. Stuttgart.

OSTER, KARL R., 1904. Über das spätere Befinden der Frauen nach Geburt einer Blasenmole. Kiel.

OTTO, HEINRICH, 1871. Ueber Tubenschwangerschaft mit Berücksichtigung eines Falles von Graviditas tubaria molaris hydatidosa. I. D. Griefswald.

PALADINO, G., 1899. Sur la structure des villosités du chorion humain au début du développement et sur leurs premiers rapports avec la muquese utérine. Arch. ital. de Biol., vol. 31.

PANUM, P. L., 1860. Untersuchungen über die Entstehung der Missbildungen zunächst in den Eiern der Vögel. Berlin.

PAUCOT, H., and A. DEBEYRE, 1913. Étude sur les grossesses ovariennes jeune. Ann. de gynéc. et d'obst. 2s vol. 10.

PAZZI, M., 1908[a]. Vescicole molari iniziali e nuova orientazione della teoria patogenica della mola vescicolare e del corio-epitelioma. Folia ginec., vol. 1.

———, 1908[b]. La nostre cognizioni intorno alla mola vescicolare ed alla annidificazione dell' uovo. Rassegna d'ostet. e ginecol., vol. 17, pp. 460, 529, 672, 721.

———, 1909. Note di patologia sperimentale e di istologia patologica intorno alla mola vescicolare e considerazioni relative. Ginecol. moderna, vol. 2, p. 577.

PEARL, M., and R. PEARL, 1908. On the relation of race crossing to the sex ratio. Biol. Bull., vol. 15, p. 194.

PEARSON, K., 1897. The chances of death and other studies in evolution. London.

PETERS, H., 1899. Ueber die Einbettung des menschlichen Eies. Wien.

PFANNENSTIEL, J., 1903. Die ersten Veränderungen der Gebärmutter infolge der Schwangerschaft Kapitel III. Von Winckel's Handbuch der Geburtshilfe. Wiesbaden.

PHELPS, E. B., 1910. A statistical study of infant mortality. Pub. Amer. Statistical Ass., vol. 11, p. 233.

PHISALIX, C., 1890. Contribution à la pathôlogie de l'embryon humain. Jour. de l'anat., vol. 26.

PINARD, A., and A. MAGNAN, 1913. Sur la fragilité du sexe mâle. Compt. rend. hebdominaires des séances de l'acad. des sciences, vol. 156, p. 401.

PLOSS, H., 1858. Ueber die das Geschlechtsverhältnis der Kinder bedingenden Ursachen. Monatschr. f. Geburtsk. u. Frauenk., vol. 12.

———, 1861. Ein Blick auf die neuesten Beiträge zur Frage über das Sexualverhältnis der Neugeborenen. Monatschr. f. Geburtsk. u. Frauenk., vol. 17.

———, 1887. Das Weib in der Natur- und Völkerkunde. Leipzig.

POLANO, OSCAR, 1904. Ueber intra-uterine Skelettierung. Zentrabl. f. Gynäk., vol. 28, part 1, p. 448.

POTEN, W., 1901. Beitrag zur Diagnose der Blasenmolen Schwangerschaft. Monatschr. f. Gebh. u. Gynäk., vol. 14.

PRINZING, F., 1905. Die kleine Sterblichkeit des weiblichen Geschlechts in den Kulturstaaten und ihre Ursachen. Arch. f. Rassen- und Gesellschaftsbiologie, vol. 2, p. 253–367.

———, 1906. Handbuch der medizinischen Statistik. Jena.

———, 1907. Die Ursachen der Totgeburt. Allgem. statistisches Arch., vol. 7, p. 21.

PUNNETT, R. C., 1903. On nutrition and sex determination in man. Proc. Camb. Phil. Soc., vol. 12.

PUNTO, CARLO, 1905–06. Die Veränderungen der Decidua und Placenta in der mit Myomen komplizierten Schwangerschaft. Beitr. z. Gebh. und Gynäk., vol. 10.

RAUBER, A., 1900. Der Ueberschuss an Knabengeburten und seine biologische Bedeutung. Leipzig.

v. RECKLINGHAUSEN, F., 1863. Ueber Eiter- und Bindegewebskörperchen. Arch. f. path. Anat. u. Physiol., vol. 28.

———, 1889. Perforierende Blasenmole bei fünfwöchentlicher Tubenschwangerschaft. Deutsch med. Wochenschr. (Merely a society minute.)

RISEL, W., 1895. Demonstration von frischen Präparaten nebst Bemerkungen. Gesellsch. f. Gebh. zu Leipzig. (As reported in Zentralbl. f. Gynäk., 1896.)

ROBERTSON, J. F., 1915. Hydatiform mole; a report of eight cases. N. Y. Med. Jour., vol. 102.

ROBIN, CHARLES, 1846. Rapport sur un cas de mort et de dissolution de l'embryon, par suite d'hemorrhagie des membranes de l'œuf présenté par M. Boussi. Soc. anat. de Paris, Dec. 1846, et Bull. de la Soc. Anat. 3e ser. decimale, vol. 3, 1848.

———, 1854. Recherches sur les modifications graduelles des villosités du chorion et du placenta. Mem. soc. biol., ser. 2, vol. 1.

Robinson, Arthur, 1904. Lectures on the early stages in the development of mammalian ova and on the differentiation of the placenta in different groups of mammals. Jour. Anat. and Phys., Lond., vol. 38, n. s., p. 18.

Robinson, Wm. J., 1919. Abortion historically and ethnologically considered. Amer. Jour. Urology and Sexology, vol. 15.

Roche, J., 1902. De la grossesse ovarienne. Thèse de Lyon.

Roemheld, Ludwig, 1895. Ueber Ursachen und Behandlung der habituellen Früh- und Fehlgeburten. I. D., Heidelberg; also Centralbl. f. Gyn., 1895, vol. 19.

Rokitansky, Carl, 1842–6. Handbuch der pathologischen Anatomie.

———, 1849. A manual of pathological anatomy, vol. III. London.

———, 1861. Lehrbuch der pathologischen Anatomie. Wien.

Rosenfeld, S., 1898. Ueber Bevölkerungsstatistik. Wien. Med. Bl., vol. 21.

———, 1900. Die Sexualproportion in Oesterreich in den Jahren 1895 und 96. Wien. med. Bl., vol. 23.

Rosenkranz, 1903. Skelettierung eines etwa viermonatlichen Foetus im Uterus infolge Fäulnis der Frucht bei missed abortion. Berlin. klin. Wchnschr., vol. 40, p. 1176.

Rossi-Doria, T., 1905. Ueber die Einbettung des menschlichen Eies, studirt an einem kleinen Eie der zweiten Woche. Arch. f. Gynäk., vol. 76.

Rust, J. L. F., 1902. Das Geschlecht der Fehl- und Totgeburten. Strassburg.

Ruth, E., 1918. A study of one hundred and thirty-five human embryos and fetuses collected in the Philippine Islands. Philippine Jour. Sci., sec. B, vol. 13, p. 319.

Sadler, M. T., 1830. The law of population. London.

Saint-Hilaire, Isidore G., 1832. Histoire générale et particulière des anomalies de l'organisation chez l'homme et les animaux, etc. Paris.

Saniter, ———, 1903. Berichte der Gesellsch. f. Gebh. u. Gyn. Berlin. Centralbl. f. Gynäk., vol. 27, p. 920. (Case demonstration.)

Schaeffer, Oskar, 1898. Ueber einjährige Retention eines Abortiveies. Monatschr. f. Gebh., vol. 8.

v. Schaetzel, Peter, 1893. Ueber den Einfluss des Alters der Mutter und der Zahl der vorausgegangenen Schwangerschaften auf Länge und Gewicht der Neugeborenen. Diss., Greifswald.

Schenk, L., 1898. Einfluss auf das Geschlechtsverhältnis. Magdeburg.

Schickele, G., 1905. Die Chorionektodermwucherung in der menschlichen Placenta, ihre Beziehung zu der Entstehung der Cysten und Fibrinknoten der Placenta. Beitr. z. Gebh. u. Gynäk., vol. 10.

———, 1906. Die Malignität der Blasenmole. Arch. f. Gynäk., vol. 78, p. 210–220.

———, 1907. Studien zur Pathologie der menschlichen Placenta. 2 Teil (mit einem Anhang): Die Schicksale retinierter abgestorbener Eier. Beitr. z. Gebh. u. Gynäk., vol. 12.

Schlesinger, Eugen, 1903. Untersuchungen über die Abhängigkeit der autolytischen Prozesse von physiologischen und pathologischen Verhältnissen. Beitr. z. chem. Phys., vol. 4.

Schroeder, van der Kolk, 1851. Waarnemigen over het maaksel van de menschlijke placenta. Amsterdam, p. 49, Taf. V, fig. 26. Given by Virchow.

Schultz, A. H., 1918. Studies in the sex ratio in man. Biol. Bull., vol. 34, p. 257.

———, 1921. Chapter vi of this volume.

Schultze, O., 1903. Zur Frage der geschlechtsbildenden Ursachen. Arch. f. mikr. Anat., vol. 63.

Schwab, A., 1905. De la syphilis du placenta. La Syphilis, vol. 3.

Schwalbe, Gustav, 1906. Die Morphologie der Missbildungen des Menschen und der Tiere. Jena.

Scott, N. S., 1901. Ovarian pregnancy; is it an explanation of ovarian hematomas? Amer. Med., vol. 2.

Seedorff, M., 1915. Ein Fall von geborstener Ovarialgravidität. Monatschr. f. Gebh. u. Gynäk., vol. 42.

Seiler, B. G., 1832. Die Gebärmutter und das Ei des Menschen in den ersten Schwangerschaftsmonaten nach der Natur dargestellt. Dresden.

Seitz, L., 1904[a]. Aetiologie und Mechanismus der vor- und frühzeitigen Geburt. Kapitel vii, von Winckel's Handbuch der Geburtshilfe, ii₂.

———, 1904[b]. Erkrankungen der Placenta. Handbuch der Geburtshilfe, vol. ii, Wiesbaden; F. von Winckel.

———, 1904[c]. Die Veränderungen von Fötus und Placenta nach dem Tode der Frucht. Von Winckel's Handbuch der Geburtshilfe, vol. ii.

Sencert, L., and M Aron, 1914. De l'indépendance qui existe entre le développement du placenta et celui de l'embryon (à propos d' un cas de grossesse ovarienne). Bibliog. anat., vol. 24.

Serebrenikowa, Olga, 1912. Ein Fall von Eierstocksschwangerschaft. Arch. f. Gynäk., vol. 98.

Sfameni, P., 1905. Sulla natura esclusivamente epitheliale delle vescicole nella mola idatigena. Ann. di ostet., vol. 27. Milano.

Siegel, W. P., 1915. Wann ist der Beischlaf befruchtend? Deutsch med. Wchnschr., vol. 41.

Simmonds, M., 1912. Nabelschnurentzündung und Syphilis. Virchow's Arch. f. path. Anat., vol. 209.

Slemons, J. M., 1916. The results of a routine study of the placenta. Am. Jour. Obst., vol. 74.

———, 1917[a]. A case of fetus amorphus anideus. Am. Jour. Obst., vol. 75.

———, 1917[b]. How clearly do the Wassermann reaction and placental histology agree in the diagnosis of syphilis? Amer. Jour. Med. Sci., n. s., vol. 153.

de Snoo, K., 1914. Bijdrage tot de anatomie en de ætiologie der blaasmola. Nederl. Tijdschr. v. Verlosk. en Gynæc., vol. 23, p. 56.

Sokoloff, A., 1896. Experimentelle Beiträge zur Frage über die Wirkung der Eierstockexstirpation auf die Schwangerschaft. Centralbl. f. Gynäk., vol. 20.

Solowij, A., 1899. Über Bösartigkeit der Blasenmole. Verhandl. der deutschen Gesellch. f. Gynäk. Achte. Versammlung.

———, 1902. Zur Kenntnis der pathologischen Anatomie der Plazenta. Monatschr. f. Gebh. u. Gynäk., vol 16.

Sommering, S. T., 1799. Icones embryonum humanorum. Frankfort.

Sormani, G., 1883. L'influence des saisons en Italie sur la distribution des sexes dans les naissances et dans les décès. Quatr. Cong. internat. d'Hyg. et de Démog., vol. 2, p. 732.

Specht, A., 1916. Ueber die Geburt bei Minderjährigen. Zentralbl. f. Gynäk., vol. 40[1], p. 60–74.

Spiegelberg, Otto, 1878. Zur Kasuistik der Ovarialschwangerschaft. Arch. f. Gyn., vol. 13.

Srdinko, O., 1907. Das Geschlechtsverhältnis bei den Geburten in Oesterreich. Arch. f. Gynäk., vol. 84.

Stadler, 1878. Ueber den Einfluss des Alters der Mutter auf das Geschlecht des Kindes. Med. chir. Centralbl., Wien, vol. 13.

Sternberg, Martin, 1910. Ueber sogenannte Fleisch-Blasen-Molen mit langerer Verhaltung im Uterus. I. D., Berlin.

Stieda, W., 1875. Das Sexualverhältnis der Geborenen. Statistische Mittheilungen, 5 Heft, Strassburg.

Stoffel, A., 1905. Untersuchungsergebnisse eines Frühstadium von Blasenmole. Monatschr. f. Geburtsh. u. Gynäk., vol. 21.

Storch, E. D., 1878. Fälle von sogenanntem partiellem Myxom der Placenta. Arch. f. path. Anat., vol. 72.

Strahl, H., 1906. Die Embryonalhüllen der Säuger und die Placenta. Hertwig's Handb. der Vergl. u. exper. Entwckl. der Wirbelth.

———, and R. Beneke, 1910. Ein junger menschlicher Embryo. Wiesbaden.

STRAHL, H., and B. HENNEBERG, 1902–3. Ueber Rückbildungserscheinungen am graviden Säugetieruterus. Anat. Anz., vols. 20 and 21.

STREETER, G. L., 1921. Weight, sitting height, head size, foot length, and menstrual age of the human embryo. Contributions to Embryology, vol. 11, Carnegie Inst. Wash. Pub. No. 274.

STRICKER, WM., 1879. Weitere Mittheilungen zur Lehre von der Menstruation. Arch. f. path. Anat., vol. 78.

STUART, VERRIJN, 1901. Untersuchungen über die Beziehungen zwischen Wohlstand, Natalität und Kindersterblichkeit in den Niederlanden. Ztschr. f. Soz. Wissensch.

STUMPF, MAX, 1892. Aetiologie und Behandlung der Fehl- und Frühgeburten. Münch. med. Wchnschr., Jahr. 40, p. 758.

SUMNER, F. B., 1916. Notes on superfetation and deferred fertilization among mice. Biol. Bull., vol. 30.

SWEENEY, T., 1917. Ovarian pregnancy. Med. Rec., vol. 92; Amer. Jour. Obst., vol. 76.

SZASZ, HUGO, 1903. Ueber durch den Tod des Fœtus begingte histologische Veränderungen der Plazenta. Beitr. f. Gebh. u. Gynäk., vol. 7, p. 145–148.

TARUFFI, 1881–95. Storia della teratologia. Bologna.

TAUSIG, FRED., 1903. Ueber die Breus'sche Hämatommole. Arch. f. Gynäk., vol. 68.

TAUSIG, F. J., 1910. Prevention and Treatment of Abortion. St. Louis.

———, 1911. Hydatiform mole of unusual type. Weekly Bull. St. Louis Med. Soc., vol. 5.

TEACHER, J. H., 1903. On chorio-epithelioma (the so-called deciduoma malignum) and the occurrence of chorio-epithelioma and hydatiform-mole-like structures in tumors of the testes. London Obst. Trans., vol. 45.

THOMPSON, J. F., 1902. Ovarian pregnancy, with report of a case. Trans. Amer. Gynec. Soc., vol. 27.

THOMSEN, O., 1905. Pathologisch-anatomische Veränderungen in der Nachgeburt bei Syphilis. Ziegler's Beiträge, vol. 38.

THURY, M., 1863. Memoire sur la loi de production des sexes chez les plantes, les animaux et l'homme. 2 ed., Genève.

TREICHLER, W., 1895. Statistische Untersuchungen über den Einfluss des Altersverhältnisses der Eltern und der Geburtenfolge auf die Häufigkeit der Totgeburten im Kanton Zürich. Zeitschr. f. schweiz. Stat., vol. 31.

TSCHUPROW. Quoted by Kroon, 1917.

VAN TUSSENBROEK, CATHERINE, 1899a. Ovarialschwangerschaft. (Ein Fall von Schwangerschaft in einem Graaf'schen Follikel.) Centralbl. f. Gynäk., vol. 23.

———, 1899b. Un cas de grossesse ovarienne (Grossesse dans un follicule de Graaf). Ann de gyn. et d'obst., vol. 52.

ULESCO-STRANGONOWA, K., 1896. Beiträge zur Lehre von mikroskopischen Bau der Placenta. Monatschr. f. Geburtsh. u. Gynaek., vol. 3.

URFEY, W., 1901. Ueber den habituellen Tod des Fötus infolge von Endometritis. Beitr. z. Geburtsh. u. Gynäk., vol. 4.

VAN DER HOEVEN, 1900. Ueber die Etiologie der Mole hydatidosa. Arch. f. Gynäk., vol. 62.

VECCHI, MARIO, 1906. Di una particolare alterazione di sviluppo die villi coriali. Note anatomiche per lo studio della mola vescicolare. Raccolta do scritti ostetrico-ginecologici pel Giubileo Didattico del Prof. Senatore Luigu Mangialli. Pavia.

VEIT, J., 1899. Das Deciduoma malignum. Blasenmole und ihr Verhältnis zum Deciduom. Veit's Handb. der Gynäk., vol. III², p. 535–593. Wiesbaden.

———, 1908. Das maligne Chorionepitheliom. Veit's Handb. der Gynäk., vol. III², p. 885.

VELPEAU, ALF. A. L. M., 1855. Embryology ou ovologie humaine contenant l'histoire descriptive et iconographie de l'oeuf humain. Paris.

VINEBERG, H. V., 1911. Hydatid mole. Amer. Jour. Obs., vol. 64.

VIRCHOW, R., 1863. Die krankhaften Geschwülste. Berlin.

———, 1871. Die Cellularpathologie in ihrer Begründung auf physiologische und pathologische Geweblehre. 4th ed. Berlin.

WALDSTEIN, EDMUND, 1913. Ueber Breus'sche Molen und retinierte Eier im allgmeinen. Monatschr. f. Gebh. u. Gynäk., vol. 37.

WALLENSTEIN, F., 1897. Beiträge zur pathologischen Embryologie. I. D., Berlin.

WALTER, 1900. Quoted by Rauber.

WARBANOFF, PETER, 1909. Ein Beitrag zur Graviditas ovarica. I. D., München.

WEBB, A. D., 1911. New Dictionary of Statistics. London.

WEBER, S. L., 1892. Remarks on the differential diagnosis and treatment of cystic degeneration of the chorion. Amer. Jour. Obst.

WEBSTER, J. C. 1901. Human placentation. Chicago.

———, 1904. Study of a specimen of ovarian pregnancy. Amer. Jour. Obst., vol. 50.

———, 1907. A second specimen of ovarian pregnancy. Trans. Amer. Gyn. Soc., vol. 22.

WELCH, W. H., 1888. Hyaline metamorphosis of the placenta, death of fetus in the fourth month and delivery of the unbroken ovum at term. Trans. Amer. Ass. Obst. and Gyn., vol. 1.

WENZEL, CARL, 1893. Alte Erfahrungen im Lichte der neuen Zeit und ihre Anschauungen über die Entstehung von Krankheiten. 1 Blasenmole, Eileiter. Wiesbaden.

WERBER, E. I., 1915. Experimental studies aiming at the control of defective and monstrous development: A survey of recorded monstrosities with special attention to the ophthalmic defects. Anat. Rec., vol. 9.

———, 1916. Blastolysis as a morphogenetic factor in the development of monsters. Anat. Rec., vol. 10.

WERTH, R., 1887. Beiträge zur Anatomie und operativen Behandlung der extrauterinen Schwangerschaft. Stuttgart.

———, 1901. Ovarialschwangerschaft. Handbuch der Geburtsh. von Winckel, vol. II₂. Wiesbaden

———, 1904. Extrauterinsebwangerschaft. Handbuch der Geburtsh. von Winckel, II₂.

WHITEHEAD, J., 1848. On the causes and treatment of abortion and sterility. Philadelphia.

WIENER, HUGO, 1905. Ueber Einfluss der Reaktion auf autolytische Vorgänge. Centralbl. f. Phys., vol. 19, p. 349.

WILLCOX, W., 1904. Proportion of the sexes in the United States. Bureau of the Census, Bull. 14.

WILLIAMS, J. W., 1910. Ovarian pregnancy. Gynecology and abdominal Surgery, Kelly-Noble.

———, 1917. Obstetrics. 4th ed., New York and London.

WILLIAMSON, —. 1900. The pathology and symptoms of hydatiform degeneration of the chorion. Trans. London Obst. Soc., vol. 41.

WILSON, E. B., 1905–12. Studies on chromosomes: I–VIII. Jour. Exper. Zool., vol. 2–13.

v. WINCKEL, F., 1903. Handbuch der Geburtshilfe, vol. 1, H. 1. Wiesbaden.

———, 1904. Handbuch der Geburtshilfe, vol, 1, H. 2. Wiesbaden.

WINCKLER, F. N., 1872. Zur Lehre über die Struktur der menschlichen Placenta. Arch. f. Gynäk., vol. 4.

WINDLE, B. C. A., 1893. On certain early malformations of the embryo. Jour. Anat., vol. 27.

WINTER, GEORGE, 1907. Lehrbuch der gynäkologischen Diagnostik. Dritte Aufl. Leipzig.

WISKOTT, ALBERT, 1882. Das Epithel der Chorionzotten. Würzburg.

WOLFF, BRUNO, 1903. Ueber intrauterine Leichenstarre. Arch. f. Gynäk., vol. 68.

WOODS, F. A., 1906. The non-inheritance of sex in man. Biometrika, vol. 5 ,p. 79.

YOUNG, E. B., and L. J. RHEA, 1911. Ovarian pregnancy: Report of a case. Bost. Med. and Surg. Jour., vol. 164.

CONTRIBUTIONS TO EMBRYOLOGY

VOLUME XII, No. 56

PUBLISHED BY THE CARNEGIE INSTITUTION OF WASHINGTON
WASHINGTON, 1921

MBL/WHOI LIBRARY
WH 18L2